

МІНІСТЕРСТВО ОХОРОНИ ЗДОРОВ'Я УКРАЇНИ
Харківський національний медичний університет

Dermatology. Venereology
Part 1

*Textbook for 4-year stomatological faculty
students trained in English*

Дерматологія. Венерологія
Частина 1

*Учбовий посібник для студентів IV курсу
стоматологічного факультету*

Затверджено
вченою радою ХНМУ.
Протокол № 1 від 25.01.2018.

Харків
ХНМУ
2018

Dermatology.Venereology. Part 1 : textbook for 4-year stomatological faculty students trained in English / comp. A. M. Bilovol, S. G. Tkachenko, A. A. Berehova. – Kharkiv : KNMU, 2017. – 36 p.

Compliers A. M. Bilovol
 S. G. Tkachenko
 A. A. Berehova

Дерматологія. Венерологія. Частина 1 : учбовий посібник для студентів IV курсу стомат. фак-ту / упоряд. А. М. Біловол, С. Г. Ткаченко, А. А. Берегова. – Харків : ХНМУ, 2018. – 36 с/

Упорядники А. М. Біловол
 С. Г. Ткаченко
 А. А. Берегова

Introduction to dermatology

Dermatovenereology – branch of medicine, dealing with the skin, which studies the subjective and objective characteristics of the various clinical manifestations of skin and mucous membranes lesions in their unity and interaction with the environment. This is the medical specialty, that studies etiology, pathogenesis, epidemiology, clinical manifestations, diagnosis, modern treatment and prophylaxis of the skin diseases and sexually transmitted diseases.

Dermatology (from Greec.) derma = skin; logos = science.

Object of dermatology-skin and its derivatives, dermatological pathology and venereological pathology, health of peoples.

Methods: visual, instrumental, laboratorial, clinical, pharmacological, physiotherapeutic and other.

A brief historical outline of the development of dermatovenereology

Mention of skin diseases has been found in written sources of various peoples ever since the appearance of a written language. In Chinese medical books, for instance, relating to 3000–2000 B.C. there are more or less accurate descriptions of leprosy, favus, scabies, ichthyosis, vitiligo, eczema, alopecia, furunculosis, carbuncle, erysipelas and acne. Detailed descriptions of eczema, leprosy, scabies, carbuncles, warts, corns etc. may be found in Egyptian papyrus relating to 3000–1000 B.C. Long before our era, favus, leprosy and other skin diseases were described in the books of Moses. Consequently, dermatology developed spontaneously among different peoples depending on the level of science and the diseases which were most common at the time.

Medicine received further development in ancient Greece, and Hippocrates (460–375 B.C.) was the first to attempt separating medicine from the religious cult. He described many skin diseases and divided them into two groups according to their exogenous or endogenous causes (the theory of abnormal mixture of humours). This humoral theory played a major role in dermatology for a long time. Hippocrates used terms many of which have retained their meaning to this day: herpes, lepra, alopecia, aphthae, carcinoma, ecthyma, petechiae, etc.

The celebrated Persian scholar Abu-Ali al-Husayn ibn-Sina (Avicenna), who was born in 980 and lived for some time in Bukhara, described pemphigus, urticaria, prurigo, guinea worm and distinguished leprosy from elephantiasis. Many of Avicenna's stipulations and prescriptions are still valid to date.

In the feudalism of the middle ages, natural sciences including dermatology, suffered a period of stagnation due to the domination of the church. In 1571 Mercurialis, an Italian, wrote the first textbook of skin diseases *De morbus cutaneus*. At the end of the 18-th century, Vienna professor Josef Plenck wrote textbook of dermatology *Doctrina de morbis cutaneus* (1776), in which he separated all skin diseases into 14 classes according morphological principles.

Ferdinand von Hebra (1816–1880) together with Kaposi (1837–1902), Austrians, elaborated patho-anatomical classification of dermatoses, which was progressive for its time and presented a new stage in the study of skin diseases. They wrote manuals of dermatology, atlases of skin diseases, described some new dermatoses (erythema multiforme exudativum, prurigo, xeroderma pigmentosum, pityriasis rubra pilaris, and others) and conducted research for improving the external methods for treating skin diseases.

The immense advances made by microbiology promoted the development of the aetiological trend in dermatology. The causative agents of many fungus diseases were discovered (the agent of favus in 1839, of parasitic sycosis in 1842, of microsporia in 1843, of trichophytosis in 1844, of leprosy in 1873). Streptococci and staphylococci were described in 1880–1884, the tuberculosis bacillus in 1882, the first filterable virus in 1892, the gonococcus in 1879, treponema pallidum in 1905, and so on.

The origin of native dermatology dates back to the end of the sixties and the beginning to the seventies of the 19th century when the first independent chairs of skin diseases were almost simultaneously organized at the Warsaw University, at the medical faculty of the Moscow University (1869) and at the Medico-Surgical Academy in St. Petersburg (1871) and some later in Kharkov (1876) and Kiev (1883).

Famous dermatologist A. G. Polotebnov (1838–1907) worked in St. Petersburg Medico-Surgical Academy. He proved the connection of the skin diseases with the state of the organism as a whole, and, therefore, the necessity for a thorough clinical analysis of all the morbid changes in the organism of a given patient. In the book *Dermatologicheskkiye issledovaniya* (Dermatological research) and in a series of works under the encompassing title *Nervnye bolezni kozhi* (Nervous diseases of the Skin) Polotebnov and his closest pupils analysed the pathogenesis of some skin diseases (psoriasis, lichen planus and others) and reached the conclusion that the functional disorders of the nervous system were the underlying factors. A. G. Polotebnov was a sturdy champion of climatotherapy, hydrotherapy and electrotherapy.

Prof. A. I. Pospelov (1846–1919), an eminent dermatologist who set up one of best clinics in Europe and an excellent museum of moulages, was the founder of the Moscow dermatological school. His original textbook *Rukovodstvo k izucheniyu kozhnykh boleznei* (Handbook of the Study of skin diseases) was published in seven editions. His works concerned with progressive atrophy of the skin (“crumpled cigarette paper”, Pospelov sign), lupus vulgaris (the “probe” sign) and trophic lesion of the skin are widely known.

Prof. A. I. Kartamyshev (1897–1973), Merited worker of science, headed the chairs of dermatology at the Bashkir and Kiev medical institutes for more than 40 years and at the Central Institute of Postgraduate Medical training for the last 17 years. He is famous for his works in the study of bullous dermatoses,

argentophile fibroses and the use of hypnosuggestive therapy in dermatology (*Gipnoz v dermatologii* [Hypnosis in dermatology] published in 1936).

Prof. M. I. Stukovenkov (1843–1897), a pupil of A. G. Polotebnov represented the Kiev dermatological school. He consistently emphasized the association of many skin diseases with the function of the viscera and, in this way, stressed the need for comprehensive examination of a dermatological patient.

Among the leading dermatologists who worked in Stukovenkov's clinic was his brilliant student Prof. P. V. Nikolsky (1858–1940) who developed the concept of *nervism* in dermatology in describing physiology of the skin and interpreting the pathogenesis of various dermatosis. He substantiated the generally known sign (mild separation of the stratum corneum from the underlying layers) in pemphigus foliaceus which is known in world literature as Nikolsky's sign.

Skin anatomy and histology

The human skin (cutis) is a outer covering of the body and is continuous with the mucous membrane in the region of the mouth, nose, urogenital organs, and the anus.

Skin layers can be divided into (*fig. 1*):

Superficial: Epidermis. Papillary layer of the dermis.

Deep: Reticular layer of the dermis. Hypodermis.

The superficial layers of the skin can give any signs of the skin due to reverse development, while the deep layers shows stable signs of the skin such as scar.

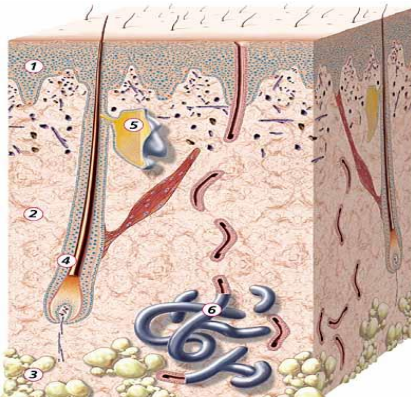


Fig. 1. Structure of Skin

1. Epidermis
2. Dermis
3. Subcutis
4. Hair follicle
5. Sebaceous gland
6. Sweat gland

Epidermis (*fig. 2*). It is a stratified epithelium undergoing kerataization, and consists of the following layers:

1. Germinal layer (*stratum basale*).
2. Prickle of coil layer (*stratum spinosum*).
3. Granular layer (*stratum granulosa*).

4. Stratum lucidum.
5. Horny layer (*stratum corneum*).

All these layers are well pounced on the skin of palm and sole, the stratum lucidum is not found on the face, chest or the flexor surface of the limbs. Stratum granuloosa is found in the areas formed of a single or sometimes of interrupted raw cells.

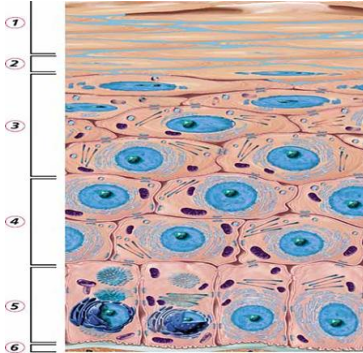


Fig. 2. Schematic diagram of the epidermis: the basal cells change, through differentiation, into flat horny skin cells that are without nuclei.

- 1 Horny layer
- 2 Clear layer
- 3 Granular layer
- 4 Prickle-cell layer
- 5 Basal layer
- 6 Basal membrane

Stratum basale – is the inner most layer of the epidermis and borders directly upon the dermis or the true skin, it consist of a single layer of columnar cells arranged like a palisade between these cells there are spaces called intre-cellular bridges.

Functions:

1. The main sprouting elements of the epidermis from which all cells of the epidermal layer are formed. The columnar cells are arranged perpendicular to the basemeant membrane and these cells are divides by mitosis.
2. The protoplasm of the germinating layer is contains melanin pigment in the form of brown granules of various sizes.

Stratum spinosum – overlies the stratum basale and it consists of 5–10 raw of cells which are cuboida in the deep part of the layer, but become flatter gradually as it approach the next layer and are separated from each other by intra-cellular bridges and comes in contact by means of protoplasmic processes.

Stratum granulosa contains 2-r raw of cells elongated parallel to the epidermis, the nuclei of these cells gradually become smaller and numerous granules are found.

Stratum corneum is the outer most layer of the epidermis; it comes in contact with the external environment. It is composed of fine anuclear keratinized elongated cells; they are firmly attached to each other and are filled with a horny substance (keratin).

Dermis or the true skin is localized between the epidermis and the subcutaneous fatty tissues. It is divided in to two papillary and granular layers.

Papillary layer is that part of dermis which is found between the epidermis and the superficial network of the blood vessels. The reticular layer merges with the subcutaneous fat. The true skin is composed of a fibrous substance, collagen, elastic, and argirophil (precollagen fibers), and a structural amorphous interstitial substance that is found between connective tissue fibers. The dermal papillary layer consists of thin bundles of collagen fibers and many fine elastic and argirophil fibers in the reticular layer the collagen bundles are more compact and thicker and they intertwine into a thick network of loops of collagen bundles determine the mobility of the skin over the underlying tissues and organs.

Muscles of the skin. Muscles stretching obliquely in relation to the hair and rising than on contraction *m. arrector pili* and muscle fibers in the walls of the vessels, and sweat glands smooth voluntary muscles of the skin. When the arrector muscle contracts it rises the hair and squeezes out the secretion from the sebaceous glands smooth muscle fibers which are not connected to the hair follicles are present in the skin of scalp, forehead, cheeks, and dorsal surface hands and feet. Considerable layers are found in the papillary layer of the skin on the scrotum, axilla, nipples, and anus. The muscles which give facial expression are the striated muscles of the skin.

Hypodermis is the deepest part of the skin (subcutaneous tissues) and consists of thick bundles of collagen and elastic fibers, stretching from the reticular layer of the dermis and forming a wide loop reticulum in which there is accumulation of large amount of fatty tissues. The fat cells are almost completely formed of large drop of fat which displace the cell's nucleus to the periphery with very small amount of protoplasm. The skin fascia which is a thick layer of connective tissue plate is also part of the hypodermis and other fuses with the underlying periosteum or aponeurosis of the muscles and form single structure bundles of connective fibers stretch from the superior surface of the fascia to the dermis and form reticulum of Curtis.

Accessory organs of skin:

Glands (sebaceous, sweat gland).

Hair.

Nails.

Skin vessels. The main blood supply to the skin is located within the dermis layer and arises from larger vessels that lie in the subcutaneous fat. Two distinct plexuses can be identified:

Deep vascular plexus which lies in the lower reticular dermis.

Superficial vascular plexus that lies in the upper reticular dermis close to its junction with the papillary dermis.

The dermis contains many arterio-venous anastomosis, includes highly specialized shunts (*Glomus bodies*) which are mainly found in the finger tips. No blood vessels penetrate to the epidermis.

Skin nerves. The nerve supply of the skin is embedded in the dermis and comprises a rich non-myelinated supply derived from sympathetic autonomic nervous system and afferent myelinated and non-myelinated fibers that detect cutaneous sensation.

The most important nerve endings are:

free nerve endings: contains myelinated and non-myelinated fibers that detect the pain, itching, and temperature sensations;

pacinian corpuscles: encapsulated nerve endings that detect pressure and vibration, and usually found in the deep dermis or subcutaneous fat of the sole and palm;

meissner's corpuscles: are found in the papillary dermis, most numerous in the hands and feet and they detect touch sensation;

merkel cells: touch receptors.

Physiology of the skin.

The skin and external mucous membranes separate the human organism from the environment and accomplish a variety of functions.

The most important skin functions:

- Protective (barrier) function
- Sensation function (skin as an organ of sense)
- Thermoregulating function
- Secretory and excretory functions
- Respiratory and resorption functions
- Metabolic function (metabolism of water, minerals – calcium, sodium, potassium, etc; fat, proteins, carbohydrates, hormones, enzymes, vitamins, trace elements).

Histomorphological changes in the skin

Three main types of inflammatory changes are distinguished in the epidermis:

- *Vacuolar degeneration* – intracellular oedema.
- *Spongiosis* – intercellular oedema.
- *Ballooning degeneration* – necrobiotic and degenerative changes in the cells of Malpighian layer.

Besides serous inflammation, the following peculiar pathological changes may be found in the epidermis:

• *Acanthosis* (intensified proliferation of the prickle-cell layer in the form of projections into dermis to this or that depth). In acanthosis the number of mitoses in the basal layer is increased and the connective tissue papillae of the dermis are elongated accordingly, the condition is known as papillomatosis. Acanthosis is encountered in psoriasis and eczema.

• *Acantholysis* is melting of intercellular epithelial bridges, the impairment of firm connections between epithelial cells with the result that cells are easily

separated and form more or less large layers of the desquamating epidermis. Such a process is observed in pemphigus.

- *Dyskeratosis* is abnormal cornification of the cells of the epidermis; it may occur as *hyperkeratosis*, i.e. thickening of the horny layer without changes in the structure of the cells, or *parakeratosis*, i.e. the presence in the horny layer of the epidermis cells with stained rod-shaped nuclei (the granular and clear layers are absent in such cases).

- *Granulosis* is thickening of the granular layer of the epidermis.

General symptomatology of skin diseases

The symptoms of skin diseases can be subjective and objective. The subjective symptoms include itching, burning, pain, paresthesia, disorders of the superficial sensitivity.

The objective symptoms divide of all dermatosis into dermatosis with rash and dermatitis without rash (alopecia, nail disorders, etc.) Skin diseases are changes in the skin structures, changes in the colour, consistency, or appearance of skin rashes. The rash can be represented by primary and secondary morphological elements, which together creates a clinical picture of the dermatosis. All morphological elements can be divided into primary or secondary.

Primary: appears on the unchanged skin. *Secondary*: appears due to reverse development or disorganization of the primary eruption. Also it can be caused by chronic changes of the skin cells without appearing of the primary elements.

For the primary morphological elements are macula/spot, urtica/bleb, nodule/papule, tubercle, node (non-cavitary) and cavitary elements (bulla/blisters, vesicle, pustula). The secondary elements are: secondary spot, scale, crust, erosion, excoriation/abrasion, fissure, ulcer, scar, vegetation, lichenification.

All primary skin elements are divided into: *cavitary* (there is a cavity, covering, and base; it may contain pus or serous) and *non-cavitary*.

Primary non-cavitary lesions:

Spot (Macula): It is a circumscribed alteration in the color of the skin or mucous membrane, in most cases not rise over the surface of the skin and doesn't differ from it consistency. Small inflammatory rose color spots which may reach the size of the nail of the little finger (up to 3 cm) and form a rash called **rosella**. Large vascular spots may reach the size of child palm (more than 5 cm) or even larger are called **erythema**. It is caused by stable non-inflammatory dilation of the superficial vessels (**teleangiectasis**), effusion of the blood to the skin may occurs causing increase in the permeability of the vascular wall and as a result hemorrhagic macula appears. Hemorrhagic macules can be seen in allergic vasculitis, scurvy, and in some infectious diseases (typhus, rubella, and scarlet fever). Pen point hemorrhages – **Pitichia**. Small round multiple hemorrhages – **Purpura**. Large linear hemorrhages – **Vibex**. Effusion of the blood over large area with irregular contours –

Ecchymosis. Massive hemorrhage with swelling of the skin which is raised over the skin surface – **Hematoma.** Primary pigmentation such as fractals, birth marks. Non-inflammatory spots do not disappear in the dioscope (take a piece of glass and press the spot, if it disappears that means it is inflammatory spot).

Papule: It is a solid lesion elevated over the surface of the skin, and when it resolves without forming a scar or cicatricial atrophy. Secondary pigmentation of skin may be seen. Papule which is found on the epidermis is called – **Epidermal papule** (e.g. flat warts). Papule on the dermis – **Dermal papule** (e.g. secondary syphilis). Papule varies in size from pen head (1–2 mm) to a coin size or larger (up to 3 cm). Papules of a millet seed or pen head size (3–4 mm) – **Miliary** (e.g. in case of lichopalms). Pea size papule (5 mm–1 cm) – **Lenticular** (e.g. psoriasis and secondary syphilis). Coin size papule (1–3 cm) – **Neumolar.**

Tubercle: It is an infiltrative solid skin elevation of non-inflammatory character. It often ulcerates and terminates by formation of secondary cicatricial atrophy or scar. It is difficult to distinguish it from nodule. *Scar:* when the tubercle is disappear with destruction of the epidermis layer (before scar there is always ulcer). *Scar atrophy:* when the tubercle is disappears without destruction of the epidermis, the pathological cells are substituted with connective tissues.

Node/nodule: It is an infiltrative primary morphological lesion with acute inflammation. Pea to walnut in size (1–5 cm). It is situated in the subcutaneous fat. At first it may not raise over the skin surface, but with its growth it gradually become elevated. The nodule often ulcerates and eventually cicatrized.

Exudative non-cavitary primary lesions:

Wheal/Urtica (bleb): It is an exudative non-cavitary lesion which is formed as a result of circumscribed acute inflammatory edema of the papillary skin. It is elevation spherical or oval in shape with an itchy character. It is a limited edema of the papillary layer. It is present of short period of time. It causes secondary pigmentation of the skin.

Exudative cavitary primary lesions:

Vesicle: It is a primary morphological lesion with an exudative character. It has a cavity which is filled with a fluid, floor and covering. The vesicle may situate under the horny layer of the epidermis. Is a small spherical formation and contains fluid inside it. It is small in size (up to 5 mm) and localized epidermis.

Bulla: It is a primary morphological lesion (1–5 cm in size) with an exudative character. Like the vesicle it contains a cavity with serous fluid, covering and floor. Bulla under the horny layer – **Subcorneal.** Bulla in the prickle layer of the epidermis – **Intraepidermal.** Bulla between epidermis and dermis – **Subdermal.**

Pustule: It is a primary morphological lesion with an exudative character and *contains pus, considerable amount of leucocytes and albumin.* Under the affects of the products of the vital activity of the microbes (mainly

streptococcus and staphylococcus) the epithelial cells undergoes necrosis which cause the appearance of cavity of the pustule. Pustules that are located in the thickness of the epidermis have a marked tendency to form a crest and hence it is called (**impetigo**) and after the crest drops and a permanent skin pigmentation appears. It can be localized in the epidermis or under it. All pustuls can be superficial or deep. It can be localized in the reticular layer of the dermis and so it can produce scar.

Secondary morphological lesions:

Pigmentation: Secondary hypermelanotic spot or hypomelanotic spot.

Scale (squami): It is physiological shading of the lamina of the horny layer which occurs continuously under the normal conditions. This lamina is removed by washing, drooping of the cloths against the skin and it is invisible in healthy skin. Scaling is a pathological abnormal processe which seen by the naked eyes. Scaling usually indicates an epidermal disorder and can result from faulty differentiation of the epidermis (ichthyosis) or accelerated turnover of the epidermis (psoriasis).

Crust: is formed when the serous exudate, pus, or blood dried up.

There are serous, purulent, serous-purulent and angiopurulent forms of crust.

Laminated massive oyster like crest is called **Rupia**, in which the upper part is the oldest and the smallest.

Superficial fissure: superficial defect of skin which does not penetrate behind the epidermis and has healed without leaving a trace.

Deep fissure (rages): deep defect of skin in the epidermis and the dermis and sometimes with the involvement of the deeper tissues. It leaves a scar after healing.

Excoriation: it is a skin defect resulting from scratching or other traumatic damage to the skin. Scratching may affect the epidermis and the papillary layer as well. Scars are not formed.

Erosion: it is a superficial skin defect within the epidermis. It appears after rupture of a vesicle, bulla, or pustule. It is pink in color and usually has a moist surface with large necrotic skin and mucosa (e.g. observed in Pemiphigus).

Ulcer: It is a skin defect with involvement of the epidermis, dermis and even deeper layers. Ulcer develop from tubercle, nodule, and after rupture of a deep pustule. Trophic ulcer is formed as a result of primary necrosis of the healthy tissues.

Scar (cicatrix): is formed in place of deep defects in the skin which replaced by fibrous connective tissues (collagen).

Scar atrophy: it is a condition with softer and less mass of connective tissue than in scar. The affected skin is very thin, devoid of the normal pattern and often depressed below the level of the smooth skin. Scar atrophy developed without preceding ulceration of the lesion.

Lichenification: it is thickening and hardening of the skin marked by disruption of skin normal patterns, hyper-pigmentation, dryness, and roughness of the skin. This may be caused by abnormal and/or excessive scratching or rubbing of the affected area.

Vegetation: is a growth of pathologic tissue consisting of multiple closely set papillary masses. Develop in the region of persisting inflammatory process, as a result of intensified proliferation of the epithelium.

True polymorphism: condition characterized by several primary morphological lesions.

False polymorphism: characterized by several primary morphological lesions with a few secondary morphological lesions.

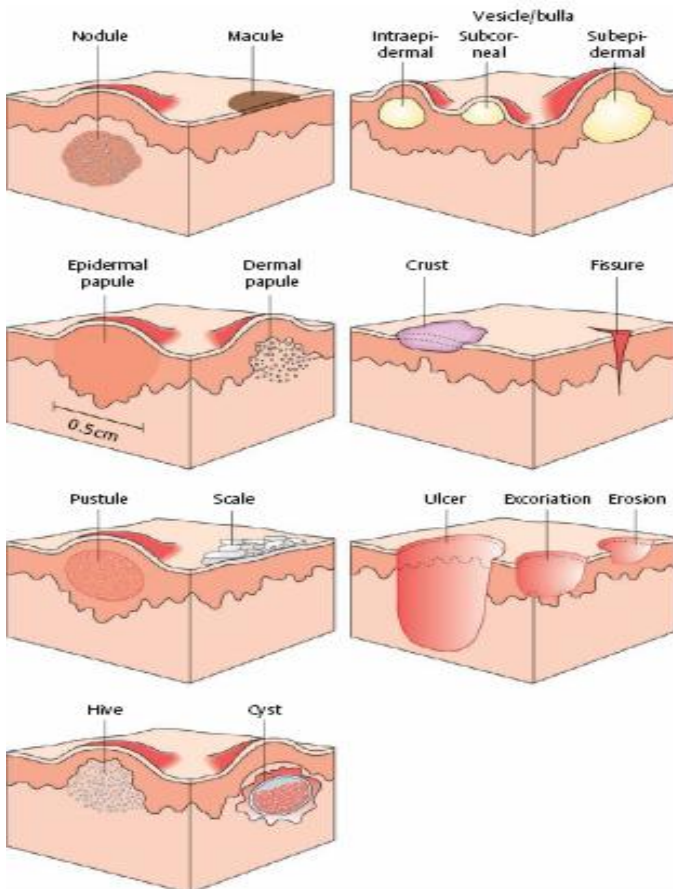


Fig. 3. Morphological elements of rash

Examination and description of skin.

The keys to successful diagnosis are systemic and complete skin examination, an understanding of anatomy and physiology of the skin, and the use of basic dermatologic terminology. Dermatology is a visual specialty. The careful morphologic description of cutaneous changes is at the center of dermatologic diagnosis. This skill must be learned, as it often leads to the correct diagnosis in itself, and cannot be replaced by laboratory examinations or other investigative procedures.

Examination of the skin in a room with daylight should include:

- palms and soles, ears, submammary, interdigital, axillary, inguinal, genital, and perianal skin.
- adjacent mucosa including lips, mouth, conjunctivae, nasal mucosa, and in some instances anus.
- skin appendages (hair and nails) as well as scalp.
- assessment of general skin appearance (color, texture, dryness, hydration, odor).
- evidence for exposure to sunlight, nicotine, other noxious agents.

Match objective evidence to subjective complaints; a patient who denies itch but has numerous excoriations may have an underlying psychosocial problem.

Description of skin lesions

Primary lesions:

- Flat; not palpable or raised, palpable
- Color: red (erythema, telangiectases, leakage of blood), blue (cyanosis, hematoma, dermal melanin), brown (dermal and epidermal melanin, hemosiderin), white (anemia, vasoconstriction, loss of melanin), yellow (carotenoids, bile, solar elastosis), gray-black (epidermal melanin, heavy metals, tar, dithranol, foreign bodies), decorative tattoos can have many colors. Both name of color and its nature (uniform, irregular, patchy).

• Configuration. Circinate: arched or rounded border. Annular: circular or ring-shaped. Discoid, nummular: disk or coin-shaped. Serpiginous: winding, twisting (snake-like). Iris or cockade (target-like) and many more, including oval, finger-shaped, leaf-like, swirled, or starry.

- Border: Sharp (well-circumscribed) or vague (blurred).
- Surface: Smooth, rough, warty, vegetating, glistening, dull.
- Consistency: Soft, doughy, hard, fluctuant, lobed, knotty, moveable, fixed, attached to
- Patterns of Distribution: Linear: following a line. Lines of Blaschko: following embryologic skin lines. Reticular: net-like. Grouped. Herpetiform: arranged in clusters, grape-like. Zosteriform: following a dermatome.
- Discrete: Solitary. Confluent: blending together. Chessboard pattern: arranged in rectangular patterns. Disseminated: randomly distributed.

Description of General Skin Condition, Vascular Status, and associated Findings

- General terms: Xerotic (dry), seborrheic (oily), ichthyotic (scaly), actinic damage, atrophic, thickened, abnormal texture, hyper-, hypo- or anhidrotic.

- Vascular status: Cyanotic, pale, cold, warm, edematous, with varicosities, necrotic.

- Nature of wound healing: Central or peripheral healing, with scarring or atrophy.

- Dynamics of lesion: All lesions in same stage or lesions in different stages.

- Associated findings: Lymphadenopathy, fever, malaise, as examples.

- Simple Clinical Tests. These tests can be done during the initial examination.

- Palpation: Consistency, movability, adherence, borders, painful or tender, pulsation? Skin warm/cold, moist/dry? Peripheral pulses?

- Remove crusts: bleeding, base of wound, extent of lesion.

- Express secretions: nature, consistency, color, odor, amount.

- Pull off scales or deposits: easily removed, firmly attached. Scales mean epidermal involvement. Always remove scales or crusts; they may be “hiding” an underlying tumor.

- Tug on hairs: easily breakable, readily removed, hair bulb visible.

- Insert probe: Can be used to explore sinus tract; used in the past to analyze tubercular lesions, which were relatively insensitive to such pressure.

- Provocation tests: Manipulate lesions by rubbing, pressing, applying heat or cold, having patient exercise.

- Look for specific clinical signs: Dermographism, pathergy, Nikolski phenomenon, Darier sign and etc.

Methods of investigation of skin.

1. Procedure of Dermographism Determination

Dermographism is a vascular reaction of skin to mechanic irritants caused by linear pressure on the skin with the blunt thing. Normal dermographism is characterized by the wide pink-red line which disappears in 1–3 minutes. In case of red dermographism a strip is wide and elevated. It lasts up to 15–20 minutes and it is accompanied by slight itching (eczema, psoriasis). White line appears in 15–20 seconds in case of white dermographism. It disappears in 5–10 minutes (atopic dermatitis (AD), prurigo). White line changes red in case of mixed dermographism. Urticarial dermographism persists for 30–40 minutes in the form of acute elevated edematous wide lines.

2. Diascopy Performing Procedure

Diascopy (vitropression) is performed with an object-plate or glass spatula pressing on the skin element. It gives an opportunity to distinguish inflammatory spot from non-inflammatory (hemorrhagic, pigmental) one. Inflammatory spot turns pale on diascopy and non-inflammatory one almost doesn't change.

3. Palpation Performing Procedure

Palpation (touching) is an important diagnostic method which requires certain experience and skills. Skin elasticity and tonicity are determined by palpation. But it should be kept in mind that tonicity and elasticity on different areas of total skin cover in one person aren't the same. Age skin changes are also taken into consideration (reduction of skin turgor and elasticity in elderly and old people). Palpation is rather useful in case of hyperelastic skin. Growth or reduction of skin temperature (erysipelas, deep staphylococcus pyoderma, erythrodermia, Raynaud's disease, scleroderma and others), element localization (epidermis, dermis, subcutaneous tissue), its sizes, shape, consistence, its connection to surrounding tissues, and tenderness can be determined by palpation. In case of edema its intensity is determined by palpation. The presence of fluctuation symptoms (abscess, hydradenitis) and tenderness absence (chancre) are also determined by palpation.

4. Methods of Examination of Skin Temperature, Pain and Tactile Sensibility

In order to determine tactile sensibility a swab and medical brush are used. They are applied on a certain skin area and the patient doesn't have to see the doctor's arms but to tell about his sensations. In order to determine temperature sensibility one uses two test-tubes which are filled with cold and warm water. Then a specialist touches in turn the skin surface with the help of these test-tubes and asks the patient about his sensations. In order to determine pain sensibility any sharp thing is used (more often it is a sewingneedle). With the help of it a specialist presses on the skin area and asks the patient about his pain sensations.

5. Methods of Skin Turgor and Elasticity Determination

This procedure is done by palpation (skin is taken into the fold with fingers) and also with the skin stroking and pressing on it. It is possible to judge about skin turgor and elasticity for the period of fold expanding on the back of the hand. It expands immediately in case of good turgor. It keeps on up to several minutes in case of reduced turgor and in old people. Skin with good tone is smooth without wrinkles. It is hard to form a skin fold. There are wrinkles on the skin with reduced tone. It is possible to form a fold. There are local foci of flaccid skin on the face. Atonic skin is very thin and flaccid. There are constant wrinkles. Flaccidness is especially seen in the para-orbital and perioral areas. Folds occur arbitrarily.

6. Methods of Scraping off Procedure (grattage). Scraping off procedure (grattage) is widespread diagnostic method in dermatology and venereology. It is done by subject glass or dull scalpel. It is possible to reveal skin peeling and its type (flour like, bran-like, small lamella, big lamella), density of flakes attachment to the skin surface using this method. We can also determine flakes and crusts cohesion with the elements of underlying eruption of the skin, the degree of crusts dryness and wetness, the condition of the skin surface under them. Feeling of pain is sometimes marked during scraping off procedure (symptom of Besnier and Meshchersky in discoid lupus erythematosus). This method is also used in psoriasis for which the following phenomena as "stearine striae", "psoriatic or terminal film" and "point-like hemorrhage" or "blood dew"

are typical. It is use din Tinea versicolor, pityriasis versicolor or haole rot, parapsorias. It is necessary to warn aboutthe nail scraping off as contamination is possible to occur at this procedure (dermatomycosis, papular syphilid).

7. Skin Tests Performing Methods. Skin tests are common methods of etiological diagnostics of allergic dermatoses. Main goal of skin test is detection of main allergens which weren't obtained in the medical history andconfirmation of allergens indicated in the anamnesis.

a. Drop Skin Testing

Drops of substance (different concentration) to be tested are placed on the skin of forearm (free from rash). Control test sample with isotonic solution of sodium chloride or distilled water (dissolvent) is applied at the same time. The results are registered in 20 minutes, 24 and 48 hours from the period of substance application. Erythema, edema, papules, vesicles developon the site of drop applied in case of positive reaction. More sensitive compress test is possiblein case of negative reaction.

b. Compress Test

Skin on the internal part of the foream is treated with 70 per cent alcohol for degreasing. A drop of substance to be tested is put on the piece of gauze (approximately 1 square centimeter) and it is rolled into 4–6 layers. Prepared piece of gauze is applied on the foramen. Then it is covered by compress paper 2x3 cm and fixed by sticking plaster. This test is estimated in a day, but if there are any complaints, it is done earlier. Test is repeated in 24–72 hours. Positive reaction develops differently – from small erythema or single rashes up to spotty erythema with edema and vesiculation exceeding the boundaries of compress.

c. Intra-Dermal Test

It is necessary to have individual tuberculin syringe and thin needle with short point for every allergen. The test is done according to the rules of scarification test. The skin is tightened down. The needle is put inside under the small angle according to the skin surface to be completely in epidermis. The distance between the points of injections is 4–5 cm. The volume of medicine and fluid to be dissolved is 0.02 ml which is equal to papilla of 2 mm in diameter. Reaction is checked in 15–20 minutes and 24 hours according to the special table

d. Scarification Skin Test

Internal skin surface of the foream is treated with 70 per cent of alcohol. Special substance, dissolvent and 0,01 per cent of histamine solution in sterile saline solution in the ratio 1 : 10 are applied by drops on the distance of 4–5 cm separately with the help of tuberculin syringe. Two parallel scratches of 5 mm in length with interval of 3 mm between them without blood vessels injuries are done along the skin above the drop with the help of sterile scarifier (with smallpox-vaccination lancet, injection needle). Drops are taken away with sterile wad of cotton wool in 5–10 minutes. These wads of cotton wool are taken as scarifiers separately for every drop. Reaction is "identified" in 15–20 minutes (immediate type of allergic reaction).

8. Methods of Scab Mites' Burrows Identification

Simple and available method is used in order to reveal the burrows of scab mites. Infected part of skin is treated with iodine alcohol solution or some aniline dye substance. The dye substance penetrates into the linear burrow left by scab female mite during its moving through the skin and definitely makes contour of it in the form of colored line 3–5 mm deep. Sometimes this line (its moving) is like a dash (dotted-type) that depends on the canal infestations with scab mite eggs or excrements.

9. Methods of Laboratory Diagnostics of Scabies

Diagnostics of parasitic skin disease- scabies means a detection of scab mite in its burrows. There are several ways of scab mites detection. The most traditional approach is scab mite's extraction with the help of needle from the blunt part of burrow, exactly in the place, where black point or scab mite female is seen. To remove scab mite with the help of needle, move needle along the burrow and the scab mite attaches as a rule to the needle. Scab mite is put on the subject glass on the drop of 10 per cent sodium hydroxide and then it is examined under the microscope. The method of thin section is used in case of fresh rash absence. This procedure can be done with the help of scalpel, blade or by scraping off from epidermis corneous layer at the place of scab mite's burrow or wheal. Then it is treated with 20 per cent sodium hydroxide with 5 minutes exposition and the following examination under the microscope. This method reveals not only the scab mite, but also its eggs. Scraping-off method with the use of 10–20 per cent alkali or 40 per cent lactic acid is also one of the easiest methods of diagnostic material gathering. These substances are used for epidermis corneous layer opening before scraping-off procedure and for clearing of diagnostic material before it is put under the microscope. A drop of 10–20 per cent alkali or 40 per cent lactic acid is applied on the scab mite's burrow. Opened epidermis in the place of scab mite's burrow is scrapped off in 5 minutes. Then it is put on the subject glass on the drop of lactic acid, then covered with micro-glass, it is immediately examined under the microscope with slight enlargement. The result is considered to be positive, if scab mite female, its eggs, larvae, egg capsules or even one of the mentioned above elements have been revealed during the procedure.

10. Methods of laboratory diagnostics of demodecosis

Microscopic method is the main one for diagnosis of demodecosis. Clinical diagnosis of demodecosis is confirmed in case scab mite is revealed in the scrapes from the rash on the face or in the secretion from sebaceous-hair follicles at the site of nasal buccal folds, eye-lashes and eye-brows. Received material for examination is put on the clean subject glass with the drop of saline solution and investigated without adding special substances during first 5–10 minutes after its collecting.

11. Methods of Baltzer's testing

Baltzer's test is used for *Tinea versicolor* (pityriasis versicolor or haole rot) diagnostics. Spots are treated with alcohol solution of 3–5 per cent iodine. Corneous layer becomes flaccid on the rash as iodine solution is absorbed here better and the spot is colored more intensively than the healthy skin.

12. Phenomenon of "honey comb"

A phenomenon of "honey comb" occurs in patients with infiltrative purulent trichophytia. Focally located pus drops occur on the surface of plaque when they are pressed. They look like honey drops when honey combs are opened.

13. Methods of luminescence diagnostics performance with the help of Wood's lamp

Wood's lamp is a portable mercury quartz lamp of special construction. Wood's filter (a glass impregnated by nickel salts) is used in this construction in order to stop long-waved parts of the ray. Diagnostics is performed in the dark room. Glow of different colors will be noted during examination of damaged skin foci or scalp. It will be bright green in case of microsporia of scalp. In *Tinea versicolor* of scalp it will be yellow-brown and it will be coralred in erythrasma.

14. Methods of fungal diseases examination

Correct procedure methods of collecting material for examination and its bacterial analysis are important for receiving reliable laboratory results of fungal infection. It is necessary to take pathological material if there is such a possibility. Scraping from the lamellae or scraps of macerated corneous layer is done with the help of scalpel or curette mainly from the peripheral focus zone in patients with skin affection. This procedure is performed in patients with foci of skin damage. Wheals and pustules covers which are taken with the help of tweezers for depilation are supposed to be examined too. Film from the mucous membrane of the oral cavity and genitals can be taken with the help of sharp curette or scalpel. And it is necessary to take material for examination from folds depths, from the bottom of fissures if it is possible. If there are some ulcerous lesions covered with crusts or papillomatous neoplasms it is necessary to take material for analysis from under neath edges of ulcer, from peripheral border surrounding the ulcer. It is recommended to place the patient under the light so that it is possible to see the broken hair not in the falling but in the transmitted light for taking hair infected with fungi. It is important, infected with fungi hair is not only broken, it loses its elasticity and often changes its colour. Fragments of broken hair become vertical and rather visible among healthy hair after passing the foci of affection over for several times by a finger or spatula. Upper lustrous layer is removed with the help of scalpel, then scraping is done from the deeper nail layers and also from under the nail corneous masses for examination of material of injured nail plates.

Microscopic analysis of pathological preparations is the first and basic method for detection of fungal diseases. All examinations are done depending on the object type, in 10–20 per cent alkaline solution (KOH or NaOH) or in

the glycerin drop, or in the saline solution. It is possible to warm scraping substances from skin, nails or others in the alkaline solution putting it 3–4 times over the burner flame in order to fasten the cleansing process. Warming in the alkaline solution should be done very carefully for examination of hair. It's better not to use this procedure for analysis as hair destruction or impairment of hair and fungus interposition may occur. Sufficient cleansing of the hair starts without warming after the hair is put into the alkaline solution for 15–20 minutes. To examine preparations from the skin foci and nail plates, it is necessary to examine a greater number of them. Puss from pustules, abscesses, fistulous tracts and so on taken with the help of ansa, pipette or by expulsion or puncture procedure is analysed on the subject glass in the drop under the micro-glass. In this case liquid pus is analysed in the drop, thick one, especially with flakes and grains, in the alkaline solution with warming or in the glycerin. Sputum (phlegm) is examined the same way as pus. Spinal fluid and urine, different kinds of exudates are centrifuged and deposition is examined for fungi presence. Prepared by different means substances are investigated under small magnification and then under a bigger one. Fungus elements are like thread lines and spores of different sizes and shapes in the skin scales, in the scrapes from the nails and also in the pus, sputum and mucus. Due to this fact various kinds and genus of fungi can often provide rather similar microscopic pictures. But from other side the same fungus can give different pictures under microscope depending on the stage of fungal process development, foci localization and so on. That's why in majority cases the type and genus of fungus can't be determined according to its microscopic picture, for example, in skin scales or nail scrape. Precise data concerning both the number of fungal elements and their morphology should be given in the laboratory analysis. Determination of fungal causative agent species and genus by means of its cultivation is of great importance as it permits to reveal and study the ways of fungal infection spreading and its source and also to work out effective methods of treatment and corresponding preventive measures for it. In order to cultivate the fungal causative agent species the sowings on different hard and liquid media are made. Due to this procedure one gets growth of colonies which are characterized by both peculiarities of their external forms and also microscopic structure. Sabouraud medium is widely used for revealing of pathogenic fungi types.

15. **Disinfection methods** of the patients' clothes and shoes suffering from fungal diseases. Shoes disinfection is done with the help of fungicide chemical solutions. If there are no conditions for chambered disinfection, shoes inside should be wiped carefully with wad moistened richly with 10–30 per cent formaldehyde solution. Then they should be wrapped into thick paper or put in the cellophane package for 2–3 days. Then shoes are supposed to be aired and dried for 12–24 hours. The shoes inside may be also wiped with the swab moistened with ammonia spirit and then with dry cotton waste. These shoes will be ready for wearing in 2–3 hours. If one adds 5 per cent (according to the

weight) chloramine or para-chlorbenzenesodium-sulfur-chloramide substances to 10 per cent formaldehyde solution then disinfection may be done for 15–20 minutes. Clothes, underwear, socks and stockings disinfection is made with the help of soap in a boiling water for about 10–15 minutes, in 1 per cent soda or soap and soda solution. Then all clothes and underwear are supposed to be ironed by a hot iron with vapor.

16. **Koebner phenomenon** (isomorphic reaction)

Koebner phenomenon (isomorphic reaction) is peculiar to some diseases especially for psoriasis and lichen planus in the aggravation stage. New papules (which are typical for this dermatosis) occur in the places of mechanical injuries of the skin (cutting, scratch, burning, beat, abrasion).

17. **Wickham's striae**

Wickham's striae are whitish lines visible in the papules of lichen planus. Liquid oil is applied on the papule or plaque and on the top of the element a whitish opal dots and crosslines in the form of net can be observed. This phenomenon is explained by unequal thickening of epidermis granular layer (granulosis) which is typical for this disease.

18. **Dosimetry methods of ultra-violet irradiation**

Biological method of dosimetry is used in case of ultra-violet irradiation. It is based on the determination of individual sensitivity to ultraviolet radiation. One biological dose is taken for dose unit. Biological dose is irradiation time after which in a definite time (latent period) the weakest erythema with clearly marked edges occurs on the skin. Biological dose is frequently determined by 50 cm distance from the lamp to the surface of the abdomen skin ectad from the middle line. Gorbachev- Dalfeld biososimeter is used for this purpose. It consists of metal plate (10 × 6 cm) with 6 rectangular openings, which are closed by moving damper. Biososimeter is sewed into the oil cloth and is provided with the tape for its fixation on the patient's body. Biodose determination includes:

- patient's position- a patient is on his back. A patient puts on protective glasses;
- biososimeter with closed windows is fixed on the skin surface. Body areas which aren't supposed to be radiated are covered with the sheet;
- the lamp is put on the vertical line to the biososimeter measuring the necessary distance with the help of centimeter tape (from reflector screw up to the biososimeter surface);
- biososimeter ports are opened consecutively in every 30 seconds and irradiation is done;
- reflector with the lamp is quickly put aside after irradiation by the sixth port.

The skin under the first port is irradiated for 3 minutes, under the second – 2.5 minutes and soon and under the sixth one it is irradiated for 30 seconds. Skin erythematous reaction develops in 6–8 hours after irradiation. Biological dose should be determined in 20–24 hours after irradiation. It is necessary to establish what irradiation duration corresponds to erythema of minimal intensity.

If there are 5 lines of increasing brightness then one biological dose is equal to 1 minute; if there are 4 lines then it is 1 minute and 30 seconds and so on. This biological dose corresponds to the patient with the lamp and distance which were taken for irradiation. Irradiation is done from different distances depending on therapeutic goals: 100, 75, 50, 25 cm. It is necessary to make mathematic calculations of biological dose for new distance. The following formula is suggested for these aims: $X = A \times B^2/C^2$. Where X is a required biological dose in minutes. A is a biological dose in minutes from 50 cm distance. B is the distance from which it is necessary to perform irradiation. C is a standard distance for biodose determination (50 cm). An example – biodose (from 50 cm distance) is equal to 1 minute. It is necessary to determine a biodose from the distance of 100 cm. The answer is that one biological dose from the distance of 100 will be 4 minutes. An "average biological dose" of the lamp for urgent irradiations (erysipelas, wounds and soon) is used as a rule. In order to determine this dose it is necessary to determine a biological dose in 10–12 completely healthy people. The arithmetic average amount among all the determined biological doses is "an average one". Lamp passport is made according to these data and it is necessary to repeat it every 3 months. An example of lamp passport: 100 cm-1 biological dose – 4 minutes; 50 cm – 1 biological dose – 1 minute; 25 cm – 1 biological dose – 15 seconds.

19. **Nikolsky's sign**

Nikolsky's sign has a diagnostic value especially in case of true pemphigus. Abruption of epidermis upper layers is observed alter the endings of bulla covering are pulled with the tweezers. It is seen not only in the bulla but also on the visibly healthy skin. This symptom is caused by acantholysis.

It also can be observed in chronic benign family pemphigus, bullous pemphigoid, toxic Lyell's necrolysis, pemphigus vegetans. Epidermis abruption is also caused by light finger rubbing between two bullae. This symptom rarely may be positive in the areas far from bullae.

20. **Asboe-Hansen sign**

In case of Asboe-Hansen sign bulla volume increases after the uninjured one is being pressed as liquid pressure leads to abruption of the bulla covering along its periphery. It is observed almost in all pemphigus dermatosis and it is mainly the variant of Nikolsky's sign.

21. **Examination methods of bullae and vesicles content** in dermatitis herpetiformis (Duhring's disease)

The surface of element is wiped with swab moistened with alcohol and then cavernous part is punctured with sterile syringe (insulin one is better). A liquid received is analyzed under microscope. Eosinophilia in bullous liquid is present 30–50 per cent in dermatitis herpetiformis (Duhring's disease).

22. **Jadassohn's test**

Jadassohn's test with potassium iodide is of great diagnostic value for differentiation of dermatitis herpetiformis (Duhring's disease) from true pemphigus. An increased patients'sensitivity to halogens or halogen elements (iodine) is

typical for dermatitis herpetiformis (Duhring's disease). 50 per cent potassium iodide ointment is applied on the forearm skin which is free from rash. If this test has positive results then burning, itching, erythema, sometimes papules and vesicles (local reaction) will develop on the site of ointment application in 24 hours. Worsening of general condition may develop (total reaction) too.

23. Tzanck's acantholytic cells testing methods

Cytologic diagnostic method of bullous dermatosis was first suggested by A. Tzanck in 1947 for examination of patients suffering from pemphigus vulgaris. This method is essential for differential diagnostics between pemphigus and dermatitis herpetiformis (Duhring's disease). Examination material is taken from the bottom surface of new bulla. The sterile degreased subject glass (method of imprints) is applied and slightly pressed, then fixed with methyl alcohol for one minute. Then it is dried in the room temperature and fresh Giemsa stain (azur- eosin solution) is applied for 20–25 minutes. Dye is washed with distilled water and smear is dried in the room temperature. After preparation and dyeing procedures all materials are examined under the microscope with 10×40 magnification. Acantholytic cells are smaller than normal epithelial ones. They are round with big nucleus dyed in intense violet or violet blue colour occupying almost the whole cell. Two or several big bright nucleoli are seen in the nucleus. Cytoplasm is closer to periphery (border of concentration). It is sharply basophilic. It is light blue closer to the nucleus. A number of cells is different- from isolated ones to a great number (clusters like).

24. Besnier–Meshchersky sign and the symptom of a "woman's heel"

Besnier–Meshchersky sign is observed in patients with discoid lupus erythematosus. There are spicules like a "woman's heel" (the symptom of a "woman's heel") under neath after corneous scales are scraped with the subject glass. Scaling is usually accompanied by morbidity (Besnier–Meshchersky sign).

25. Examination methods for lupus erythematosus cells (LE-cells) detection

Patient's freshly taken peripheral blood is examined. A procedure of two hours blood clot is the most suitable and used; 10–15 ml of blood is taken into the sterile tube keeping it in the thermostat at the temperature of 37 °C. Blood clot is separated from the tube walls with the thin metal net and received material is centrifuged. There are three layers after this procedure. The upper layer (plasma) is aspirated with pipette and removed; the second layer (leucocytes) is aspirated carefully and some smears are prepared and stained. Then the smear is examined under the microscope with 10×8 magnification, some shady parts are examined under the microscope with 10×40 magnification. This test is considered to be positive if 2–3 typical cells of lupus erythematosus are revealed. They are considerably bigger than normal leucocytes. Their nucleus is intensively stained and pushed to periphery. There is phagocytic mass which is more marked and localized in the center in the form of rosette. The result is considered to be negative if LE-cells are not revealed after examination of several hundreds of leucocytes in 2–3 smears.

26. A sign of probe dipping (Pospelov's sign)

Tubercles in case of tuberculosis of skin (especially in Lupus vulgaris) get pasty, soft due to collagen and elastic fibers destruction. Taking into consideration this peculiarity A. I. Pospelov (1886) suggested the sign of probe dipping. Dipping occurs on the surface of tubercle after a light press on the tubercle with button-like probe. It disappears very slowly. The probe as if deepens into the tubercle (lupoma) after a hard press on the tubercle with button-like probe. Light bleeding and insignificant morbidity occur during this procedure. The sign is more marked in the new lupoma.

27. The "apple jelly" symptom

The symptom of "apple jelly" is a diagnostic procedure in tuberculosis of skin (especially in Lupus vulgaris). The blood is flowing out from dilated vessels of the tubercle and the brownish-yellow staining occurs looking like an apple jelly after the lupoma is pressed hard with transparent spatula or subject glass.

28. Method of hard chancre palpation (ulcus durum)

There is a marked easily detected induration on the base of hard chancre, especially its ulcerous form. To determine this peculiarity, the hard chancre is slightly pressed with fingers in gloves at its base and pushed up ward. Infiltration usually exceeds 1–2 mm the erosion or ulcer border.

29. Method of palpation in indurative edema

Indurative edema is one of atypical signs of primary syphilis. It occurs in the places richly supplied with deposition of fat, more often on the labia majora, the scrotum, and the foreskin. Palpation of damaged parts is of great importance for diagnosis. After pressing on it with a finger in glove, no dipping occurs in edema.

30. Yarish–Lukashevich–Herxheimer reaction

Yarish–Lukashevich–Herxheimer reaction or "exacerbation" reaction develops in the recent secondary syphilis. Many patients have an increased body temperature after antibiotic therapy of syphilis (more often after the 2-nd–3-rd injection). Sometimes it may be up to 38–39 °C. Roseolas become brighter, elevated. New spotty rash occurs. This reaction has a diagnostic value in cases of doubt (for diagnosis making of new or recurrent syphilis). A reaction occurs due to death of a great number of treponemas, their endotoxins in the blood that causes specific immunological cellular reaction accompanied by general signs. Leukocytosis and increased ESR is observed in the patient's blood taken at this period. In case of this reaction development the doctor's strategy is expectant as a rule. In some hours the above symptoms regress spontaneously.

31. Method of material taking for Treponema pallidum analysis and examination procedure

Tissue liquid (serum) from syphilitic elements or secretion from lymphatic gland is an examination material for Treponema pallidum detection. There are several methods for serum getting among which the most effective ones are:

a. Irritation method.

An element for examination (hard chancre, wet papula, large condyloma and others) is cleansed carefully with cotton wool moistened with sterile saline

solution and then dried with gauze or swab. Careful (in order not to cause bleeding) stroking movements along the erosion surface (papule, ulcer) are done with platinum ansa (if there is a lack of platinum wire it can be easily changed on tungsten one). Erosion surface becomes bright due to the tissue liquid dripping in some seconds, in a minute. Rarely it takes more time. Tissue liquid is transparent or slightly opalescent, colorless or slightly yellowish. Sometimes it is necessary to wait a little after irritation, then serum secretion from erosion surface becomes more profuse. In case of bleeding development, it should be arrested (compressed with swab) and then the procedure should be continued. Small blood admixture to the serum is permissible.

b. Compression method

Erosion, ulcer or papule is squeezed from each side with the fingers or pincette and serum appears on its surface. This method is more frequently combined with irritation method. Sometimes examination has no results if the element had been treated with some local therapy before or there is a secondary infection. Local compresses with saline solution are recommended in this case and examination should be repeated in 1–2 days.

31. **Puncture of regional node** is used in case when the mentioned above methods give no results, in doubtful clinical picture, when chancre is hidden or when it has been completely epithelialized. Regional node (the nearest one to the initial sclerosis) is usually punctured. It is as a rule hard, movable, without any signs of acute inflammation. Two-five gram syringe with good piston and sharp short needle is chosen for puncture procedure. Prick part is rubbed with iodine. A node to be analysed is fixed with the two fingers of the left hand and right one makes a puncture. Prick is done at one of the node poles and then the needle is pushed toward the lymphatic node axis through its length up to the opposite pole. Then the needle is slowly taken out the node pulling the piston off the syringe. It helps to get substance for analysis from all layers of the node and even from the cortical one. A puncture can be done with enrichment. For this purpose the syringe is filled with 0.1–0.2 ml of sterile saline solution before hand. After a prick, solution is injected into the node and after a slight massage, is taken back into the syringe again. Needle with syringe is moved off the node after 3–4 injections. Lymphocytes presence in the material for examination proves the puncture has been done correctly.

32. **Treponema pallidum in the dark field examination**

T. pallidum is difficult to culture. The easiest means of diagnosing syphilis is through direct microscopic detection of the organism. However, *T. pallidum* presents some challenges to microscopic detection. When unstained, *T. pallidum* cannot be seen with standard bright-field microscopy due to its small cell diameter. The spirochete is best seen with dark-field microscopy. Dark-field microscopy allows a lower limit of resolution than bright-field microscopy (0.1 μm versus 0.2 μm) allowing spirochetes to be visualized. Like the terms suggest, objects are observed against a bright background in bright-field microscopy as light is

focused directed on the specimen, and against a dark background in dark-field microscopy where directly transmitted light is excluded by a dark-field condenser allowing only scattered light to be focused on the specimen. With dark-field microscopy bacteria appear luminous against a dark background. Preparation for the dark visual field is done in the following way—a drop of saline solution (hemp grain size) is put on the subject glass. The same amount of serum received from the examination element is put near. Then two drops are mixed and covered with the micro glass (it is necessary not to have airy space under the microglass). Lymphatic node secretion isn't diluted with saline solution. A drop of simple water or cedar oil is put on the upper lens of condenser. The preparation is put on the microscope table. So there is homogeneous medium (water, oil) between the substance and condenser and it prevents the light rays deviation. Spirochete pallidum looks like very soft moving spiral with nearly silver glance or like dotted lines due to the brighter shining of the convex part of the curling lines. Neutrophils are like round brightly fluorescent granulated formations. Lymphocytes are grayish dark round dimly fluorescent cells. Epithelial cells are significantly bigger than leucocytes. They have round and irregular outlines and shine brightly. Erythrocytes look like dark rounded elements with a line of fluorescent border. Despite mentioned above large cells, the whole field of vision is covered with a great number of the smallest fluorescent units with continuous random movement. This is Brownian motion of solid particles and it proves that the test is done correctly.

33. Method of Thomson's two glass test

Two-glass test makes it possible to determine anterior urethritis from a posterior one. After 6–8 hours of urine retention, a patient urinates approximately in equal portions into two glasses (without stream interruption). Urine received is examined under microscope. Turbidity, filaments and flakes of pus in the first glass proves the damage of anterior part of urethra (anterior urethritis). All mentioned above signs in the second glass testify damage of posterior section of urethra (posterior urethritis). When the urine is turbid in both glasses it indicates on the total urethra damage.

34. Method of three-glass test

Three-glass test is done in case of latent inflammatory process in urethra, symptoms typical for posterior urethritis, and two-glass test is negative. A patient is asked to retain urine for about 3–4 hours. The bladder is emptied by passing urine into a series of 3 test tubes, and the contents of the first and the last are examined. The first tube contains the washings from the anterior urethra, the second, material from the bladder, and the last, material from the posterior urethra, prostate, and seminal vesicles. If there are such changes as turbidity, flakes of pus, swimming filaments in the 1-st portion, it indicates on the damage of the anterior part of urethra. If there are such changes in the 2-nd portion, it indicates on the damage of the posterior part of urethra. If these changes are present in the 3-rd glass, it indicates on the damage of the whole urinary bladder.

35. Smear taking procedure

External reproductive organs are wiped with the swab moistened with the sterile isotonic solution of sodium chloride (in males it is the glans penis; in females it is the labia genitalia, the genital atrium and vagina, the clitoris and the external opening of the urethra). It is easy to get a drop of pus in case of its free discharge. If there is no pus discharge, then, in male, a drop of it is extruded with the help of a finger pressing on the posterior surface of urethra and a slight movement towards the external opening. Then it is spread along the surface of subject glass. If visible portion of secreted substance is absent ansa or special spoonis put 1.5–3 cm into the female's urethra or 3–4 cm in the male's one. Then it is carefully turned inside it for 5–10 seconds.

Cervical smear is a very safe test. The speculum is inserted into the vagina to allow visualization of cervix which is located deep inside the vagina. A small piece of wooden spatula or plastic brush is inserted through the speculum to obtain some cells sample from the surface of the cervix. After wards, the cells sample is smeared onto a glass slide or transferred to a bottle of liquid for preservation. The speculum is removed and the test is finished. Smears received are dried in the air and sent to the laboratory together with the indication of the patient's first name, patronymic, surname and the organ from which this element for analysis has been taken.

Tools of the Trade

Spatula. Tongue blade: Used to remove crusts and scales, test for dermatographism, and examine mouth.

Glass spatula: Used for diascopy. By pressing on the skin hard enough to exclude blood flow, one can eliminate purely vascular lesions and better appreciate dermal changes, such as the “apple jelly” color of many granulomatous infiltrates (tuberculosis, sarcoidosis).

Wood's Light Examiaton. Definition: UV radiation from a mercury-vapor source is passed through a nickel oxide filter, producing light at a wave length of about 365 nm. Uses: *Dermatophyte infection:* *Microsporum* species that infect hairs impart a green fluorescence. Wood's light can be used for screening or for control of therapy. Both sebum and salicylic acid preparations may have blue-green fluorescence; also the scales do not fluoresce, just infected hairs. In addition,

Trichophyton infections do not fluoresce. *Favus:* *Trichophyton schoenleinii* imparts a green fluorescence. *Erythrasma:* Coral red fluorescence. *Trichomycosis axillaris:* Orange fluorescence. *Tinea versicolor:* Orange fluorescence. *Pseudomonas:* Green fluorescence. *Porphyrin:* Red fluorescence of skin and teeth in some porphyrias; fluorescence of urine in others. *Pigment abnormalities:* Hypopigmentation can be distinguished from depigmentation, vitiligo more readily seen, ash leaf macules in tuberous sclerosis and cafe-lait macules in neurofibromatosis more easily found.

Patch Testing and Photopatch Testing. Principle: In order to prove type IV contact sensitization, the potential allergen is applied to the skin under occlusion in a nontoxic concentration for 24–48 hours. In sensitized individuals, a localized dermatitic reaction occurs. In photopatch testing, the allergens are applied in parallel, and one set is irradiated.

Potassium hydroxide (KOH) examination is used for suspected fungal infections of skin, hair and nails. Scrape a burrow or unexcoriated papule, and apply KOH or mineral oil to the slide before microscopic for scabies diagnosis. Fungal cultures (Sabouraud’s agar) confirm a diagnosis of tinea capitis, tinea corporis or onychomycosis. Tzanck smear is used for diagnosis of herpes simplex or varicella-zoster virus. Bacterial cultures – purulent material from representative lesions are swabbed with a soft sterile swab, inserted into the appropriate tube and sent to the laboratory. Viral culture requires a special transport medium, which is available at most large hospitals. Blister fluid and the base of the lesion should be swabbed or aspirated and then inoculated into the appropriate media. Skin biopsy is carried out for routine histopathologic or immunofluorescence examination.

Medical History

Principles. The history is not as crucial to dermatologic diagnosis as it is in most other specialties, but it often provides valuable clues and should be taken carefully when the physical examination has not provided a diagnosis. When allergic reactions, infections, exogenous damage, drug reactions, or cutaneous manifestations of systemic diseases are being considered, the history often is the only way to obtain the diagnosis. In addition, it is often essential in planning therapy. *Procedure.* The most useful approach is to concentrate on a few key questions, which can be expanded upon depending on the clinical situation. The patient’s answers also provide the framework for additional questions. Questioning should be direct, but not aggressive; preserving the doctor–patient relationship is more important than any single question.

When exactly did the skin changes start? Patients often gives misleading answers as they either have not noticed the early stages of their diseases or have ignored them. The first changes may have developed at a site where the patient could not easily observe them. *Are the lesions symptomatic?* (Do they burn, itch, feel tight, warm, cold?) Symptoms such as itching or pain may turn out to be misleading. Do not ignore the possibility of scabies just because the patient says the lesions do not itch. *How did the lesions spread? How did the individual lesions first look and how have they changed?* Patients often have a different understanding of morphologic terms than do physicians. Be sure to ask what is really meant by terms such as “pimple,” “boil,” “eczema,” or “sore”. *What do you think started the problem? What makes it worse?* Ask what the patient was doing when the problem started. Some diseases are typically made worse by cold, exercise, or the like. Often the patient may provide valuable clues, but just

as often their assessment of etiology or causality is very misleading – remain skeptical, without showing it. *How have you treated it so far?* Frequent washing or the use of a tincture may explain why an exanthema is very dry; use of an ointment in the groin may clarify the development of macerated lesions. If the answer is still unclear, then take a complete medical, social and family history, as well as a detailed medication history. Additional helpful questions include: *Have you ever had anything similar to this before? What was the diagnosis then? Do you have any skin problems elsewhere* (mouth, feet, nails, scalp, genital region, perianal region, groin, axillae, ears)? *What has been the influence of external factors* (sun, work, eating, drinking, cosmetics, stress, medications) or internal factors (menses, pregnancy, nursing, illnesses)? *What are the associated signs and symptoms? How do you feel otherwise* (malaise, fever, weight loss, night sweats)? *What medications are you taking?* Be sure to ask about tranquilizers, sleeping pills, vitamins, headache preparations, laxatives, appetite control pills and natural products. Patients often do not consider one or more of these categories as medications, and fail to report them. Lifestyle – drugs, alcohol, smoking, stress. Sexual practices, last time you had sex (when relevant). *Any systemic signs or symptoms before skin disease started* (prodrome)? *Any other illnesses?* Be sure to ask about cardiovascular, renal, hepatic, thyroid, rheumatologic diseases, HIV, diabetes mellitus. *Personal or family history of atopic dermatitis, hay fever or asthma?* Other allergies? Ethnic background. Foreign travel, especially to tropical regions. *How much does the skin disease influence daily function* (quality of life assessment)? Psychosocial situation – job, family, relationships, handicaps.

Principles of medical deontology in the practice of dermatologist and venerologist.

Besides prescribing general and topical treatment, the attendant physician should therefore find out first of all with great tact and care the causes which could have led to a “break” in the nervous activity in the given patient. Only a physician who gains full confidence of the patient by his behavior, inner culture, sincere manner, by his appearance and the manner of his speech and dress can count on the patient’s frankness in questions that on first glance seem to be private and intimate.

Medical deontology is based on the humanness, honesty, kindness, sympathy, and unselfishness of the medical personnel. To fulfill one’s duty, the medical personnel must be polite, reserved and patient; each member of the medical staff should constantly develop these characteristics himself.

Psychotherapy of dermatological patients begins as soon as they are admitted to the clinic or when they visit the out-patient clinic. The psychotherapeutic effect depends on the skill of the medical personnel in speaking with the patient, comforting him, and filling him with the belief that he will recover, that he is given proper and effective treatment.

There is hardly any difference in the problems of medical deontology in the practice of dermatologist, internists, and other specialist, but in the practice of venereologist they have specific moments knowledge of which is necessary for a physician working in the field. In order to detect, examine, and treat a patient who is a source of infection, and to find out all persons with whom he had every-day or sexual contact, the venereologist must study the conditions of the patient's intimate life. It is advisable to create an atmosphere of confidence for the interview that is why the presence of other medical personnel or medical students is not conducive to a favorable atmosphere and a frank conversation of the physician with patient. The "sex" history should be taken after diagnosis and stage of the disease have been established exactly. In patients with an active form of syphilis, for instance, the physician must have information on sexual contacts not in general, but on those which took place in a definite period of time.

The venereologist's approach to keeping the physician's secret is an important part of his work. In such case the interests of the sick person and the society are closely interwoven and are often opposed. The venereologist, like all specialists in other fields of medicine, is bound to keep the physicians secret in all cases when this does not clash with the interests of the society and is made answerable before the law for divulging.

Venereal diseases are among the morbid conditions which the sick person often conceals from his relatives and close friends. The patient becomes reserved, "buttoned up his disease", and phobic experience may occur. That is why the task of not only the physician, but the entire staff consists in creating in the department, dispensary, or out-patient clinic the appropriate atmosphere which would have a favorable and soothing effect on the patient. To achieve this, the patient personality and intellect, and knowledge of the problems of venereal diseases should be taken into account.

Keeping to the laws of medical deontology helps to avoid iatrogenic diseases and phobic reaction. Syphilophobia, as well as gonophobia, may be of great harm to the patients' health, therefore the venereologist, and other specialists, should observe strictly "psychic aseptic", i.e. all that is said above.

Main principles in the treatment of dermatological patients.

In some dermatoses the aetiological (microbial) agent is known (various clinical forms of pyoderma, dermatomycoses, tuberculosis, cutaneous leishmaniasis, virus dermatosis, leprosy, scabies, etc.). Isolation and study of causative agent in the laboratory, and the inoculation of the experimental animals with it made it possible in most cases to develop and introduce into practice therapeutic agents, which cause a specific effect on the microbe and in this way make easier the task of liquidating the infectious or parasitic dermatosis. This is known as *aetiotropic (aetiological)* therapy of a dermatosis.

Some dermatoses very difficult for management are often encountered in practice of various specialists (dermatologist, specialist in occupational diseases and infectious diseases, pediatricians, allergologists, and others). These diseases arise because of the organism's altered reactivity, the skin in particular, to exogenous and endogenous stimuli (food, drugs, chemicals, household and occupational factors, etc.). A large group of dermatoses (eczema, neurodermatitis, urticaria, etc) is in fact caused by hypersensitization, i.e. increased sensitivity of the organism. If the physician has identified the dermatosis-causing factor (e.g. a chemical allergen in occupational dermatosis), which has as yet not produced polysensitization (hypersensitivity to more than one substance), its removal results in recovery within a relatively short time. In practice, however, cases are most frequently encountered, in which the physician cannot determine the character of the allergen that caused the dermatosis or the patient produces an abnormally strong reaction to many stimuli because of genetically determined or acquired polyvalent sensitization. In such cases the main importance is attached to general treatment, hyposensitizing and symptomatic therapy, and the treatment of foci of chronic infection and diagnosed diseases of the viscera, nervous system or endocrine glands sustaining the dermatoses. Pathogenetic therapy (taking into account the form, stage and spread of the dermatosis) is, therefore, in essence the only type of treatment for the most common skin diseases.

Purely symptomatic treatment is now less prescribes in dermatology than aetiologic and pathogenetic therapy to which symptomatic measures are added.

The therapeutic options in dermatology are drugs (topical and systemic), physical (surgical excision, curettage, electrodesiccation, cryotherapy, radiotherapy, phototherapy, laser therapy) and physiotherapeutic (electrical therapy, ultrasound therapy etc.).

General therapy

For didactic purposes, the methods of general treatment are separated into possesses a diverse effect. This applies to hormones, vitamins, and other drugs.

Exerting an effect on the nervous system. Sedative therapy.

In view of the fact that functional disorders of the nervous system play a very important part in the development of various dermatoses (in the first place those which are attended with itching), various sedative agents causing an effect on the nervous system are used extensively in dermatology. There are preparations of bromide (sodium bromide, potassium bromide, camphor bromide), valerian, procaine hydrochloride, calcium salts (glycerophosphate, gluconate, lactate, pantothenate, chlorade), tranquillizers (chlordiazepoxide, meprobamate), etc. Besides antihistaminic and sedatives, dermatologists use analeptics, neuroleptics and antidepressants widely.

Hyposensitization therapy.

Specific sensitization is used widely in chronic and recurrent pyoderma, for which purpose staphylococcus toxoid, staphylococcal antiphagin, filtrate or bacteriophage, and streptococcal and staphylococcal vaccines are administered.

Non-specific hyposensitization is already begun when the allergen that caused the dermatosis is still being identified, or when polysensitization has developed, or, more frequently, when the allergen cannot be found. There are very many agents and methods that can be used for non-specific hyposensitization. There are corticosteroids, vitamin C and P, calcium chloride, sodium thiosulfate, calcium gluconate, antihistamines, and non-specific immune hyposensitization therapy (injection of analogous blood or milk, transfusion of banked blood or plasma, treatment with pyrogens, gamma globulin, histaglobin, etc.).

Antihistamines are widely used in dermatology because histamines and substances possessing a histamine-like effect contribute greatly to the pathogenesis of allergic skin diseases (acetylcholine, serotonin, bradykinin, etc.). Antihistamines alleviate erythema, swelling, and itching which are manifestations of the histamine reaction.

Autohaemotherapy is used extensively in dermatology because it has a market hyposensitizing effect and promotes the organism's immunological reactivity. Intravenous infusion of native plasma causes desensitizing and detoxifying effects, improves the immunological resistance, reduces dysproteinaemia, and replenishes the patient's body with proteins, hormones, enzymes, salts, vitamins, and immune bodies. Autohaemotherapy is also included in the group of stimulating methods of fever in which fever (pyrexial) therapy carried out with bacterial pyrogens (Pyrogenal, Prodigiosan, Acetoxan) also belongs. Since bacterial pyrogens are microbic lipopolysaccharides, they cause a hyposensitizing effect and stimulate the mechanism of immunological defense. Injection of aloe extract and placental extract should also be included among the methods of non-specific stimulation.

Gamma globulin, histaglobulin, pentoxyl, methyluracil, and irradiation of skin with ultraviolet rays are used widely in dermatology, because in one hand, they are measures of non-specific hyposensitization and, on the other, they improve the organism's immunobiological resistance.

Vitamin therapy in skin diseases. The development of some dermatoses is caused by hypo- or avitaminosis (scurvy, pellagra, phrynoderma). In such cases vitamin therapy has a specific effect on the disease itself and on the skin manifestation developing in it.

Hormonal therapy. A group of skin diseases (pemphigus vulgaris, acute lupus erythematosus, dermatomyositis, periarteritis nodosa, severe erythroderma, psoriatic erythroderma, psoriasis arthropatica etc.) deserves to be distinguished, in which the prescription of corticosteroid hormones is a vital necessity. Hormones of the pituitary (ACTH) and adrenals (glucocorticoid steroid hormones) possess marked anti-inflammatory and antiallergic (hyposensitizing) effects due to which they were used widely not only when vitally indicated, but in other skin diseases (eczema, neurodermatoses etc.) when their prescription was a method of choice.

Anabolic hormones have a beneficial effect on nitrogen metabolism, retain in the body potassium, sulfur, and phosphorus which are necessary for protein synthesis, and contribute to the fixation of calcium in bones. With the prescription of anabolic hormones, the patient's appetite and general condition improve and deposit of calcium in the bones is accelerated, that is why they are indicated in long-term treatment with steroid hormones.

Antibiotic therapy. A very great number of antibiotics are available today, because they are principle drugs used in the treatment of patients suffering from infectious dermatosis (mostly pyoderma, also tuberculosis of skin, erysipeloid, anthrax, venereal diseases, some skin diseases unknown etiology such as scleroderma, lichen planus, and oth.).

Chemotherapy. Sulphonamides, antimalarial agents (derivatives of the quinolone series), and preparations of isonicotinic acid hydrazide and of the sulphone series are chemotherapeutic agents used in dermatology. Synthetic

Antimalarial drugs (Resoquine, chloroquine, Delagil, Plaquenil, and oth.) are mainly used in dermatology in the management of chronic lupus erythematosus. Preparations of isonicotinic acid hydrazide (phthivazid) are used as a therapeutic measure in the rarely encountered tuberculous skin diseases. Sulphones (diaminodiphenylsulphone or DDS, Avlosulfon, Dapsone, sulphtrone, sulphatin, etc.) are the main and most effective measures in the treatment of patients suffering from leprosy, Duhring's disease.

Topical treatment.

External pharmacological agents also cause a general effect of some degree on the patient's organism because of the presence of a neuro-receptive apparatus in the skin. To success of topical therapy is determined by the physician's proper consideration for many factors: the character of the dermatosis (acute, subacute, chronic), the stage of the process (progressive, stationary, regressive), depth and localization of the disease, the pharmacological properties of the drug prescribed, the indications and contraindications for its application, the concentration of drug, the set of measures applied, the drug form of the topical agent, and other factors.

The common rule is that more acute inflammatory process, the more superficial is the effect caused by the chosen drug form and the anti-inflammatory substances composing it. Lotions, powders and suspensions have a more superficial effect than pastes, while the effect of pastes is more superficial than that of ointments or compresses. In the depth of their action, topical agents may be arranged in the following order (beginning with those causing the most superficial effect): powders, lotions, shake lotions (suspensions), pastes, ointments, compresses, glue, plasters, varnish. Before any topical medicament is applied, the focus of affection should be cleansed of pus, crust, scales, and the remnants of the tops of vesicles and bullae. No force should be applied in removing scales, crusts and the residues of ointments. Such areas are richly soaked with sunflower-seed, linseed or some other oil and 15–20 minutes after

the focus is again cleansed or the oil bandage is left in place for a longer period of time. Contaminated erosion and ulcers are cleansed with a 3 per cent hydrogen peroxide solution. In pyoderma and other infectious dermatoses, the skin around the lesions is wiped with camphor or 2 per cent salicylic or boracic acid.

Powders are applied to the affected area in a thin, even layer. They dry and degrease the skin, cool it, and facilitate constriction of superficial skin vessels. Powders are prescribed in acute inflammation to reduce hyperemia and swelling and relieve the sensation of fever and the itching and are never applied to weeping surface. Mineral and plant substances are used as powders. Magnesium silicate (talc) and zinc oxide are most common mineral components; wheat starch (*Amylum tritici*) – the plant component. Sulphanilamide powder, xeroform (bismuth tribromophenate) and dermatol (bismuth subgallate) are used as components of powders applied in the treatment of erosions and ulcers.

Lotions in the form of aqueous and alcohol solutions are often used in dermatology to produce an anti-inflammatory, astringent, and disinfectant effect.

Application method: four or six layers of gauze or a soft cloth are soaked in the cooled solution, wrung out, and applied to the affected weeping area. The dressing is changed every 5 to 15 minutes (as soon as it dries and gets warm) for one to one and a half hours; the procedure is repeated several times a day. The most commonly used lotions are 1 or 2 per cent tannin solution, 0,25–0,5 per cent silver nitrate solution, 2–3 per cent boric acid solution, 0,25–0,3 per cent amidopyrine solution, lead water (Aq. Plumbi 2 %).

When puriform infection is present in the foci of an acute inflammatory lesion, disinfectant lotions are applied: 0,1 per cent ethoxydiaminoacridine lactate solution (rivanol), 0,05 per cent potassium permanganate solution, 1–2 % resorcin solution.

Wet dressing. This dressing is prepared by the same method as a dressing with lotion, but more layers of gauze are used (8–12) and the dressing is changed much less frequently (in 30 to 60 minutes and more) as it dries. A wet dressing is covered with a thin layer of hygroscopic cotton and bandaged. These dressing help in abating the symptoms of acute inflammation because the slowly evaporating solution cools the skin (though less actively than lotion cools it).

Paints for affected areas are aqueous or alcohol solutions of aniline dyes (e.g. brilliant green), aqueous- alcohol solutions of menthol (1–2 %), carbolic acid (1,0–1,5 %), aqueous solutions of blue vitriol (2–10 %) or silver nitrate (2–10 %).

Shake lotions are aqueous and oil solutions. They are the same powders but suspended in water and glycerin so that they remain on the skin for a long time without falling off. After the water evaporates, the powders (they account for 30 to 45 % of the lotion mass) are deposited on the skin in a thin even layer and stay on it for a long time because of glycerin. Thus, shake lotions, like lotions, cause an anti-inflammatory and drying effect. Zinc oxide, talc, kaolin, and starch are used most commonly as the powdered substances. Aqueous shake

lotions have the same effect as powders: anti-inflammatory, antipruritic and relieve the sensation of burning. Aqueous-alcohol shake lotions contain 96 % ethyl alcohol. Oil shake lotions are composed of powdered substances and a liquid oil base (such as sunflower-seed, peach-kernel or vaseline (petroleum) oil). "Zinc oil" is a very favoured shake lotion; it contains 30 % of zinc oxide and 70 % of a vegetable oil. Oil shake lotions soften the skin, reduce the sensation of straining and tightening and help in the removal of scales and crusts. Preparation of sulphur, ichthammol, tar, menthol, etc. may be added to the shake lotions. Shake suspensions are not applied to a weeping surface or to the scalp.

Pastes are a mixture of equal parts (in weight) of different powders (zinc oxide, talc, starch, etc.) and a base of greasy substance or oil (lanolin, Vaseline, etc.). Pastes penetrate deeper than do shake lotions but are less active than ointments; they have an anti-inflammatory and drying effect. Because their dough-like consistency they may be used without a bandage. They are not applied to the scalp if there is weeping surface. A paste is applied to the skin once or twice a day and once in three days it is removed with a tampon moistened in vegetable oil. Soft pastes are prepared with lesser amounts of the powdered substances. Whenever indicated, naphthalan, ichthammol, preparations of sulfur and tar are added.

An *ointment* contains one or more medicaments mixed evenly with a greasy base (Vaseline, lanolin, lard, naphthalan, etc.) which must be neutral chemically (so as not to cause irritation of the skin) and be of a soft, elastic consistency which does not change under the effect of body temperature. Synthetic substances are now used more and more widely as the bases of ointments: ethylene oxide polymers, cellulose derivatives, esters of sorbitol and higher fatty acids, etc. Ointments with such a base penetrate the skin better and are freed more easily of the medicaments included in them; they do not undergo oxidation or disintegration, and are tolerated well by the skin. Ointments cause a deep effect and are therefore prescribed in chronic and subacute diseases, in inflammatory infiltration in the skin. Naphthalan, tars and ichtammol are keratoplastics. Substances which cause separation of the horny layer (keratolytics) are salicylic (3 %), benzoic and lactic acids. Very popular are ointments containing corticosteroids, antibiotics, and interferon etc. The ointment is applied to the focus of affection and fixed with bandage. An ointment is applied once or twice a day. In pityriasis versicolor and scabies the ointment is rubbed vigorously into the skin.

A *cream* is used for dry skin which has lost its elasticity and which is mildly inflamed. Lanolin (animal fat) makes the skin soft and elastic. The water contained in the cream cools the skin and in this manner causes an anti-inflammatory effect. The skin tolerates creams well, but in those for children vaselin (petroleum jelly), which irritates the skin, is replaced by castor oil or sunflower-seed oil. Unna's or lanolin cream (lanolini, vaselini, aq. Calcis āa) as well as other creams produced by perfume industry are used widely.

Plaster (emплаstrum). Wax or rosin, sometimes resins, caoutchouc, and other substances form the base of a plaster in addition to fat. Therapeutic plasters contain medicaments (e.g. plaster is used urea, salicylic acid, phenol, etc.). A plaster is thicker and more sticky than an ointment and penetrates deeper. Before use it is heated and sticks to the skin and is held on it tightly.

A *varnish* is a solution which dries rapidly on the skin and leaves a fine film. A varnish usually consists of collodion to which various medicaments are added (salicylic acid, resorcinol, griseofulvin, etc.). Varnish is usually used when it is desirable to exert a deep effect on the tissue (e.g. the nail plate) and on a limited area.

According to the *character o action*, all topical agents are divided into several groups. Medicaments used for lotions, powders, shake lotions. Pastes as well as corticosteroid ointments and creams are all *anti-inflammatory agents*. *Keratoplastic, or reducing, agents* in small concentrations have also anti-inflammatory effect. Among such agents are ichthammol, preparations of sulfur, tar, mercury, naphthalan oil, naphthalan. The group of *keratolytic agents* mainly includes various acids (salicylic, lactic, benzoic acids) and alkali in a 3–10–15 % used for scaling of the superficial parts of the corneal layer. The *antipruritic agents* may be divided into two groups. The first is composed of agents which (in a solution, ointment and cream) cause only an antipruritic effect; these are menthol, anaesthesin (benzocain), chloreton (chlorbutamol), vinegar solutions, thymol, antihistaminic, chloral hydrate, etc. The second group includes agents which cause an anti-inflammatory or keratoplastic effect and at the same time relieve itching; these are tar and sulfur preparations, salicylic acid, corticosteroids in ointments and creams. *Disinfectants (antiseptics)* and *antiparasitic drugs* are components of a large group of agents which produce only a disinfectant or also an antiparasitic effect or only an antiparasitic effect. Such agents are iodine, alcohol, boric acid, ethoxydiaminoacridine lactate, aniline dyes, hydrogen peroxide, salicylic acid, resorcinol, thymol, benzoic acid, sulphur and tar preparations, antibiotics, sulphonamides, dermatol (bismuth subgallate), xeroform, benzyl benzoate (benzoic acid benzyl ether), etc. the group of astringents and caustics includes salicylic acid and resorcinol (in high concentrations), silver nitrate, lactic acid, podophyllin solution, arsenic, pyrogallol, acetic and trichloro-acetic acids, caustic alkali etc. Effect of a substances may differ depending on the form in which it is used and its concentration. Resorcinol is most illustrative in this respect: it has a keratoplastic (in small concentrations), keratolytic (in mildly higher concentrations), and an astringent (in still higher concentrations) effects. Tar, a typical keratoplastic agent, is also used to produce an antiparasitic and antipruritic effect. A 3 % salicylic acid acts as a mild keratoplastic agent, while a higher concentration of the acid exerts a keratolytic effect.

Навчальне видання

Дерматологія. Венерологія

Частина 1

*Учбовий посібник для студентів IV курсу
стоматологічного факультету*

Упорядники Біловол Алла Миколаївна
 Ткаченко Світлана Геннадіївна
 Берегова Алла Анатоліївна

Відповідальний за випуск А. А. Біловол



Комп'ютерна верстка О. Ю. Лавриненко

Формат А5. Ум. друк. арк. 2,3. Зам. № 18-33569.

Редакційно-видавничий відділ
ХНМУ, пр. Науки, 4, м. Харків, 61022
izdatknmurio@gmail.com

Свідоцтво про внесення суб'єкта видавничої справи до Державного реєстру видавництв, виготівників і розповсюджувачів видавничої продукції серії ДК № 3242 від 18.07.2008 р.

Dermatology. Venereology

Part 1

*Textbook for 4-year stomatological faculty
students trained in English*