

Ministry of Health of Ukraine
Kharkiv National Medical University

**RESPIRATORY SYSTEM EXAMINATION. LUNGS
PERCUSSION. TECHNIQUE OF COMPARATIVE AND
TOPOGRAPHIC PERCUSSION.**

Methodical instructions for students

Рекомендовано
Ученым советом ХНМУ
Протокол №__от_____2017 г.

Kharkiv
KhNMU
2017

Respiratory system examination. Lungs percussion. Technique of comparative and topographic percussion.: Method. instr. for students /

Authors. T.V. Ashcheulova, O.M. Kovalyova, G.V. Demydenko. –
Kharkiv: KhNMU, 2017. – 16 p.

Authors: T.V. Ashcheulova
O. M. Kovalyova
G.V. Demydenko

PERCUSSION OF THE LUNGS

Two types of percussion of the lungs – comparative and topographic – are existed.

Comparative percussion of the lungs

The *task* of comparative percussion is to compare percussion sounds over the lungs on the opposite parts of the chest, and also on neighboring areas on the one side.

The technique of comparative percussion. The patient should be in a comfortable posture and relaxed. The best position is standing or sitting. Patients with grave diseases should be percussed in the lying posture. The room should be warm and protected from external noise.

Percussion consists of setting up vibrations in the chest wall by means of a sharp tap. The middle finger of the left hand (pleximeter finger) is placed in close contact with the chest wall in the intercostals space. A firm sharp tap is then made by the middle finger of the right hand (plexor finger) kept at right angles to the pleximeter finger. Loud percussion (with a normal force of tapping) is used (Fig. 1).

All areas of the chest are percussed, that is, the front, both axillary regions, and back.



In *anterior percussion*, place pleximeter finger parallel to the clavicle in the right, in the left suprascapular regions, and then along midclavicular line. On the left side percussion is carried out only to the 3rd interspace, because underlying heart below this level changes percussion sound (Fig. 2.).

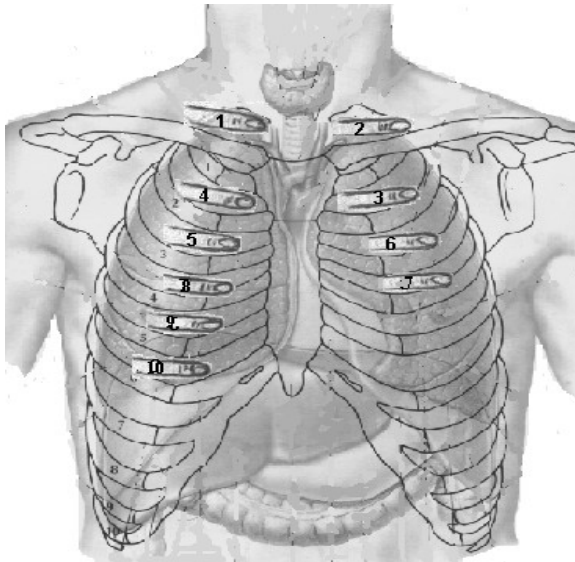


Fig. 2.. Comparative percussion of the lungs. Anterior view.

Axillary regions are percussed with the patient's arms folded at the back of the head. Percuss lateral chest along midaxillary line, starting from the right side (Fig. 3).

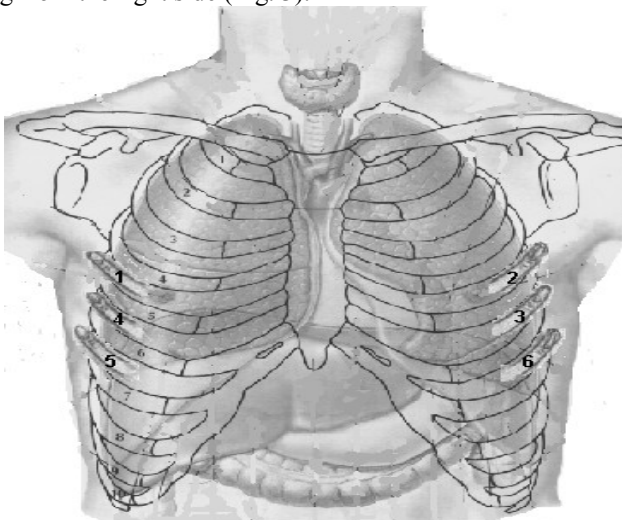


Fig 3. Comparative percussion of the lungs. Axillary regions.

When percussing *posteriorly* the patient keeps both arms crossed in front of the chest to move scapulae anteriorly. Place pleximeter finger

in the suprascapular regions horizontally, in the interscapular regions vertically, and in infrascapular again horizontally (Fig. 4).

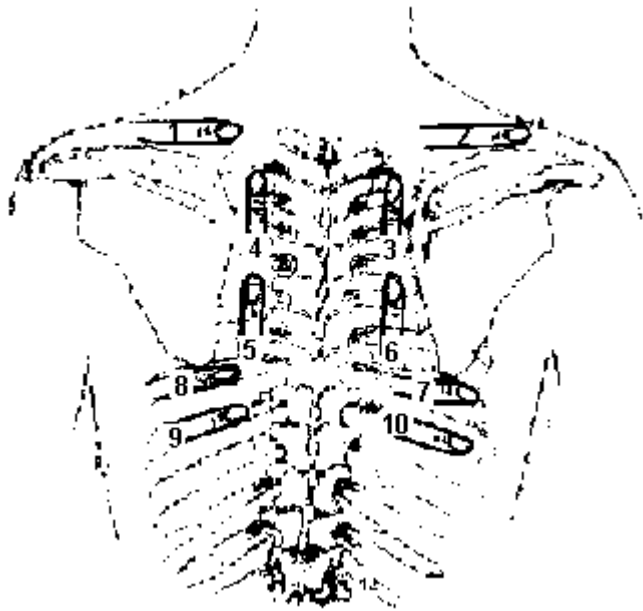


Fig. 4. Comparative percussion of the lungs. Anterior view.

Percussion notes can usually be distinguished in their basic qualities of sound: intensity, pitch, and duration.

It should be remembered that these qualities could be not equal in healthy person on symmetrical part of the chest (Tab. 1).

Tab. 1. Physiological changes of the percussion sounds over the lungs.

Location	Changes of qualities	Cause
Over the right upper lobe as compared with left one	Softer and shorter	Left upper lobe locates below the right due to the shorter right main bronchus
2nd and 3rd interspaces to the left of the sternum	Softer and shorter	Close location of the heart
Over the upper lobes of the lungs as compared with lower lobes	Softer and shorter	Smaller amount of pulmonary tissue
Right axillary region as compared with left one	Softer and shorter	Close location of the liver
Left axillary region	Louder and higher (with tympanic character)	Resonant effect of the stomach

The air-containing lung tissue will give a clear pulmonary sound (resonance) in percussion. Comparative percussion helps to determine whether the underlying tissues are air-filled, fluid-filled, or solid. The common cause of percussion changes include:

- decreased airiness of the pulmonary tissue or full absence of air in a part of the lung;
- increased airiness of the pulmonary tissue;
- pleural accumulation of fluid;
- pleural accumulation of air.

Tab. 2. Characteristics of the percussion sounds.

Sound	Relative intensity	Relative pitch	Relative duration	Example location	Pathological examples

			n		
Clear pulmonary (resonance)	Loud	Low	Long	Normal lungs	---
Intermediate	Softer	Higher	Shorter	Heart covered by the lungs	Decreased airiness of the pulmonary tissue
Bandbox (hyper-resonance)	Very loud	Lower	Longer	None normally	Increased airiness of the pulmonary tissue
Dullness	Soft (Medium)	High (Medium)	Short	Liver (airless organs)	Consolidation of the pulmonary tissue, fluid
Tympany	Loud	High (with music tembre)	Long	Airiness organs	Large pneumothorax, cavity filled with air
Metallic	Soft			None normally	Large cavity
Cracked-pot				None normally	Superficial cavity

In decreased amount of air in the lungs clear pulmonary sound becomes duller, that is **intermediate**. Causes include:

1. lobar pneumonia initial stage, when alveoli in addition to air contain also a small amount of fluid, or when air-containing tissue alternates with consolidations;
2. pneumosclerosis, fibrous-focal tuberculosis;
3. pulmonary edema due to the left ventricular failure;
4. compressive atelectasis (above fluid level);

5. pleural adhesion or obliteration, which interferes with normal distension of the lungs during inspiration;
6. obstructive atelectasis due to gradual resorption of air from the lungs below obstruction.

Dullness replaces resonance when solid tissue replaces air-containing lungs in such conditions as:

1. acute lobar pneumonia (consolidation stage), when the alveoli are filled with the exudates;
2. formation in the lung of a large cavity, which is filled with inflammatory fluid (sputum, pus, etc);
3. pulmonary tumor (airless tissue);
4. dullness also heard when fluid occupies the pleural space (over fluid): pleural accumulation of serous fluid (pleural effusion), blood (hemothorax), or pus (empyema).

Generalized hyperresonance (**bandbox sound**) may be heard over the hyper inflated lungs of emphysema.

Unilateral **tympany** suggests a large pneumothorax or possibly a large smooth-wall air-filled cavity (bullae) communicated with bronchus (pulmonary abscess, tubercular cavern). *Metallic percussion sound*: tympanic sound resembling a stroke on a metal may be heard over a large (6-8 cm in diameter) air-filled bulla in the lungs. *Cracked-pot percussion sound* (soft, resembles that of a cracked pot) may be heard over a large superficial cavity communicated with the bronchus through the narrow slit.

Topographic percussion of the lungs

Topographic percussion has following potential uses:

- determination of the upper borders (apices) of the lungs;
- determination of the lower borders of the lungs;
- determination of the excursion of the lower borders of the lungs.

Determine the **upper borders of the lungs** both anteriorly and posteriorly. To assess location of the lung apex *anteriorly*, place pleximeter finger parallel to the clavicle and move it gradually upwards and medially to dullness on the right side then on left one (Fig. 5). Normally the upper level of the lung apices is 3-4 cm above clavicle.

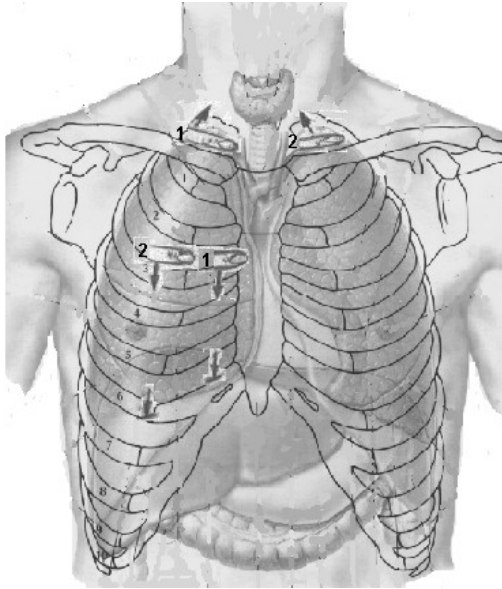


Fig. 5. Topographic percussion of the lungs. Anterior view.

In order to determine the upper borders of the lungs apices *posteriorly*, place pleximeter finger parallel to the scapular spine and move it gradually upwards to the point located 3-4 cm laterally to the spinous process of the 7th cervical vertebra (C7). Normally, the upper level of the lungs apices is about at the level of the C7.

The upper borders of the lungs can vary depending on the amount of air in the apices. In increased airiness of the pulmonary tissue (emphysema, attack of the bronchial asthma) the apices increased in size and move upwards. In decreased airiness of the pulmonary tissue (presence of connective tissue in the lungs as a result of inflammation in tuberculosis or pneumonia) the apices decreased in size and move downwards.

In order to determine the **lower lungs borders** percussion is carried out along topographic lines. First determine the lower border of the *right lung* anteriorly from second interspace along parasternal and midclavicular lines (Fig. 6). Lateral percussion starts from the axillary fossa along anterior axillary, midaxillary, and posterior axillary lines (Fig. 2.28). The patient should put his hands behind the back of the head.

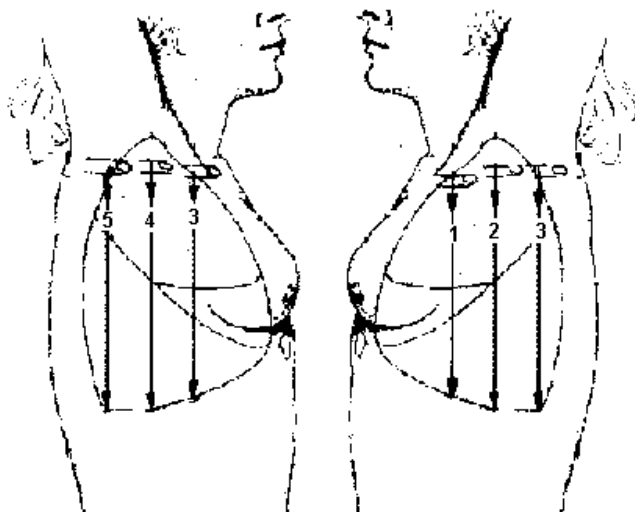


Fig. 2.28. Topographic percussion of the lungs. Lateral view.

To outline the lower border of the right lung posteriorly, percuss from the 7th interspace (below scapular angle, which ends at the level of the 7th rib) along scapular and parasternal lines (Fig. 2.29).

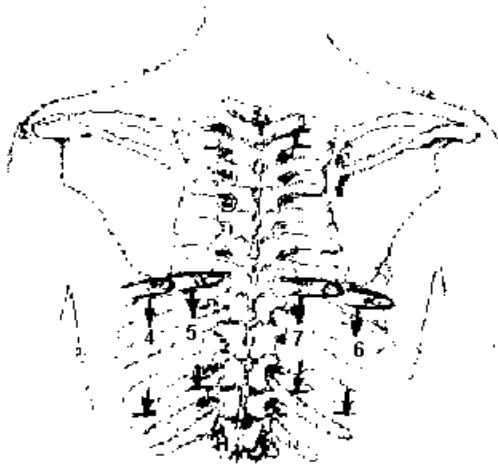
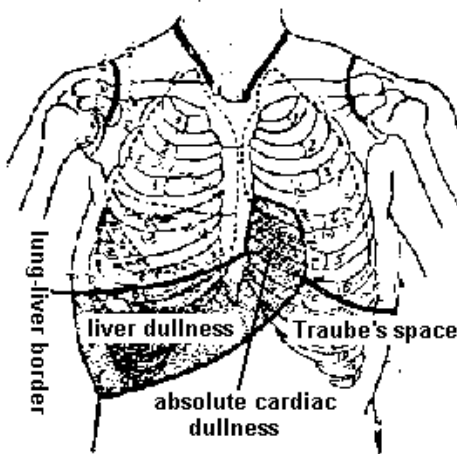


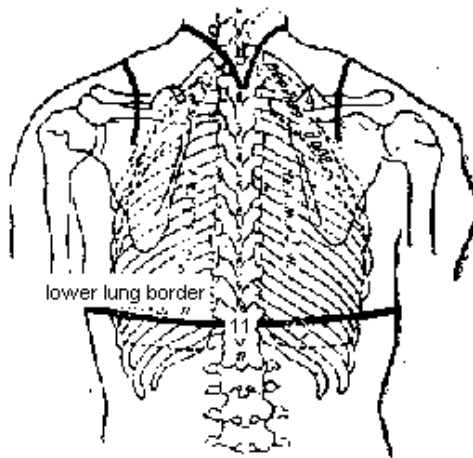
Fig. 2.29. Topographic percussion. Posterior view.

Right lung lower edge is at the point of transition of clear pulmonary sound to dullness – so-called lung-liver border (Fig.2.30; Fig.2.31).



The lower edge of the *left lung* is not determined anteriorly because of presence of the heart (Fig.2.30). Identify the lower border of the left lung only laterally along axillary lines (Fig. 2.28), and posteriorly, along scapular and paraspinal lines (Fig. 2.29). Along anterior and midaxillary lines the lower border of the left lung is at the site of transition of resonance to tympany (Traube's space) (Fig.2.30; Fig.2.31).

Anterior view



Posterior view

Fig.2.30. The normal lower borders of the lungs.

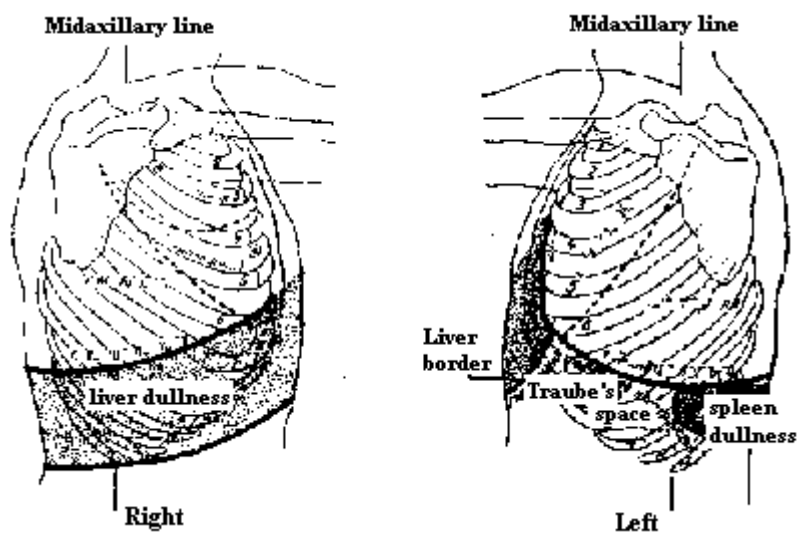


Fig.2.31. The normal lower borders of the lungs. Lateral view.

The normal lower borders of the lungs are represented in Tab. 2.4.

Tab. 2.4. Lower borders of the lungs in normosthenic persons.

Topographic lines	Right lung	Left lung
Parasternal	5 th interspace	---
Midclavicular	6 th interspace	---
Anterior axillary	7 th interspace	7 th interspace
Midaxillary	8 th interspace	8 th interspace
Posterior axillary	9 th interspace	9 th interspace
Scapular	10 th interspace	10 th interspace
Paraspinal	Spinous process of T11	Spinous process of T11

Displacement of the lower border of the lung can be bilateral or unilateral.

Bilateral lowering of the lower lungs edges is observed in:

- asthenic persons;
- in acute dilation of the lungs (attack of bronchial asthma);
- in chronic dilation of the lungs (emphysema).

Unilateral lowering of the lower lung edge is observed in:

- compensatory emphysema of one lung with inactivation of the other (pleural effusion, hydrothorax, pneumothorax, hemiparesis of the diaphragm).

Bilateral elevation of the lower lungs edges is observed in high diaphragm level:

- in hypersthenic persons;
- temporary in late pregnancy;
- ascitis;
- meteorism;

- presence of air in abdomen due to acute perforation of gastric or duodenal ulcer.

Unilateral elevation of the lower lung edge is observed in:

- pneumosclerosis;
- obstructive atelectasis;
- compressive atelectasis;
- marked enlargement of the liver or the spleen.

Respiratory excursion may be estimated by noting the distance between the levels of lower pulmonary borders on full expiration and full inspiration.

Identify respiratory mobility by right midclavicular, midaxillary, and scapular lines, and also by left midaxillary and scapular lines (Tab. 2.5).

Tab. 2.5. Respiratory excursion of the lower border of normal lungs in cm.

Topographic lines	Right lung			Left lung		
	Inspiration	Expiration	Total	Inspiration	Expiration	Total
Midclavicular	2-3	2-3	4-6	---	---	---
Midaxillary	3-4	3-4	6-8	3-4	3-4	6-8
Scapular	2-3	2-3	4-6	2-3	2-3	4-6

Respiratory mobility of the lower border of the lungs is decreased in inflammatory processes, decreased elasticity of the pulmonary tissue (emphysema), pleural effusion, adhesion or obstruction.

Tests.

1. How do the physical properties of the lung tissue at dull sound?
 - A. Increase of air content
 - B. Increase of density
 - C. Reduction of air content
 - D. Reduction of density
2. How do the physical properties of the lung tissue at tympanic sound?
 - A. Increase of air content
 - B. Reduction of air content
 - C. Increase of density
 - D. Reduction of density
3. There is dullness over the chest on the left along the scapular and posterior axillary lines from the 8th to the 10th interspace. What diagnosis can be supposed?
 - A. Pneumonia
 - B. Lung congestion
 - C. Lung infarction
 - D. Exudation pleurisy
 - E. Pulmonary emphysema
4. There is dullness over the chest on the left of posterior lateral portions from the 10th to the 11th interspace. What diagnosis can be supposed?
 - A. Pneumonia
 - B. Lung infarction
 - C. Lung congestion
 - D. Exudation pleurisy
 - E. Obstructive atelectasis
5. There is dullness over the chest beginning from the 5th rib along the posterior axillary line, from the 8th rib along the paravertebral line, from the 7th rib along midaxillary line to the lower border of the lungs. What diagnosis can be supposed?
 - A. Pneumonia
 - B. Lung infarction
 - C. Lung cornification
 - D. Exudation pleurisy
 - E. Congestion in the lungs
6. There is dull tympanic sound over the chest on the left along the posterior and midaxillary line from the 7th to the 9th interspace. What diagnosis can be supposed?
 - A. Pneumonia
 - B. Pulmonary emphysema
 - C. Cavity in the lungs
 - D. Incomplete obstructive atelectasis
 - E. Exudation pleurisy
7. There is bandbox sound along the anterior surface of the chest. What diagnosis can be supposed?
 - A. Cavity in the lungs
 - B. Pneumothorax
 - C. Lung emphysema
 - D. Incomplete obstructive atelectasis of the lungs
 - E. Exudation pleurisy
8. There is tympanic sound from the 2nd rib to the lower border of the lungs on the right

side of the chest. What diagnosis can be supposed?

- A. Pulmonary emphysema
- B. Cavity in the lungs
- C. Pneumothorax
- D. Incomplete obstructive atelectasis
- E. Exudation pleurisy

9. There is tympanic sound from the 7th to the 9th interspace in the left axillary area, the sound is dull under this area. What diagnosis can be supposed?

- A. Pneumonia
- N.B. There can be two correct answers

- B. Pulmonary emphysema
- C. Pyopneumothorax
- D. Pneumothorax
- E. Exudation pleurisy

10. There is tympanic sound on the right along the parasternal and midaxillary areas from the 2nd to the 4th ribs. What diagnosis can be supposed?

- A. Pneumothorax
- B. Cavity in the lungs
- C. Pulmonary emphysema
- D. Pneumonia
- E. Exudation pleurisy

Keys: 1B,C; 2A,D; 3A,C; 4C,D; 5D; 6A,D; 7C, 8C, 9C, 10B.

Methodical instructions

RESPIRATORY SYSTEM EXAMINATION. LUNGS PERCUSSION. TECHNIQUE OF COMPARATIVE AND TOPOGRAPHIC PERCUSSION.

Methodical instructions for students

Authors: T.V. Ashcheulova
O. M. Kovalyova
G.V. Demydenko

Chief Editor Ashcheulova T.V.

Редактор _____
Корректор _____
Компьютерная верстка _____

Пр. Ленина, г. Харьков, 4, ХНМУ, 61022
Редакционно-издательский отдел