

Health care ministry of Ukraine
Kharkiv National Medical University

Chair of Phthisiology and Pulmonology

PHTHISIOLOGY

Note-book for self-students' work at home

IV course of higher medical foundation medical faculty with IV level of accreditation

Student's name _____

faculty _____ **group** _____

Kharkiv ____/____

The authors: O.S. Shevchenko, S.L.Matveyeva, A.I. Choporova

Approved at Chair of Phthisiology and Pulmonology

protocol №

_____ 2011.

This note-book is recommended for improvement of students' individual extra-auditorium training. It presents training tasks for mastering of phthisiology educational program's data.

The note-book is created accordingly to credit-module system of education.

Authors

Module №1
Tuberculosis epidemiology
Etiology and pathogenesis of tuberculosis
Immunity. Clinical classification of tuberculosis

I level. Read the pages 15-23, 64-68 A teaching manual in Ukrainian and English “Phthisiology” I.T. Pyatnochka, 2002 or the pages 15-41; 75-81 A textbook for students “Phthisiology” V. I. Petrenko, 2008 and the pages 4-8 “Phthisiology” Handbook for medical students with English medium for individual work O.S. Shevchenko with coauthors., 2011.

Answer to the question briefly in written form:

1. What are the main factors defining risk of a contact with mycobacterium tuberculosis?
2. What are the risk factors influence the incidence rate of tuberculosis?
3. Enumerate the epidemiological indices of tuberculosis prevalence
4. What are the groups of high risk to develop tuberculosis?
5. What disease might promote the increase of tuberculosis incidence rate?
6. What are the main sources of tuberculosis infection?
7. What are the main modes of TB transmission?
8. Enumerate the types of mycobacterium tuberculosis.
9. Enumerate the properties of mycobacterium tuberculosis (MTB) pathogenicity.

10. Write the classification of atypical MTB. What disease is caused by atypical MTB?
11. What is the basic pathogenic factor of MTB?
12. What is the structure and chemical composition of MTB?
13. What is L-shaped MTB?
14. What happens to macrophages on their first contact with MTB?
15. What is the structure of tuberculous granuloma?
16. What types of TB drug resistance do you know? Which conditions and environment factors promote TB drug resistance?
17. Describe two periods of tuberculosis infection
18. What are the ways of MTB spreading in the body?
19. Characterize peculiarities of tuberculosis immunity
20. What types of tuberculosis process according to classification do you know?
21. Recite the clinical forms of primary tuberculosis

22. Recite the clinical forms of secondary tuberculosis
23. Enumerate the methods of etiology confirmation of tuberculosis
24. What are the criteria for dispensary follow up?
25. Which categories of dispensary follow up are related to active TB? Which category is related to a group of high risk to develop TB?
26. Which phases of tuberculosis process reflect its activity?
27. Which phases of tuberculosis process correspond to his extinction?
28. Enumerate the complications of pulmonary tuberculosis.
29. What is the structure of tuberculosis clinical diagnosis?

2 level. Solve the tests:

1. Case of tuberculosis – is:

- a. chronic disease accompanied by recurrent cough, sputum expectoration and specific changes on X-ray;
- b. disease accompanied by changes on X-ray in the upper lung fields, and also in root's of the lymph nodes;
- c. disease confirmed by detection of mycobacterium tuberculosis, allocated from the affected focus, (with sputum, urine etc.) or received from tissues by biopsy.
- d. disease accompanied by X-ray changes in the upper lobe of the lung, hemoptysis and emaciation.
- e. disease confirmed by pathological changes in the upper lung fields on EMR tomography.

2. Tuberculosis incidence rate (incidence of new cases) is number:

- a. of tuberculous patients per 10 000 population;
- b. of tuberculous patients in percents from all population;

- c. of tuberculous patients per 1000 population;
 - d. of tuberculous patients with positive Mantoux test;
 - e. newly revealed patients in certain year per 100 000 population.
3. One untreated open case of tuberculosis infects in one year about:
- a. 20 persons;
 - b. 10 persons;
 - c. 10-12 persons
 - d. 30 persons;
 - e. 50 persons.
4. Tuberculosis as the reason of death among infectious diseases occupies:
- a. 1st place;
 - b. 5th place;
 - c. 6th place;
 - d. 8th place;
 - e. 9th place;
5. The first morphological reaction in the site of mycobacterium tuberculosis entering and multiplication will be:
- a. formation of caseous necrosis;
 - b. formation of tuberculosis granulomas;
 - c. formation of HeLa cells;
 - d. formation of elastic fibers;
 - e. formation of Boettcher's crystals
6. Concept of exogenic super infection includes:
- a. mycobacterium penetration from the outside into uninfected body;
 - b. penetration of mycobacterium from the outside into already infected organism;
 - c. repeated penetration of mycobacterium from the outside in previously uninfected body;
 - d. exogenic penetration of mixed unspecific infection from the outside into previously infected body
7. Endogenic reinfection is:
- a. activation of latent tuberculosis infection in the body;
 - b. occurrence of tuberculosis infection in internal organs as a consequence of exogenous TB infection penetration into the body;
 - c. progression of tuberculosis infection in the body.
 - d. activation of tuberculosis infection after confluence with non-specific infection.
8. Tuberculosis of the respiratory organs is characterized by:
- a. the acute start of the disease;
 - b. the gradual start of the disease;
 - c. the asymptomatic beginning of disease.
9. With tuberculosis of the respiratory organs, the changes between clinical data and those discovered on X-ray examination are as a rule:
- a. in complete correspondence;
 - b. there is no complete correspondence. Clinical symptoms that are more informative;
 - c. there is no complete correspondence. X-ray changes are more extensive.
10. The patient (42) complains on the fever up to 37,2 °C, weakness, sweats, cough with the sputum. Plane chest X-ray picture: infiltrate with cavitation is present in the right upper lobe, MTB were found in the sputum. Which diagnosis formulation is correct?
- a. new case of PTB (12.02.2011) of right upper lobe (infiltrative one), Destr+, MTB+, M+, C+, Hist. 0, Cat.1, Cog. 1(2011).
 - b. new case of PTB (12.02.2011) of right upper lobe (infiltrative one), Destr+, MTB+, M+, C+, Resist.0, Hist.0, Cat.1, Cog. 1(2011).

- c. new case of PTB (12.02.2011) of right upper lobe (infiltrative one), Destr+, MTB+, M+, C-, Hist.0, Cat.1, Cog.1 (2011).
- d. new case of PTB(12.02.2011) of right upper lobe (infiltrative one), MTB+, M+, C+, Resist I 0, Resist. II +, Hist.0, Cat..1, Cog.1 (2011).
- e. new case of PTB(12.02.2011) of right upper lobe (infiltrative one), Destr.+, Resist. I 0, Resist. II +, Hist.0.

11. The patient (43 years) was examined by clinical and X-ray methods. The diagnosis: new case of PTB (21.01.2011) of upper right lobe (infiltrative one), Destr.+, MTB+, M-, C+, Resist. I -, Resist. II -, Cat.1, Coh.1(2011). Which phase of tuberculosis the meaning “Destr + ” corresponds with?

- a. phase of infiltration
- b. phase of dissemination
- c. phase of induration
- d. phase of cavitation
- e. phase of resolution

12. The patient (23 years) complains on the weakness, subfebrile fever, mild cough with the sputum. After clinical, laboratory and X-ray investigations the diagnosis was made: new case of PTB(17.12.2011) of both lungs (disseminative one, phase of infiltration), Destr.+, MTB+, M-, C+, Resist. I-, Resist. II-, Hist.0, Cat. 1, Coh. 4 (2011). Which category the patients must be related to?

- a.Category 5
- b.Category 4
- c.Category 1
- d. Category 2
- e. Category 3

13.The patient (32 years) was undergoing chemotherapy in antituberculous dispensary with the diagnosis: new case of PTB (16.06.2011) of left S_{1,2} (infiltrative one), Destr+, MTB+, M+,C+, Resist I 0, Resist II 0,Hist 0,Cat 1,Coh 2(2011). During 6 months antimycobacterial chemotherapy was carried out in the hospital, then 2 months he was treated as outpatient. Now bacilli excretion is stopped, the cavern is healed. Which way to estimate the effectiveness of treatment?

- a.treatment is over;
- b.treatment failure;
- c.treatment interruption;
- d.patient is dropped out;
- e.recovery

14. The patient (40 years) complains on the cough with the sputum, weakness, fever. Physical findings: pathological changes of respiratory system are absent. Plane chest X-ray changes: cavity with peripheral inflammation is present in the right S_{1,2} and there are lesions of dissemination in both lungs. MTB are found in the sputum. The diagnosis was made: new case of PTB (15.01.2011) of right upper lobe (infiltrative one), Destr+, MTB+, M+,C+, Resist I 0, Resist II 0, Hist 0, Cat 1. Coh 1 (2011). Which method to find MTB corresponds with M+.

- a.culture method;
- b.biological test;
- c.bacteriological method;
- d.microscopy;
- e.method of pure culture.

15. The patient (38 years) takes medical treatment at antituberculosis dispensary. Preliminary diagnosis was: new case of PTB (12.11.2011.) of lungs (disseminative one, phase of infiltration and cavitation), Destr.+, MTB+, M+, C+, Resist.-, Resist II -, Hist.0, Cat.1, Cog.4 (2011). Which way to estimate the effectiveness of treatment?

- a. stopped bacilli excretion;
- b. the recovery;
- c. the treatment is continued;
- d. treatment failure;
- e.the treatment is over

16. Patient (34 years) was admitted at antituberculous dispensary due to infiltrates with cavitation revealed in upper right lobe of lungs by the chest X-ray examination. The complains: weakness, subfebrile fever, and cough with the sputum. Physical examination has not revealed any pathological changes in respiratory system. MTB were found in the sputum bacteriologically.

Which diagnosis formulation is correct?

- a.new case of PTB (15.11.2009.) (nodular one), Destr+, M-, C-, Hist.0, Cat. 3, Cog. 4 (2009)
- b.new case of PTB (15.11.2009.) of both lungs (disseminated one, phase of infiltration), Destr-, MTB-, C-, Hyst.0, Cat. 3, Cog. 4 (2009)
- c.new case of PTB (15.11.2009.) of the right middle lobe (infiltrated one), Destr.+, MTB-, C+, Hist.0, Cat. 3, Cog. 4 (2009)
- d.chronic case of PTB (3.12.2005.) of the right upper lobe (cirrhotic one), Destr.-, MTB-, C-, Hist.0, Cat. 3, Cog. 4 (2009)
- e. new case of PTB (15.11.2009) of the right upper lobe (infiltrated one), Destr.+, MTB+,M-, C+, Hist.0,Resist.0, Resist.11 0, Cat. 1, Cog. 4 (2009)

17. The patient (35 years) complains on breathlessness while walking, weakness, and pain in the area of heart. He suffers from tuberculosis during 15 years. Plane chest X-ray picture: intensive shadow spreads over upper left lobe with volume lost of the lobe, left hilum is up, and mediastinum shadow is shifted to the left. MTB are found in the sputum by culture method.

Which clinical form of tuberculosis the patient suffers with?

- a. fibrous-cavernous one;
- b. infiltrative one;
- c. caseous pneumonia
- d. cirrhotic tuberculosis;
- e. tuberculoma.

18. The patient (30 years) was admitted at antituberculous dispensary with first diagnosed changes in the X-ray picture: the shadow with the diameter about of 1 cm, of slight intensity with unclear counters with the cavitation in the centre revealed by tomography. MTB are found in the sputum by culture method. The diagnosis of nodular tuberculosis was made.

Which phases of tuberculosis X-ray changes corresponds with?

- a. phase of infiltration and dissemination
- b. phase of infiltration and cavitation
- c. phase of resolution and scarring
- d. phase of cavitation and dissemination
- e. phase of induration and resolution

1. a b c d e	6. a b c d e	11. a b c d e	16. a b c d e
2. a b c d e	7. a b c d	12. a b c d e	17. a b c d e
3. a b c d e	8. a b c d	13. a b c d e	18. a b c d e
4. a b c d e	9. a b c	14. a b c d e	
5. a b c d e	10. a b c	15. a b c d e	

3 level. Resolve the clinical situational tasks:

1. A patient S, 29 year, in 3 weeks after influenza had a cough with sputum expectoration; shortness of breath, general weakness, night sweats, the fever was up to 39 °C. 2 years ago the patient was treated

for 2 weeks in connection with the right-side exudative pleurisy. On X-ray throughout the whole length of both lungs nodular shadows of medium and big sizes with vague contours are seen. MTB are found in the sputum by culture method.

What would be a correct diagnosis according to clinic classification?

2. A 20-year-old patient revealed his right lung caseous pneumonia, placed in its upper part. There is MTB in excretion. There is a darkened area placed in the right lung upper part having multiple fields of translucency. Besides there is low intensity focal shadow with unclear contours localized in the down parts of both lungs.

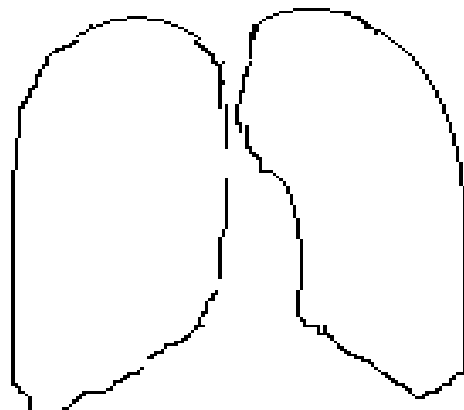
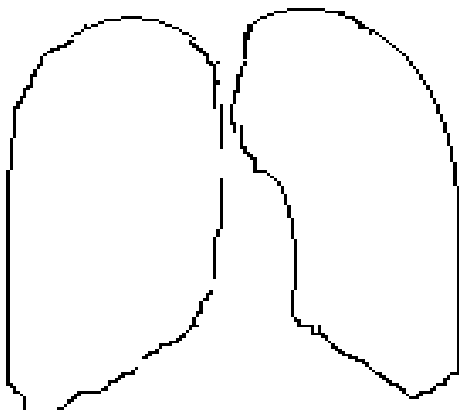
What phase of TB process is it?

3. A 25-year-old patient has complaints on high temperature (up to 39⁰C), weakness, hemorrhage, body mass large loss. X-Ray picture says as follows: 1) the right lung VI segment blackout and the lung size lessening, 2) dilation of the lung root on account of expanding intrathoracic lymph nodes. Blood index is L-12x10⁹/l, ESR – 27 mm/hour. Bronchoscopy shows that glands-bronchial fistula is taking place in the VI segmental bronchus. There is MTB in excretion, according to bacteriological analysis.

To what category should the patient belong?

4 level. Set up localization of each segments in both lungs.

Point out “alarm zones” for tuberculosis, typical location of pneumonia and malignant processes.



Student's subscription: _____

Module № 2

General approaches to TB diagnostics. Special methods to reveal and diagnose a TB case (microbiology diagnostics, X-ray investigations, tuberculin test).

1 level. Read the pages 25-46 A teaching manual in Ukrainian and English “Phthiology” I.T. Pyatnochka, 2002 or the pages 41-70 A textbook for students “Phthiology” V. I. Petrenko, 2008 and the pages 12-14 “Phthiology” Handbook for medical students with English medium for individual work O.S. Shevchenko with coauthors, 2011.

Answer briefly in written form to the question:

1. What patients' complains are characteristic of tuberculous intoxication?
2. What patients' complains is characteristic of bronchi-pulmonary-pleural syndrome?
3. What are the masks of tuberculosis?
4. What percussion phenomena can be found in different clinical forms of tuberculosis process?
5. What auscultation phenomena can be found in different clinical forms of tuberculosis process?
6. Enumerate compulsory and additional investigation methods in case of pulmonary tuberculosis suspicions.
7. Using which methods of diagnostics one can probably confirm pulmonary tuberculosis?
8. What kind of bacterioscopy methods revealing of MTB do you know? How they perform?
9. What advantages and deficiency of bacterioscopy method revealing of MTB?
10. What advantages and deficiency of bacteriological method revealing of MTB?
11. What other specimens other then sputum can be collected from a tuberculous patient?

12. What is the method of bronchial lavage?
13. How many TB bacilli should 1 ml contain for the successful diagnosis with bacterioscopy and culture?
14. What are the methods of accelerated TB identification?
15. What kind of MTB resistance to the antituberculous drugs do you know?
16. What kind of pathological shadows is characteristic for pulmonary tuberculosis?
17. What is the criterion for nodular shadow detection? Give characteristic signs of them.
18. What is the criterion for focal shadow detection? Give characteristic signs of them.
19. What are the criteria for disseminated shadow detection? Give characteristic signs of them.
20. What are the criteria for round shadow detection? Give characteristic signs of them.
21. What is cavity? What kind of them do you know?
22. Enumerate and characterize phases of tuberculosis process, which ascertained by X-ray examination.

23. What is tuberculin?
24. Enumerate the types of tuberculin.
25. Indicate the purposes of tuberculin test performance for adults and for children.
26. What factors can suppress tuberculin reaction?
27. What factors can intensify tuberculin reaction?
28. What way the results of Mantoux test with 2 TU PPD-L are interpreted?
29. What is the conversion of tuberculin skin test?
30. What does positive Mantoux test with 2 TU PPD-L indicated to?
31. What are the contraindications to tuberculin test?
32. What are the goals of Koch test performance?
33. How the results of Koch test are interpreted?

34. What changes in complete blood count are characteristic of a tuberculosis patient?

35. What histological signs of tuberculosis do you know?

2 level. Solve the tests:

1. Which X-ray sign is permitted to suppose cavity in the lung?

- a. translucency on darkening background;
- b. ring shadow;
- c. absents of bronchial -vesicular patterns in the limited areas of damaged lung;
- d. a and b are correct;
- e. all above enumerated are wrong.

2. Which method is used more often for revealing of cavitation in lung tissue?

- a. plain X-ray;
- b. tomography;
- c. target X-ray;
- d. radioscopy;
- e. bronchography

3. The patient (48 years) complains on the weakness, raised body temperature up to 37,7°C, cough with a sputum, breathlessness. The patient is of lowered body weight. The slight dullness is heard over the upper lobes of lungs and tympanic sound is heard over the lower lobes during the percussion. Bronchial breathing is heard over the upper lobes of lungs and weakened breathing is heard is over the lower lobes during the auscultation. Plain chest X-ray picture: dissemination with the lesions of moderate intensity of 5-10 mm in the diameter with unclear counters is present. The translucency of lung tissue is increased in the lower lobes. Which changes in lungs are the cause of the tympanic sound and increased translucency of lung tissue in the lower lobes?

- a. emphysema development;
- b. bronchiectatic formation;
- c. pneumosclerosis formation;
- d. pleurisy involvement;
- e. infiltrative foci which appear after lesions have fused.

4. The patient (33 years) complains on the cough with the sputum, weakness, fever up to 37,2°C, poor appetite during 3 weeks. Physical examination did not reveal any pathological changes.

What is necessary to clear during past history detailing?

- a. smoking;
- b. regimen of the work and rest;
- c. contact with tuberculous patient;
- d. going in for sport;
- e. presence of emotional lability.

5. The patient (55 years) suffers from tuberculosis during 3 years. He complains on the cough with the sputum, fever, weakness, breathlessness on physical exertion. Amphoric breathing sound is heard over the subclavicular area of the right lung.

Which changes in the lungs stipulated such auscultative phenomena?

- a. exudates;
- b. large cavern;
- c. lung atelectasis;
- d. small cavern;
- e. cirrhotic changes.

6. The patient (32 years) was admitted at antituberculous dispensary with the relapse of tuberculosis. The patient's examination revealed the signs of bronchial-pulmonary syndrome.

Which symptoms are characteristic for bronchial-pulmonary syndrome?

- a. fever, weakness, poor appetite, lost of weight, sweats;
- b cough, weakness, insomnia, headache, hoarseness;
- c. cough with sputum, weakness, hoarseness, dry rales, dullness during the percussion;
- d. breathlessness, insomnia, malaise, moist rales, vocal phremitus;
- e. dyspepsia, vomiting, rashes, sweats, cough, fever.

7. What is the cause of pain in the chest at "fresh" uncomplicated tuberculosis

- a. decay of lung tissue;
- b. high-grade exudation of lung tissue;
- c. bronchus lesions ;
- d. pleura affection ;
- e. prevalence of productive reaction.

8. Which method of MTB revealing is more sensitive and specific?

- a. direct microscopy;
- b. cultural investigation;
- c. biological probe;
- d. polymerase chain reacti;
- e. immune- enzyme analysis.

9. Which method allow to determine sensitivity MTB to antituberculous drugs

- a. bacterioscopic;
- b. bacteriological;
- c. polymerase chain reaction;
- d. immune- enzyme analysis;
- e. biological.

10. What are the characteristic urine changes at pulmonary tuberculosis with significant intoxication signs?

- a. moderate proteinuria, moderate leukocyturia, total macrohematuria;
- b. moderate leukocyturia, solitary erythrocytes;
- c. significant proteinuria without leukocytes quantity changes, initial macrohematuria;
- d. ischuria, cylindruria, microhematuria;
- e. total macrohematuria with painful syndrome.

11. Who and when submit Mantoux test with 2 TU PPD-L?

- a. adults annually;
- b. children and teenagers quarterly;
- c. children since 12- month annually independently on results of previous probe.
- d. children, who often suffer from acute respiratory disease
- e. to all contingents of children and

12. Who does not need reexamination at phthisiologist?

- a. The person with firstly positive reaction, which unbound with BCG immunization ;
- b. The person with hyperergic reaction of Mantoux test with 2 TU PPD-L;
- c. The person with increased tuberculin sensitivity (by 6 mm and more) during 1 year (at tuberculin positive child and teenagers);
- d. The person with positive Mantoux test result with 2 TU PPD-L during 1,5-2 years after; qualitative vaccination by BCG or BCG-M vaccine;
- e. The person with durable preservation tuberculin reaction papule size 12 mm and more during several years.

13. What period of time must be passed after Mantoux test with 2 TU of PPD-L till BCG vaccination is allowed to perform?

- b. in 6 month;
- c. in 2 weeks;
- d. in 3 days;
- e. in 1 month.

14. Negative tuberculin test in a child of early age:

- a. allows to exclude primary infection;
- b. is the proof of an inefficiency of BCG vaccination;
- c. tuberculin testing is not the criteria for primary infection;
- d. allows to testify presence of active tuberculosis;
- e. allows to suspect presence of immunodeficiency.

15. Definition of drug sensitivity is basically pursuing the following purposes:

- a. selection of anti-tubercular preparations for treatment;
- b. maintenance of clinically helpful information for individual correction of chemotherapeutic tactics;
- c. epidemiological monitoring;
- d. scientific studies;
- e. all above mentioned.

16. The child (5 years) shows the result of Mantoux test with 2 IU of PPD-L as papule of 14 mm in the diameter. BCG scar of 7 mm is on the left arm. At the age of 4 years old Mantoux test was of 5 mm. Which definition of this Mantoux test is correct?

- a. tuberculin test conversion;
- b. hyperergic tuberculin reaction;
- c. positive reaction;
- d. increasing tuberculin sensitivity;
- e. tuberculin conversion with hyperergic reaction.

17. The child (3 years) was BCG vaccinated at maternity home. There is BCG scar on his left shoulder with the diameter of 7mm. At the age of 1 year old Mantoux test with 2IU PPD-L was of 10 mm, 2 years – 8 mm, 3 years – 14 mm.

Which conclusion made on the ground of tuberculin test is correct?

- a. secondary pulmonary tuberculosis;
- b. post-BCG immunity;
- c. infectious immunity;
- d. hyperergic tuberculin reaction;
- e. tuberculin conversion with hyperergic reaction.

18. The child (4 years) was BCG vaccinated at maternity home. BCG scar is of 7 mm. At the age of 1 year Mantoux test was not done. At the age of 2 year Mantoux test result was of 8 mm, at the age of 3 year Mantoux test result was of 6 mm, at the age of 4 year Mantoux test result is 3mm.

Which conclusion must be done on the ground of Mantoux test results?

- a. TB infection;
- b. Positive tuberculin test;
- c. Tuberculin conversion;
- d. BCG-induced immunity;
- e. Negative tuberculin test.

1. a b c d e	6. a b c d e	11. a b c d e	16. a b c d e
2. a b c d e	7. a b c d e	12. a b c d e	17. a b c d e
3. a b c d e	8. a b c d e	13. a b c d e	18. a b c d e
4. a b c d e	9. a b c d e	14. a b c d e	
5. a b c d e	10. a b c d e	15. a b c d e	

3 level. Solve the clinical situational tasks:

1. The child at the age of 3 years old was admitted to a hospital at the severe state: fever 38,0-39,0 °C, diffused cyanosis. Pulse – 140 beats per 1 min, breathlessness – 35 in min., dry cough. At physical examination is revealed diffuse cyanosis, on auscultation: weakened vesicular breathing. The liver is under the rid with 3 cm. Plain X-ray picture was shown: multiple equal lesion of slight intensity with diameter 1-2 mm diffused symmetrically all over the lung fields. Mantoux test papule size 22 mm, a year ago – 5 mm. BCG sign – 3mm. Blood test: leucocytes -17,0 $10^9/l$, sticks. – 10%, lymph.- 16%, ESR – 35mm/h. MTB are absent in the sputum microscopically. Past history: it was the contact with his grandmother suffers from tuberculosis. Separate out from task condition symptoms of disease and form their groups according to pathogenic syndromes complex.

Symptoms	Syndromes

2. The patient C., 36 years old, address one's requests to family doctor with complaints on cough with mucous-purulent sputum during 3 weeks, weakness, fatigability, night sweats, body temperature 37,2 - 37,3°C during month. Patient have been smoked during 15 years, doesn't drink. He is resided with father suffers from fibrous-cavernous tuberculosis of lungs. Objectively: on examination pathological changes was not revealed, percussively – distinct vesicular resonance, auscultation – rough breathing, isolated dry rales.

What could be suspected at the person and because of what signs?

What is the tactics of family doctor?

3. The patient D. of 28 years old has no complains. He was in the contact with the neighbor suffering from tuberculosis. He hadn't been examined for last 3 years by X-ray. When he becomes employed focus shadowing 4 cm in diameter, middle intensity with vague contours and sickle-shaped eccentric translucency in right lung S₁ was revealed by X-ray. Blood analysis is normal. Objectively: on examination pathological changes was absent, percussively – clear vesicular resonance, on auscultation – vesicular breathing.

What signs tuberculosis suspected are present at the person?

Which investigation could confirm the diagnosis of tuberculosis?

Make an X-ray diagnosis (clinical form of tuberculosis, localization of pathology, phase of tuberculosis process)

4. The child at the age of 7 year is resides in a nidi of tuberculous infection. He was vaccinated BCG in maternity house. At the age of 1 and 2 years papule of Mantoux test with 2 TU PPD-L was 10 mm and 8 mm in diameter. At the age of 3 year - 4 mm. At the age of 4, 5, 6 years – negative, at the age of 7 years - papule 17 mm. Postvaccinal seam is marked.

What is the nature of reaction on Mantoux test with 2 TO in 1 year?

What is the nature of reaction on Mantoux test with 2 TO in 7 year?

What is the tactics of a doctor concerning revaccination?

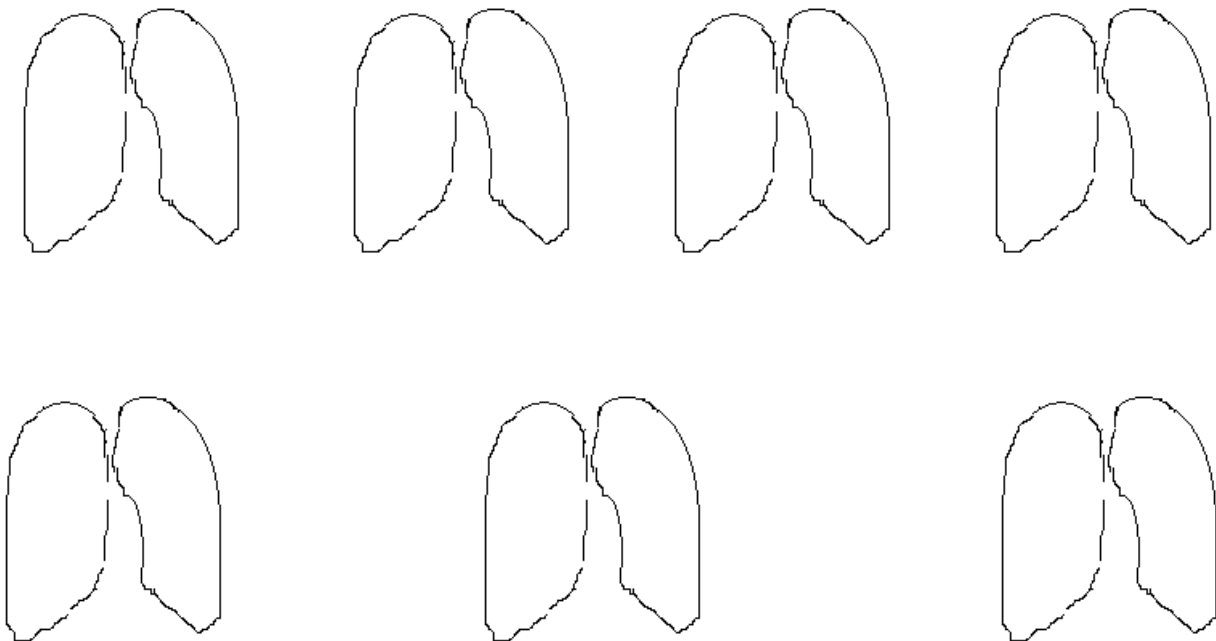
What is the further judgment and management of this case by doctor?

4 level.

1. Complete scheme of distinction between post-vaccination tuberculin allergy and post-infectious allergy.

Criteria	Post-vaccination tuberculin allergy	Post-infectious allergy
Time appearance of positive tuberculin reaction		
Evidence degree of tuberculin reaction		
Tuberculin reaction in dynamics		
Clinical signs of disease		
Contact with a person discharging mycobacteria		
Post-vaccination scar		
Pigmentation		

2. Draw up the X-ray view of tuberculosis changes according to radiological syndromes?



Student's subscription: _____

Module № 3

Prophylaxis against tuberculosis. Social prophylaxis. Sanitary prophylaxis. BCG vaccination and revaccination. Chemoprophylaxis.

1 level. Read the pages 224-236 A teaching manual in Ukrainian and English “Phthisiology” I.T. Pyatnochka, 2002 or the pages 263-271 A textbook for students “Phthisiology” V. I. Petrenko, 2008 and the pages 27-31 Handbook for medical students with English medium for individual work O.S. Shevchenko with coauthors.

Give an answer in written form to the next question:

1. Give the definition of “tuberculosis prophylaxis”
2. What is the classification of tuberculosis prophylaxis?
3. What is related to social prophylactics of tuberculosis?
4. What is related to sanitary prophylaxis of tuberculosis?
5. Give the definition of tuberculous infection nidus, enumerate groups of them depending on their epidemic danger.
6. What are the criteria for the epidemic danger of TB infection nidus does you know?
7. What is the BCG vaccine and how many microbial bodies 1 mg of BCG vaccine contains?

8. What is the goal for vaccination and revaccination?
9. What dose of BCG and BCG-M vaccine is used for vaccination?
10. Enumerate timely contraindications for BCG vaccination?
11. Enumerate absolute contraindications for BCG vaccination
12. What are the complications, which might appear after BCG vaccination or revaccination.
13. What is BCG revaccination? What terms for its performing?
14. Enumerate contraindications to BCG revaccination?
15. What is chemoprophylaxis and what types of chemoprophylaxis are there?
16. What are the aims and measures for chemoprophylaxis?
17. What population contingents should receive chemoprophylaxis?

2 level. Solve the tests.

1. What ensure the development of antituberculous immunity at BCG vaccination?

- a. alive MTB of vaccine strain ;
- b. destroyed MTB of vaccine strain ;
- c. L- shape form of vaccine strain ;
- d. vitality products of vaccine strain ;
- e. all above mentioned are correct.

2. To whom application of BCG-M vaccine is indicated?

- a. prematurely born child with body weight at delivery 2000g and more;
- b. prematurely born child with body weight after nourishment 2300g and before discharging from maternity hospital;
- c. child, who not vaccinated at maternity hospital, by medical indication after recovery in 1-6 month;
- d. all above mentioned are correct ;
- e. all above mentioned are is wrong.

3. How long has been formatted immunity vaccination after BCG vaccination?

- a. 2 weeks;
- b. 1 month;
- c. 2 month;
- d. 4 month;
- e. 10 month.

4. Which method of vaccine BCG introduction used at Ukraine?

- a. per os; b. cutaneous ; c. intracutaneous; d. subcutaneous;
- e. all above mentioned are correct.

5. Which size of post-vaccination scar corresponded to the presence of vaccine immunity?

- a. 1-2 mm;
- b. 3-4 mm;
- c. 5-7 mm; d. all above listened are correct; e. all above mentioned are wrong

6. What is the contraindication to BCG revaccination?

- a. revaccination BCG 5 years ago; b. positive anergia;
- c. contamination by MTB; d. presence of scar after previous vaccination;
- e. all listened above are correct.

7. Which variant, among listened below, does not belong to a contraindication for BCG revaccination?

- a. contamination by MTB or tuberculosis in the past;
- b. positive anergy;
- c. 1 month recovery after infectious diseases;
- d. aggravation stage of allergy disease;
- e. immunodeficiency conditions or treatment by immunosuppressant.

8. What reduces tuberculous infection spreading?

- a. timely revealing of tuberculous patients ;
- b. isolation and treatment of massive bacilli excretion persons ;
- c. abolishment of infected by tuberculosis animals;
- d. antituberculosis immunization and chemoprophylaxis of contact person;
- e. all mentioned are correct.

9. What is chemoprophylaxis of tuberculosis?

- a. handling of patients' apartment by disinfection agents ;
- b. prescription of antituberculous drugs to the patients;
- c. prescription of antituberculous drugs to health person from groups of risk;
- d. all above mentioned are correct;
- e. all above mentioned are wrong.

10. Which antituberculous drugs are used at chemoprophylaxis for morbidity rate prevention?

- a. streptomycin ;
- b. isoniazid;
- c. rifampicin;
- d. ethambutol.

11. Among main causes producing hyperergic sensitivity to tuberculin are:

- a. tuberculosis;
- b. activation of a tuberculosis infection in a body;
- c. increasing level of specific sensibilization of a body owing to a super infection, and also the active form of tuberculosis;
- d. factor of nonspecific allergy.

12. The patient (35 years) has the diagnosis: new case of PTB (7.02.2009) of the right lung (infiltrative one) Destr.+, MTB+,M-,C+, Resist.-, Resist. 11-, Hist.0, Cat. 1, Coh.1 (2009). Bacilli excretion is scanty. The patient resides with his wife and his mother.

Which type of TB nidus the patient's residence belongs to?

- a. this residence is not TB nidus;
- b.1 type;
- c.3 type;
- d.2 type;
- e. conventional one.

13. The patient (25 years) has the diagnosis: new case of PTB (7.03.2009) of the right upper lobe (infiltrative one) Destr.+, MTB+,M-,C+, Resist.-, Resist. 11-, Hist.0, Cat. 1, Coh.1 (2009). The patient resides with his wife and his daughter of 1 year old.

Which measure must be performed in such type of TB nidus for the first turn?

- a. to examine the wife;
- b. to improve patient's living conditions;
- c. to carry out chemoprophylaxis to his wife and his daughter;
- d. to perform current disinfection;
- e. to isolate (hospitalize) the patient .

14. The woman gave birth to the healthy child with 3 kg of body weight (8 balls according to Apgar's scale). Baby's father suffers from "open case" of tuberculosis (TB) and is at home now.

What is the pediatrician's management concerning the child?

- a. to vaccinate the child with BCG-1 and discharge him from the maternity home;
- b. to vaccinate the child with BCG-1, discharge him from the maternity home and to carry out the course of chemoprophylaxis;
- c. to vaccinate the child with BCG-1 and keep him at the maternity home for 1 month more;
- d. to vaccinate the child with BCG-M and discharge him from the hospital;
- e. to vaccinate the child with BCG-1, discharge him from the maternity home and to send his father to antituberculous hospital.

15. The woman suffers from fibrous-cavernous pulmonary tuberculosis (MTB+) gave birth to the healthy child with 3800 g of body weight (8 balls according to Apgar's scale). Just after the birth the child was isolated from the sick mother.

What is the pediatrician's management concerning the child?

- a. to perform chemoprophylaxis;
- b. to perform X-ray examination;
- c. to perform BCG-1 vaccination;
- d. to perform BCG-M vaccination;
- e. to perform Mantoux test with 2TU of PPD-L.

16. 5 kids were Mantoux tested with 2TU of PPD-L before BCG revaccination. Following results were obtained: 1st child – papule of 10 mm, 2nd child – papule of 4 mm with the vesicle in the centre, 3rd child – papule of 3 mm, 4th child – hyperemia only, 5th child – injection reaction.

Which child submits to BCG revaccination?

- a. 1st
- b. 2nd
- c. 3^d
- d. 4th
- e. 5th

17. The child (6 months) was not BCG-1 vaccinated at maternity home because of acute viral infection. Now the child is well. BCG-vaccination is needed.

Which investigation is needed to solve the question about BCG-vaccination?

- a. Mantoux test with 2TU of PPD-L;
- b. blood test;
- c. biochemical blood test;
- d. X-ray examination;
- e. immunological blood test.

18. In specialized maternity home department the woman suffers from “open case” of TB has the prematurely born child with body weight of 2300 g and height of 50 cm. The child is well.

What is the pediatrician's management concerning the child?

- a. to BCG-1 vaccinate at maternity home;
- b. to BCG-M vaccinate at maternity home;
- c. to BCG-1 vaccinate during the first 2 months of life in the polyclinic;
- d. to BCG-M vaccinate during the first 2 months of life in the polyclinic;
- e. to perform chemoprophylaxis and then to BCG-1 vaccinate.

19. The child (3 months) was BCG-1 vaccinated at maternity home at birth. The child's general state now is satisfied but vaccination complication develops – lymphadenitis (enlarged armpit lymphatic node with the abscess). Which local treatment the child is needed?

- a. local therapy only;
- b. isoniazid + local therapy only;
- c. isoniazid +rifampicin+ local therapy only;
- d. isoniazid +rifampicin;
- e. rifampicin+ local therapy.

20. The child (7 years) shows hyperergic Mantoux test result – papule of 22 mm in the diameter. This boy is in the contact with his grandmother suffers from “open case” of pulmonary TB. Course of chemoprophylaxis is needed for the boy.

Which drug (or drug combination) is needed to be exploited for secondary chemoprophylaxis?

- a. Isoniazid;
- b. isoniazid + ethambutol;

- c. ethambutol + pyrazinamide;
- d. rifampicin + pyrazinamide;
- e. isoniazid + PAS.

1. a b c d e	6. a b c d e	11. a b c d e	16. a b c d e
2. a b c d e	7. a b c d e	12. a b c d e	17. a b c d e
3. a b c d e	8. a b c d e	13. a b c d e	18. a b c d e
4. a b c d e	9. a b c d e	14. a b c d e	19. a b c d e
5. a b c d e	10. a b c d e	15. a b c d e	20. a b c d e

3 level. Solve the clinical tasks:

1. In child (7years) after 6 months of BCG-1 revaccination keloid scar of 5 mm in the diameter has appeared on the left shoulder in the site of injection. General state is good.

What is the pediatrician's management according to the child?

2. The girl (7 years) was BCG-1 vaccinated at birth. Mantoux test with 2 TU of PPD-L result at the age of 1, 2 and 3 years old is negative. BCG-scar on the left shoulder is absent.

What is the pediatrician's management concerning the child?

3. The woman suffering from fibrous-cavernous pulmonary TB (MTB+) gave a life to healthy infant with body weight of 3800g who received 10 scores by Apgar' scale.

What is the pediatrician's measures concerning the child?

Is BCG vaccination indicated for the child?

4 level. Make a plan of preventive measures at the tuberculous nidus, where patient suffering from fibrous-cavernous tuberculosis, MBT (+) resides if there are two adults and two kids in the family and if one child has positive tuberculin reaction.

Student's subscription: _____

Module № 4

Main principles of TB patient treatment. Antituberculosis drugs. Standardized chemotherapy regimens of TB patient treatment.

TB patient adjacent (non-specific) treatment. Antituberculosis drugs. Hygienic regimen, diet, pathogenic, symptomatic treatment. Surgical treatment. Sanatorium treatment.

1 level. Read the pages 195-221 A teaching manual in Ukrainian and English “Phthiology” I.T. Pyatnochka, 2002 or the pages 207-242 A textbook for students “Phthiology” V. I. Petrenko, 2008 and the pages 36-40, 45-47 “Phthiology” Handbook for medical students with English medium for individual work O.S. Shevchenko with coauthors., 2011.

Give an answer in written form to the next question:

1. Enumerate the basic principles of tuberculosis patients' treatment?
2. What are the phases of tuberculosis patients' treatment?
3. Write the classification of antimycobacterial drugs
4. What is primary and secondary drug resistance?

5. What is the most frequent cause of drug resistance?
6. What does “complex therapy mean”? What does “combinative therapy” mean?
7. What are the standardized regimens of antimycobacterial chemotherapy at the initial phase according to category number? I II III IV
8. What dietetic regimen is applied to the patient suffering from tuberculosis. Make a background for its application.
9. What are the indications and contraindications to corticosteroid therapy?
10. What pathogenic and symptomatic therapy can be applied for treatment of tuberculosis?
11. What are the criteria of TB patient recovery?
12 Enumerate indications for surgical treatment of pulmonary tuberculosis patient
13. What are the indications for pulmonary tuberculosis patient’s treatment at a health resort?

2 level. Solve the tasks.

1. The diagnosis of mycobacterium tuberculosis primary drug resistance is established if:
 - a. resistance of mycobacterium, which has been isolated from the patient never treated before with antituberculosis drugs;
 - b. resistance of mycobacterium isolated from the patient treated with antituberculosis drugs no more than 4 weeks;
 - c. infection by resistant mycobacterium tuberculosis;
 - d. resistance of mycobacterium isolated from the patient treated with antituberculosis drugs during several courses of chemotherapy.

2. Acquired (secondary) resistance of mycobacterium tuberculosis is:
 - a. drug resistance of mycobacterium tuberculosis developed during the treatment of tuberculosis;
 - b. drug resistance of mycobacterium isolated from the patient never taking antituberculosis preparations before;
 - c. infection by resistant mycobacterium tuberculosis.
 - d. all above mentioned are correct

3. Multidrug resistance tuberculosis is:
 - a. resistance of mycobacterium tuberculosis to any one antituberculous drug.
 - b. resistance of mycobacterium tuberculosis to isoniazid and rifampicin.
 - c. resistance of mycobacterium tuberculosis to symptomatic and pathogenic drugs.
 - d. distribution of various substances in nature by various human activities;

4. Formation of MTB resistance to antituberculosis drugs is caused by:
 - a. natural abilities of mycobacterium tuberculosis to genetic mutations;
 - b. inadequate treatment (including interruption) with antituberculosis drugs;
 - c. long treatment by single antituberculosis preparations.
 - d. all above mentioned are correct

5. During treatment with single or with combination of inadequately chosen antituberculosis drugs, resistance of mycobacterium tuberculosis is developed in:
 - a. 2-3 weeks;
 - b. 2-3 months;
 - c. in one year;
 - d. 1-10 days.

6. At the present the most dangerous form of multidrug-resistance of mycobacterium tuberculosis is:
 - a. simultaneous drug resistance of mycobacterium tuberculosis to several antituberculosis preparations;
 - b. drug resistance of mycobacterium tuberculosis to rifampicin and isoniazid;
 - c. drug resistance of mycobacterium tuberculosis to pyrazinamide and isoniazid;
 - d. drug resistance of mycobacterium tuberculosis to streptomycin and PAS.

7. What is the side effect caused by usage of rifampicin?
 - a. neurotoxicity;
 - b. hepatotoxicity;
 - c. nephrotoxicity;
 - d. influence on digestive system function.

8. What is the side effect caused by usage of isoniazid?
 - a. caused polyneuritis;
 - b. caused arthritis;

- c. influence on blood pressure;
- d. influence on visual acuity;
- e. ototoxicity.

9. Which antituberculous drug induces hepatotoxicity?

- a. isoniazid, streptomycin, ethambutol;
- b. isoniazid, rifampicin, pyrazinamide;
- c. ethionamide, kanamycin, isoniazid;
- d. ethambutol, cycloserin, florimycin sulfate;
- e. rifampicin, streptomycin, pyrazinamide.

10. The patient (40 years) takes the course of chemotherapy at antituberculous department with the diagnosis: new case of PTB (15.02.2009) of the upper right lobe (infiltrative one, phase of cavitation and dissemination), Destr.+, MTB+, M-, C+, Resist. -, Resist.II 0, Hist.0, Cat.1, Coh.1 (2009). 3 months after the chemotherapy had been begun the patient leaved the ward by his own decision. He did not take anti- TB drugs during following 2,5 months. Now he was admitted at the hospital again because the disease progresses.

Which chemotherapy regimen is needed for the patient?

- a. isoniazid + rifampicin + streptomycin + ethambutol;
- b. isoniazid + rifampicin + ethambutol + pyrazinamide;
- c. isoniazid + rifampicin + streptomycin + pyrazinamide;
- d. isoniazid + rifampicin + streptomycin + ethambutol + pyrazinamide;
- e. isoniazid + streptomycin + kanamycin.

11. The patient (42 years) takes the course of chemotherapy at antituberculous department with the diagnosis: new case of PTB (01.01.2011) of the upper right lobe (infiltrative one, phase of cavitation and dissemination), Destr.+, MTB+, M-, C+, Resist. I -, Resist. I 0, Hist.0, Cat.1, Coh.1(2011). Plain X-ray picture: infiltrates with the cavity of 3 x 4 cm in the diameter and the lesions of bronchogenic dissemination in both lungs. The treatment with chemotherapy of isoniazid (0,3) + rifampicin (0,6) + streptomycin (1,0) + pyrazinamide (2,0) regimen was prescribed. 2,5 months later X-ray examination reveals significant resolution of the lesions and infiltrates and the reducing of cavity. Bacilli excretion remains the same.

Which further treatment management is correct?

- a. to apply surgery intervention
- b. to continue the chemotherapy according the same scheme
- c. to use a new scheme of the chemotherapy in the regimen:
- d. isoniazid + rifampicin + streptomycin + ethambutol + pyrazinamide
- e. to continue the chemotherapy with isoniazid + rifampicin + streptomycin

12. In the patient (24 years) the diagnosis of new case of PTB (14.02.2011) of the upper right lobe (infiltrative one, phase of cavitation and dissemination), Destr.+, MTB+, M-, C+, Resist. + (H, R), Resist.II 0, Hist.0, Cat.1, Coh.1 (2011) was made for the first time. 6 months later the patient was discharged from the hospital because of he ignored the hospital regime. Then 2 months later he again was admitted at the hospital to continue the chemotherapy. Now the diagnosis is new case of PTB (14.02.2011) (fibrous-cavernous one, phase of infiltration and dissemination), Destr.+, MTB+, M-, C+, Resist. I+ (H, R,E,Z), Resist. II 0, Hist.0, Cat.1, Coh.1 (2011). Plain X-ray picture: giant cavern with the diameter of 6 x 7 cm is present in the upper right lung. Surgery intervention is suggested.

Which kind of surgery is the most rational to be exploited in this case?

- a. Cavernotomy;
- b. Pulmonectomy;
- c. Segmentectomy;
- d. Lobectomy;

e. Cavern plastic;

13. The patient (36 years) was admitted at the antituberculous dispensary with the diagnosis: new case of PTB (4.11.2009) of lungs (disseminative one, phase of infiltration), Destr.+, MTB+, M+, C+, Resist. 0, Resist. 11 0, Hist.0, Cat.1, Coh.4 (2009). According to Category 1 chemotherapy regimen was prescribed: isoniazid + rifampicin+ streptomycin+ pyrazinamide. The patient is alcohol abuser. Which drug as non-specific medication is the most rational one for the patient?

- a. Ambroscsol;
- b. Karsil;
- c. Lidase;
- d. Trental;
- e. Almagel;

14. Therapeutic tactics with the appearance of adverse reactions in the period of chemotherapy is determined by:

- a. the degree of the manifestation of side effects;
- b. the correct identification of the chemical preparation, which produced side effect;
- c. the pathogenesis of the revealed side effect;
- d. timely taking of the remedial measures.
- e. all above mentioned

15. The duration of hospital course of treatment of the tuberculous patient is determined by:

- a. clinical form of tuberculosis;
- b. presence destructive changes in lungs;
- c. massive bacteria expectoration;
- d. efficiency of spent medical measures;
- e. presence of accompanying measures.

1. a b c d e	6. a b c d e	11. a b c d e
2. a b c d e	7. a b c d e	12. a b c d e
3. a b c d e	8. a b c d e	13. a b c d e
4. a b c d e	9. a b c d e	14. a b c d e
5. a b c d e	10. a b c d e	15. a b c d e

3 level. Solve the clinical situation tasks:

1. The patient (40 years) was in contact with patient suffering from tuberculosis at the childhood. When he become employed shadow of darkening 2 cm in diameter with middle intensity and distinct contours is revealed by X-ray examination in the S₁ of right lung. Solitary nodular of low intensity shadow is detected at the nearest lung tissue. Any complains are absent. No pathology was revealed by physical examination. Blood analysis is normal. MTB is not revealed. The diagnosis was established: tuberculoma in the right lung S₁, MTB-.

Which category the patient must be related to?

Which chemotherapy regimen is needed for the patient at the intensive phase?

2. The patient (53 years) suffers from pulmonary tuberculosis during 6 years. Two years ago the diagnosis was made: chronic case of PTB (2.09.11) of lungs (fibrous-cavernous one, phase of infiltration and dissemination), Destr.+, MTB+, M+, C+, Resist. I-, Resist. I 0, Hist.0, Cat.4, Coh.3 (2011).

Which chemotherapy regimen the patient needs?

Which pathogenic treatment and preventive measures for side effects of antituberculous drugs are the patient needs?

3. The patient (50 years) takes the course of chemotherapy at antituberculous department with the diagnosis of tuberculous meningitis which is confirmed by presence of MTB in cerebro-spinal fluid. Chemotherapy regimen: isoniazid +PAS (intravenously) + rifampicin + streptomycin (intramuscular) + pyrazinamide (per os) is performed.

Which chemotherapy regimen the patient needs?

Which drug is rational to be taken intralumbar during lumbar puncture?

4 level. Enumerate the contraindication for usage I line antituberculous drugs.

Student's subscription: _____

Module №5

Primary tuberculosis. Tuberculosis of non-established localization. Tuberculosis of intrathoracic lymphatic nodes. Primary tuberculous complex. Pathogenesis, path morphology, clinics, diagnostics, differential diagnostics, treatment, consequence.

1 level. Read the pages 69-79 A teaching manual in Ukrainian and English “Phthiology” I.T. Pyatnochka, 2002 or the pages 92-103 A textbook for students “Phthiology” V. I. Petrenko, 2008 and the pages 52-57 “Phthiology” Handbook for medical students with English medium for individual work O.S. Shevchenko with coauthors, 2011.

Give an answer in written form to the next question:

1.Enumerate characteristic signs of primary tuberculosis
2. Write the definition of tuberculosis of unknown primary localization.
3. What are paraspecific reactions, what are the clinical signs of them?
4.Diagnosis of the tuberculosis of unknown primary localization is based on the data:
5. What is the difference between early and late tuberculous intoxication?
6. What are the typical complains at the tuberculosis of unknown primary localization?
7. What diseases should one differentiate tuberculosis of unknown primary localization from?
8.Write the definition of intrathoracic lymph node tuberculosis
9. Enumerate the groups of intrathoracic lymph nodes according to the V.A. Sukelnikov's classification
10. What are the X-ray forms of intrathoracic lymph node tuberculosis?

11. What are the clinical symptoms of intrathoracic lymph node tuberculosis?
12. What complications intrathoracic lymph node tuberculosis may follow by?
13. What diseases should one differentiate intrathoracic lymph node tuberculosis from?
14. What is the primary tubercular complex?
15. What are the X-ray stages of the primary tubercular complex?
16. What is the Gohn focus?
17. What are the early and late complications of the primary tubercular complex?
18. What diseases are to be included into the differential diagnosis with the primary tuberculous complex?
19. What diagnostic tests should be done for a child or a teenager with pulmonary parenchyma infiltration and enlarged intrathoracic lymph nodes?
20. How is uncomplicated primary tubercular complex treated?

2 level. Solve the tests.

1. Choose the correct formulation of primary tuberculosis:

- first manifestation of tuberculous changes in lungs;
- disease of patient infected by mycobacterium tuberculosis of human type;
- disease of patient with positive reaction to Mantoux test;
- disease of the patient due to contact with tuberculous patients;
- new disease in adult, who had tuberculosis in the childhood.

2. Early sign of primary period of tuberculosis infection is:

- positive reaction to Mantoux test;
- tuberculous lesion of intrathoracic lymphatic nodes;
- hyperergic reaction to tuberculin;
- conversion of Mantoux test;
- increasing allergy to tuberculin.

3. Morphological changes are most typical for the primary tubercular complex as all listed, except for:
- exudative reactions;
 - productive reactions;
 - caseous necrosis in lungs;
 - caseous necrosis in lymph nodes of a root lungs.
4. Difference in a course of tuberculous process in its primary period from its course in secondary period consists:
- in a higher general sensibilization of organs and tissues to a tuberculosis infection;
 - in the greater predisposition to generalization of infectious process;
 - in more often occurrence of paraspecific reactions in tissues of different organs;
 - involvement of specific process in lymphatic nodes.
5. Negative tuberculin test in children of early age:
- allow to exclude primary infection;
 - is the proof of an inefficiency of BCG vaccination;
 - tuberculin testing is not the criteria for primary infection
 - allow to define clinical form of tuberculosis
6. The basic methods of revealing tuberculosis in children are:
- mass tuberculin test;
 - fluorography;
 - examination of the groups of children with high risk for tuberculosis;
 - examination of the persons who have referred to the phthisiologist.
7. A basic cause of transition of primary infection into tuberculosis is:
- massive super infection;
 - adverse premorbid conditions and frequent intercurrent diseases;
 - weakening of the post vaccination immunity;
 - . all above mentioned.
8. The tuberculosis of children at early age is mainly revealed by:
- method of tuberculin diagnostic;
 - during inspection on contact;
 - clinical symptoms of disease;
 - all above mentioned.
9. What is related to the criteria of «tuberculous intoxication» as agreed by the clinical classification of tuberculosis?
- syndrome of functional changes in the early period of primary tuberculosis infection;
 - preservation of intoxication syndrome after standard course of treatment with one drug;
 - absence of local forms of tuberculosis but with signs of the disease;
 - all above mentioned.
10. Erythema nodosum can be a symptom of all listed diseases, except:
- sarcoidosis; b. rheumatism;
 - typhoid fever; d. primary tuberculosis.
11. Composition of primary tuberculosis complex consists of:
- focus in lungs and tuberculosis of regional lymph nodes;
 - focus in lung, specific lymphangitis and tuberculosis of regional lymph nodes;
 - specific bronchitis, focus in lung and tuberculosis of regional lymph nodes.

12. The tuberculosis of mediastinum lymphatic nodes is most frequently complicated by:

- a. bronchial obstruction;
- b. lymphogenic dissemination;
- c. hematogenic dissemination;
- d. all variants are correct

13. Basic methods of revealing patients with tuberculosis of intrathoracic lymph nodes are:

- a. X-ray investigation; b. tuberculin test.
- c. clinical symptoms of disease; d. all variants are correct

14. What is most typical for uncomplicated primary complex:

- a. dry cough; b. moist cough; c. chest pains; d. syndrome of intoxication.

15. The uncomplicated TB primary complex is characterized by the following radiological signs:

- a. expansion and widening of lung root shadow;
- b. homogeneous section of opacity in the lung with indistinct contours;
- c. inflammatory path to a root;
- d. all variants are correct.

16. The primary tubercular complex is most often necessary to differentiate with:

- a. lung cancer with metastasis in lymph nodes of lungs;
- b. acute pneumonia;
- c. malformation of the lungs;
- d. eosinophilic infiltration.

17. With which lymphatic diseases can tuberculosis of intrathoracic lymph nodes be differentiated:

- a. nonspecific lymphadenitis;
- b. lymphogranulomatosis;
- c. sarcoidosis;
- d. all variants are correct

18. The child (4 years) took the chemotherapy in pediatrician antituberculous hospital because of the diagnosis: New case of TB (9.02.2011) of tracheo-bronchial lymph nodes (small form, phase of infiltration), Destr+, MTB-, M-, C-, Resist I (0), Resist II (0), Hist 0, Cat.3, Coh.1(2011). As a result of carried treatment 2 intensive shadows are present at the right lung hilum at the X-ray picture. Which clinical variant of intrathoracic lymph nodes TB is actual?

- a. "small" one; b. caseous one;
- d. tumor-like one; e. indurative one; c. infiltrative one.

19. The patient (10 years) was BCG-revaccinated at the age of 7 years old. At the age of 8 years old Mantoux test with 2 TU of PPD-L was 10 mm, 9 years – 8 mm, now (10 years) – 10 mm. Two months ago the child was in the contact with his grandfather suffers from "open case" of pulmonary tuberculosis. The child complains on the tiredness, malaise, weakness, his appetite is decreased. He becomes irritable. Physical findings: skin is pale and moist. Enlarged soft painless peripheral lymphatic nodes (3-5 mm) are palpable in the posterior cervical triangle region. Blood test: erythrocytes - $4,5 \times 10^{12}/l$, leucocytes - $9,2 \times 10^9/l$, stabs – 8%, ESR – 17 mm/hour. Chest X-ray picture: abnormality is absent. Which clinical form of TB the child suffers from?

- a. pulmonary nodular tuberculosis;
- b. TB of meninges and nervous system;
- c. tuberculosis of non-established localization;
- d. tuberculosis of intra thoracic lymph nodes (small form);

20. The child 12 years old. Mantoux test shows infiltrate with diameter 17 mm. At maternity house the child was BCG vaccinated, BCG sign is 3 mm. Blood test: leucocytes – $7,4 \cdot 10^9/l$, ESR - 15mm/hour. In 3 sputum smears MTB were not found microscopically. X-ray picture: there is shadowing 4 cm · 4 cm of slight intensity of the left lung and enlargement of the lung hilum due to enlargement of intrathoracic lymph nodes. The child is from the family contact with the patient suffers from pulmonary tuberculosis. Mantoux tests were negative all previous years.

Which clinical form of TB the child suffers from?

- a. pulmonary nodular tuberculosis;
- b. primary tuberculosis complex;
- c. tuberculosis of non-established localization;
- d. TB bronchitis;
- e. tuberculosis of intrathoracic lymph nodes (small form).

1. a b c d e	6. a b c d e	11. a b c d e	16. a b c d e
2. a b c d e	7. a b c d e	12. a b c d e	17. a b c d e
3. a b c d e	8. a b c d e	13. a b c d e	18. a b c d e
4. a b c d e	9. a b c d e	14. a b c d e	19. a b c d e
5. a b c d e	10. a b c d e	15. a b c d e	20. a b c d e

3 level. Solve the clinical situational tasks:

1. The child (5 years) complains on the weakness, malaise, subfebrile fever up to 37, 3-37,5°C periodically, irritability. Enlarged peripheral lymphatic nodes are palpable in the posterior cervical triangle region. Percussion and auscultation did not reveal any abnormality in lungs. Mantoux test result is 13 mm, last year – 8 mm. X-ray chest picture and medium tomogram – abnormality is absent. Blood test: leucocytes – $7,7 \times 10^9/l$, eosinophils – 3%, sticks – 6%, segments – 60%, lymphocytes – 21%, monocytes – 10%, ESR - 18 mm/hour.

Make the clinical diagnosis formulation accordingly to clinical classification?

Which chemotherapy regimen is needed for the child?

2. The child (13 years) complains on the weakness, subfebrile fever up to 37,3°C, decreased appetite, rapid fatigability, sweats loss of energy, mild cough. His father suffers from “open case” of tuberculosis. Mantoux test conversion is found with the papule of 14 mm in the diameter. Blood test: leucocytes – $10,9 \times 10^9/l$, ESR – 18 mm/hour. Physical findings failed to reveal pathology in lungs.

What diagnosis formulation is correct?

Which investigation is needed to confirm the diagnosis?

3. The child (7 years old) complains on dry cough, predominantly at night, sweetness, weakens, and heightened irritability. Objectively: phlyctenular conjunctivitis enlarged peripheral lymphatic nodes. Blood test: leukocytes $7,9 \times 10^9/l$, ESR 30 mm/h. Mantoux test with 2 TU of PPD-L – infiltrate 13

mm (at 6 years – 2 mm). On X-ray: right lung hilum is widened with unclear structure and with wavy contour, MTB(-)

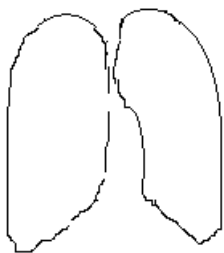
What diagnosis formulation accordingly to clinical classification is correct?
Prescribe chemotherapy regimen an intensive phase.

4 level.

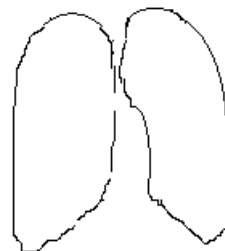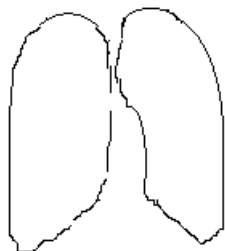
1. Make a scheme of differential diagnosis between primary tuberculosis complex and pneumonia.

2. Make a diagrammatic drawing of the X-ray shadows due to:

primary tuberculous complex



tuberculosis of intrathoracic lymphatic nodes



Infiltrative variant

Tumorous variant

Student's subscription: _____

Module № 6

Disseminative pulmonary tuberculosis. Miliary tuberculosis. Tuberculosis of nerves system and menings. Pathogenesis, path morphology, clinics, diagnostics, differential diagnostics, treatment, consequence. Examination of the patients.

1 level. Read the pages 80-84,127-130,158-163 A teaching manual in Ukrainian and English “Phthisiology” I.T. Pyatnochka, 2002 or the pages 104-116, 202-205, 196-200 A textbook for students “Phthisiology” V. I. Petrenko, 2008 and the pages 72-74 Handbook for medical students with English medium for individual work O.S. Shevchenko with coauthors, 2011.

Give an answer in written form to the next question:

1. What is disseminated tuberculosis?
2. What are the forms of disseminated tuberculosis?
3. What is miliary tuberculosis?
4. What are the clinical types of miliary tuberculosis?
5. What are the causes of miliary tuberculosis?
6. What conditions are necessary for miliary tuberculosis occurrence?
7. What are the characteristic symptoms of miliary tuberculosis?
8. What X-ray changes are characteristic for miliary tuberculosis?
9. What diseases should miliary tuberculosis be differentiated from?
10. What chemotherapy regimen is indicated for treatment of patients with miliary tuberculosis?

11. What clinical symptoms and signs on physical examination are characteristic for subacute disseminative pulmonary tuberculosis?
12. What are the outcomes of subacute disseminative pulmonary tuberculosis?
13. What are the X-ray features of subacute and chronic disseminated pulmonary tuberculosis?
14. What diseases are to be considered for differential diagnosis at disseminated pulmonary tuberculosis?
15. Prescribe the chemotherapy regimen at the intensive phase for person suffering from subacute and chronic disseminative pulmonary tuberculosis. What categories should be administered?
16. What is tuberculosis meningitis?
17. What are the forms of tuberculosis meningitis by localization?
18. What are the clinical periods of tuberculous meningitis?
19. What are the syndromes are characteristic for TB meningitis?
20. What symptoms are characteristic for meningeal syndrome?
21. What symptoms of increased tonic muscle construction are most often found at meningeal tuberculosis?
22. What cranial nerves are affected at meningeal tuberculosis?
23. Which changes of cerebrospinal fluid are characteristic for meningeal tuberculosis?

24. What diseases are to be considered for differential diagnosis at meningeal tuberculosis?

25. What are the main components of neurotuberculosis or meningeal tuberculosis complex treatment?

2 level. Solve the tests.

1. Miliary tuberculosis is characterized by:

- a. scanty mycobacterium expectoration;
- b. poor mycobacterium expectoration;
- c. absence of mycobacterium expectoration;
- d. periodic mycobacterium expectoration.

2. Tuberculin test results in the patient with miliary tuberculosis at the beginning of the disease:

- a. positive;
- b. hyperergic;
- c. misinterpreted;
- d. hypoergic;
- e. negative.

3. First manifestations of acute hematogenic disseminated (miliary) tuberculosis are all listed, except for:

- a. body temperature rising;
- b. insignificant usual dry coughs;
- c. strong coughs with poor sputum;
- d. manifestations of dyspnea and tachycardia.

4. For meningeal tuberculosis characteristic pleocytosis:

- a. more than 5.000 cells in 1 mm^3 liquor;
- b. 2000-5000 cells;
- c. 200-400 cells;
- d. 5-10 cells.

5. At tuberculosis meningitis the level of glucose and chlorides in the lumbar liquor:

- a. increased;
- b. increased only level of glucose;
- c. unchanged;
- d. decreased

6. Cerebrospinal fluid may have xanthochroid character:

- a. at purulent meningitis;
- b. at serous meningitis
- c. at tuberculous meningitis;
- d. in the norm

7. Which changes of cerebrospinal fluid more characteristic for meningeal tuberculosis?

- a. increasing of protein, chloride, glucose amount;

- b. higher cytolysis (more than 1000 cells), neutrophilic character, moderate increasing amount of protein, liquid is cloudy;
- c. insignificant increasing amount of protein, moderate lymphocytic cytolysis, glucose and chlorides in norm;
- d. higher rate of protein amount, moderate cytolysis (200–400 cells and more), predominantly lymphocytic, decrease of glucose and chlorides)

8. Choose the correct formulation of disseminated tuberculosis of respiratory organs:

- a. bilateral extensive opacity in the lungs;
- b. total unilateral focal damage of the lungs;
- c. bilateral limited or widespread damage of the lungs with prevalence of foci and interstitial changes;
- d. unilateral focal damage of lobe of lung;
- e. cavernous damage of the superior lobe of one lung with focal dissemination of inferior part of both lungs.

9. To manifestation signs of acute hematogenic-disseminated (miliary) tuberculosis of lungs belongs all of listened below, except for:

- a. rising body temperature till hectic level;
- b. insignificant, usually dry cough;
- c. intense cough with scanty sputum;
- d. occurrence of dyspnea and tachycardia

10. Clinical signs, which allow to suspect acute miliary tuberculosis at the patient are:

- a. fever, breathlessness, intense cough, scattered dry rales in the lungs;
- b. fever, constant intensify breathlessness in the time of physical symptoms absence, tachycardia;
- c. fever, cough with sputum, scattered dry and local moist rales in the lungs.

11. The decay at subacute hematogenic-disseminated tuberculosis of lungs is characterized all listened, except for:

- a. curve inner contours;
- b. symmetrically located decays in both lungs;
- c. stamp-like their walls.

12. The outcome of subacute hematogenic-disseminated pulmonary tuberculosis in case of favourable dynamic more often are:

- a. complete resorption;
- b. induration;
- c. calcinations;
- d. formation of fibrous-sclerous changes
- e. correct answers are b) and d)

13. The exacerbation of chronic hematogenic-disseminated pulmonary tuberculosis is characterize:

- a. appearance of new nidus;
- b. development of perifocal inflammation changes;
- c. appearance of decay in the lungs;
- d. throat lesions and large bronchus;
- e. by all mentioned above.

14. The lesions of lungs at lymphogenic-disseminated tuberculosis are characterize by all listened, except for:

- a. symmetry; b. asymmetry;
- c. limitation; d. prevalence

1. a b c d e	6. a b c d e	11. a b c d e
2. a b c d e	7. a b c d e	12. a b c d e
3. a b c d e	8. a b c d e	13. a b c d e
4. a b c d e	9. a b c d e	14. a b c d e
5. a b c d e	10. a b c d e	

3 level. Solve the clinical situational tasks:

1. Patient of 19 years old was admitted at the infectious hospital with diagnosis typhoid fever. He is ill during 2 weeks. 2 days ago was emerged sharp worsening of general state – body temperature was rising till 39,8°C, strong headache, nausea, fountain-like vomiting, which does not improve general condition. Objectively: severe patient's state, lies on “trigger” posture, express occipital muscle rigidity, positive Kernig's and Brudzinski symptoms. Vesicular breathing in the lungs is heard. X-ray is without pathology. Analysis of blood: leukocytes $10,5 \cdot 10^9/l$, ISR 40 mm/hour. Liquor analysis: transparent with opalescence, cytolysis 300 cells/mm³, glucose 1,8 mmol/l, in 12 hours thin fibrin film was deposit where MTB are found by bacterioscopy.

Formulate the diagnosis according to functional classification

Prescribe the treatment

2. The woman of 25 years old becomes ill acutely. The body temperature rising up to 39,0°-39,5°C, appeared sharp weakness, breathlessness, dry cough. Objectively is without pathology. Multiply small nodular shadows, small intensity with unclear contours, without tendency to fusion on background of washed lung pattern throughout the both lungs was revealed by X-ray.

Which clinical form of TB is detected at the woman?

Which category of the treatment this case is related to?

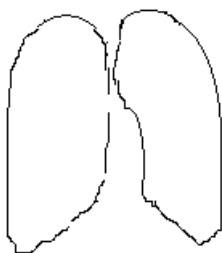
Prescribe the patient's treatment in intensive phase.

3. Man of 26 years old suffers on pain in the thorax left side, breathlessness, which intensified. He was in contact with TB patient. Dullness on percussion was heard in the left lung from 4-th rib till diaphragm, on auscultation breathing is absent. Homogenous shadows with clear upper contours in the left lung on X-ray was revealed. Few intensive nodular shadows were revealed in the left lung 2-nd segment. Pleural exudates: specific density - 1020, serous, slight opalescent, protein 50 g/l, lymphocytes - 80%, Rivalt's test - positive.

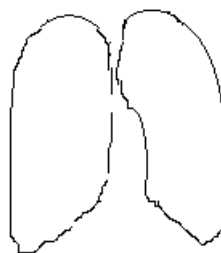
Which signs illustrate exudative pleurisy presence of tuberculous etiology?

4 level Make the scheme of differentiation between the typhoid type of miliary tuberculosis and typhoid fever?

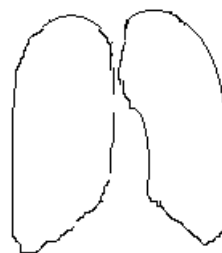
Make a diagrammatic drawing of the X-ray shadows due to:



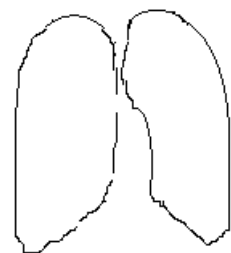
Miliary TB



Acute disseminated



Subacute disseminated TB



Chronic disseminated

Student's subscription: _____

Module № 7

Secondary tuberculosis. Focal and infiltrative pulmonary tuberculosis. Caseous pneumonia. Tuberculoma of the lung. Pathogenesis, path morphology, clinics, diagnostics, differential diagnostics, treatment, consequence.

1 level. Read the pages 87-104,137-155 A teaching manual in Ukrainian and English “Phthisiology” I.T. Pyatnochka, 2002 or the pages 116-157, 159-173 A textbook for students “Phthisiology” V. I. Petrenko, 2008 and the pages 60-62, 65- 67 “Phthisiology” Handbook for medical students with English medium for individual work O.S. Shevchenko with coauthors, 2011.

Give an answer in written form to the next question:

1. What is nodular tuberculosis?

2. What are the clinical and radiological types of nodular tuberculosis?

3. In what segments does nodular tuberculosis localize typically?
4. What diseases should nodular tuberculosis must be differentiated with?
5. What are the possible outcomes of nodular pulmonary tuberculosis treatment?
6. Give the definition of pulmonary infiltrative tuberculosis?
7. Enumerate the X-ray variants of tuberculous infiltrates.
8. What are the “masks” of pulmonary infiltrative tuberculosis?
9. What are the outcomes of pulmonary infiltrative tuberculosis?
10. What diseases pulmonary infiltrative tuberculosis must be differentiated from?
11. Give the definition of caseous pneumonia.
12. What forms of tuberculosis are previous ones for caseous pneumonia?
13. What are the typical X-ray and clinical signs of caseous pneumonia?
14. What diseases should one differentiate caseous pneumonia from?

15. What is the treatment of caseous pneumonia?
16. What are the favorable and unfavorable outcomes of caseous pneumonia?
17. Give the definition of pulmonary tuberculoma.
18. What are the clinical and x-ray signs of tuberculoma?
19. What diseases one should differentiate tuberculoma from?
20. What are pulmonary tuberculoma outcomes?

2 level. Solve the tests.

1. In which segments of lungs focal tuberculosis is located:

- a. 3, 4, 5, 6; b. 1, 2, 6; c. 1, 2; d. 6; e. 8, 9.

2. The basic method of nodular pulmonary tuberculosis finding in adults is:

- a. prophylactic fluorography;
b. diagnostic fluorography;
c. tuberculin diagnosis;
d. the microbiological examination for mycobacterium expectoration;
e. radiography.

3. Infiltrative pulmonary tuberculosis is necessary to differentiate with all listed diseases, except for:

- a. pneumonia;
b. lung cancer;
c. sarcoidosis;
d. eosinophylic pneumonia;
e. atelectasis.

4. What is the most reliable radiological sign indicating cavity in lung of tubercular genesis:

- a. presence of the horizontal level of liquid;
b. thickening of the draining bronchus wall;
c. foci of bronchogenic dissemination;
d. presence of sequestration;
e. localization of a cavity in the upper lobe.

5. The most reliable method for diagnosis of destructive pulmonary tuberculosis is:

- a. fluorography;
 - b. X-ray;
 - c. tomography;
 - d. ultrasonic sound;
 - e. radioisotope imaging.
6. The probable reason of disease relapse at the patients suffering from nodular tuberculosis are:
- a. character of pulmonary residual changes;
 - b. inadequate character of chemotherapy basic course;
 - c. mycobacterium tuberculosis drug resistance;
 - d. presence of concomitant disease;
 - e. all listened above.
7. Predominance of exudative inflammation process at infiltrative tuberculosis with caseous necrosis and frequent cavitation occur:
- a. due to body hyperergic reaction against mycobacterium tuberculosis;
 - b. due to pulmonary tissues hypersensibilization on mycobacterium tuberculosis antigens;
 - c. due to massive infectious multiplication in the lesion focus;
 - d. concomitant disease.
8. The classification of TB infiltrate variants is based on:
- a. bronchus lesion;
 - b. specific inflammation degree of manifestation and his spreading;
 - c. presence of atelectasis changes;
 - d. volume of lungs lesion;
 - e. symptoms of disease manifestation
9. Which pathology tuberculous lobular infiltrate must be differentiated from?
- a. nodular pneumonia;
 - b. benign tumor;
 - c. retention cyst;
 - d. echinococcus;
10. Which pathology tuberculous round infiltrate must be differentiated from?
- a. with pneumonia;
 - b. with lung cancer;
 - c. with benign tumor;
 - d. all above mentioned.
11. The cloud-like infiltrate is characterized by:
- a. clinical signs of pneumonia;
 - b. clinical symptoms of bronchitis;
 - c. absence of clinical symptoms;
 - d. pain on lesion side;
12. The consequence of TB cloud-like infiltrate effective treatment:
- a. area of pneumosclerosis;
 - b. area of pneumosclerosis with lesions;
 - c. segmental cirrhosis;
 - d. all listened;

13. Which pathology one should differentiate tuberculous lobitis from?
- lobar pneumonia
 - lung cancer;
 - eosiniphilic pneumonia;
 - all listened above
14. The main morphological distinction caseous pneumonia from infiltrative tuberculosis is:
- large volume of lesion;
 - predominance of caseous necrosis;
 - more often cavitation;
 - inclination to bronchogenic dissemination.
15. An outcome caseous pneumonia effective treatment is:
- area of pneumosclerosis;
 - pneumosclerosis with nidus;
 - multiple tuberculoma;
 - cirrhotic and fibrous-cavernous tuberculosis.
16. The cavitation formation with tuberculoma can be:
- central;
 - peripheral;
 - marginal;
 - any variants listened above.
17. Which disease one should differentiate tuberculoma from?
- peripheral cancer;
 - aspergillums;
 - with retention cyst;
 - all answers are correct.
18. The radiological changes listened below have no diagnostic value for differentiation between tuberculoma and peripheral cancer, except for:
- calcified focus and petrified nidus;
 - fibrosis;
 - polymorphic lesions;
 - all answers are correct.
19. For diagnosis verification of round shadow located in deep lung segments sufficiently to apply:
- trans thoracic needle lung biopsy;
 - trans thoracic pinching biopsy;
 - bronchoscopy with catheter-biopsy;
 - mediastinum-scopy with biopsy.
20. The main indication for tuberculoma surgical treatment is:
- torpid tuberculoma duration of middle and large size; concomitant disease which enhance exacerbation disease risk & necessity in accelerated patient's labour rehabilitation;
 - presents of multiple tuberculoma in one lung lobe;
 - progressive disease duration, delayed regression rates during chemotherapy and impossibility to conducting valuable chemotherapy;
 - all answers are correct.

1. a b c d e	6. a b c d e	11. a b c d e	16. a b c d e
2. a b c d e	7. a b c d e	12. a b c d e	17. a b c d e
3. a b c d e	8. a b c d e	13. a b c d e	18. a b c d e
4. a b c d e	9. a b c d e	14. a b c d e	19. a b c d e
5. a b c d e	10. a b c d e	15. a b c d e	20. a b c d e

3 level. Solve the clinical situational tasks:

1. Solitary, small intensity nodular shadows with unclear contours, middle size at the apical segments of both lungs were found in patients of 20 years old by fluorography. Compliances are absent. Objectively: without pathology. Blood analysis is normal. It was established diagnosis: pulmonary tuberculosis.

Which clinical form of pulmonary tuberculosis was found in the patient?

Prescribe the patient's treatment in the intensive phase

2. Patient of 34 years old fell ill acutely. Body temperature is rising up to 39° C, appear cough with mucous sputum up to 50 ml/day. Contact with TB patients isn't ascertaining. He has diabetes mellitus. Under whole upper lobe of right lung is revealing dullness of percussion sound, weakness of vesicular breathing with single moist rales. On X-ray: non-homogenous shadowing with partial translucency in upper lobe of right lung. MTB are found in the sputum.

Which type of TB infiltrate is found in the patient?

Formulate the diagnosis according to active classification.

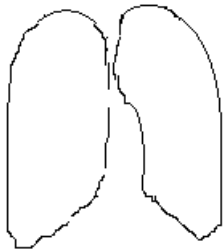
3. The patient C. (46 years old) suffers from tuberculosis during 5 years. He has compliance on cough with sputum, hemoptysis. Objectively: low body weight, amphoric breath sound under portion of right lung S₁₋₂ projection is heard on auscultation. At the right lung S₁₋₂ deforming cavitation with thick walls on background of fibrosis changes was revealed. Nodular shadowing different size and intensity at the middle and lower portion located. MTB are found in the sputum by bacterioscopy investigation.

Which clinical form of pulmonary tuberculosis it was revealed at the patient?

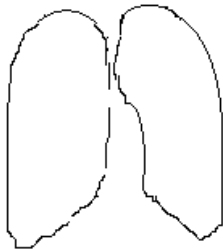
To which treatment category this case is related?

4 level. 1. Make a scheme of differential diagnosis between infiltrative tuberculosis, pneumonia and peripheral cancer.

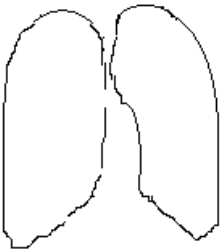
2. Make a diagrammatic drawing of the X-ray shadows due to:



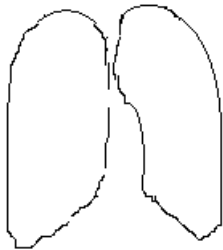
Nodular TB



Infiltrative TB



Tuberculoma



Caseous pneumonia

Student's subscription: _____

Module № 8

Fibrous-cavernous tuberculosis and cirrhotic tuberculosis of the lungs.

Pathogenesis, clinics, diagnostics, treatment.

Complications of tuberculosis: hemoptysis, lung hemorrhage, spontaneous pneumothorax, chronic cor pulmonale, amyloidosis of internal organs.

Tuberculous pleurisy and empyema. Pathogenesis, pathomorphology, clinics, diagnostics, differential diagnostics, treatment, consequence.

1 level. Read the pages 106-120, 137-157 A teaching manual in Ukrainian and English “Phthysiology” I.T. Pyatnochka, 2002 or the pages 142-156; 159-173 A textbook for students “Phthysiology” V. I. Petrenko, 2008 and the pages 62, 66-67, 81-85 Handbook for medical students with English medium for individual work O.S. Shevchenko with coauthors.

Give an answer in written form to the next question:

1. Give the fibro-cavernous form of pulmonary tuberculosis definition.
2. What forms of tuberculosis precede the fibro-cavernous one?
3. What radiological signs are characteristic for fibro-cavernous tuberculosis?
4. What course can fibro-cavernous tuberculosis take?
5. What percussive and auscultative phenomena can be found in a patient with fibro-cavernous pulmonary tuberculosis?
6. What are fibro-cavernous tuberculosis outcomes?
7. With what disease should one differentiate fibro-cavernous tuberculosis?

8. What is cirrhotic tuberculosis?
9. What are the X-ray signs of cirrhotic pulmonary tuberculosis?
10. What indicators of cirrhotic tuberculosis activity do you know?
11. What kinds of cirrhotic tuberculosis are defined according to their genesis?
12. What are the chief complaints of patient with cirrhotic pulmonary tuberculosis?
13. What is the difference between cirrhotic tuberculosis and post tuberculous cirrhosis?
14. What are the characteristic signs of cirrhotic tuberculosis on physical examination?
15. What disease should one differentiate cirrhotic tuberculosis from?
16. What is the peculiarity of chronic tuberculosis treatment?
17. Give the definition to “pulmonary hemorrhage, hemoptysis”.
18. What is the pathogenesis and factors promoting hemoptysis and pulmonary hemorrhage?

19. What is the classification of hemorrhage according to their intensity?
20. What are the symptoms of hemoptysis and pulmonary hemorrhage?
21. What is haemostatic therapy aimed at?
22. What is spontaneous pneumothorax? What are the types of pneumothorax?
23. What are the clinical signs of spontaneous pneumothorax?
24. What are the causing factors of spontaneous pneumothorax at pulmonary tuberculosis?
25. What are the X-ray signs of spontaneous pneumothorax?
26. What is the pathogenesis of tuberculous pleurisy?
27. What is pleurisy classification depending on the character of exudate?
28. Enumerate the clinical and radiological signs of tuberculous pleurisy.
29. What are the outcomes of exudative pleurisy?

30. What is the congestive heart failure?
31. What is the classification of congestive heart failure depending on the time of development?
32. Enumerate the functional and anatomical factors of chronic congestive heart failure formation?
33. What are the types of congestive heart failure and their clinical symptoms?
34. What are the electrocardiographic signs of chronic congestive heart failure?
35. What is the etiology of amyloidosis? What is the manifestation the 1 st stage of amyloidosis?

2 level. Solve the tests:

1. Which form of pulmonary tuberculosis morphologically corresponds with thick wall cavity and nodular, infiltrative and fibrotic changes around it?

- a. chronic disseminated tuberculosis;
- b. fibrous-nodular tuberculosis;
- c. infiltrative tuberculosis;
- d. fibrous-cavernous tuberculosis;
- e. cirrhotic tuberculosis.

2. Which X-ray sign doesn't confirm the presence of cavitation?

- a. ring shadow;
- b. horizontal level of liquid in the ring shadow;
- c. bronchial dissemination;
- d. enlargement of pathological shadow size on the lesion side;
- e. all listened are correct.

3. What are the causes of pulmonary fibrous-cavernous tuberculosis formation?

- a. late tuberculosis revealing;
- b. inadequate treatment;
- c. lesion of drain bronchus;
- d. all above mentioned are correct;
- e. all above listened are wrong.

4. Which forms of pulmonary tuberculosis transform into fibro-cavernous tuberculosis more often?
- primary tuberculosis complex, tuberculosis of intrathoracic lymphatic nodes;
 - fresh nodular, fibrous-nodular tuberculosis;
 - infiltrative, disseminative tuberculosis;
 - tuberculoma, miliary tuberculosis;
 - pleurisy, cirrhotic tuberculosis.
5. What character of sputum occurs more often in patient with pulmonary fibrous-cavernous tuberculosis?
- glassy;
 - mucous;
 - viscid;
 - purulent;
 - mucous-purulent.
6. Which morphological changes are not characteristic for patients with cirrhotic pulmonary tuberculosis?
- rough deform sclerosis;
 - bronchiectatic decay;
 - emphysematous bulla;
 - cavitation with sign of progression.
7. Effective medicinal means of struggle with hemoptysis are:
- intravenous introduction 10% of a solutions calcium chloride 5-10 ml;
 - the cooled alkaline solutions per os and means of struggle with cough;
 - intra muscular etamsylatum (dicinon), intra vein, vitamin C, vicasol;
 - impose right on extremities and subcutaneous introduction of oxygen
8. The basic reason of lung blood expectoration at the tuberculosis patients is:
- the damage of vessel wal;
 - disturbance in blood coagulation;
 - disturbance in anticoagulation with blood system;
 - congestion phenomena in a small circle blood circulation;
 - defects of blood vessels development.
9. The main cause of pulmonary hemorrhage occurrence at “fresh forms“ of tuberculosis:
- formation of caseous necrosis in lung parenchyma;
 - occurrence of disintegration of lung tissue;
 - destruction of pulmonary arteries or veins wall;
 - destruction of the bronchial artery or veins wall.
10. Pulmonary hemorrhage is observed:
- at fresh, sharply proceeding forms of lesions of lungs;
 - with acute and subacute disease, with disintegration of lung tissue;
 - with chronic disease, accompanying by the cirrhosis formation in the lung tissue.
11. A principal cause of death of patients with pulmonary hemorrhage is:
- sharp pneumonia;
 - hemorrhagic shock;
 - asphyxia.

12. The basic clinical symptoms of spontaneous pneumothorax:
- fever, cough with sputum;
 - chest pains and dyspnea;
 - fever, dry hoarse cough, chest pains;
 - chest pains hard breathing, cough with sputum.
13. Spontaneous pneumothorax is the most often complication of:
- bullous dystrophies of lungs;
 - tuberculosis of lungs;
 - abscesses of lungs;
 - tumors of lungs.
14. What is the cause of more probable pleural effusion protracted preservation at adolescent?
- pneumonia;
 - pulmonary tuberculosis;
 - malignant lung tumor;
 - cardio-vascular disease;
 - mesotelioma;
15. With which form of pulmonary tuberculosis exudative pleurisy occurred rarely?
- primary tuberculosis complex;
 - subacute disseminated tuberculosis;
 - chronic disseminated tuberculosis;
 - tuberculosis of intrathoracic lymphatic nodes;
 - nodular tuberculosis.
16. Which factor has more value in tuberculous pleurisy development?
- specific sensibilization of pleura;
 - hematogenic spreading of MTB;
 - perifocal inflammation around of subpleural tuberculous lesion;
 - localization of tuberculous inflammation in upper-posterior portions of lungs;
 - immune suppression.
17. Which factor has the least value in tuberculous empyema development?
- cavitation rapture into pleural cavity
 - formation of residual post resection pleural cavity;
 - large residual changes after primary tuberculosis;
 - multiple pleural punctures with exudative pleurisy.
18. Which method more informative for introduce clarity into pleurisy etiology?
- bronchoscopy with biopsy;
 - radionuclide diagnostic;
 - computer tomography;
 - thoracoscopy with pleura;
 - ultrasound investigation.
19. At which form of pulmonary tuberculosis formatted empyema of pleura more often?
- primary tuberculous complex;
 - disseminated tuberculosis;
 - nodular tuberculosis;
 - tuberculoma;

e. fibrous-cavernous tuberculosis.

20. Which cells are predominated in exudate at tuberculous serous pleurisy?

- a. eosinophils;
- b. neutrophils;
- c. lymphocytes;
- d. monocytes;
- e. mesothelium cells

21. For what disease is typical pleurisy with predominance of neutrophils in serous exudate?

- a. tuberculosis;
- b. pneumonia;
- c. lung cancer;
- d. Hodgkin disease;
- e. sarcoidosis.

22. Which character of exudate more typical for tuberculous pleurisy?

- a. serous;
- b. purulent;
- c. hemorrhagic;
- d. cholesterol;
- e. lacteal.

23. Which clinical symptom is absent at dry pleurisy?

- a. pain at the thorax cage;
- b. restriction of thorax cage movement;
- c. pleural friction rub;
- d. dullness of percussive note;
- e. pain irradiation.

24. Which X-ray symptom is absent at exudative pleurisy?

- a. oblique upper shadowing border;
- b. darkening shape changes at deep patient's breath;
- c. darkening shape changes at alteration of patient's position;
- d. shifting of mediastinum shadowing into health side;
- e. lung pattern on background of shadowing.

25. Which cells absent in exudate at tuberculous pleurisy?

- a. neutrophils;
- b. lymphocytes;
- c. epithelioid cells;
- d. eosinophils;
- e. mesothelium cells.

26. Which method more informative at trace liquid in pleural cavity?

- a. percussion;
- b. X-ray;
- c. pleural cavity puncture;
- d. ultrasound investigation;
- e. computer tomography.

27. About what the nature of have arisen pleurisy is portions of pleura calcification testify?

- a. para pneumonic;
- b. sarcoidosis;
- c. allergic;
- d. rheumatic fever;
- e. tuberculous

28. Which method of investigation better revealed interlobar pleurisy?

- a. ultrasound investigation;
- b. direct X-ray;
- c. pleural puncture;
- d. lateral X-ray;
- e. direct tomography.

29. What is the cause of effusion in pleural cavity at elderly age more probable?

- a. pneumonia;
- b. pulmonary tuberculosis;
- c. malignant lung tumor;
- d. tuberculous of intrathoracic lymphatic nodes;
- e. sarcoidosis.

1. a b c d e	6. a b c d e	11. a b c d e	16. a b c d e	21. a b c d e	26. a b c d e
2. a b c d e	7. a b c d e	12. a b c d e	17. a b c d e	22. a b c d e	27. a b c d e
3. a b c d e	8. a b c d e	13. a b c d e	18. a b c d e	23. a b c d e	28. a b c d e
4. a b c d e	9. a b c d e	14. a b c d e	19. a b c d e	24. a b c d e	29. a b c d e
5. a b c d e	10. a b c d e	15. a b c d e	20. a b c d e	25. a b c d e	

3 level. Solve the clinical situational tasks:

1. The patient of 40 years old suffers from fibro-cavernous tuberculosis of right lung for 10 years with periodical bacilli excretion. He complains on dyspnea, weakness, sweating, subfebrile temperature, but exclude hospitalization. In the evening at the patient started pulmonary hemorrhage, blood loss 300 ml.

What is the management of this case?

What is the urgent aid?

2. The patient N., of 54 years old suffers from pulmonary disseminated tuberculosis in the phase of destruction, MTB+. In the morning after coughing acute pain in the thorax right side and dyspnea appear. The patient is admitted at the hospital. Objectively: skin is pale, pulse 110 bit/min. Tympanic sound is revealed over the thorax right side, breathing is not conducted. Right lung is collapsed on 1/3 of his own volume, organs of mediastinum are shifted to the left.

Define the diagnosis.

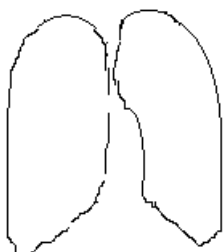
Which urgent aid is necessary to provide for the patient?

3. A patient of 44 years old suffers from cirrhotic pulmonary tuberculosis, МБТ+. The process exacerbation is appeared periodically. General state is of moderate severity. He is annoyed with dyspnea at slight physical loading. Objectively: tachycardia, accent of II tone under pulmonary artery, enlarged and painful liver, lower extremities puffiness at the evening, oliguria, nicturia. Signs of overloading of right atrium and ventricle on ECG ($P_{II-III} = 2,5 \text{ mm}$, $R/S > 1 \text{ в } V_1$).

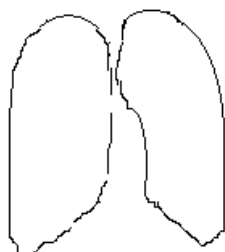
Which complication of tuberculosis takes please in the person?

Prescribe the treatment concerning to complication.

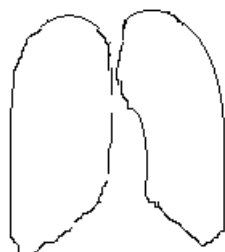
- 4 level.** 1. Make a diagrammatic drawing of the X-ray shadows due to:



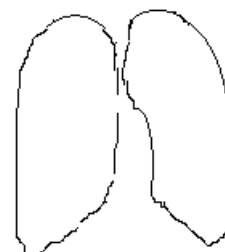
Fibro-cavernous TB



Cirrhotic TB



TB pleurisy



Spontaneous pneumothorax

2. Make up the scheme of patient's treatment with pulmonary tuberculosis, complicated by compensated and decompensated congestive heart failure?

3. Draw the scheme of differential diagnosis between pleurisy of different etiology (tuberculous, tumorous, and bacterial).

Student's subscription: _____

Module № 9

Pulmonary tuberculosis and occupational diseases. Tuberculosis in HIV/AIDS patients. Clinical picture. Diagnostics. Clinical features and treatment.

1 level. Read the pages 123-127; 179-195 A teaching manual in Ukrainian and English “Phthysiology” I.T. Pyatnochka, 2002 or the pages 157-158; 182-183 A textbook for students “Phthysiology” V. I. Petrenko, 2008 and the pages 90-95 “Phthysiology” Handbook for medical students with English medium for individual work O.S. Shevchenko with coauthors.

Give an answer in written form to the next question:

1. What is pneumoconiosis?
2. What types of pneumoconiosis according to etiology do you know?
3. What complication develops most often in patients with pneumoconiosis?
4. What is silicosis?

5. List X-ray characteristics for silicosis stages (I-st, II-nd, III-rd)
6. What is coniotuberculosis?
7. Which causes promote the occurrence of tuberculosis in patient with silicosis?
8. Which factors are responsible for tuberculosis formation with silicosis?
9. What is the pathogenesis of tuberculosis with silicosis?
10. What patient's laboratory investigation data suggests tuberculosis as a complication of silicosis?
11. What clinical signs suggest the silicosis infection at patients with tuberculosis?
12. What is the clinical form of silicotuberculosis?
13. What are the clinical signs of silicotuberculosis?
14. What are the X-ray signs of silicotuberculosis?
15. What are the principals of silicotuberculosis patients' treatment?

16. Give the definition of HIV-infection, enumerate its stages.
16. Give the definition of AIDS.
17. List the clinical features suspicious for HIV-infection in patients with tuberculosis.
18. What are the peculiarities of clinical course of early and late HIV/AIDS- associated tuberculosis?
19. What are the diagnostics criteria for HIV/AIDS- associated tuberculosis?
20. What are the X-ray signs of HIV/AIDS-associated tuberculosis?
21. Describe the treatment measures for patients with HIV-associated tuberculosis.

2 level. Solve the tests.

1. What are the most typical symptoms of silicosis accompanied by tuberculosis in the patient of 46 years old?

- a. absence of symptoms;
- b. only dry cough;
- c. pain in the chest;
- d. hemoptysis;
- e. weakness, rapid fatigability, sweating, stable subfebrile body temperature, the focuses on lungs apices.

2. At the patient of 57 years old is revealed with expressed conglomerate pneumofibrosis. What is the pneumoconiosis stage number?

- a. 1;
- b. 2;
- c. 3;
- d. 4;
- e. 5

3. In the patient of 56 years old, recently worked on mine for 30 years, revealed focal changes in the hilus regions, however, fluorography examination displayed nidi on apices of lungs. Patient's condition is quite satisfactory. Which disease should be speculated upon?

- a. disseminated pulmonary tuberculosis;
- b. silicotuberculosis;
- c. silicosis;
- d. carcinomatosis;

4. The patient of 40 years old suffers from silicosis I stage. What is the percent of joining tuberculosis to the process?

- a. In 20-30%;
- b. In 20-60%;
- c. In 60-80%;
- d. In 80-100%.

5. The patient M., (52 years old) suffers from silicosis during a long time contacts with open case of pulmonary tuberculosis. What is the most likely genesis of pulmonary tuberculosis with silicosis?

- a. endogenous variant of residual changes;
- b. dissemination from intrathoracic lymph nodes;
- c. result of exogenous super infection;
- d. from extrapulmonary foci.

6. Stabbing pain in left side of thorax cage, breathlessness on physical loading, rarely dry cough at patient of 39 years old are marked. He is loader, but has been worked on sandblaster during 3 years. Patient excludes the contact with tuberculosis patients. The body temperature, appetite and sleep are normal. The blood analysis: erythrocytes $4.7 \cdot 10^{12} / l$, leucocytes $5.3 \cdot 10^9 / l$, lymphocytes 19.0 %, monocytes 4.0 %, ESR 10mm/h. On auscultation: rough breathing, on percussion: pulmonary sound. Scattered small nodular shadowing with quite distinct contours, predominantly located near root on background of deformed and enriched lung pattern are marked on X-ray. The sinuses are free. MTB in bronchial lavage water are not revealed. On cytological examination atypical cells are absent. Mantoux test with 2 TU – papule 5 mm. Which disease in the patient is the most probable?

- a. disseminated pulmonary tuberculosis;
- b. sarcoidosis;
- c. bilateral nodular pneumonia;
- d. silicosis;
- e. carcinomatosis.

7. At the patient S., of 48 years old, carpenter, compliance on cough with excretion of scanty amount of sputum, breathlessness at walking, decreased appetite, disposition to sweating. He has been worked by miner during 6 years. Gradually strengthening of breathlessness during 5 years, periodically dry cough are marked. He was undergone surgical operation (resection of peripheral lymph nodes due to tuberculosis lesions) several years ago. The body temperature is normal. Weakened vesicular breathing, scattered dry rales in both lungs, in right interscapular space after tussiculation small moist bubbling rales are revealed on auscultation. Patient is not smoker, excludes the contact with tuberculosis patients. MTB in sputum are not revealed. Mantoux test with 2 TU – papule 15 mm. Sharply marked pneumosclerosis with multiple small nodular shadows of middle intensity in both lungs, which formatted spread conglomerates. Root unstructured with multiple lymphatic nodes like “eggshell” unevenly calcified. The heart shadowing unchanged. The blood analysis is normal.

Which disease in the patient is the most probable?

- a. disseminated pulmonary tuberculosis;
- b. silicotuberculosis;

- c. silicosis;
- d. sarcoidosis.

8. A patient of 47 years old suffers from destructive pulmonary tuberculosis and AIDS. What is the duration of the basic course of treatment in the patient with combination of this diseases?

- a. 3 month;
- b. 6 month;
- c. 9 month;
- d. non less then 12 month.

9. With HIV infected patients mycobacterium tuberculosis:

- a. practically are not revealed;
- b. are revealed only as L-forms;
- c. are revealed only as BCG strain;
- d. completely are displaced by non tuberculosis mycobacterium;
- e. are found out frequently, alongside with others mycobacterium.

10. Mortality from tuberculosis among HIV infected patients, in comparison with HIV not infected is:

- a. higher;
- b. lower;
- c. not different.

11. HIV infection increases the risk of side effects occurrence with anti-tuberculosis drugs:

- a. yes;
- b. no.

12. What are the laboratory criteria for HIV/AIDS-associated tuberculosis diagnostics?

- a. Typical blood indices;
- b. Quantitative indices of T-helpers;
- c. Changes of relations CD₄/CD₈ coefficient;
- d. Disturbance of natural immunity;
- e. Atypical indices for this disease

1. a b c d e	5. a b c d e	9. a b c d e
2. a b c d e	6. a b c d e	10. a b c d e
3. a b c d e	7. a b c d e	11. a b c d e
4. a b c d e	8. a b c d e	12. a b c d e

3 level. Solve the clinical situational tasks.

1. The patient D., of 59 years old visited the physician with complaints on worsening of his own condition, increase of cough, rising of body temperature up to 38⁰ C. He has professional route on the mine during over then 20 years. He is situated on dispensary follow-up with diagnosis silicosis II stage. At the X-ray examination the appearance of nodular shadowing different size and intensity in upper parts of both lungs, in some areas confluence character, are revealed. MTB are found in sputum analysis.

Formulate the diagnosis according to active classification.

Define the compulsory and additional methods of investigation.

Make the plan of treatment.

2. The patient A., of 30 years old suffers from HIV/AIDS during 5 years. In recent time he feels worse: rising body temperature, cough, sputum with blood admixtures, pain in the chest are appeared. The focus shadowing with unclear contours and area of translucency in S₆ of right lung is revealed. MTB are found in sputum by microscopy.

Formulate the diagnosis according to active classification.

Make up the plan of the patient's examination.

Make the plan of treatment.

3. The homogenous shadow in diameter 3.0· 2.0 cm with unclear contours? Translucency in the centre and “path” to the hilum is revealed in S₁₋₂ of right lung in patient of 30 years old by fluorography. The diagnosis is made: NTB (29.01.2011) of S₁₋₂ of right lung (infiltrative), Destr+, MTB-,M-,C-Hist (0), Cat 3, Coh 1(2011).

Is the disease was found in time?

4 level. 1. Make the plane of patient examination for estimation combined pathology: pulmonary tuberculosis & HIV/AIDS infection.

2. List the measures for tuberculosis prevention in HIV infected person.

Student's subscription: _____