

DOI: <https://doi.org/10.34921/amj.2024.3.011>

## ÖRTÜK TOXUMALARDA ODLU SİLAHLA YARANAN DEFEKTLƏRİN BƏRPASINDA CƏRRAHİ TAKTİKANIN OBYEKTİVLƏŞDİRİLMƏSİ

İ.A.Lurin<sup>1</sup>, I.P.Xomenko<sup>1</sup>, M.A.Kaşalyan<sup>2</sup>,  
V.V.Nehoduyko<sup>3</sup>, R.S.Vastyanov<sup>2</sup>, S.V.Tertişniy<sup>2</sup>,  
G.F.Stepanov<sup>2</sup>, O.İ.Solodyanikova<sup>4</sup>, N.V.Tanasıçuk-Gajieva<sup>5</sup>

<sup>1</sup>Milli Tibb Elmləri Akademiyası, Kiyev, Ukrayna;

<sup>2</sup>Odessa Milli Tibb Universiteti, Odessa, Ukrayna;

<sup>3</sup>Xarkov Milli Tibb Universiteti, Xarkov, Ukrayna;

<sup>4</sup>Kiyev Milli Xərçəng İnstitutu, Kiyev, Ukrayna;

<sup>5</sup>A.A.Boqomolets adına Milli Tibb Universiteti, Kiyev, Ukrayna

**Xülasə.** Məqalədə odlu silahla yaralanmış 126 döyüşçüdə örtük toxuması defektlərinin bərpasında cərrahi taktikanın obyektivləşməsinin nəticələri təqdim edilib. Bu məqsədlə yaralılar 2 qrupa bölünüblər: I qrupa 68 yaralı daxil edilib; dinamik angiografik multimodal nəzarət altında 75 rekonstruktiv-bərpaedici əməliyyat yerinə yetirilib; II qrupa daxil edilmiş 58 yaralıda isə adi taktika ilə 96 cərrahi əməliyyat aparılıb. Zədələnmiş anatomik strukturların tez bərpası və onların estetik görünüşü, çarıqların kiçilməsi I qrupdakı xəstələrdə əməliyyatın nəticələrinin yaxşı olduğunu göstərib.

Aparılan işin nəticələri göstərir ki, dinamik monitorinq cərrahi rekonstruktiv-bərpa əməliyyatlarının keyfiyyətini yaxşılaşdırır və tibbi köməyin bütün mərhələlərində tətbiq edilə bilər.

**Açar sözlər:** odlu silah yaraları və yumşaq toxumaların defektləri, örtük toxumalar, termografiya, cərrahi taktikanın effektivliyi

**Ключевые слова:** огнестрельные раны и дефекты мягких тканей, покровные ткани, термография, эффективность хирургической тактики

**Key words:** gunshot wounds and soft tissue defects, integumentary tissue, thermography, effectiveness of surgical tactics

## OBJECTIVIZATION OF SURGICAL TACTICS IN CASE OF COVERING TISSUE GUNSHOT DEFECTS RESTORATION

I.A.Lurin<sup>1</sup>, I.P.Khomenko<sup>1</sup>, M.A.Kashtalyan<sup>2</sup>,  
V.V.Nehoduiko<sup>3</sup>, R.S.Vastyanov<sup>2</sup>, S.V.Tertyshnyi<sup>2</sup>,  
G.F.Stepanov<sup>2</sup>, O.I.Solodyanikova<sup>4</sup>, N.V.Tanasichuk-Gazhieva<sup>5</sup>

<sup>1</sup>National Academy of Medical Sciences of Ukraine, Kyiv, Ukraine;

<sup>2</sup>Odesa National Medical University, Odesa, Ukraine;

<sup>3</sup>Kharkiv National Medical University, Kharkiv, Ukraine;

<sup>4</sup>National Cancer Institute, Kyiv, Ukraine;

<sup>5</sup>A.A.Bogomolets National Medical University, Kyiv, Ukraine

**Summary.** The article presents the results of the objectification of surgical tactics in the restoration of defects in the integumentary tissue due to gunshot wounds in 126 soldiers. For this purpose, all the wounded were divided into 2 groups: Group I included 68 wounded, in whom 75 reconstructive operations were performed under dynamic angiographic multimodal control. Group II consisted of 58 wounded patients who underwent 96 surgical operations using conventional tactics. Rapid restoration of damaged anatomical structures and their aesthetic appearance, reduction of scars showed good results of operations in group I of patients.

The results of the work show that dynamic monitoring improves the quality of surgical reconstructive operations and can be recommended at all stages of medical care.

## Introduction

Currently, almost every day in all directions of the clash between the Armed Forces of Ukraine (AFU) and the Russian Federation (RF), high-energy weapons of mass destruction (multiple launch rocket system – MLRS), controlled air bombs (UAB). This causes a large number of wounded with gunshot defects of the integumentary tissue, constituting 64.9-68.2% of the total number of wounded [1].

The use of dynamic multimodal monitoring during surgical tactics allows us to objectify the clinical picture of the morphological transformation of a gunshot wound, select the optimal type of reconstruction and trace the features of changes in the microvascular bed in the intra- and postoperative period. Determining indicators for optimal assessment of changes in microvascular blood flow is relevant and one of the most important components of surgical treatment to restore all components (function, volume and aesthetics) of the damaged anatomical structure [2-5].

The purpose of the study was to increase the effectiveness of surgical tactics in the reconstructive plastic approach through the use of dynamic monitoring of the fire transformation of integumentary tissues.

**Material and methods.** The study included 126 wounded servicemen of the Ukrainian Armed Forces aged 25 to 60 years with gunshot wounds with the formation of integumentary tissue defects who took part in combat operations from 02/24/2022 to 01/02/2024. All wounded servicemen were men, they had soft tissue defects: small size in 46 (36.5±4.3), medium size in 48 (38.1±4.3), large size in 19 (15.1±3.2%) and giant – in 13 (10.3±2.7%). Standard general clinical examinations, radiography and ultrasound examination of the damaged anatomical area were performed on all wounded.

All patients were divided into 2 comparable groups. Group I (main) included 68 wounded patients who underwent reconstructive operations using dynamic multimodal monitoring in combination with angiography (75 operations). Group II (comparison group) included 58 wounded patients with conventional surgical treatment tactics (96 operations). Both groups were statistically and clinically comparable: in terms of gender, age, damage to the anatomical structure, comorbidity, contamination of the wound surface, damage to the vascular bed and conservative therapy regimen.

In order to objectify the gunshot transformation and monitor morphological readiness for

reconstructive restoration at all stages, dynamic digital thermography, ultrasound studies of the speed and volume of blood flow and angiography were performed in patients of group I to establish the quantitative and qualitative state of the vascular bed of the affected anatomical zone [7]. Depending on the indicators of the qualitative and quantitative bacterial component, the temperature gradient on the wound surface, the speed and volume of blood flow, angioarchitects individually selected the direction and volume of reconstruction in the wounded of group I and subsequent primary surgical treatment of wounds in group II [8, 9].

In the course of the study, the bacterial contamination of the microflora of the wound substrate obtained from the surface of gunshot wounds, the size of the area and volume, the temperature and the speed of blood flow of the wound defect in the complex with paravulnar structures, which was evaluated dynamically during reconstruction, were evaluated.

The results of bacterial contamination of gunshot wounds were obtained within 7 days: the first microflora results were previously obtained on days 4-5 and indicated the pathogen, the final identification of the bacterial composition and sensitivity to antibiotics and antiseptics were identified on day 7 using the “ladder” method, and in the future according to the fundamental pathogenetically determined principle [8, 9].

The area of complications in the form of infiltration and destruction by the type of necrosis was assessed with a transparent ruler template with a grid of squares with an area of 1 mm<sup>2</sup>. To evaluate the effectiveness and objectification of clinical tactics for reconstruction of gunshot defects of soft tissues, we used monitoring of bacterial transformation of the wound substrate (by qualitative component - pathogens, and quantitative composition  $\geq 10^5$ ), dynamic multimodal screening in the main group I (temperature 31o C, which indicates stable restoration of the damaged area ). In the wounded of group II, they followed the classical tactics in the form of staged debridement with the application of secondary sutures and a combination of secondary sutures with a split skin graft [9-11]. The final reconstruction of the wound defect or “closure” was assessed using the follow-up method at 1 month, 6 months, 1 year.

Statistical analysis was performed using Statistica 10 software (StatSoft Inc, USA).

**Results and discussion.** Studies of bacterial contamination have shown that several cultures are established in the wound substrate, namely *St. aureus*, *St. epidermidis*, *E. coli*, *Pr. mirabilis*, *Ps. aureginosa*, *Klebsiella aerogenes*. In 35% of

the results obtained, a combination of the given microorganisms occurred.

The quantitative composition of  $\geq 10^5$  directly depended on the period of evacuation to the next level of medical care, the conditions and season of injury, and the provision of medical care from the moment of injury.

Among the wounded, who, due to the difficult combat situation, did not allow evacuation and surgical care, Ps was recorded in 41.1% of group I and 41.37% of group II cases. aureginosa, Klebsiella aerogenes (Fig. 1). During identification, polyresistance to antimicrobial drugs and individual sensitivity to clindamycin and vancomycin were established. Gram – positive flora in the form of St. aureus, St. epidermidis occurred in second place in our study and was sensitive to cephalosporins and fluoroquinolones.

The transformation of the wound surface was assessed using the thermography method

from the moment of admission to the 2nd level of medical care. At the same time, it was necessary to comply with the following requirements that created automatic thermo-regulation systems: a thermostable zone ( $t=21^\circ\text{C}$ ), no direct flow of air and light onto the wound defect of the damaged anatomical area, scanning of the symmetrical (undamaged) anatomical area.

The obtained results of the thermographic gradient of wound surfaces indicated that for both groups, when the indicators  $t \geq 28,5^\circ\text{C}$  were established, strategic necrosis was prognostically stated over the next 3-7 days (Fig. 2). Upon receipt of thermostable indicators ( $t \geq 31^\circ\text{C}$ ), tissue viability was established during the first examination, and when this indicator was reached, a decision was made from the lower temperature numbers to further close the wound defect.

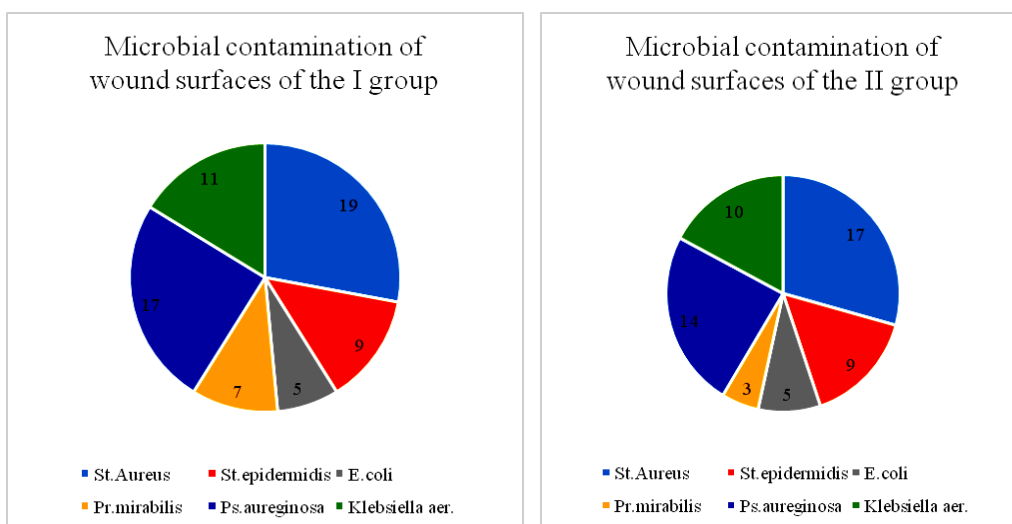


Fig. 1. Microbial contamination of wound surfaces in the wounded study groups

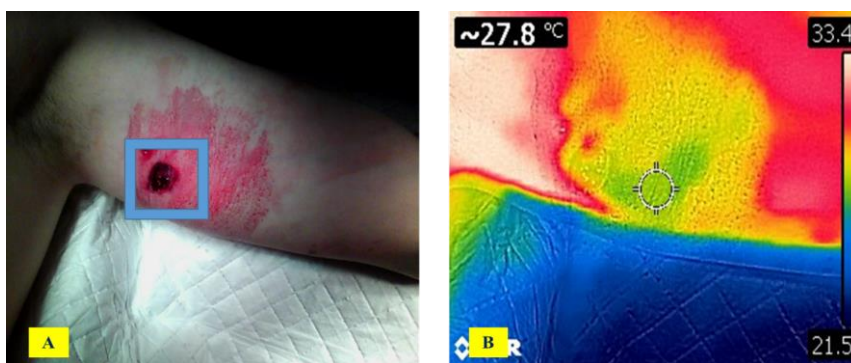
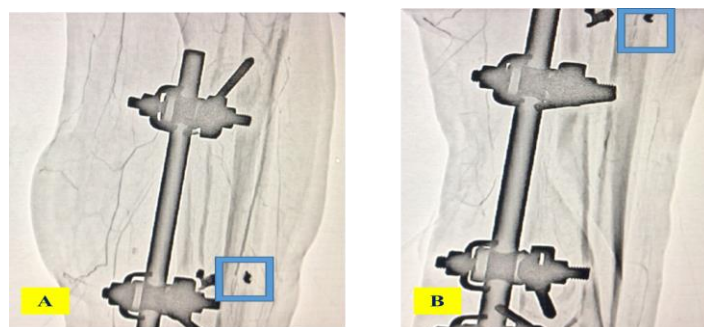


Fig. 2. Thermographic observation of a blind gunshot fragment wound of the inner surface of the upper third of the left shoulder: Fragment A – a wound defect on the inner surface of the left shoulder is circled with a blue square, Fragment B – thermography of the wound surface of the left shoulder, in the center – a cold area (zone of potential necrosis)



**Fig. 3.** CT angiography of the leg with altered angioarchitecture.

Fragment A – lateral projection of the left shin, upper – middle third with the presence of a foreign body – a fragment.

Fragment B – direct projection, middle – lower third with the presence of a fragment in the blue square (damaging the anterior tibial artery).

Thermography made it possible to identify the final blood flow in the form of perforating vessels, to establish a clear location of the specified vessel (according to the angiosomal concept of Ya. Taylor), and sonographic examinations in the form of audio Dopplerometry at the II level of medical care and sonography of the blood flow of the affected structure at the III level of medical care.

When volume and velocity blood flow decreased below 50% within the normal anatomical area, we recorded a direct relationship with a decrease in temperature on the surface of the wound substrate. When the norms for the speed and volume of blood flow were achieved or the temperature increased by 20–25% from the time of injury, reconstruction could be planned.

The final objectification component of the reconstruction was the performance of angiography at the III level of medical care, which demonstrated not only confirmation of previous multimodal screening methods, but also complemented the change in the angioarchitecture of the affected area. This, in turn, made it possible to select the basis for feeding the flap, thanks to which reconstruction was performed, and reduced the time of surgical intervention and the number of complications in the intra and postoperative period (Fig. 3).

The presented approach of dynamic multimodal monitoring from the moment of injury and the application of the principles of reconstructive and restorative tactics (in combination with the use of ultrasonic

cavitation and a controlled negative pressure system) made it possible to observe in group I of the wounded an early “cleaning” of the early surface from days 5 to 10,  $9 \pm 3.2$  days), while in group II of the wounded with classical tactics and staged primary surgical treatment, the time period for the formation of new granulation tissue was 9–17 days (on average  $13.6 \pm 3.4$  days). The time required for flap integration and epithelization of the wound defect in group I averaged  $29.0 \pm 3.5$  days, and in the comparison group –  $45.0 \pm 4.2$  days.

Dynamic multimodal screening was supplemented with follow-up reviews at 1 month, 6 months, and 1 year. This tactic provided the opportunity to assess compensation for the volume of the wound surface; when restoring the tone and turgor of the defect area, the next component was an assessment (sensitivity, fat and sweating), indicators indicating the restoration of biochemical processes in the transferred organ complex.

The main part of the reconstruction was the restoration of the functional component of the damaged anatomical area, therefore, reconstructive tactics in the wounded of the first group helped restore this parameter ( $72.0 \pm 3.5\%$ ), while in the comparison group these figures were  $29.0 \pm 4.3\%$ .

A retrospective analysis of the treatment process and the factors that influenced the characteristics of the growth of granulation tissue and the reconstruction of the damaged anatomical area found that one of the dominant components that influenced the rate

of wound healing was the presence of combined or mixed cultures of the microflora of the wound substrate. The established multicomponent quantitative and qualitative composition of the microflora extended the renewal period. In group I wounded this figure was  $11.7 \pm 4.3$  days, in group II wounded –  $14.5 \pm 2.3$  days, which was due to the use of multifactorial influence and monitoring of objective signs of a positive result in group I.

### **Discussion**

The presented objective methods of dynamic monitoring of the study showed that in wounded patients with no bacterial contamination of the wound surface (“clean wounds”), thermostable indicators of  $32^{\circ}\text{C}$ , restoration of the speed and volume of blood flow of  $\geq 20 - 25\%$  within the anatomical segment of wound restoration occurred 1.8 times faster, which has certain agreement with the data available in the scientific literature [4, 5, 11, 12].

According to the planimetric classification, large and extra-large wounds in area and volume in group I were restored due to a multicomponent organ complex of tissues from another anatomical area, which caused additional blood flow and increased nutrition of the damaged area. In turn, in group II, where classical staged surgical care took place with identical wound sizes, the wounds were restored using secondary sutures in combination with a split skin graft, which increased the treatment period and reduced the restoration of the function of the wound defect.

### **Conflict of interest**

*The authors declared no potential conflicts of interest with respect to the research, authorship, and/or publication of this article.*

Analyzing the objective factors of treatment tactics in a reconstructive approach based on dynamic multimodal screening [13], it should be noted that the indicators of dynamic digital thermography, sonographic indicators (velocity and volume of blood flow), angiography results (with altered angioarchitecture) not only confirm the clinical picture of the morphological transformations of the wound surface of gunshot genesis and complement each other, and also act as alternative screening factors in the absence of an expanded material and technical base and especially in conditions of limited resources.

It is important to note that the wounded who underwent reconstruction based on the principles of the reconstructive-restorative ladder [13] had a faster rate of recovery, a higher percentage of functional recovery and a greater aesthetic option. In our opinion, the presented definitions of Group I can be integrated at all levels of medical care in the armed forces and be considered as a good alternative to classical monitoring of gunshot wounds.

**Conclusions.** Reconstructive tactics with dynamic monitoring of all stages of the treatment process can not only speed up the wound healing process, improve the quality of surgical care by restoring the functional component of the damaged anatomical structure, but also objectify the surgical tactics of treating patients with gunshot wounds.

## **REFERENCES**

1. Meade A., Hembd A., Cho M.J., Zhang A.Y. Surgical Treatment of Upper Extremity Gunshot Injuries: An Updated Review // *Ann Plast Surg.* 2021; 86 (3S Suppl 2): 312-318. doi: 10.1097/SAP.0000000000002634.
2. Tsymbalyuk V.İ., Lurin I.A., Abdullayev R.Ya., Qreçanik Ye.İ., Tsymbalyuk Ya.V. Ultrasound diagnosis of gunshot injuries of peripheral nerves // *Azerbaijan medical journal (ATJ)*, 2022, №3, C. 62-71.
3. Zheng D.W., Li Z.C., Shi R.J., Sun F., Xu L., Shou K.S. Use of giant-sized flowthrough venous flap for simultaneous reconstruction of dual or multiple major arteries in salvage therapy for complex upper limb traumatic injury // *Injury.* 2016; 47(2): 364-371.
4. Obadan I.O., Michael A.I., Iyun A.O., Ademola S.A., Olawoye O.A., Aderibigbe R.O. & Oluwatosin O.M. (2024). Thermographic Mapping of Arterial Perforators in the Leg // *J West Afr Coll Surg.* 14(1):90-93. [https://doi.org/10.4103/jwas.jwas\\_84\\_23](https://doi.org/10.4103/jwas.jwas_84_23)

5. Taylor G.I. (2003). The angiosomes of the body and their supply to perforator flaps. *Clin Plast Surg.*, 30(3):331-342. [https://doi.org/10.1016/s0094-1298\(03\)00034-8](https://doi.org/10.1016/s0094-1298(03)00034-8)
6. Sheean A.J., Tintle S.M., Rhee P.C. Soft tissue and wound management of blast injuries // *Curr Rev Musculoskelet Med.* 2015; 8(3): 265-71. doi: 10.1007/s12178-015-9275-x.
7. Khomenko I.P., Tertyshnyi S.V., Vastyanov R.S., Talalayev K.O., Turchin M.I. & Panasenko S.I. (2022). Experimental background of thermometry using with diagnostic purposes in soft tissue gunshot damages // *World of Biology and Medicine*, 1(79). – С. 237-243. <https://doi.org/10.26724/2079-8334-2022-1-79-237-243>
8. Nabiev M., Yusupova S., Azimov A., Boronov T. Peculiarities of diagnostics, surgical tactics and restoration operations in necrotizing infection of soft tissues. *Avicenna Bulletin.* 2018; 20(1): 97-102.
9. Kokkalis Z.T., Papanikos E., Mazis G.A., Panagopoulos A., Konofaos P. Lateral arm flap: indications and techniques // *Eur J Orthop Surg Traumatol.* 2019. 2(29): 279-284. doi: 10.1007/s00590-019-02363-0.
10. Grechanyk O.I., Abdullaev R.Ya., Lurin I.A., Humenyuk K.V., Nehoduiko V.V. & Slesarenko D.O. (2021). Modern aspects of the diagnosis of gunshot wounds to the abdomen. The experience of the hybrid war in the east of Ukraine // *Clinical surgery*, 88(5-6): 42-52. <https://doi.org/10.26779/2522-1396.2021.5-6.42>.
11. Baum G.R., Baum J.T., Hayward D. & MacKay B.J. (2022). Gunshot Wounds: Ballistics, Pathology, and Treatment Recommendations, with a Focus on Retained Bullets // *Orthopedic Research and Reviews*, 14: 293–317. <https://doi.org/10.2147/ORR.S378278>.
12. Khomenko I.P., Lurin I.A., Korol S.O., Shapovalov V.Yu., Hrebennikov K.O., Halushka A.M., Tertyshnyi S.V. & Matviichuk B.V. (2020). Organization of sorting and surgery of wounds with soft tissue defects during the joint force surgery // *Journal of Education, Health and Sport*, 10(1): 259-269. <http://dx.doi.org/10.12775/JEHS.2020.10.01.029>
13. Lurin I.A., Khomenko I.P., Nehoduiko V.V., Tertyshnyi S.V., Makarov V.V. (2023). Prospects of the high-speed multimedia data transmission technologies use in the structure of the system for providing aid to injured persons having a gunshot defect of soft tissues // *Wiadomości Lekarskie Medical Advances*, 76(5; part II), 1191-1198. <https://doi.org/10.36740/WLek202305209>

## **ОБЪЕКТИВИЗАЦИЯ ХИРУРГИЧЕСКОЙ ТАКТИКИ ПРИ ВОССТАНОВЛЕНИИ ОГНЕ-СТРЕЛЬНЫХ ДЕФЕКТОВ ПОКРОВНЫХ ТКАНЕЙ**

**И.А.Лурин<sup>1</sup>, И.П.Хоменко<sup>1</sup>, М.А.Каштальян<sup>2</sup>,  
В.В.Негодуйко<sup>3</sup>, Р.С.Вастьянов<sup>2</sup>, С.В.Тертишний<sup>2</sup>,  
Г.Ф.Степанов<sup>2</sup>, О.И.Солодянникова<sup>4</sup>, Н.В.Танасичук-Гажиева<sup>5</sup>**

<sup>1</sup>Национальная академия медицинских наук Украины, Киев, Украина;

<sup>2</sup>Одесский национальный медицинский университет, Одеса, Украина;

<sup>3</sup>Харківський національний медичний університет, Харків, Україна;

<sup>4</sup>Национальный институт рака, Киев, Украина

<sup>5</sup>Национальный медицинский университет им. А.А.Богомолеца, Киев, Украина

**Резюме.** В статье представлены результаты объективизации хирургической тактики восстановления дефектов покровной ткани вследствие огнестрельных ранений у 126 военнослужащих. Для этого все раненые были разделены на 2 группы: в I группу вошли 68 раненых, у которых под динамическим ангиографическим мультимодальным контролем было выполнено 75 реконструктивных операций. II группу составили 58 раненых, которым выполнено 96 хирургических операций с использованием общепринятой тактики. Быстрое восстановление поврежденных анатомических структур и их эстетического вида, уменьшение рубцов показали хорошие результаты операций у больных I группы.

Результаты работы показывают, что динамический мониторинг повышает качество хирургических реконструктивных операций и может быть рекомендован на всех этапах оказания медицинской помощи.

### **For correspondence:**

**Tertyshnyi Serhii**, Department of Disaster Medicine and Military Medicine, Odessa National Medical University

**E-mail:** drug2008@ukr.net