

UDC 611.817.1:611.133.33:57.086  
DOI: 10.24061/1727-0847.23.1.2024.12

**M. O. Kalinichenko, O. Yu. Stepanenko**

*Department of Histology, Cytology and Embryology (Head – Prof. O. Yu. Stepanenko) Kharkiv National Medical University, Kharkiv*

## FRACTAL ANALYSIS OF BRANCHING OF HUMAN CEREBELLAR ARTERIES

## ФРАКТАЛЬНИЙ АНАЛІЗ РОЗГАЛУЖЕНОСТІ ПОВЕРХНЕВИХ АРТЕРІЙ МОЗОЧКА ЛЮДИНИ

---

**Резюме.** Мозочок людини живлять три артерії: верхню поверхню мозочка живить верхня мозочкова артерія (ВМА), нижню – передня нижня та задня нижня мозочкові артерії (ПНМА і ЗНМА). Традиційно розгалуженість поверхневого судинного русла визначається суб'єктивно; вирізняють магістральний, розсипний або проміжний типи. Об'єктивним альтернативним методом є фрактальний аналіз.

Метою роботи є дослідження фрактальної розмірності розгалуженості поверхневих артерій мозочка людини та встановлення взаємозв'язку між величиною фрактального індексу та формою мозочка.

Матеріал і методи. Було досліджено 100 препаратів мозочка разом зі стовбуром мозку. Вимірювали ширину, довжину і висоту мозочка. Визначали величину параметрів форми мозочка: відносної ширини (rW), відносної довжини (rL) та відносної висоти мозочка (rH), як відношення квадрата одного лінійного розміру до добутку двох інших. Для фрактального аналізу були відібрані 15 мозочків різної форми (9 осіб – чоловічої та 6 – жіночої статі). Проводили фрактальний аналіз цифрових зображень верхньої та нижньої поверхонь мозочка справа та зліва методом підрахунку квадратів.

Результати дослідження. Встановлено діапазон значень фрактального індексу, визначено інтервали значень, що відповідають проміжному (1,54 ÷ 1,73), магістральному (<1.54) та розсипному (>1.73) типам галуження. Верхній поверхні більш властивий магістральний або проміжний тип галуження, тоді як для нижньої більш характерний проміжний або розсипний типи галуження. Найбільше різноманіття варіантів галуження артерій – від магістрального до розсипного – як на верхній, так і на нижній поверхнях мозочка, спостерігається в найбільш численній групі – мозочків середньої форми, незалежно від того, який показник форми аналізується. Характер галуження поверхневих артерій мозочка прагне до розсипного типу у відносно вузьких та відносно коротких мозочків і навпаки – до магістрального – у відносно широких і відносно довгих мозочків. Протилежним чином впливає відносна висота: характер галуження поверхневих артерій мозочка прагне до розсипного типу при збільшенні відносної висоти мозочка. Так, відносно низькі мозочки мають зазвичай магістральний тип галуження (що більш помітно на верхній поверхні), тоді як у відносно високих мозочків характер галуження прагне до розсипного (що більш помітно на нижній поверхні).

**Ключові слова:** головний мозок, мозочок, артерії, морфометрія, фрактальний аналіз.

---

Cardiovascular, including cerebrovascular, diseases account for two-thirds of all lethal cases in Ukraine and represent a significant medical and social issue. Cerebrovascular diseases manifesting as strokes, both ischemic and hemorrhagic, constitute the most severe form of vascular disorders affecting the brain. The prevalence of ischemic strokes in Ukraine is five times higher than that of hemorrhagic strokes [1]. Cerebellar strokes comprise approximately 3-4 % of all ischemic strokes [2-5].

The human cerebellum is supplied by three arteries: the superior cerebellar artery (SCA) nourishes

the superior surface of the cerebellum, while the anterior inferior cerebellar artery (AICA) and the posterior inferior cerebellar artery (PICA) supply the inferior surface. Traditionally, the branching pattern of the superficial vascular network is described according to one of three types: trunk, lose or mixed, depending on the intensity of vessel branching, diameter of the branches and the number of anastomoses between them. Determination of these branching types is typically performed subjectively. Instead, an objective morphometric method for quantitative evaluation of the complexity of spatial organization of structures,

including the branching of the vascular network, is fractal analysis: it has been established that different branching types correspond to distinct ranges of values of the fractal index (FI) [6].

A manifestation of individual anatomical variability of the cerebellum is the variability of its shape: based on the distribution of relative width values, relatively narrow, proportional in width and relatively wide cerebella can be distinguished; relative length values – relatively short, proportional in length and relatively long cerebella; relative height values – relatively low, proportional in height, and relatively high cerebella [7]. Cerebella of different shapes differ in external structure, primarily in the shape and size of lobules, as well as in the direction and depth of fissures [7]. Cerebella of different shapes fundamentally do not differ in the distribution of vascular supply areas. However, the pattern of branching of superficial arteries in cerebella of different shapes has not been previously investigated.

**The aim of this study** is to investigate the fractal dimension of branching complexity of superficial arteries in the human cerebellum and to establish the relationship between the magnitude of the fractal index and the shape of the cerebellum.

**Material and Methods.** The study was conducted on 100 samples. Each sample included cerebellum and an adjacent brainstem. They were obtained from adult human cadavers (67 male and 33 female) who died of causes unrelated to brain pathology at the age between 20 and 92. The Commission on Bioethics of the Kharkiv National Medical University (protocol No. 4 dated 15.09.2020) established that the research does not contradict the basic bioethical standards of the Helsinki Declaration, the Council of Europe Convention on Human Rights

and Biomedicine (1977), relevant WHO regulations and laws of Ukraine.

The width, length, and height of the cerebellum were measured. The magnitude of cerebellar shape parameters was determined: relative width (rW), relative length (rL), and relative height (rH), defined as the ratio of the square of one linear dimension to the product of the other two [7].

For fractal analysis, 15 cerebella of different shapes were selected (9 from male and 6 from female individuals), varying in relative parameter, so that each relative parameter fell within the ranges of small, medium, and large values at least 4 times each range, and the distribution of relative shape parameter values did not differ from that of the entire sample (Fig. 1, 2).

The superior and inferior surfaces of these cerebella were photographed along with a calibration ruler using a digital single-lens reflex camera. Subsequently, in Adobe Photoshop CS5 software, a square corresponding to the area on the surface of the right or left hemisphere of the cerebellum measuring 3.5×3.5 cm was cropped from the digital image (Fig. 3, 4).

The fractal index of superficial arteries (FISA) of the cerebellum was calculated using the *box-counting* method [6]. Statistical analysis of the FI values distribution was conducted, including calculation of the sample mean (M), standard deviation (S), coefficient of variation (Cv) and determination of the minimum and maximum values. To assess the relationship between FI magnitude and cerebellar shape parameters, a correlation analysis was conducted with calculation of the Pearson correlation coefficient (r), assessing its significance using the t-test and deriving linear regression equations.

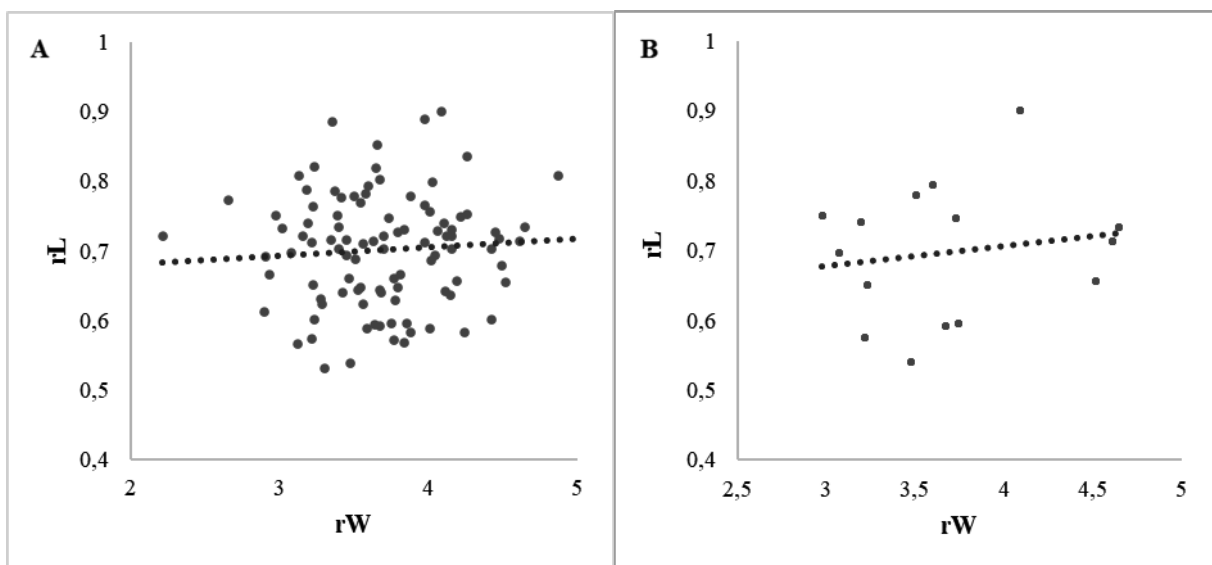


Fig. 1. The distribution of values of rW and rL overall (A) and in the sample subjected to fractal analysis (B)

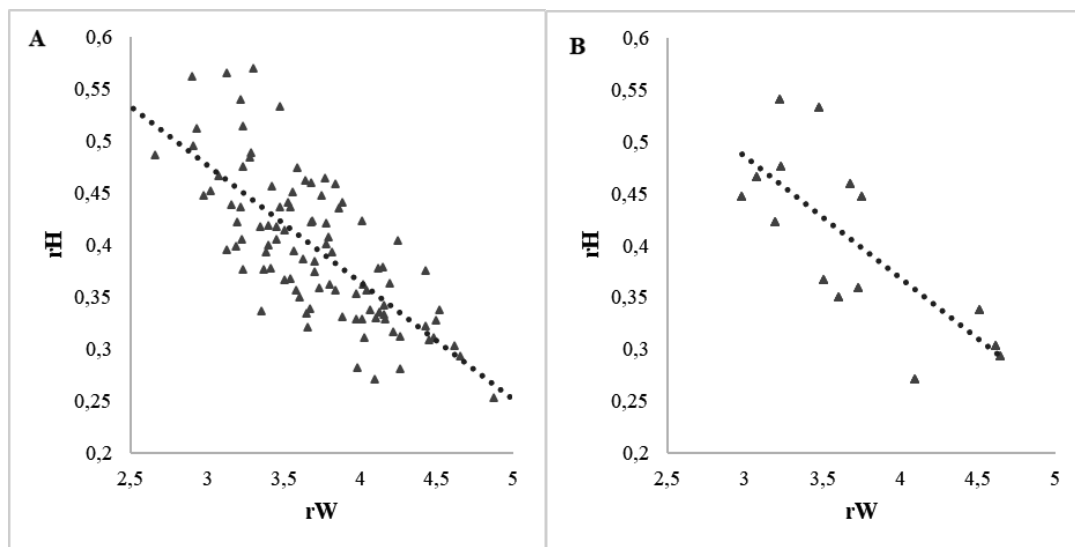


Fig. 2. The distribution of values of  $rW$  and  $rH$  overall (A) and in the sample subjected to fractal analysis (B)

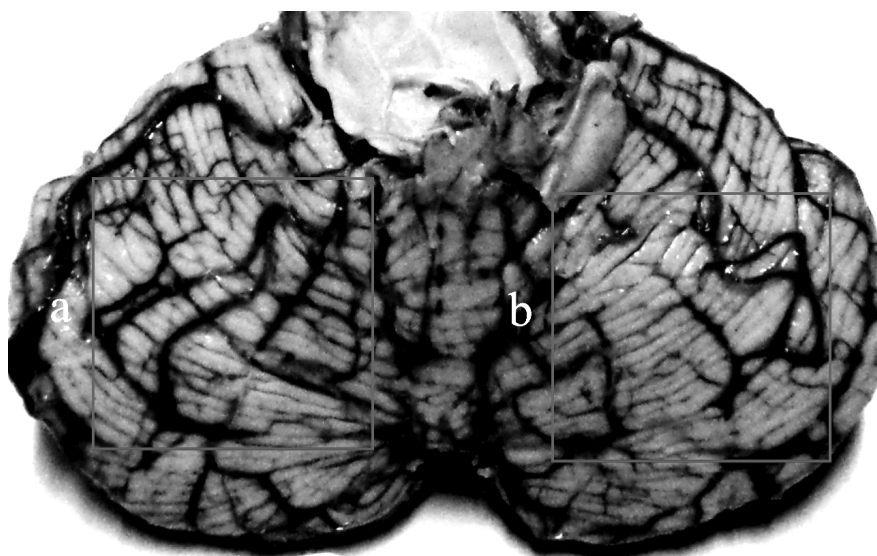


Fig. 3. Example of selecting areas on the superior surface of the cerebellum (territory of the SCA): a – area of the left hemisphere of the cerebellum, b – area of the right hemisphere of the cerebellum

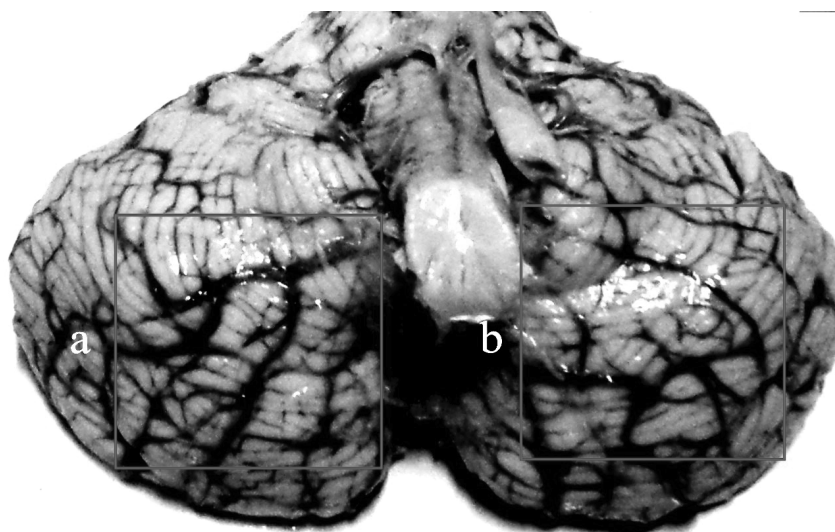


Fig. 4. Example of selecting areas on the inferior surface of the cerebellum (territory of the AICA and PICA): a – area of the right hemisphere of the cerebellum, b – area of the left hemisphere of the cerebellum

**Research results and their discussion.** Table 1 presents the values of cerebellar shape parameters, while Table 2 displays the FISA values for the superior and inferior surfaces of the cerebellum, as well as the overall FISA values.

As evident from the data in Table 2, the variability of FISA values of the superior and inferior surfaces, assessed by the coefficient of variation, in the investigated sample is insignificant. The overall range of mean FISA values of the cerebellum corresponds to a range from 1.54 to 1.73. The FISA values on the superior and inferior surfaces of the cerebellum do not coincide (Fig. 5); the FISA of the superior surface of the cerebellum is significantly smaller than that of the inferior surface ( $p < 0.05$ ).

Figures 6-8 show the relationships between the relative parameters of cerebellar shape and FISA separately for the superior and inferior surfaces.

As evident from the data in Fig. 6 (A), objects with large values of rW, indicating relatively wide cerebella, predominantly exhibit small FISA values on

the superior surface, corresponding to a trunk branching pattern of arteries. Objects proportional in relative width (with mean rW values) mostly have average FISA values, but in certain cases, small values corresponding to a trunk branching pattern or, conversely, large values corresponding to a loose branching pattern are observed. The greatest diversity in the distribution of FISA values is observed among cerebella with relative width values close to the mean sample value. Objects with small values of rW, indicating relatively narrow cerebella, have average or small FISA values. Overall, cerebella with rW values ranging from the minimum to the mean more frequently exhibit average FISA values, while cerebella with rW values ranging from the mean to the maximum exhibit average and small values. There is a tendency for FISA values of arteries on the superior surface to decrease with increasing in relative width of the cerebellum, as indicated by the slope of the regression line; however, the relationship between rW and FISA of arteries on the superior surface is weak and statistically insignificant ( $r = -0.24$ ,  $p > 0.05$ ).

Table 1

Statistical evaluation of the distribution of values of relative parameters of the cerebellum

Parameter	M	m	S	Cv, %	min	max
rW	3.69	0.07	0.54	14.60	2.98	4.65
rL	0.70	0.01	0.09	13.52	0.54	0.90
rH	0.41	0.01	0.08	20.57	0.27	0.54

Table 2

Statistical evaluation of the distribution of fractal index values of superficial cerebellar arteries

Parameter	M	m	S	Cv, %	min	max
FISA of superior surface	1,60	0,02	0,09	5,92	1,42	1,79
FISA of inferior surface	1,68	0,02	0,09	5,27	1,50	1,82
FISA (overall)	1,64	0,02	0,10	6,02	1,42	1,82

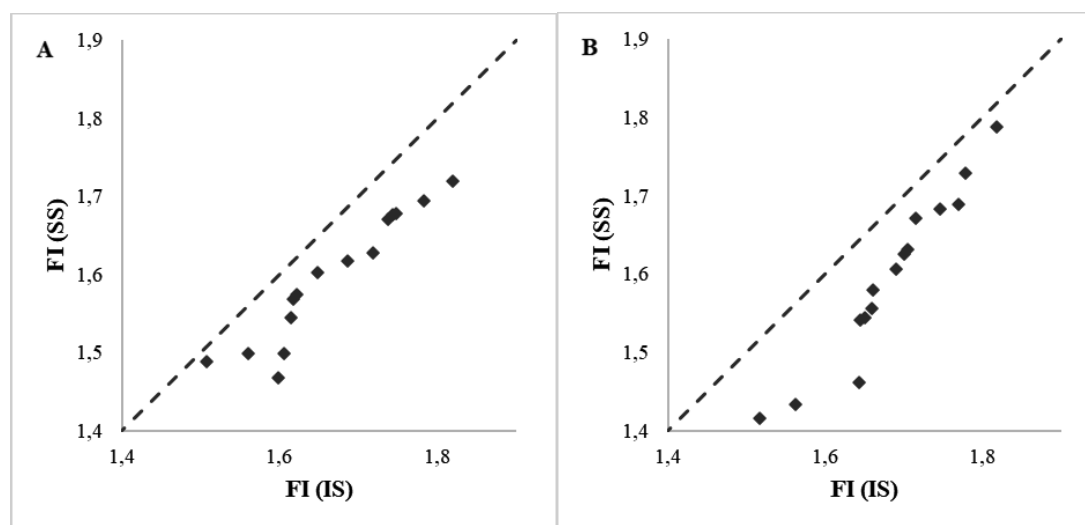


Fig. 5. The distribution of FI values of superficial arteries on the right (A) and left (B) hemispheres: SS – superior surface of the cerebellum, IS – inferior surface of the cerebellum. The dashed line corresponds to the function  $x = y$

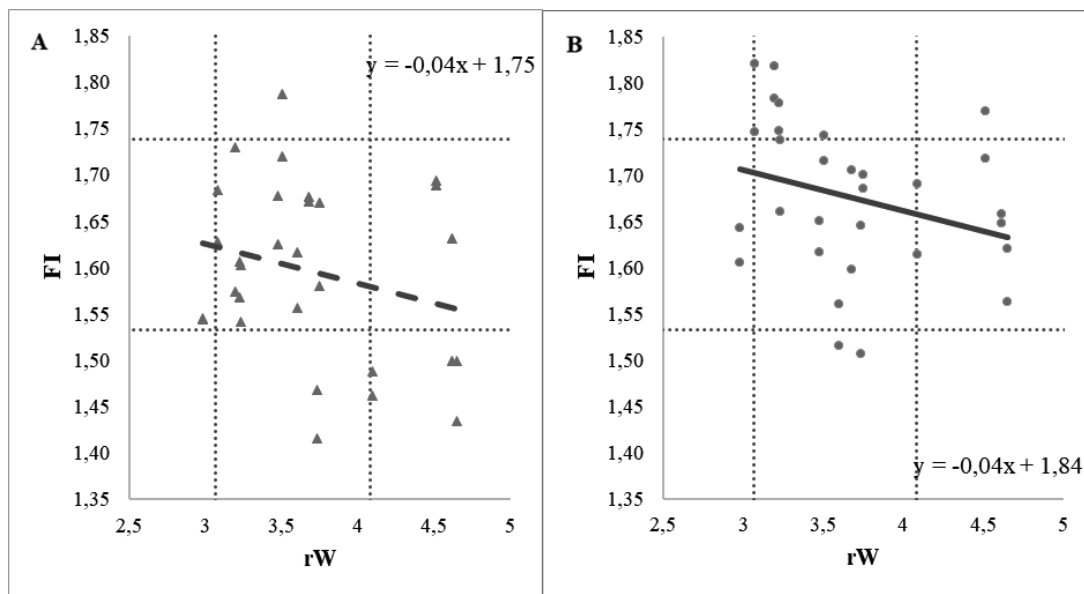


Fig. 6. Relationship between FISA values and rW: A – superior surface, B – inferior surface. Note: dashed lines correspond to M–S and M+S values (according to Tab. 1 and 2, here and in Fig. 7, 8)

On the *inferior surface* (Fig. 6 (B)), relatively wide cerebella mostly exhibit average FISA values. Objects proportional in relative width have the widest range of FISA values: mostly average values, but a portion have small or large FISA values. Relatively narrow cerebella have average FISA values. Cerebella with rW values ranging from the minimum to the mean more frequently have average and large FISA

values, while cerebella with rW values ranging from the mean to the maximum have average and small values. Overall, FISA values of arteries on the inferior surface decrease with increasing in relative width of the cerebellum; there is a weak, statistically insignificant linear relationship between rW and FISA of arteries on the inferior surface of the cerebellum ( $r = -0.29, p > 0.05$ ).

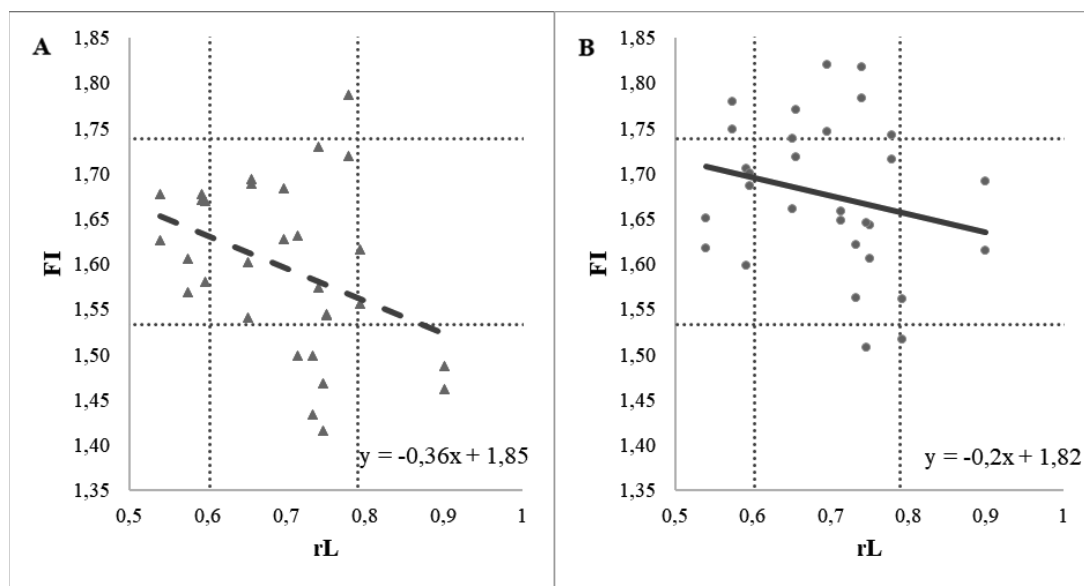


Fig. 7. Relationship between FISA values and rL: A – superior surface, B – inferior surface

As evident from the data in Fig. 7 (A), on the *superior surface*, objects with large values of rL, indicating relatively long cerebella, have average and low FISA values. Objects with mean rL values (proportional in relative length) mostly have average, then small, and the fewest – large FISA values. Relatively short cerebella (with small rL values)

have average FISA values. The greatest disparity in the distribution of FISA values is observed among cerebella with rL values ranging from the mean to the maximum. The slope of the regression line indicates that FISA values of arteries on the superior surface decrease with the increasing in relative length of the cerebellum. The linear relationship between FISA

and rL on the superior surface of the cerebellum is moderate in strength and statistically significant ( $r = -0.36, p < 0.05$ ).

The data in Fig. 7 (B) indicate that on the *inferior surface*, objects with large values of rL tend to fall within the range of average and small FISA values. Objects proportional in relative length mostly exhibit average FISA values, with the second most frequent group being objects with large values; occasional instances of objects with small values are also observed. Relatively short cerebella more frequently

display average FISA values and sporadic instances of large FISA values. Throughout the entire range of rL values, cerebella with small FISA values are rarely encountered. There is a tendency for FISA values of arteries on the inferior surface to decrease with increasing in relative length of the cerebellum; however, the relationship between these parameters is weak and statistically insignificant ( $r = -0.23, p > 0.05$ ). When analyzing the entire sample, the relationship between FISA and rL becomes significant ( $r = -0.27, p < 0.05$ ).

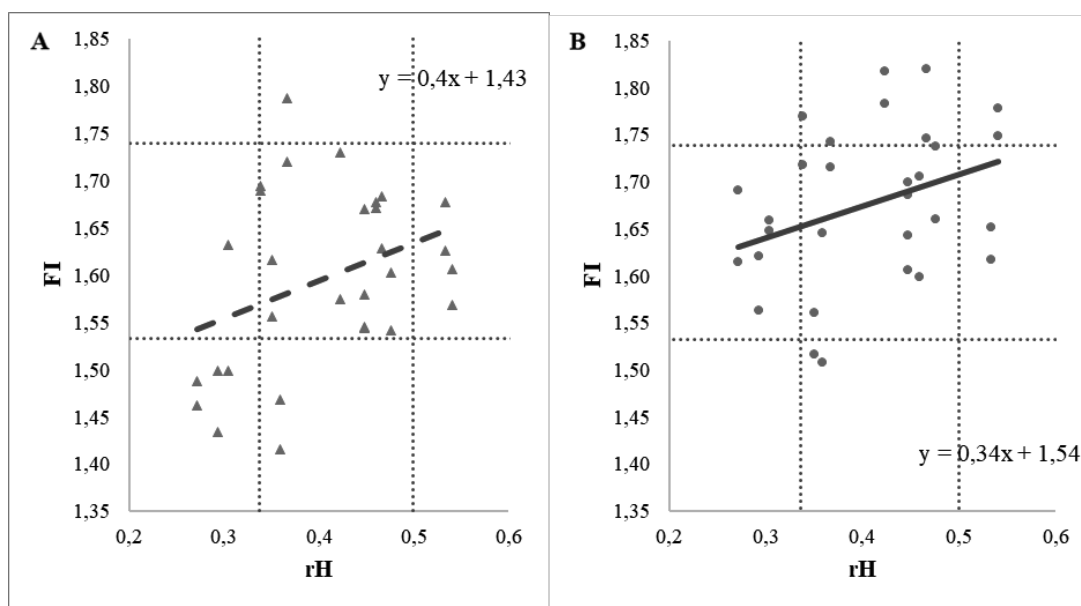


Fig. 8. Relationship between FISA values and rH: A – superior surface, B – inferior surface

The data in Fig. 8 (A) indicate a direct relationship between the values of rH and FISA of arteries on the *superior surface*. Objects with large values of rH, representing relatively high cerebella, exhibit average FISA values on the superior surface. Objects with average values of rH (proportional in relative height) show a wide dispersion of FISA values: most of these cerebella have average FISA values, with fewer instances of small or large values. Objects with small values of rH (relatively low) more frequently display small FISA values. Throughout the entire range of rH values, cerebella with large FISA values are scarce. The slope of the regression line indicates that the FISA values of arteries on the superior surface increase with increasing in relative height of the cerebellum, demonstrating a moderate statistically significant relationship between rH and FISA of arteries on the superior surface ( $r = 0.36, p < 0.05$ ).

The data in Fig. 8 (B) indicate that on the *inferior surface*, relatively high cerebella with large rH values are situated in the region of large and average FISA values. Cerebella proportional in relative height exhibit large, average and small FISA values, with

the majority being average. The greatest diversity in the distribution of FISA values is observed among cerebella with rH values close to the sample mean. Relatively low cerebella have average FISA values. Overall, cerebella with rH values ranging from the minimum to the mean more frequently display small and average FISA values, while those with rH values ranging from the mean to the maximum exhibit average and large values. There is a tendency for the FISA values of arteries on the inferior surface to increase with increasing in relative height of the cerebellum, as indicated by the slope of the regression line. The linear relationship between rH and FISA of the inferior surface of the cerebellum is moderate in strength and statistically insignificant ( $r = 0.34, p > 0.05$ ). However, upon analyzing the entire sample, the relationship between FISA and rH becomes significant ( $r = 0.32, p < 0.05$ ).

Fractal analysis represents an objective alternative to subjective methods for assessing the degree of vascular branching on the surface of an organ. The distribution of FISA values of arteries on the surface of the cerebellum according to a normal

distribution allows for the application of this criterion to quantitatively determine the type of vascular branching: large FISA values characterize maximal vascular branching and a significant number of anastomoses between them, moderate values indicate moderate branching, while small values denote weak vascular branching. These can be correlated with traditional types of vascular branching: FISA values within the range of  $M \pm S$  correspond to the mixed type of vascular structure, higher values correspond to a loose type, and lower values correspond to a trunk type. The ranges of FISA values obtained in our study did not significantly differ from those reported in previous research [6].

The difference in FISA between the different surfaces of the cerebellum indicates varying degrees of branching of the arteries with which they are supplied: the superior surface is more characteristic of the trunk or mixed types of branching, while the inferior surface is more typical of mixed or loose types of branching; the FISA value of the inferior surface is always greater than that of the superior surface. These findings can also be explained by the fact that typically only one of the main cerebellar arteries (the SCA) supplies the superior surface of the cerebellum, whereas two arteries (the AICA and PICA) supply the inferior surface, each with their own branching patterns and anastomoses between them. Previous studies [8] did not find significant differences in FISA between the superior and inferior surfaces of the cerebellum, which may be attributed to the selection of different surface areas of the cerebellum for analysis.

The greatest diversity of arterial branching patterns – from the trunk to loose type – is observed in the most numerous group – cerebella of proportional shape, regardless of which shape parameter is analyzed. The branching pattern of superficial cerebellar arteries tends towards a loose type in relatively narrow and relatively short cerebella, and conversely towards a trunk type in relatively wide and relatively long cerebella. Conversely, relative height has an opposite effect: the branching pattern of superficial cerebellar arteries tends towards a loose

type as the relative height of the cerebellum increases. Thus, relatively low cerebella typically exhibit a trunk branching pattern (more noticeable on the superior surface), while in relatively high cerebella, the branching pattern tends towards loose (more noticeable on the inferior surface).

The tendency of relatively high and relatively short cerebella towards a loose branching pattern is a risk factor for the development of ischemia due to smaller average vessel diameter. Similarly, relatively low and relatively long cerebella, which tend towards a trunk branching pattern, are more vulnerable to thrombosis and embolism. Following the same principle, the vessels of the superior surface of the cerebellum are more sensitive to thrombosis and embolism, while those of the inferior surface – to ischemia.

Our data complement previous studies on the regularities of the fractal organization of cerebellar vessels [8], where a direct correlation between the FISA of the cerebellum and its mass, relative height, and an inverse correlation with relative width were established.

**Conclusions.** 1. Fractal analysis was used to quantitatively characterize the branching pattern of arteries on the superior and inferior surfaces of the cerebellum and the range of its variability was established using the fractal index. Intervals of fractal index values corresponding to the mixed (1.54 to 1.73), trunk (<1.54) and loose (>1.73) types of arterial branching on the cerebellar surface were determined. 2. It was determined that the superior surface of the cerebellum is more characteristic of the trunk or mixed types of arterial branching, whereas the inferior surface tends towards the mixed or loose types. 3. It has been demonstrated that there is a certain correlation between the shape of the cerebellum and the type of arterial branching on its surfaces. The likelihood of a loose type of branching increases with an increase in relative height and a decrease in relative length of the cerebellum, while the likelihood of a trunk type of branching decreases.

**Prospects for further investigations.** Further research will help better understand the causes of cerebellar vascular pathologies.

## References

1. Mishchenko T. *Epidemiology of cerebrovascular diseases and organization of medical care for patients with stroke in Ukraine. Ukrains'kyi visnyk psyhonevrolohii.* 2017;25(2):41-3. [in Ukrainian].
2. Calic Z, Cappelen-Smith C, Anderson CS, Xuan W, Cordato DJ. *Cerebellar Infarction and Factors Associated with Delayed Presentation and Misdiagnosis. Cerebrovasc Dis.* 2016;42(5-6):476-84. doi:10.1159/000448899.
3. Edlow JA, Newman-Toker DE, Savitz SI. *Diagnosis and initial management of cerebellar infarction. Lancet Neurol.* 2008;7(10):951-64. doi:10.1016/S1474-4422(08)70216-3.
4. Savoirdo M, Bracchi M, Passerini A, Visciani A. *The vascular territories in the cerebellum and brainstem: CT and MR study. AJNR Am J Neuroradiol.* 1987;8(2):199-209.

5. Venti M. Cerebellar infarcts and hemorrhages. *Front Neurol Neurosci.* 2012;30:171-5. doi:10.1159/000333635.
6. Stepanenko A, Mar'enko N. Fraktal'nyj analiz kak metod morfometrisheskogo issledovaniya poverhnostnoj sosudistoj seti mozzhechka cheloveka. *Ekspierimental'na i klinichna medicina.* 2015;4:50-5. [in Ukrainian].
7. Kalinichenko M, Stepanenko O. Shape and Surface Structure of the Human Cerebellum: Variant Anatomy. *Acta Morphologica Et Anthropologica.* 2023;30(3-4):78-86. doi: 10.7546/AMA.30.3-4.2023.10.
8. Stepanenko A. Zakonomernosti individual'noj izmenchivosti struktury poverhnostnoj sosudistoj seti mozzhechka. *Ekspierimental'na i klinichna medicina.* 2017;2:44-8. [in Ukrainian].

## FRACTAL ANALYSIS OF BRANCHING OF HUMAN CEREBELLAR ARTERIES

**Abstract.** Human cerebellum is supplied by three arteries: the superior surface is nourished by the superior cerebellar artery (SCA), while the inferior surface is supplied by the anterior inferior cerebellar artery (AICA) and the posterior inferior cerebellar artery (PICA). Traditionally, the branching pattern of the superficial vascular network is subjectively assessed, distinguishing between the trunk, loose or mixed types. Fractal analysis is an objective alternative method.

The aim of this study is to investigate the fractal dimension of branching complexity of superficial arteries in the human cerebellum and to establish the relationship between the magnitude of the fractal index and the shape of the cerebellum.

**Material and Methods.** A total of 100 cerebellum samples, including the brainstem, were examined. The width, length, and height of the cerebellum were measured. Parameters of cerebellar shape, namely relative width (rW), relative length (rL), and relative height (rH), were determined as the ratios of the square of one linear dimension to the product of the other two. For fractal analysis, 15 cerebellar samples of various shapes (9 from male and 6 from female individuals) were selected. Fractal analysis of digital images of the superior and inferior surfaces of the cerebellum was performed bilaterally using the box-counting method.

**Results.** The range of fractal index values was determined, and intervals corresponding to the mixed (1.54-1.73), trunk (<1.54) and loose (>1.73) branching types were identified. The superior surface predominantly exhibited trunk or mixed branching types, whereas the inferior surface was more characteristic of mixed or loose branching types. The greatest diversity of arterial branching patterns – from the trunk to loose type – is observed in the most numerous group – cerebella of proportional shape, regardless of which shape parameter is analyzed. The branching pattern of superficial cerebellar arteries tends towards a loose type in relatively narrow and relatively short cerebella, and conversely towards a trunk type in relatively wide and relatively long cerebella. Conversely, relative height has an opposite effect: the branching pattern of superficial cerebellar arteries tends towards a loose type as the relative height of the cerebellum increases. Thus, relatively low cerebella typically exhibit a trunk branching pattern (more noticeable on the superior surface), while in relatively high cerebella, the branching pattern tends towards loose (more noticeable on the inferior surface).

**Key words:** brain, cerebellum, arteries, morphometry, fractal analysis.

### *Відомості про авторів:*

**Калініченко Михайло Олександрович** – аспірант кафедри гістології, цитології та ембріології Харківського національного медичного університету, м. Харків;

**Степаненко Олександр Юрійович** – доктор медичних наук, професор, завідувач кафедри гістології, цитології та ембріології Харківського національного медичного університету, м. Харків.

### *Information about the authors:*

**Kalinichenko Mykhailo O.** – PhD Student of the Department of Histology, Cytology and Embryology Kharkiv National Medical University, Kharkiv;

**Stepanenko Oleksandr Yu.** – MD, Professor, Head of the Department of Histology, Cytology and Embryology Kharkiv National Medical University, Kharkiv.

Надійшла 20.02.2024 р.  
Рецензент – проф. Т. В. Хмара (Чернівці)