



USAID
ВІД АМЕРИКАНСЬКОГО НАРОДУ

PATH
P O S S I B L E

ISSN 2220-5071 (Print)
ISSN 2522-1094 (Online)

ТУБЕРКУЛЬОЗ ЛЕГЕНЕВІ ХВОРОБИ ВІЛ-ІНФЕКЦІЯ

український рецензований
науково-практичний спеціалізований журнал

№ 1 (56) 2024

Human-Beta-Defensin-1, Ferritin,
Interleukin-6 and their Relationship
with Clinical and Laboratory Parameters
of the Severity of the Tuberculosis Process

Вплив CD4⁺ Т-лімфоцитів
на напруженість протидифтерійного
імунітету в дорослих, які живуть з ВІЛ

Рівень сироваткового інтерлейкіну-10
у госпіталізованих пацієнтів
з коронавірусною хворобою

Tuberculosis

Lung Diseases

HIV Infection

ukrainian scientific
and practical journal

www.tubvil.com.ua
www.vitapol.com.ua

ТУБЕРКУЛЬОЗ ЛЕГЕНЕВІ ХВОРОБИ ВІЛ-ІНФЕКЦІЯ

український рецензований науково-практичний
спеціалізований журнал

№ 1 (56)
2024

Головний редактор В.І. Петренко

Журнал зареєстровано та індексується в міжнародних наукометричних системах і спеціалізованих каталогах Scopus, Index Copernicus, Google Scholar, Ulrich's Periodicals Directory, Scientific Indexing Services, ResearchBib, ICMJE, Polska Bibliografia Naukowa, CrossRef, 1findr, Dimensions, Scilit, Lens, Microsoft Academic, Naver, BASE, WorldCat, EuroPub, Sciencegate, OUCI, NLM Catalog, Research4Life, KOAR, Wizdom.ai, ReadCube, Semantic Scholar, LibKey

Журнал внесено до загальнодержавних баз даних «Україніка наукова», «Наукова періодика України» Національної бібліотеки України імені В.І. Вернадського

Матеріали публікуються в УРЖ «Джерело»

Подяка

Журнал опубліковано завдяки щирій підтримці американського народу, наданої Агентством США з міжнародного розвитку (USAID) шляхом фінансування проєкту «Підтримка зусиль у протидії туберкульозу в Україні»

Зміст журналу є відповідальністю видавця та не обов'язково збігається з точкою зору USAID чи уряду Сполучених Штатів

**Tuberculosis
Lung Diseases
HIV Infection**

ЗАСНОВАНИЙ У ТРАВНІ 2010 РОКУ
ВИХОДИТЬ 4 РАЗИ НА РІК

КИЇВ // ПП «ІНПОЛ ЛТМ» // 2024 р.

ukrainian scientific
and practical journal

www.tubvil.com.ua

ТУБЕРКУЛЬОЗ ЛЕГЕНЕВІ ХВОРОБИ ВІЛ-ІНФЕКЦІЯ

український рецензований науково-практичний спеціалізований журнал

Реєстраційне свідоцтво

КВ № 16607-5079Р від 05.05.2010 р.

Засновники

Національний медичний університет
імені О.О. Богомольця
Приватне підприємство «ІНПОЛ ЛТМ»

Рекомендовано Вченою радою НМУ імені О.О. Богомольця

Протокол № 8 від 29.02.2024 р.

Журнал включено до Переліку
наукових фахових видань України
з медичних наук, в яких можуть
публікуватися результати дисертаційних
робіт на здобуття наукових ступенів
доктора наук, кандидата наук та ступеня
доктора філософії. Категорія «Б»
Наказ МОН України № 409 від 17.03.2020 р.

Видавець

Приватне підприємство «ІНПОЛ ЛТМ»
Свідоцтво суб'єкта видавничої справи
ДК № 5460 від 15.08.2017 р.

Комп'ютерна верстка та дизайн

Корженівська А. В.

Коректор

Теплюк В. М.

Періодичність

4 рази на рік

Друк

ТОВ «ПРО ФОРМАТ»
02166, Київ, вул. Кубанської
України, 45б, оф. 16
(код ЄДРПОУ 41438677)

Свідоцтво суб'єкта видавничої справи
ДК № 5942 від 11.01.2018 р.

Підписано до друку 04.03.2024 р.

Замовлення № 0124ТЛ

Ум. друк. арк. 12,78

Формат 60×84/8

Папір офсет. Друк офсет.

Наклад — 480 прим.

Адреса редакції та видавця

03179, м. Київ,
вул. Академіка Єфремова, 19а, оф. 3

Телефон (044) 298-00-60

E-mail: vitalpol3@gmail.com



Надруковано на безкислотному папері

РЕДАКЦІЙНА РАДА

Ботнару В. (Botnaru Victor)
(Chisinau, Moldova)

Голубовська О.А. (Київ)

Грищук Л.А. (Тернопіль)

Дужий І.Д. (Суми)

Зайков С.В. (Київ)

Коваль Г.Д. (Чернівці)

Костик О.П. (Львів)

Кузик П.В. (Київ)

Литвиненко Н.А. (Київ)

Мацегора Н.А. (Одеса)

Норейко С.Б. (Київ)

Островський М.М.

(Івано-Франківськ)

Процюк Р.Г. (Київ)

Разнатовська О.М. (Запоріжжя)

Ракішева А.С. (Алмати, Казахстан)

Рибак Н.Р. (Rybak N.R.)

(Род Айленд, США)

Сіренко І.О. (Харків)

Степаненко В.І. (Київ)

Тарасюк О.О. (Львів)

Тодоріко Л.Д. (Чернівці)

Фланіган Т.П.

(Flanigan Timothy P.)

(Провіденс, США)

Хоффнер С.

(Hoffner Sven)

(Стокгольм, Швеція)

Шевченко О.С. (Харків)

Яременко Л.М. (Київ)

НАУКОВІ РЕДАКТОРИ

Науковий редактор за тематикою «Фтизіатрія»

Тодоріко Л.Д. (pulmonology@bsmu.edu.ua)

Науковий редактор за тематикою «ВІЛ-інфекція»

Голубовська О.А. (ogolubovska@gmail.com)

Науковий редактор за тематикою «Ппульмонологія»

Норейко С. Б. (normans@meta.ua)

Секретар Бондаренко Ярослава (bondarenko1yaroslava@gmail.com)

Відповідальність за зміст, добір та викладення фактів у статтях несуть автори.

До друку приймаються наукові матеріали, які відповідають вимогам до публікацій у цьому виданні.

Видання призначене для фахівців галузі охорони здоров'я.

© 2024 Національний медичний університет імені О.О. Богомольця,
<https://nmuofficial.com>

© 2024 Приватне підприємство «ІНПОЛ ЛТМ»,
www.vitalpol.com.ua

Журнал опубліковано завдяки щирій підтримці американського народу,
наданої Агентством США з міжнародного розвитку (USAID).

Зміст журналу є відповідальністю видавця та не обов'язково збігається
з точкою зору USAID чи уряду Сполучених Штатів.

- 58 A Study of the Effect of Specific Antibacterial Therapy on the Course of Tuberculous Spondylitis in an Experiment
Н.Н. Holka, V.V. Vesnin, V.V. Burlaka, A.O. Oliynyk, O.H. Fadeev, O.V. Hoptsi, E.Yu. Frolova-Romaniuk
Дослідження впливу специфічної антибактеріальної терапії на перебіг туберкульозного спондиліту в експерименті
Г.Г. Голка, В.В. Веснін, В.В. Бурлака, А.О. Олійник, О.Г. Фадєєв, О.В. Гопцій, Е.Ю. Фролова-Романюк
- 67 Вплив коронавірусної інфекції на результати черезшкірного коронарного втручання в пацієнтів з ішемічною хворобою серця
Г.Б. Маньковський, М.В. Кучерява
The Influence of Coronavirus Infection on the Results of Percutaneous Coronary Intervention in Patients with Coronary Artery Disease
G.B. Mankovsky, M.V. Kucheriava
- 72 Динаміка тиску в правому шлуночку під час стрес-ехокардіографії у пацієнтів, які мають серцеву недостатність зі збереженою фракцією викиду лівого шлуночка
Є.Ю. Марушко, Н.М. Руденко, Я.Ю. Джунь
Dynamics of Right Ventricle Pressure During Stress Echocardiography in Patients with Heart Failure with Preserved Ejection Fraction
Ye.Yu. Marushko, N.M. Rudenko, Ya.Yu. Dzhun

ВИПАДОК З ПРАКТИКИ / CASE OF PRACTICE

- 78 Difficulties in Diagnosing of Pancreatic Cancer in HIV Infection with Generalised Lymphadenopathy: Tuberculosis, Non-Tuberculosis Mycobacterial Infection or Metastases (Clinical Case)
О.М. Raznatovska, V.I. Petrenko, O.S. Shalmin, R.M. Yasinskyi, A.V. Fedorec, A.O. Svitlitsky, O.A. Svitlytska
Складнощі діагностики раку підшлункової залози при ВІЛ-інфекції з генералізованою лімфаденопатією: туберкульоз, нетуберкульозна мікобактеріальна інфекція чи метастази (клінічний випадок)
О.М. Разнатовська, В.І. Петренко, О.С. Шальмін, Р.М. Ясінський, А.В. Федорець, А.О. Світлицький, О.А. Світлицька
- 86 Диференційна діагностика синдрому легень, що зникають, при лімфангіолейоміоматозі та COVID-19 пневмонії за допомогою цифрової програмної обробки даних комп'ютерної томографії (клінічні випадки)
М.І. Линник, І.В. Ліскіна, В.І. Ігнат'єва, Г.Л. Гуменюк, В.А. Святненко, О.П. Чоботар, О.К. Яковенко
Differential Diagnostics of the Disappearing Lung Syndrome in Lymphangiomyomatosis and COVID-19 Pneumonia Using Digital Software Processing of Computer Tomography Data (Clinical Cases)
M.I. Lynnyk, I.V. Liskina, V.I. Ignatieva, G.L. Gumeniuk, V.A. Svyatnenko, O.P. Chobotar, O.K. Yakovenko

ОГЛЯДИ / REVIEWS

- 95 Сучасні напрями оптимізації емпіричної антимікробної терапії негоспітальної пневмонії (огляд літератури)
М.В. Хайтович, Д.В. Турчак, В.В. Уліщенко, В.Ю. Рафальський
Modern Directions of Optimization of Empirical Antimicrobial Therapy of Community-Acquired Pneumonia (Review)
M.V. Khaitovych, D.V. Turchak, V.V. Ulishchenko, V.Yu. Rafalskyi
- 103 Сучасні особливості епідеміологічної ситуації з туберкульозу в Україні (огляд)
Ю.М. Валецький, В.О. Ничипорук, Р.О. Валецька
Modern Features of the Epidemiological Situation of Tuberculosis in Ukraine (Review)
Yu.M. Valetskyi, V.O. Nychyporuk, R.O. Valetska

ДО УВАГИ АВТОРІВ / INFORMATION FOR AUTHORS

- 109 Умови публікації в журналі «Туберкульоз, легеневі хвороби, ВІЛ-інфекція»
Submitting articles to the journal «Tuberculosis, lung diseases, HIV infection»



H.H. Holka, V.V. Vesnin, V.V. Burlaka, A.O. Oliynyk,
O.H. Fadeev, O.V. Hoptsii, E.Yu. Frolova-Romaniuk
Kharkiv National Medical University, Kharkiv, Ukraine

A Study of the Effect of Specific Antibacterial Therapy on the Course of Tuberculous Spondylitis in an Experiment

Objective — to assess the impact of modern antibacterial therapy on the development of a specific destructive process in experimental tuberculous spondylitis in animals.

Materials and methods. The experiments were conducted on 40 sexually mature guinea pigs (age over 6 months) with an average weight of 350–500 grams. Tuberculous spondylitis was induced using a proprietary method (Patent No. 112423 (UA) Ukraine).

All experimental animals were divided into 4 equal groups. Groups 1–3 (main groups) received an injection of 0.5 ml of *M. tuberculosis* suspension (0.1 mg of dry weight in 1 ml) into the body of the vertebra, according to the specified method. Group 4 served as the control, receiving an injection of sterile physiological solution (0.9 % NaCl, 0.5 ml) into the vertebra.

Specific first-line antibacterial drugs (ABDs) consisting of isoniazid, streptomycin, and rifampicin were administered to Group 1, which consisted of 10 guinea pigs. Group 2, also comprising 10 guinea pigs, received specific second-line ABDs, including amikacin, rifabutin and ofloxacin. Groups 3 and 4, each consisting of 10 guinea pigs, received no treatment.

Results and discussion. The morphological analysis revealed the presence of an active tuberculosis process in the vertebral bodies and paravertebral tissues of animals subjected to tuberculosis simulation, regardless of whether they received specific first-line ABD treatment or not. Notably, the severity of destructive changes in affected vertebrae was similar between untreated animals and those treated with first-line ABDs.

Animals modeled for tuberculosis and treated with specific second-line ABDs exhibited a suppression of the pathological process. This was evidenced by the formation of immature bone and connective tissue to varying degrees, along with the presence of a delineating zone separating the inflammatory focus from healthy tissue in the early stages of the disease (one month).

Conclusions. Based on the histological examination of the vertebral bodies, it was established that the animals treated with specific first-line ABD showed clear morphological features of tuberculous inflammation. In animals treated with specific second-line ABD, inhibition of the pathological process.

This study showed that the implementation of modern intensive specific antibacterial therapy in experimental conditions allows to achieve the delimitation of the destructive process in the relatively early stages of the disease development (4–5 weeks).

The obtained new knowledge about the pathomorphological features of the course of TS against the background of carrying out specific antibacterial therapy allows radical surgical interventions on the musculoskeletal system without the risk of generalization of the tuberculosis process at an earlier time (compared with the generally accepted ones).

Keywords

Experimental modeling of tuberculous spondylitis, antibacterial therapy.

At the current stage, Ukraine belongs to the group of countries with a high incidence rate of tuberculosis and has a significantly higher incidence rate than in the vast majority of Central and Eastern European countries [1, 10].

According to epidemiological surveillance data, the incidence rate of tuberculosis in Ukraine is 45.1 per 100,000 population. In 15 regions of our country, there is an increase in the incidence of tuberculosis [1].

In the conditions of the current epidemiological situation in Ukraine, bone and joint tuberculosis (BJT) occupies the first place in the structure of the incidence and morbidity of extrapulmonary tuberculosis, and in the structure of the total incidence of tuberculosis, extrapulmonary localizations account for 10.6 % [1, 5, 10].

In turn, the specific weight of tuberculous spondylitis (TS) in BJT in adults takes the leading place and reaches 40.0–61.5 % [7, 20, 21]. The main manifestations of a specific inflammatory process in the spine are the destruction of the vertebrae, resulting in a violation of the stability of the spine, development of its deformations, chronic back pain. In 40–75 % of cases, infectious inflammatory diseases of the spine occur with neurological complications of varying degrees of severity, presence of overflow abscesses, fistulae [4, 7, 12, 15, 19].

In the scientific literature, the topic of experimental pulmonary tuberculosis is presented quite widely both in domestic specialised literature and especially in foreign literature, but the issue of experimental bone and joint tuberculosis is presented only in isolated publications [13, 14, 17].

The world priority in experimental modeling of BJT rightfully belongs to the Leningrad Institute of Tuberculosis Surgery. Until now, the works of P.G. Kornev and E.M. Belendir, known worldwide, are devoted to the study of BJT development using experimental models of this disease in animals [2, 6, 9].

It is important to note that the vast majority of experimental studies on BJT, both in the Commonwealth of Independent States (CIS) countries and abroad, were conducted long before a clear understanding of BJT development and in the pre-antibacterial era of medicine. The majority of known experimental tuberculosis models are based on the intravenous hematogenous introduction of *Mycobacterium tuberculosis*. In our opinion, this approach hinders the full reproduction of the prespondylitic stage of the disease development [6, 1].

At the same time, during a literature search on the Internet over the past 15 years, we managed to find only a few publications devoted to the study of BJT in experimental conditions, which in their main

mass relate to issues of diagnosis or the development of certain types of surgical intervention [13, 16, 18].

Fundamentally important, in our opinion, is the lack of experimental studies in the world scientific literature dedicated to the study of the impact on the destructive specific tuberculous inflammatory process of the spine, not only of modern antibacterial antituberculosis drugs, which have been introduced into the treatment standards over the past decades (amikacin, rifabutin, ofloxacin), and those that were used in clinical practice at the end of the last century. The only exception is the study of the effect of streptomycin on the course of tuberculous inflammation of the musculoskeletal system, conducted by O.P. Skoblin in 1953 [7].

Objective – to assess the impact of modern antibacterial therapy on the development of a specific destructive process in experimental tuberculous spondylitis in animals.

Materials and methods

The research was conducted on the basis of Kharkiv Institute of Experimental and Clinical Veterinary Medicine of the National Academy of Agrarian Sciences of Ukraine. Experiments were conducted on 40 sexually mature (more than 6 months) guinea pigs (average weight 350–500 g). The protocol of the experiment on animals was approved by the Commission on Bioethics of Kharkiv National Medical University, in accordance with the rules of the European Convention for the Protection of Vertebrate Animals Used for Experimental and Other Scientific Purposes.

When comparing the structure of the spine, according to the literature, the shape and size of guinea pig vertebrae differ from those of humans, but the general plan of the anatomical structure of the spine is similar [3]. The choice of animals is also due to high susceptibility to *Mycobacterium tuberculosis*.

Modeling of tuberculous spondylitis was carried out on the basis of the method developed by us (Patent No. 112423 (UA) Ukraine) [8]. The basis of a useful model was the task of creating a model of tuberculous spondylitis as close as possible to the natural process based on its clinical and radiological features.

According to the useful model, the animal is immobilised and in a position on the right or left side, the skin in the area of the projection of the lumbar spine above the wing of the iliac bone is freed from fur and treated with an iodine solution, the operating field is separated with sterile napkins, and layer-by-layer external abdominal access is performed to the front-lateral surface of the bodies vertebrae of the L2–L4 segments by separating the muscles of the anterior abdominal wall and squeezing the parietal sheet of the peritoneum together

with the contents of the abdominal cavity to the medial side. After highlighting the anterior-lateral surface of the vertebral bodies, the segmental vessels are visualised, the latter are taken on holders from two sides, tied and cut, then a culture of mycobacteria tuberculosis of 0.5 ml suspension of *M. bovis* strain Valle is injected into the body of the vertebra under visual control with a syringe. Ligation of segmental vessels significantly impairs blood circulation in the vertebra, thereby creating favorable conditions for the development of a specific inflammatory process. The postoperative wound is sutured in layers, followed by dynamic clinical and radiological control until the appearance of clinical and radiological signs of tuberculous spondylitis.

All experimental animals were divided into 4 equal groups:

- Groups 1–3 (main) – an injection of 0.5 ml of *M. tuberculosis* suspension (0.1 mg of dry weight in 1 ml) into the body of the vertebra according to the method.
- Group 4 – control. The animals were injected with a sterile physiological solution (0.9 % – 0.5 ml) into the body of the vertebra.

Group 1 – 10 guinea pigs were treated with specific first-line antibacterial drugs (ABD) (isoniazid, streptomycin, rifampicin). Group 2 – 10 guinea pigs were treated with specific second-line antibacterial drugs (ABD) (amikacin, rifabutin, ofloxacin). Group 3, 4 with 10 guinea pigs in each received no treatment.

Specific ABDs were administered in dosages according to the weight of the animals (parenterally) every day.

The choice of the site of infection was due to the high frequency of > 50 % localization of primary osteitis in the subchondral zone of the body of the vertebral bone in TS patients.

Before the start of the experiment, the animals were examined for the presence of parasitic and infectious diseases, followed by the Mantoux reaction with 25 tuberculin units of *M. bovis* and *M. avium*. In all the selected animals, the results of the Mantoux reaction testified to the absence of immunity to tuberculosis, which means that these animals do not suffer from tuberculosis and have not suffered from it.

At the first stage of the experiment, 16 animals (4 from each group) were withdrawn from the experiment after the detection of signs of the spondylitic stage of tuberculous spondylitis (after 1 month). At the second stage, after the clinical and radiological spondylitic stage was detected, 16 animals were also killed. Removal from the experiment was carried out by overdose of ether.

Further on, we waited for the appearance of the post-spondylitic stage or remission of the disease,

but most animals in which TS was modeled died within 3 to 4 months. The cause of death of these animals, according to the results of the macroscopic examination at autopsy, was the generalization of the infectious process with subsequent damage to vital organs and systems.

We managed to obtain the post-spondylitic stage of the disease only in 2 guinea pigs of the second group, treated with specific second-line ABDs. Two guinea pigs of the control group were at the end of the experiment without any signs of an infectious process.

Dynamic observation of all animals was carried out with detailed clinical examination, weighing, examination of the function of the spine and lower limbs. During the clinical examination, the behavior, posture and nature of movement of the animals were taken into account.

X-ray examination was carried out according to indications from 3 to 5 times during the period of observation of an animal. Radiography of the spine was carried out when the guinea pig was fixed on a special machine and immobilized with xylazine (5 mg per 1 kg of animal weight). The structure of the vertebrae, the condition and size of the intervertebral discs, the presence of foci of destruction, their time course, and the condition of the paravertebral tissues were studied.

X-ray signs of tuberculous spondylitis included: deformation of the locking plates; narrowing of the intervertebral space due to the destruction of the intervertebral disc; wear of vertebrae; focal osteoporosis; wedge-shaped deformation of the vertebra; compression fractures.

All animals removed from the experiment were subjected to a pathomorphological examination.

Results and discussion

One month after infection, all animals of the main observation group had an average temperature increase of 0.5°, and at the same time, restriction of movement in the large joints of the lower limbs appeared and increased. The loss of body weight of the animals ranged from 20.0 to 40.0 g. Six guinea pigs developed overflow abscesses on the anterior and medial surface of the thigh. Development of abscesses could be a consequence of the destruction of the cortical layer near the focus of destruction, followed by the involvement of paravertebral tissues in the inflammatory process and the migration of necrotic masses through the muscles to the thigh. X-rays of the spine showed local osteoporosis, a focus of destruction with destruction of the subchondral zone was visible.

Subsequent observation of the experimental animals showed that in the future tubercular osteitis was formed and increased in size (only within the vertebra).

During the next 4–6 weeks, the symptoms of intoxication continued to increase (animal lethargy, decreased appetite), weight loss averaged 60 g. In some animals, thickening and infiltration of soft tissues were noted in the area of postoperative access, and paravertebral, flexion contracture was noted in the joints of the lower limbs. Severe lameness was detected, the limb of the animal was not loaded, it was pulled behind the trunk (Fig. 1). X-rays showed an increase in destructive foci, they occupied the entire vertebra with a transition to the adjacent segment. Cells of destruction contained sequestrations of different shapes and sizes (Fig. 2).

The removal of experimental animals from the experiment was carried out according to a previously developed schedule. Before euthanasia, the animals were carefully examined, and after it, blocks of segments of the lumbar spine that were affected by the destructive process were made, the obtained macro-specimens were subjected to radiography and pathomorphological examination, and pathomorphological studies of internal organs were also carried out.

Pathomorphological studies

Anatomical preparation and macroscopic examination of spinal specimens were carried out immediately after the animals were removed from the experiment. The condition of the spine, the musculoskeletal system, the presence of overflow abscesses was studied macroscopically, and macro-specimens of the vertebrae were made (Fig. 3).

For histological examination, guinea pig vertebrae and adjacent muscles were isolated and fixed in a solution with a mass fraction of 10 % neutral formalin. To study the inflammatory process in vertebrae, decalcification of bones was carried out in a solution with a mass fraction of nitric acid of 4 % at a temperature of 18 to 22 °C. Bones after decalcification and muscles adjacent to vertebrae were dehydrated in alcohols of increasing strength (50°, 70° alcohols and twice in 96°) and in alcohol with ether (1 : 1 solution), enclosed in celloidin. Histological sections were prepared on a Reichert sled microtome and stained with hematoxylin and eosin and Van Gieson. Histological analysis was performed using an Axio Star Plus light microscope (Carl Zeiss) using a Canon Power Shot A610 digital camera and the AxioVision computer software for photography.

During histological examination 1 month after modeling the inflammatory process, all animals clearly showed signs of inflammation (infectious process).

On histological specimens made from the lumbar spine of guinea pigs infected with mycobacterium tuberculosis and treated with a specific first-line



Fig. 1. Appearance of guinea pigs in the spondylitic phase of the disease

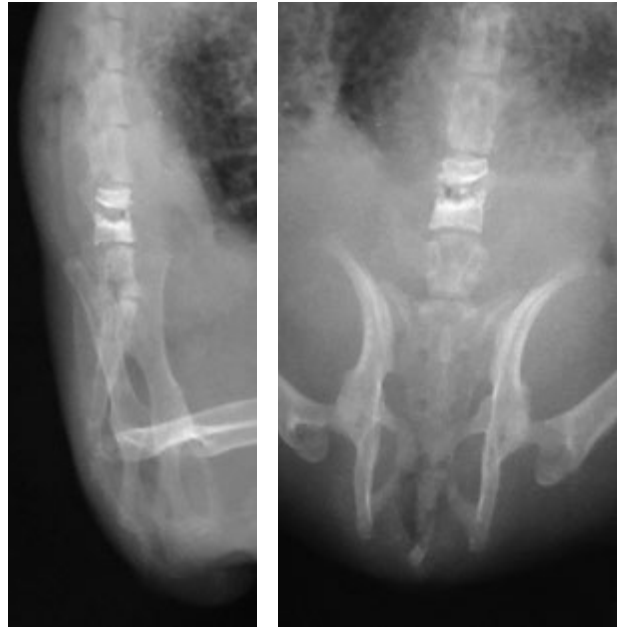

Fig. 2. X-ray of the spine. Contact destruction of vertebrae

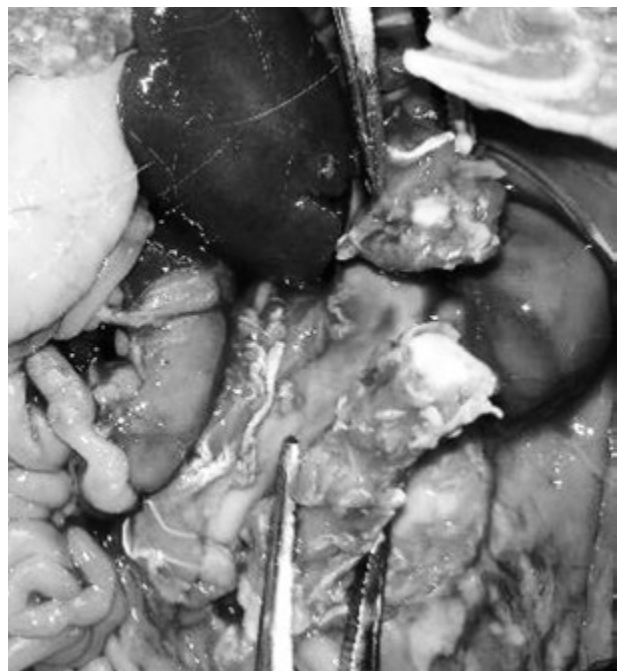


Fig. 3. Selection of a macro-specimen of segments of the lumbar spine affected by a specific destructive process

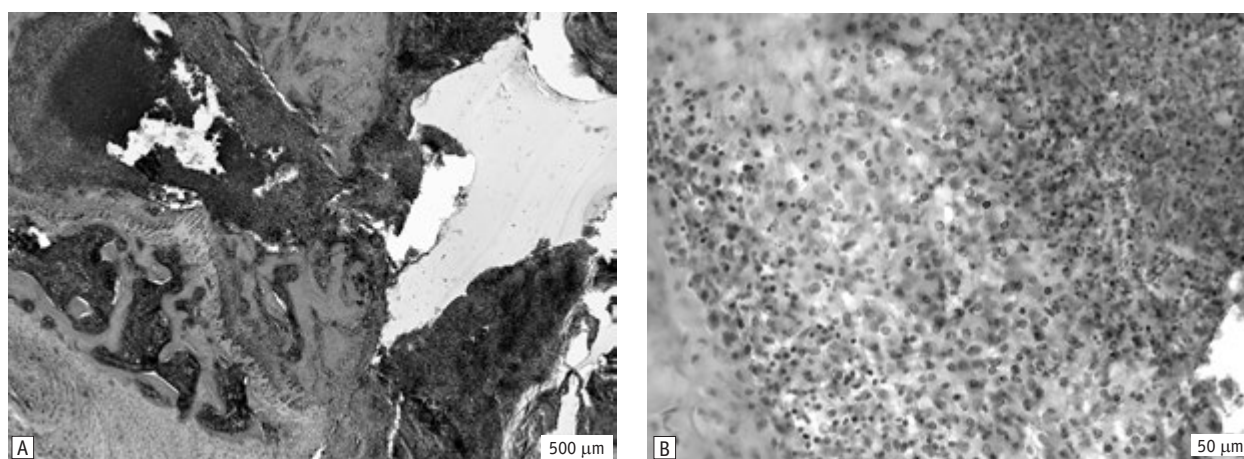


Fig. 4. Fragment of the body of a vertebra of the lumbar spine of a guinea pig after modeling tuberculosis and treatment with a specific first-line ABD

A — focus of a specific inflammatory process, destruction of the cortical layer; B — peripheral part of the necrotic tubercle, macrophages, lymphocytes, plasma cells. H&E stain.

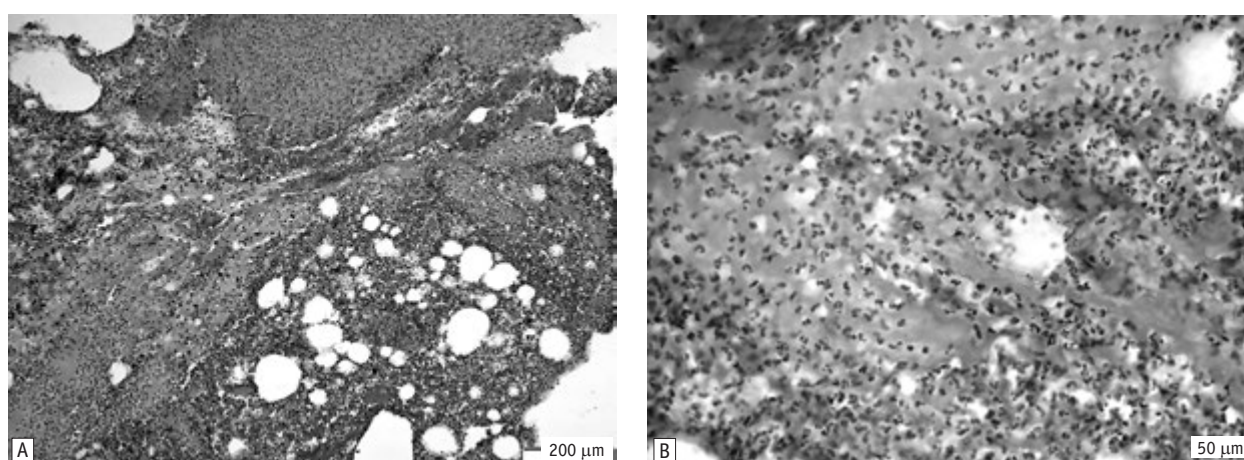


Fig. 5. Classic pathomorphological picture of bone tuberculosis

A — spread of the inflammatory process in the paravertebral soft tissues with the formation of an abscess; B — diffuse infiltration by leukocytes, caseous necrosis. H&E stain.

ABD, foci of a specific inflammatory process were found in the spongy tissue of the vertebral body, which was manifested by the formation of epithelioid (center — epithelioid cells) and necrotic (center — caseous necrosis). A shaft of epithelioid cells was found around the centers of the nodules, and further there were lymphocytes, macrophages, plasma cells, multinucleated Pirogov–Langhans giant cells (Fig. 4).

Spongy bone tissue with the presence of destructive changes was observed in the areas of the vertebral body. In places, it did not contain osteocytes, trabeculae had an uneven surface, foci of lacunar resorption, foci of homogeneous decay. The destruction of the epiphyseal cartilage zone, the cortical part of the vertebral body, with the spread of the inflammatory process into the soft tissues around the vertebra, namely into the periosteum, ligaments, and muscle tissue with the formation of an abscess,

was also noted. This is a characteristic sign of bone tuberculosis (Fig. 5).

After treating the animals with a specific second-line ABD microscopic analysis revealed changes characteristic of the subsidence of the inflammatory process. Sclerosis of trabeculae and cortex, formation of newly formed spongy bone tissue with a significant density of brightly colored osteocytes on the surface at the border with the affected area was observed. The cells did not form lacunae and contained large hyperchromic nuclei and basophilic cytoplasm. Reticulo-fibrous tissue was located in the intertrabecular spaces.

However, the restoration of the integrity of the vertebral body was not noted. In the area affected by his tubercular inflammation, after the action of a specific second-line ABD, connective tissue of various degrees of maturity was formed with a significant number of vessels of various diameters,

densely packed fibroblasts, and the presence of lymphoid and plasma cells.

Pathological changes when examined 1 month after TS modeling in the affected vertebrae of guinea pigs that did not receive specific ABDs were characterized by the following pattern: an examination of a section at the level of destruction revealed an infiltrate located subchondrally. Among the infiltrates there was a small necrotic focus with the presence of elements of decay.

Necrotic foci with granular disintegration of cellular elements of granulation tissue were found among the inflammatory infiltrate. Inflammatory swelling of the loose connective tissue was observed along with the infiltrate. Necrotic changes were observed in the subchondral bone at the border with the subchondral tuberculous focus described above in the bone beams.

In the tubercle, there was a high density of epithelioid cells, which have a characteristic structure, namely a small weakly basophilic nucleus surrounded by abundant cytoplasm.

In the intertrabecular spaces, the destruction of the bone marrow and the formation of foci of productive inflammation and epithelioid-cellular tubercles, which differed from each other, took place. Some of them did not contain all the elements of the tubercle. They were represented by epithelioid cells with light oval nuclei. A high density of lymphocytes, macrophages and fibroblasts was found in the peripheral parts of the tubercles. Plasma cells were solitary.

Thus, as a result of the morphological study, the presence of an active tuberculosis process in the vertebral bodies and paravertebral tissues was established in animals with simulated tuberculosis and treated with specific first-line ABD, as well as in animals that did not receive specific treatment.

It is important to note that the severity of destructive changes in the affected vertebrae in animals that were not treated and those that received first-line ABD were practically the same.

In animals that were modeled for tuberculosis and treated with specific second-line ABD, inhibition of the pathological process was observed. This was accompanied by the formation of young bone and connective tissue of varying degrees of maturity. Additionally, a zone separating the focus of inflammation from healthy tissue in the early stages of the disease (one month) was revealed (Fig. 6).

During the microscopic examination of the internal organs of animals that were modeled with TS and treated with specific first-line ABDs and untreated animals, pathological changes characteristic of the generalization of the tubercular pathological process were detected.

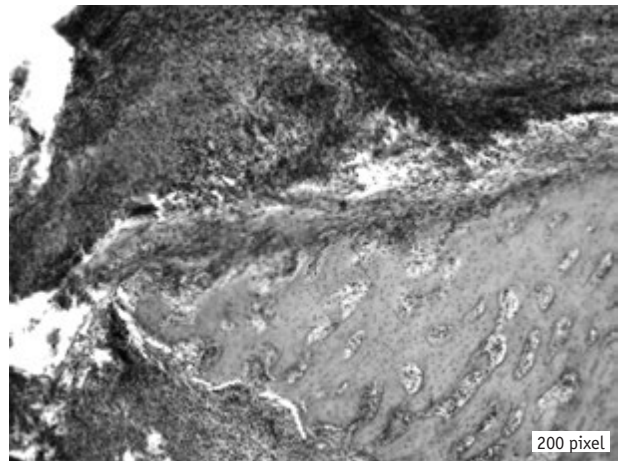


Fig. 6. A fragment of the vertebral body of the lumbar spine of a guinea pig after tuberculosis simulation and treatment with a specific second-line ABD. Newly formed bone tissue with a significant density of osteocytes. Visualization of the delimitation of the zone of a specific destructive process. Thickened periosteum. Connective tissue with foci of diffuse infiltration. H&E stain

A pathological examination of the lungs showed a violation of organization: the alveolar structure was not visible, desquamation of the epithelium was determined in the bronchioles and bronchi, their lumens were filled with fluid, and there were foci of lymphocytes and plasma cells in the peribronchial region. Productive specific inflammation was revealed. Multiple nodules with an epithelioid-cellular structure were observed in all fields of vision (Fig. 7A). Several layers of epithelioid cells, macrophages, lymphocytes and plasma cells were observed. Multinucleated Pirogov–Langhans cells were located between the epithelioid cells (Fig. 7B).

In contrast to animals with simulated tuberculosis treated with first-line drugs and untreated guinea pigs of the control group and in animals treated with second-line ABD, the alveoli were in a state of dystelectasis, partially expanded, filled with a small amount of fluid. Inter-alveolar crossbars were thin. Alveolocytes were located in one row on the basal membrane, had eosinophilic cytoplasm and a round small hyperchromic nucleus. Bronchioles had a folded inner shell with a cylindrical single-row epithelium, the nuclei were located on the basement membrane.

Summarising the observations of guinea pigs, we come to the conclusion that tuberculous spondylitis, confirmed clinically and pathohistologically, was obtained in all cases with this method of infection.

In our experiment, it was possible to trace the stages of the development of tuberculous spondylitis in guinea pigs and to correlate the phases of its evolution with the stages of the development of TS outlined in the generally accepted classification of E.M. Belendir [2] in accordance with the tasks.

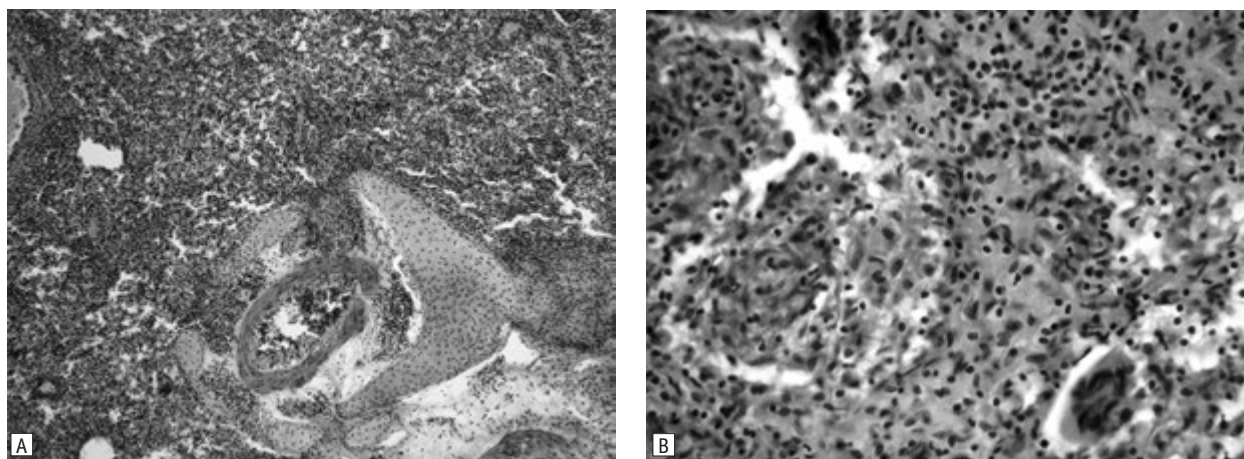


Fig. 7. Fragment of a guinea pig lung after modeling tuberculosis and treatment with the drug of the first group

A — absence of alveolar structure, productive specific inflammation; B — a productive epithelioid tubercle with a Pirogov-Langhans giant cell. H&E stain.

The identity of the model of tuberculosis of the spine in a guinea pig with the intravertebral method of infection with the main clinical forms of TS in humans was revealed: tuberculous osteitis developed up to 4 weeks (stage 1 according to the classification of E.M. Belendir), until 8–9 weeks the progression of ostitis with the onset of spondylitis was observed (stage 2 according to this classification) with subsequent spread of destruction to adjacent segments of the spine.

It should be noted that in our country no fundamental research is conducted regarding the features of the modern course of TS, its pathomorphological features. The latest Russian-language publications devoted to the experimental modeling of these diseases date back to the 1960s. There are practically no publications on TS modeling in the last 20 years in foreign literature.

In the studies of the leading specialists of LIHT, it is noted that violation of microcirculation around the lesion is the most important thing in the pathogenesis of tuberculosis, which plays a major role in the spread of infection, its localization in organs and tissues, in the very development and course of tuberculosis inflammation, that is, a violation of microcirculation plays a leading role in primary focal lesions of organs [2, 7, 11]. The manipulation of ligation of segmental vessels in guinea pigs was aimed at the disruption of microcirculation in the infection zone during the experiment, which allowed us to successfully implement the idea of creating an experimental model of TS in all experimental animals.

Conclusions

In our experiment, it was possible to trace the stages of the development of tuberculous spondylitis in guinea pigs and correlate the phases of its

evolution with the stages of the development of tuberculous spondylitis outlined in the generally accepted classification of E.M. Belendir in accordance with the tasks.

Based on the histological examination of the vertebral bodies, it was established that the animals treated with specific first-line ABDs showed clear morphological features of tuberculous inflammation. In animals treated with specific second-line ABDs, inhibition of the pathological process with the formation of young bone and connective tissue of various degrees of maturity was noted, but without restoration of the integrity of the vertebral body.

As a result of the microscopic examination of the internal organs of guinea pigs in animals with simulated tuberculosis in which the generalization of tuberculosis in the lungs occurred, a specific productive inflammation was found, the morphological features of which were the same in both groups.

The above indicates the low effectiveness of the antibacterial action of specific first-line ABDs, and the high efficiency of second-line ABDs, the lack of generalization of the tuberculosis process against the background of treatment with these drugs.

Thus, this study showed that the implementation of modern intensive specific antibacterial therapy in experimental conditions allows to achieve the delimitation of the destructive process in the relatively early stages of the disease development (4–5 weeks).

The obtained new knowledge about the pathomorphological features of the course of TB against the background of carrying out specific antibacterial therapy allows radical surgical interventions on the musculoskeletal system without the risk of generalisation of the tuberculosis process at an earlier time (compared with the generally accepted ones).

The authors declare no conflict of interest.

Participation of the authors: research concept and design — H.H. Holka, V.V. Vesnin; collection of material — V.V. Burlaka, A.O. Oliynyk; processing of the material — O.H. Fadeev, E.Yu. Frolova-Romaniuk; statistical data processing — V.V. Vesnin, O.V. Hoptsi; text writing — H.H. Holka.

References

1. Аналітично-статистичний довідник «Туберкульоз в Україні», 2022. ДУ «Центр громадського здоров'я Міністерства охорони здоров'я України», ДЗ «Центр медичної статистики Міністерства охорони здоров'я України». https://phc.org.ua/sites/default/files/users/user90/TB_surveillance_statistical-information_2022_dovidnyk.pdf.
2. Беллендир ЭН. Экспериментальная патология и хирургия внелегочного туберкулеза и ее клиническое значение. Хирургия внелегочного туберкулеза. Л.; 1983:13-27.
3. Бергхоф ПК. Мелкие домашние животные. Болезни и лечение. 2010. 224 с.
4. Внелегочный туберкулез: руководство для врачей. Под ред. АВ Васильева. СПб: Фолиант; 2000. 568 с.
5. Голка ГГ, Веснін ВВ, Бурлака ВВ, та ін. Оптимізація лікування пацієнтів із туберкульозним спондилітом. Ортопедия, травматология и протезирование. 2019;(1):19-24. doi: 10.15674/0030-59872019119-24.
6. Корнев ПГ. Хирургия костно-суставного туберкулеза: в 3-х ч.; АМН СССР. Ленинград: Медицина; 1971. 223 с.
7. Костно-суставной туберкулез. Под ред. ЮН Левашева, АЕ Гарбуза. М.: Медицина и жизнь; 2003. 294 с.
8. Патент 112423 (UA) Україна, МПК: G09B 23/28, G09B 25/00. Спосіб моделювання туберкульозного спондиліту. Веснін ВВ, Голка ГГ; заявник і патентовласник Харківський медичний національний університет. № у 2016 07946; заявл. 18.07.2016; опубл. 12.12.2016, Бюл. № 23.
9. Перельман МИ. Заглянем вперед... Туберкулез и болезни легких. 2011;12:3-4.
10. Феценко ЮІ, Мельник ВМ. Організація лікування хворих на туберкульоз. К.: Здоров'я; 2009. 488 с.
11. Чистович АН. Патологическая анатомия и патогенез туберкулеза. Л.: Медицина; 1973. 175 с.
12. Divya A, Shukla DP, Bahubali VH, et al. Consumption of spine by tuberculosis in the era of directly observed treatment, short-course and genomic diagnosis. Indian J Tuberc. 2021;68(1):73-9. doi: 10.1016/j.ijtb.2020.08.017.
13. Gotsulya AS, Zazhzharskiy VV, Davydenko PO, et al. Experimental simulation of tuberculosis and its features in rabbits under conditions of isoniazid and N'-(2-(5-((theophylline-7-yl methyl)-4-ethyl)-1,2,4-triazole-3-ylthio)acetyl)isonicotinohydrozide. Ukrainian Journal of Ecology. 2021;11(3):135-40. doi: 10.15421/2021_155.
14. Hunter L, Ruedas-Torres I, Agulló-Ros I, et al. Comparative pathology of experimental pulmonary tuberculosis in animal models. Frontiers in Veterinary Science. 2023;10. doi: 10.3389/fvets.2023.1264833.
15. Jain AK, Rajasekaran S, Jaggi KR, Myneedu VP. Tuberculosis of the Spine. J Bone Joint Surg Am. 2020;102(7):617-28. doi: 10.2106/JBJS.19.00001.
16. Khanna K, Sabharwal S. Spinal tuberculosis: a comprehensive review for the modern spine surgeon. Spine J. 2019;19(11):1858-70. doi: 10.1016/j.spinee.2019.05.002.
17. McMurray DN, Collins FM, Dannenberg AM Jr, Smith DW. Pathogenesis of experimental tuberculosis in animal models tuberculosis. Curr Top Microbiol Immunol. 1996;215:157-79. doi: 10.1007/978-3-642-80166-2_7.
18. Rodriguez-Takeuchi SY, Renjifo ME, Medina FJ. Extrapulmonary tuberculosis: pathophysiology and imaging findings. Radiographics. 2019;39(7):2023-37. doi: 10.1148/rg.2019190109.
19. Wang P, Liao W, Cao G, et al. Characteristics and management of spinal tuberculosis in tuberculosis endemic area of Guizhou Province: A retrospective study of 597 patients in a Teaching Hospital. Biomed Res Int. 2020;2020:1468457. doi: 10.1155/2020/1468457.
20. World Health Organization. Global Tuberculosis Report 2022. 2. TB disease burden. [Accessed on 12 December, 2022]. <https://www.who.int/teams/global-tuberculosis-programme/tb-reports/global-tuberculosis-report-2022/tb-disease-burden>.
21. Zaheen A, Bloom BR. Tuberculosis in 2020 — new approaches to a continuing global health crisis. N Engl J Med. 2020;382(14):e26. doi: 10.1056/NEJMp2000325.

Г.Г. Голка, В.В. Веснін, В.В. Бурлака, А.О. Олійник, О.Г. Фадєєв, О.В. Гопцій, Е.Ю. Фролова-Романюк
Харківський національний медичний університет

Дослідження впливу специфічної антибактеріальної терапії на перебіг туберкульозного спондиліту в експерименті

Мета роботи — вивчення впливу сучасної антибактеріальної терапії на розвиток специфічного деструктивного процесу при експериментальному туберкульозному спондиліті на тваринах.

Матеріали та методи. Експерименти були проведені на 40 статевозрілих (більше 6 міс) морських свинках (середня вага 350–500 грамів). Моделювання туберкульозного спондиліту проводилось на основі розробленого нами способу (Патент № 112423 (UA) Україна).

Усі дослідні тварини були розділені на 4 рівні групи. Групи 1–3 (основні) — проводилась ін'єкція 0,5 мл суспензії *M. tuberculosis* (0,1 мг сухої маси в 1 мл) у тіло хребця згідно з методикою. Група 4 — контрольна — тваринам виконувалась ін'єкція стерильного фізіологічного розчину (0,9 % — 0,5 мл) у тіло хребця.

У групі 1 (10 свинок) проводилося лікування специфічними антибактеріальними препаратами (АБП) першої лінії (ізоніазид, стрептоміцин, рифампіцин). У групі 2 (10 свинок) проводилося лікування специфічними АБП другої лінії (амікацин, рифабутин, офлоксацин). У групі 3, 4 (по 10 свинок) — не проводилося лікування.

Результати та обговорення. У результаті морфологічного дослідження встановлено наявність активного туберкульозного процесу в тілах хребців і паравертебральних тканинах у тварин із моделюваним туберкульозом і лікуванням специфічним АБП першої лінії, а також у тварин, що не приймали специфічного лікування. Важливо зазначити, що ступінь вираженості деструктивних змін у вражених хребцях у тварин не лікованих і тих, що приймали АБП першої лінії, практично однакові.

У тварин, яким моделювали туберкульоз і лікували специфічним АБП другої лінії, виявлено пригнічення патологічного процесу з утворенням молоді кісткової та сполучної тканини різного ступеня зрілості та наявністю зони, що відмежовує вогнище запалення від здорової тканини в ранні терміни захворювання (один місяць).

Висновки. На підставі гістологічного дослідження тіл хребців встановлено, що у тварин, яких лікували специфічним АБП першої лінії, виявлені яскраві морфологічні особливості туберкульозного запалення. У тварин, яких лікували специфічним АБП другої лінії, відмічено пригнічення патологічного процесу.

Дане дослідження показало, що проведення сучасної інтенсивної специфічної антибактеріальної терапії в умовах експерименту дає змогу досягти відмежування деструктивного процесу в порівняно ранні терміни розвитку захворювання (4–5 тиж).

Ключові слова: експериментальне моделювання туберкульозного спондиліту, антибактеріальна терапія.

Контактна інформація / Corresponding author

Голка Григорій Григорович, д. мед. н., проф., зав. кафедри травматології та ортопедії
<https://orcid.org/0000-0002-3741-8924>
61018, м. Харків, пров. Балакірева, 3-А
E-mail: gr_golka@ukr.net

Стаття надійшла до редакції / Received 08.01.2024.

Стаття рекомендована до опублікування / Accepted 02.02.2024.

ДЛЯ ЦИТУВАННЯ

- Holka HH, Vesnin VV, Burlaka VV, Oliynyk AO, Fadeev OH, Hoptsiy OV, Frolova-Romaniuk EYu. A Study of the Effect of Specific Antibacterial Therapy on the Course of Tuberculous Spondylitis in an Experiment. *Туберкульоз, легеневі хвороби, ВІЛ-інфекція*. 2024;1:58-66. doi: 10.30978/TB2024-1-58.
- Holka HH, Vesnin VV, Burlaka VV, Oliynyk AO, Fadeev OH, Hoptsiy OV, Frolova-Romaniuk EYu. A Study of the Effect of Specific Antibacterial Therapy on the Course of Tuberculous Spondylitis in an Experiment. *Tuberculosis, Lung Diseases, HIV Infection (Ukraine)*. 2024;1:58-66. <http://doi.org/10.30978/TB2024-1-58>. Ukrainian.