

# PRZEGLĄD LEKARSKI

ORGAN TOWARZYSTWA LEKARSKIEGO KRAKOWSKIEGO - ODDZIAŁU PTL

2016/73/Suplement 1

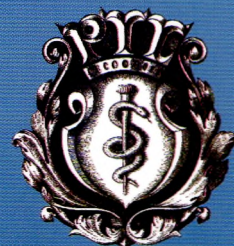rok  
założenia  
1862

**INTERNATIONAL  
MEDICAL**

STUDENTS' CONFERENCE  
Kraków, April 14th - 16th 2016



Czasopismo indeksowane:  
INDEX MEDICUS / MEDLINE  
Punktacja MNiSzW – 10  
INDEX COPERNICUS  
[ICV 2014: 80.95]  
POLSKA BIBLIOGRAFIA LEKARSKA



ISSN 0033-2240  
Wydawany od 1862 roku

**RADA NAUKOWA**

(Scientific Advisory Committee)

Prof. dr S. Angielski (Gdańsk)  
Dr hab. M. Barczyński (Kraków)  
Prof. dr A. Basta (Kraków)  
Prof. dr Z. Chodorowski (Gdańsk)  
Prof. dr S. Czekalski (Poznań)  
Prof. dr S. Cichoń (Kraków)  
Prof. dr J. Dubiel (Kraków)  
Prof. dr E. Florek (Poznań)  
Prof. dr T. Grodzicki (Kraków)  
Prof. dr T. Guzik (Kraków)  
Prof. dr P. Hirszel (Bethesda, USA)  
Prof. dr D. Karcz (Kraków)  
Prof. dr K. Kawecka-Jaszcz (Kraków)  
Prof. dr F. Kokot (Katowice)  
Prof. dr A. Krolewski (Boston, USA)  
Prof. dr A. Książek (Lublin)  
Prof. dr R. Kurzawa (Rabka)  
Prof. dr A. Kübler (Wrocław)  
Prof. dr T. Mach (Kraków)  
Prof. dr M. T. Małecki (Kraków)  
Prof. dr J. Musiał (Kraków)  
Prof. dr M. Mydlik (Košice, Slovak Republic)  
Prof. dr M. Myśliwiec (Białystok)  
Prof. dr E. Niżankowska-Mogilnicka (Kraków)  
Prof. dr W. Nowak (Kraków)  
Prof. dr W. Ostrowski (Kraków)  
Prof. dr M. Owecki (Poznań)  
Prof. dr J. Pach (Kraków)  
Prof. dr J. Pawłęga (Kraków)  
Prof. dr L. Paćzek (Warszawa)  
Prof. dr B. Rutkowski (Gdańsk)  
Prof. dr M. Rybakowa (Kraków)  
Prof. dr A. Skotnicki (Kraków)  
Prof. dr W. Szostak (Warszawa)  
Prof. dr K. Szyfter (Poznań)  
Prof. dr W. Tracz (Kraków)  
Prof. dr A. Urbanik (Kraków)  
Prof. dr J. Woy-Wojciechowski (Warszawa)

**Przewodniczący Rady Naukowej**

(President)

Prof. dr Tadeusz Popiela (Kraków)

**Z-ca Przewodniczącego**

**Rady Naukowej** (Vice-President)

Prof. dr Henryk Gaertner (Kraków)

**KOLEGIUM REDAKCYJNE**

(Editorial Board)

**Redaktor Naczelny** (Editor-in-Chief)

Prof. dr Władysław Sułowicz

**Z-ca Redaktora Naczelnego** (Vice-Editor)

Prof. dr Jacek Sieradzki

**Redaktor Działu** (Deputy-Editor)

Prof. dr Jerzy W. Naskalski

**Sekretarz Naukowy** (Scientific Secretary)

(Scientific Secretary)

Dr med. Katarzyna Krzanowska

**Sekretarz Techniczny**

(Technical Secretary)

Stanisława Uwer

Tel. +48 660 680 450

**Adres Redakcji** (Address)

31-501 Kraków, ul. Kopernika 15

Tel./Fax +48-12-421 88 66

e-mail: redakcja@wydplek.com.pl

www.wydplek.com.pl

**Punktacja Ministerstwa Nauki  
i Szkolnictwa Wyższego**

**za zamieszczenie publikacji naukowej: 10 pkt**

www.nauka.gov.pl

**Index Copernicus Value 2014 – 80.95**

http://journals.indexcopernicus.com

# PRZEGLĄD LEKARSKI

## 2016 / 73 / Supplement 1

### INTERNATIONAL MEDICAL STUDENT'S CONFERENCE

Kraków, April 14<sup>th</sup>-16<sup>th</sup> 2016

*Honorary Patronage*

*Vice-prime Ministers of Poland,  
Minister of Science and Higher Education  
Dr Jarosław Gowin*



Ministry of Science  
and Higher Education  
Republic of Poland

*Voivode of the Lesser Poland Voivodeship  
Mr Józef Pilch*



*Marshal of the Lesser Poland Voivodeship  
Mr Jacek Krupa*



**MAŁOPOLSKA**

*Rector of the Jagiellonian University  
Prof. Wojciech Nowak, MD, PhD*



JAGIELLONIAN UNIVERSITY  
IN KRAKÓW

*Vice-Rector of the Jagiellonian University for the Medical College  
Prof. Piotr Laidler, PhD*

*Representative of the Rector of the Jagiellonian University  
for Education and International Co-operation at the Medical College  
Prof. Beata Tobiasz-Adamczyk, PhD*

*Representative of the Rector of the Jagiellonian University  
for Research and Development at the Medical College  
Prof. Maciej Małecki, MD, PhD*

*Dean of Faculty of Medicine  
Prof. Tomasz Grodzicki, MD, PhD*

*Dean of Faculty of Pharmacy  
Prof. Jacek Sapa, PhD*

*Dean of Health Sciences Faculty  
Prof. Tomasz Brzostek, MD, PhD*

*Supervisors of Students' Scientific Society of the Jagiellonian University Medical College  
Prof. Tomasz Brzozowski, MD, PhD  
Prof. Tomasz Guzik, MD, PhD*

INTERNATIONAL  
MEDICAL  
STUDENT'S CONFERENCE

Kraków, April 14<sup>th</sup>-16<sup>th</sup> 2016

*Organizing Committee*

*Students' Scientific Society of the Jagiellonian University Medical College*

*President of the Student's Scientific Society: Anna Mydlowska*  
*Vice-President of the Student's Scientific Society: Mateusz K. Hołda*  
*Vice-President of the Student's Scientific Society: Helena Zwinczewska*  
*Treasurer: Magdalena Duchńska*

*Board:*  
*Kornelia Kliś*  
*Tomasz Nowak*  
*Jakub Hołda*  
*Daria Zwinczewska*  
*Kamil Tyrak*  
*Dawid Bugara*  
*Matthew Ficinski*  
*Katarzyna Borowiecka*  
*Katarzyna Roguska*  
*Natalia Mackiewicz*  
*Joanna Śladowska*  
*Sara Romanowska*  
*Agnieszka Stempniewicz*

*Session Coordinators:*

*Tomasz Nowak, Dorota Ławrynowicz, Natalia Mackiewicz, Karol Mystek, Klaudia Walocho, Arkadiusz Sulisz, Patrycja Pieczka, Matthew Ficinski, Aleksandra Mielimonka, Magdalena Bryndza, Magdalena Dębicka, Beata Adrianowicz, Agnieszka Stempniewicz, Zofia Loster, Kamila Migacz, Agnieszka Słowik, Małgorzata Koziol, Przemysław Pękala, Karolina Jaworska, Natalia Kutryba, Magdalena Górecka, Ewelina Rzucidło-Preizner, Paulina Dusińska, Tomasz Jaźwiecki, Tomasz Berger, Katarzyna Konarska, Paulina Godzisz, Kornelia Kliś, Paulina Donicz, Aleksandra Gładysz, Karolina Kainka, Palina Vyhouskaya, Noah John, Szymon Piecyk, Anna Tereszko, Anna Słowińska, Karolina Strojny, Konrad Janik, Paulina Wyszyńska, Zofia Wojciechowska*

*Workshops Coordinators:*

*Aleksandra Mielimonka, Magdalena Bryndza, Patrycja Jęda, Aleksandra Zajęc, Agata Suszyńska, Małgorzata Maraj, Aleksandra Gauden, Katarzyna Roguska, Agnieszka Gorycka, Ewelina Wojcieszak, Michał Furtak, Joanna Śladowska, Kornelia Kliś, Gustaw Roter, Natalia Mackiewicz, Piotr Płatek, Michał Szotek*

**Przegląd Lekarski jest czasopismem cytowanym przez EXCERPTA MEDICA i INDEX MEDICUS.**

**Streszczenia prac w języku angielskim znajdują się w bazie danych MEDLINE i CHEMICAL ABSTRACTS.**

**Przegląd Lekarski jest rejestrowany w bazie „Polska Bibliografia Lekarska Głównej Biblioteki Lekarskiej” ([www.gbl.waw.pl](http://www.gbl.waw.pl))**

**Warunki prenumeraty w roku 2016**  
**Prenumerata indywidualna**  
12 miesięcy: 100,00 zł (+8% VAT)  
**Prenumerata dla Instytucji**  
12 miesięcy: 250,00 zł (+8% VAT)  
**Prenumerata zagraniczna 100% droższa.**  
**Prenumeratę prosimy wpłacać dla:**  
Wydawnictwo Przegląd Lekarski  
31-501 Kraków, ul. Kopernika 15  
**konto:**  
**PKO BP I/O Kraków, ul. Wielopole 19**  
**Nr 05 102028920000510201416031**

Wszystkie artykuły zamieszczone w Przeglądzie Lekarskim nie mogą być kopiowane, tłumaczone bez pisemnej zgody Redakcji.

This journal is published by  
Wydawnictwo Przegląd Lekarski  
(Medical Review).

Recommended annual subscription rate:  
(12 issues and supplements)


**2016 year in Poland**  
Individuals: 100.00 zł (+ 8% VAT)  
Institutions: 250.00 zł (+ 8% VAT)  
Outside Poland subscription rate:  
additional 100%  
Supplements are included  
in the subscription.  
Subscriptions are entered  
with prepayment only.

**Orders should be addressed to:**  
Wydawnictwo Przegląd Lekarski  
31-501 Kraków, ul. Kopernika 15  
**Bank Account: Poland**  
**PKO BP I/O Kraków, ul. Wielopole 19**  
**Nr 05 102028920000510201416031**

All articles published in „Przegląd Lekarski” are protected by copyright, which covers the exposure rights to reproduce and distribute the articles, as well as all translation rights. No articles may be reproduced without first written permission from the publisher. Redakcja i Wydawca nie ponoszą odpowiedzialności za treść zamieszczonych ogłoszeń i reklam.

**Projekt okładki (Cover design)**  
Władysław Pluta

Wersją pierwotną czasopisma jest wersja papierowa.

**Wydawca (Editor)**  **Wydawnictwo Przegląd Lekarski**

31-501 Kraków, ul. Kopernika 15  
Tel./Fax: (+12) 421 88 66  
e-mail: [redakcja@wydplek.com.pl](mailto:redakcja@wydplek.com.pl)  
[www.wydplek.com.pl](http://www.wydplek.com.pl)  
Czasopismo specjalistyczne

Skład: DANBERT, Druk: Drukarnia GOLDRUK

### Embryo in bladder

**Authors:** Hanna Nebesna

**Tutors:** Oleksandra Dymnik MD, PhD, Natalya Kapustnik MD, PhD

**University:** Kharkiv National Medical University

**Introduction:** Genitourinary fistula is a pathologic track between the organs of reproductive and urinary systems. Vesicouterine fistula is a rare pathology, which is usually caused by trauma during lower segment cesarean section or uterine perforation during intrauterine procedures. Considering the increase of surgical interventions for last years, we find this question very actual.

**Case Description:** 42 years old woman was admitted to the hospital with complaints of lower abdominal pain, difficulty with urination, pink-colored urine. A woman was observed earlier in the antenatal clinic, where the 7th week of pregnancy and threatened abortion were diagnosed. At the time of admission to the hospital, the term of pregnancy was at 14 weeks of gestation, according to last menstruation. From medical history: two abortions and two cesarean sections were performed; a second operation (approximately 10 years ago) resulted in a bladder injury that was complicated by vesicouterine fistula. Conservative treatment was performed. During bimanual examination the uterus appeared to be enlarged up to 9 weeks of pregnancy, mobile, painless. In front of the uterus, a liquid-containing formation, 8 cm in diameter, with dense content was defined. US: uterus cavity was expanded and chorionic tissue was determined. In the area of postoperative scar on the anterior wall of the uterus, hypoechoic site that connected the uterus with bladder was visualized. A deformed fetus at 11 weeks, without heartbeat was visualized in the bladder. Cystoscopy: embryo, fragments of amniotic membranes and the umbilical cord fragments were visualized in the cavity of the bladder. A hole with saped borders was located on the posterior wall of the bladder. Supravaginal uterine amputation, embryo removal and plastic surgery of the bladder were conducted.

**Conclusion:** Well-timed diagnosis and choice of optimal treatment method will prevent such complications as vesicouterine fistulas. Since conservative management of this disease is not always effective, surgery remains the main method of treatment. Women in reproductive age with genitourinary fistulas in history, should be consulted by the urologist during the pregravid preparation.

**Keywords:** cesarean section, vesicouterine fistula, pregnancy

### Appendectomy in pregnant woman- a case report

**Authors:** Magdalena Görecka, Ewelina Rzucidlo, Aleksandra Cora

**Tutors:** Małgorzata Radon-Pokracka MD, PhD

**University:** Jagiellonian University

**Introduction:** Appendectomy is one of the most common surgical procedures in pregnant. The frequency of the appendicitis during pregnancy range from 0,1 to 0,3%. Symptoms of the appendicitis in pregnant women are not typical and often delayed diagnosis. Treatment of choice is appendectomy by laparotomy or laparoscopy depending on surgeon's skills or technical conditions. Performing these procedures before the end of the first trimester may be associated with higher risk of miscarriage or congenital malformation.

**Case Description:** Presented case refers to 30-years-old pregnant woman admitted to the maternity ward in 28th week of gestation due to symptoms of acute abdomen - the patient underwent appendectomy in 25 week of gestation. Possible obstetric complication was excluded and after the surgical consultation, the relaparotomy was performed. During the intervention, the space after appendix and the omentum was found to be inflamed. Necrotic changed tissues were excised and the drain was applied. Postoperative course proceed without surgical and obstetric complications. The pregnancy was ended by the cesarian section in 37 week of gestation.

**Conclusion:** The following case shows that there are possible unusual and rare complications after the routine surgical procedure in pregnant. But it also indicates that the treatment can be safe for the fetus.

**Keywords:** pregnancy, appendectomy, relaparotomy, appendicitis

### Cardiac surgery in pregnant woman - a case report

**Authors:** Magdalena Görecka, Ewelina Rzucidlo, Artur Mysiński

**Tutors:** Małgorzata Radon-Pokracka MD, PhD

**University:** Jagiellonian University

**Introduction:** The incidence of cardiac tumours is very rare (3:100000). Early diagnosis of this pathology is very difficult because of lack of characteristic symptoms. The presence of cardiac tumours in a pregnant woman is a challenge for both the cardiothoracic surgeons and obstetricians due to lack of medical guidelines.

**Case Description:** The case described refers to a 29-years-old pregnant woman, in whom in the 13th week of gestation a surgery to remove the tumour of the atrium was performed. The procedure was conducted in the extracorporeal circulation without any adverse effects on fetus. It was the second cardiac surgery for the patient because in childhood she went through an intervention of closing interatrial septum defect. Then the pregnancy was uncomplicated and the patient gave birth in the 36th week of gestation. The procedure was performed by caesarean section due to fetal asphyxia. The postoperative period after the procedure was uneventful and the patient was discharged home in good general condition. The newborn, apart from the typical disorders associated with prematurity, revealed no deviations in norm.

**Conclusion:** This case shows there is possibility to perform difficult cardiothoracic procedures from the second trimester without adverse effects on fetus.

**Keywords:** pregnancy, cardiac tumour, tumour of the atrium, cardiothoracic surgery

### Subcapsular hematoma of the liver in the HELLP syndrome - a case report

**Authors:** Wojciech Bednarz, Anna Modrzyńska, Joanna Rypel

**Tutors:** Małgorzata Radon-Pokracka MD, PhD, Prof. Huber Huras MD, PhD

**University:** Jagiellonian University Medical College

**Introduction:** HELLP syndrome is a severe pregnancy complication - it occurs in approximately 1% maternity cases with diagnosed hypertension. This syndrome is characterized by the presence of 3 symptoms: hemolytic anemia, elevated liver enzymes and low platelets. As a result, it may lead to the formation of subcapsular hematoma or even liver rupture. Treatment in this case is extremely difficult and requires the cooperation of specialists in many fields of medicine.

**Case Description:** We present a case of 36-year-old woman in the 37th week of her third pregnancy admitted to the Department of Obstetrics and Perinatology CMUJ. The patient suffered from severe colic pain under the right costal arch. Medical history data revealed gestational diabetes and gestational hypertension. Laboratory tests showed features of HELLP syndrome. Heterogeneous, hypoechoic findings in the liver were detected in ultrasonography rising suspicion of subcapsular haematoma. An emergency caesarian section in general anaesthesia was performed. The newborn's general condition was good. Hematoma was provided by usage of the drain and TachoSil - sponge containing fibrinogen and thrombin. The patient in the early postoperative period has been hospitalized in Intensive Care Unit for 9 days and later in Maternity Ward. The patient was discharged home with the recommendation of surgical consultation after puerperium because of two stable, asymptomatic hematomas.

**Conclusion:** This case is an example of cooperation of physicians with many specializations. The hemorrhage was controlled by a new method of conservative therapy - TachoSil. After almost 3 weeks of hospitalization a patient of interdisciplinary team could be discharged home. No permanent complications for neither the mother nor the neonate occurred.

**Keywords:** liver haematoma, pregnancy, HELLP syndrome