

## **CLINICAL CASE OF ACUTE CHORD RUPTURE OF THE MITRAL VALVE POSTERIOR LEAFLET IN OLDER PATIENT WITH COMORBIDITIES**

Zhuravlyova Larysa Volodymirivna, MD, Professor, Head of Department of Internal Medicine № 3, Kharkiv National Medical University, Department of Internal Medicine № 3, Lenina avenue 4, Kharkiv 61022, Ukraine.

[l.zhuravlyova@mail.ru](mailto:l.zhuravlyova@mail.ru)

Lopina Nataliia Andreevna, graduate student, Kharkiv National Medical University, Department of Internal Medicine № 3, Lenina avenue 4, Kharkiv 61022, Ukraine.

[alamajor@yandex.ua](mailto:alamajor@yandex.ua)

Kuznetsov Igor Volodymirovich, MD, Head of Cardiology Department Kharkiv Regional Hospital, Pravda Avenue 13, Kharkiv 61058, Ukraine.

[kuznetsov\\_i\\_v@mail.ru](mailto:kuznetsov_i_v@mail.ru)

Lopin Dmytro Oleksandrovich, doctor of ultrasound diagnostics department, GI “V.T. Zaicev Institute of General and Urgent Surgery”, 1, Balakireva vjezd, Kharkiv, 61103, Ukraine.

[doctorlopin@yandex.ru](mailto:doctorlopin@yandex.ru)

Kramarenko Irina Anatolievna, Head of ultrasound diagnostics department, Kharkiv Regional Hospital, Pravda Avenue 13, Kharkiv 61058, Ukraine.

Sumanova Irina Anatolievna, doctor of ultrasound diagnostics department, GI “V.T. Zaicev Institute of General and Urgent Surgery”, 1, Balakireva vjezd, Kharkiv, 61103, Ukraine.

### **ABSTRACT**

The article describes the etiologic role of the various factors such as chronic rheumatic heart disease, bacterial endocarditis, aortic valve stenosis, hypertension, coronary heart disease, including acute myocardial infarction, degenerative disease of the valves, connective tissue diseases, chest trauma, systemic lupus erythematosus, congenital heart disease which leading to the mitral valve chords rupture, gives the current classification of the nosology and also features of manifestation and clinical course. Also described a clinical case of mitral valve posterior leaflet chord rupture of patient with hypertension, ischemic heart disease and chronic obstructive pulmonary disease, which reflects all the stages of diagnostic search and the difficulties encountered in making the diagnosis, analyzed the basic concepts of medical and surgical treatment, features the choice of treatment strategy depending on the degree of mitral valve insufficiency.

**Keywords:** chord rupture; congestive heart failure; mitral valve insufficiency.

## **КЛИНИЧЕСКИЙ СЛУЧАЙ ОСТРОГО ОТРЫВА ХОРДЫ ЗАДНЕЙ СТВОРКИ МИТРАЛЬНОГО КЛАПАНА У ПОЖИЛОЙ ПАЦИЕНТКИ С КОМОРБИДНОСТЬЮ**

Журавлёва Лариса Владимировна, д.м.н., профессор, заведующая кафедрой внутренней медицины № 3

Харьковский национальный медицинский университет, кафедра внутренней медицины № 3, проспект Ленина 4, г. Харьков, 61022, Украина.

[l.zhuravlyova@mail.ru](mailto:l.zhuravlyova@mail.ru)

Лопина Наталия Андреевна, аспирант кафедры внутренней медицины № 3, Харьковский национальный медицинский университет, кафедра внутренней медицины № 3, проспект Ленина 4, г. Харьков, 61022, Украина.

[alamajor@yandex.ua](mailto:alamajor@yandex.ua)

Кузнецов Игорь Владимирович, к.м.н., заведующий кардиологическим отделением, КУОЗ «Харьковская областная клиническая больница – центр экстренной медицинской помощи и медицины катастроф», проспект Правды 13, г. Харьков, 61058, Украина.

[kuznetsov\\_i\\_v@mail.ru](mailto:kuznetsov_i_v@mail.ru)

Лопин Дмитрий Александрович, врач ультразвуковой диагностики, Институт общей и неотложной хирургии им. В.Т. Зайцева, въезд Балакирева, 1, г. Харьков, 61103, Украина.

[doctorlopin@yandex.ru](mailto:doctorlopin@yandex.ru)

Крамаренко Ирина Анатольевна, заведующий отделением ультразвуковой диагностики, КУОЗ «Харьковская областная клиническая больница – центр экстренной медицинской помощи и медицины катастроф», проспект Правды 13, г. Харьков, 61058, Украина.

Суманова Ирина Анатольевна, врач ультразвуковой диагностики, Институт общей и неотложной хирургии им. В.Т. Зайцева, въезд Балакирева, 1, г. Харьков, 61103, Украина.

### **АННОТАЦИЯ**

В статье рассмотрена этиологическая роль различных факторов возникновения отрыва хорды митрального клапана таких как хроническая ревматическая болезнь сердца, бактериальный эндокардит, стеноз клапана аорты, артериальная гипертензия, ишемическая болезнь сердца, в том числе острый инфаркт миокарда, дегенеративная болезнь клапанов, заболевания соединительной ткани, травма грудной клетки, системная красная волчанка, врожденные пороки сердца, приведена существующая классификация данной нозологии, а также особенности манифестации и клинического течения. Также

описан клинический случай отрыва хорды задней створки митрального клапана у пациента с артериальной гипертензией, ишемической болезнью сердца и хронической обструктивной болезнью лёгких, отражающий все этапы диагностического поиска и трудности, возникшие при постановке диагноза, проанализированы основные концепции медикаментозного и оперативного лечения, особенности выбора лечебной тактики в зависимости от степени недостаточности митрального клапана.

**Ключевые слова:** отрыв хорды; сердечная недостаточность; недостаточность митрального клапана.

### Introduction

Rupture of the chordae tendineae of the mitral valve was first described by Corvisart in 1806 in patient with endocarditis. Since that time has been described many cases of chords ruptures and related to it severe mitral regurgitation and progression of heart failure [9, 573; 10, 253]. Chordal rupture complicate chronic rheumatic valvular disease (mostly during the chronic stage) [1, 134; 6, 121], bacterial endocarditis on both normal and rheumatic valves [2, 297; 6, 121], degenerative mitral valve disease, ischemic heart disease, acute myocardial infarction, non-mitral heart and valvular abnormalities (such as aortic stenosis and aortic regurgitation), it may be in patients with systolic hypertension [5, 978; 8, 77], systemic or generalized connective tissue abnormality (Marfan's and the Ehlers-Danlos syndromes, osteogenesis imperfect), after blunt chest trauma or surgery [12, 257], in patient with systemic lupus erythematosus, congenital heart disease, hypertrophic obstructive cardiomyopathy [11, 259], systolic click-late systolic murmur (mitral valve prolapse) syndrome and in association with pregnancy. Acute mitral regurgitation resulting from rupture of chordae tendineae has also been reported in those who engage in vigorous exercises [3, 256] (Table 1).

Table 1. Predisposing factors of chord ruptures.

Chronic rheumatic valvular disease
Bacterial endocarditis (on both normal and rheumatic valves)
Degenerative mitral valve disease (local myxomatous degeneration)
Non-mitral heart and valvular abnormalities (such as aortic stenosis and aortic regurgitation)
Ischaemic heart disease
Acute myocardial infarction
Systemic or generalized connective tissue abnormality: <ul style="list-style-type: none"> <li>• Marfan's and the Ehlers-Danlos syndromes</li> <li>• Osteogenesis imperfect</li> </ul>
Blunt chest trauma or surgery
Systemic lupus erythematosus

Congenital heart disease
Hypertrophic obstructive cardiomyopathy
Systolic click-late systolic murmur (mitral valve prolapse) syndrome
Pregnancy
Systolic hypertension
Vigorous exercises

So, rupture of the chordae tendineae can be spontaneous (without causes) and secondary. Patients with spontaneous rupture are predominately among men older than 50 years, and is rare in young adults and children. The etiological basis of spontaneous chordal rupture is still unclear, but it probably results from abnormalities of collagen synthesis and degradation. Isolated posterior rupture of the mitral valve occur more frequently than anterior one. There are a higher incidence of spontaneous ruptured chordae of the posterior leaflet. Rarely, ischemic heart disease is associated with chordal rupture. Acute myocardial infarction results in papillary muscle dysfunction, less frequently, papillary muscle rupture. The papillary muscles are supplied by end arteries. Chordae tendineae are avascular structures, although in the normal mitral valve a small proportion of chordae show a muscle core throughout their length. The most common impaired site in patients with rheumatic mitral valve disease is the anterior leaflet. The most common site of spontaneous chordae rupture is the posterior leaflet. However, the mechanism of such a difference remains unclear.

Mild/moderate mitral regurgitation/heart failure usually caused by chordae rupture, which involves separation of a single chorda that leads to minimal hemodynamic effect and requires neither intervention nor treatment. Severe mitral regurgitation/heart failure usually caused by rupture which involves multiple chords simultaneously and may cause severe acute mitral insufficiency, a life-threatening emergency requiring immediate surgical intervention. But some case reports exhibited evidence that severe rupture may be either immediate onset or a progressive process in which minimal rupture precedes more extensive or even complete rupture.

Table 2. Classification and features of chord ruptures, mitral valve ruptures.

<b>Chord rupture</b>
<b>Predisposing factors:</b> <ul style="list-style-type: none"> <li>• No – spontaneous (without causes, may be abnormalities of collagen synthesis and degradation)</li> <li>• Yes – secondary (presence of predisposing factors)</li> </ul>
<b>Gender prevalence:</b> <ul style="list-style-type: none"> <li>• Spontaneous – men</li> <li>• Secondary – women</li> </ul>
<b>Rupture of the mitral valve</b> <ul style="list-style-type: none"> <li>• posterior – rupture of posterior leaflet of the mitral valve (most frequently, spontaneous)</li> </ul>

- anterior – rupture of anterior leaflet of the mitral valve (most in patients with rheumatic mitral valve disease)

**The amount of chord ruptures:**

- Separation of a single chorda (mild/moderate mitral regurgitation/heart failure)
- Multiple chords simultaneously (severe mitral regurgitation/heart failure)

According to the systematic review of Uri Gabbay and Chaim Yosefy «Underlying causes of chordae tendinae rupture» in which they analyzed 1390 cases of chordae tendinae rupture (CTR) before and since 1985 and till 2009 [4, 113-118]. Chordae tendinae rupture overall rates before and since 1985 remain considerable (52.5% vs. 51.2%), yet median decreased (35% and 14%). Sub-acute endocarditis and rheumatic heart disease were the most frequent causes before 1985 (54.4% and 42.1%, respectively); since 1985 sub-acute endocarditis and rheumatic heart disease have dropped sharply to 37.4% and 24.8%, respectively. Since 1985, mitral valve prolapse and myxomatous degeneration have caused 44.5% and 11.7% of cases, respectively. All other causes were almost not evident.

One of the most frequent causes of acute mitral valve rupture is degenerative mitral valve disease. According to the histology degenerative mitral valve disease includes myxomatous infiltration, fibroelastic deficiency, collagen alterations, and mucopolysaccharide accumulation. Elongated or ruptured chordae are often associated with these abnormalities and characterised by thickening and proliferation of the spongiosa with pooling of glycosaminoglycans. Degeneration may be either idiopathic or inherited. Previous studies suggested x-linked inheritance or autosomal dominant inheritance. Myxomatous degeneration of the mitral valve is more frequent among males, and with age. Detection of myxomatous degeneration is varied and depends on the measure in use, which in most cases is done visually during valve surgery. Microscopic examination is more accurate than macroscopic visualization but it is not routinely performed, therefore myxomatous degeneration may be underestimated. Echocardiography detection of myxomatous degeneration of a competent valve is limited.

**Classification mitral valve incompetence.**

The impairment of any component (annulus, leaflets, chordae tendinae, and papillary muscle) of the mitral valve may result in mitral valve incompetence. Carpentier and colleagues classified mitral valve incompetence into three types [7, 190]. In type II, the free edge of one or both leaflets overrides the plane of the annulus during systole. Type II lesions are related to excess leaflet tissue, elongated or ruptured chordae, dysfunction or ruptured papillary muscle. Types I and III may be associated with type II. In type I, the free edges of the leaflets remain below the plane of the annulus during systole and open normally during diastole. Mitral regurgitation is related to annular dilation or leaflet perforation. In type III, one or both leaflets do not open fully during diastole. Mitral regurgitation is related to restriction of leaflet motion of rheumatic or ischemic origin. Carpentier and colleagues in France and Duran and associates in Spain have both proposed nomenclatures of the mitral valve.

The valve is divided into two leaflets, posterior and anterior. The posterior leaflet is further divided into three scallops, P1, P2, and P3, which are anatomically evident. P1 is adjacent to the anterolateral commissure, close to the left atrial appendage. P3 is adjacent to the posteromedial commissure. The anterior leaflet is also divided into three scallops, A1, A2, and A3 facing the corresponding scallops of the posterior leaflet. P2 prolapse is the most frequent abnormality. The two nomenclatures are shown in figure 1.

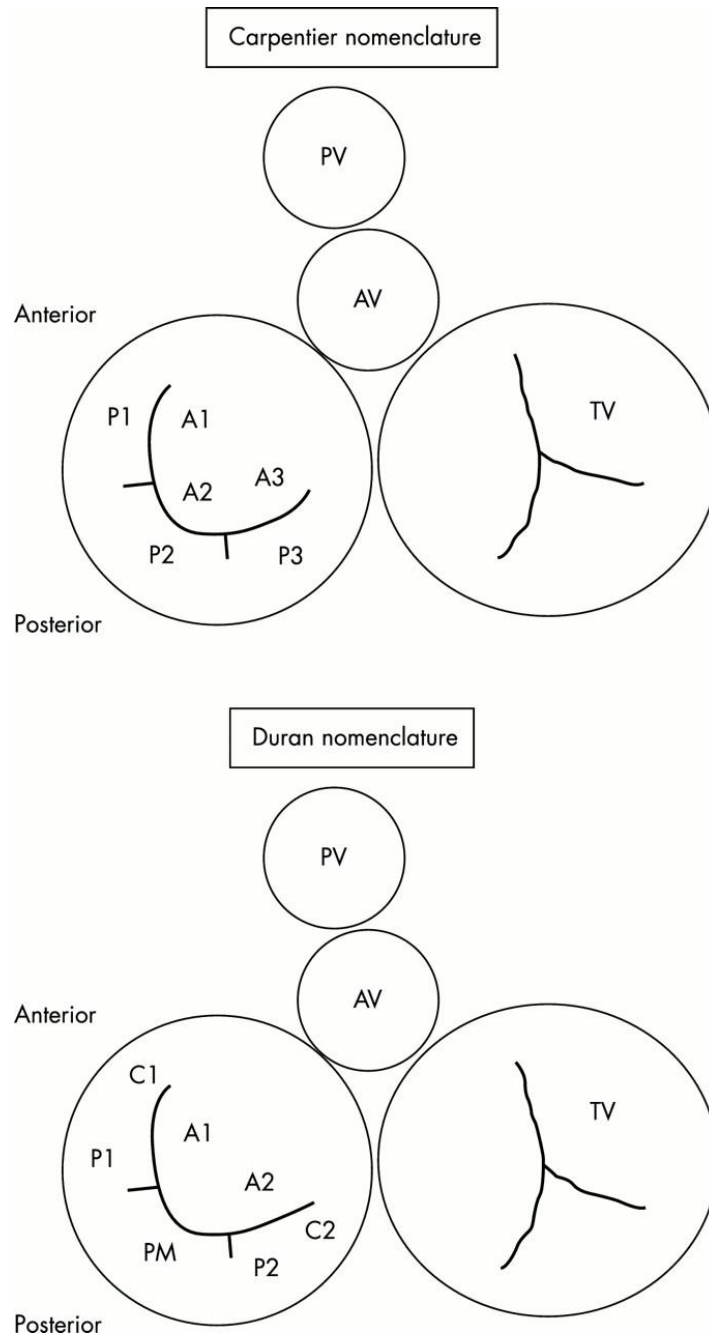


Figure 1. Carpentier and Duran nomenclatures of the mitral valve.

In the Duran nomenclature, the three scallops of the posterior leaflet are named P1, PM (middle), and P2. The anterior leaflet has only two scallops A1 and A2. The Carpentier nomenclature is described in the text. AV, aortic valve; PV, pulmonic valve; TV, tricuspid valve.

### Case report description

A 76-year-old woman was admitted because of dyspnea, lower limbs edema and fever during the previous several days. She noted a sharp appearance of sudden dyspnea a week ago. In the district hospital chest X-ray was carried out and bilateral lower lobe pneumonia was revealed. There wasn't any significant positive treatment outcome. Thus heart failure was regarded the leading causes of the disease, and the patient was referred to the cardiology department. Over the past 20 years patient suffered from arterial hypertension and regularly took antihypertensive drugs. She had a 30 years history of work with paint materials. Upon admission she had attenuation of the percussion sound in the basal parts of the lungs. Pulmonary auscultation revealed hard breathing, dry wheezing. Also the left heart boundaries expanding, systolic murmur at all points of auscultation, mainly in the area of the projection of the mitral valve, which is held in the left axillary region, edema of the limbs were registered.

### Description of the problem, procedures, techniques and/or equipment used

Mitral chordae tendinae rupture is a rare but important cause of severe mitral valve insufficiency and left ventricular dysfunction in patients with degenerative mitral valve disease.

The electrocardiogram showed sinus rhythm, left ventricular hypertrophy with no signs of ischemia.

Transthoracic echocardiography reported the left heart cavities enlargement, first stage aortic valve stenosis, 2<sup>nd</sup> stage of pulmonary hypertension (73 mm Hg) (figure 2) and mitral valve posterior leaflet chordae tendinae rupture (pic.3) with severe mitral regurgitation (figure 3).

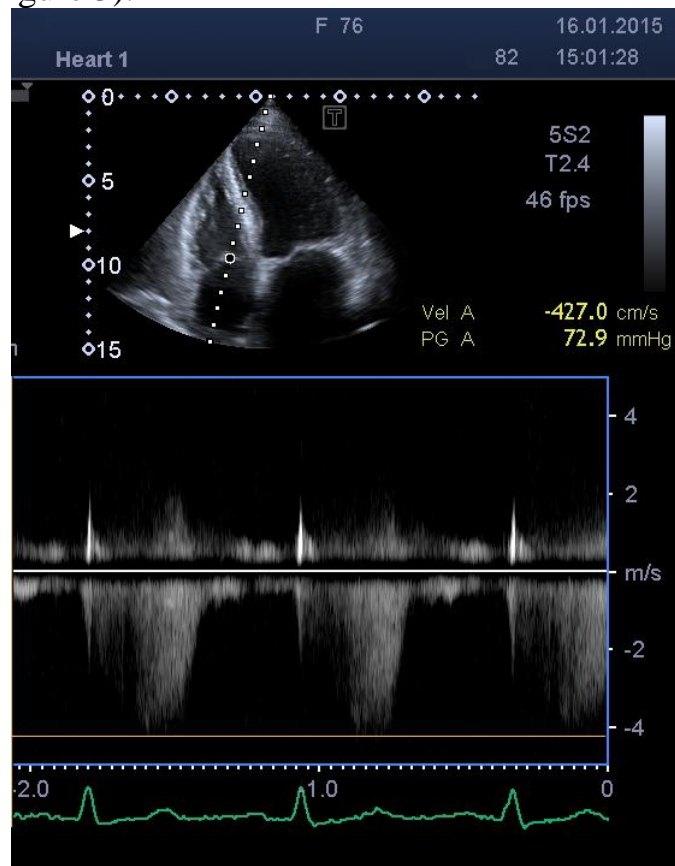


Figure 2. Pulmonary hypertension (73 mm Hg).

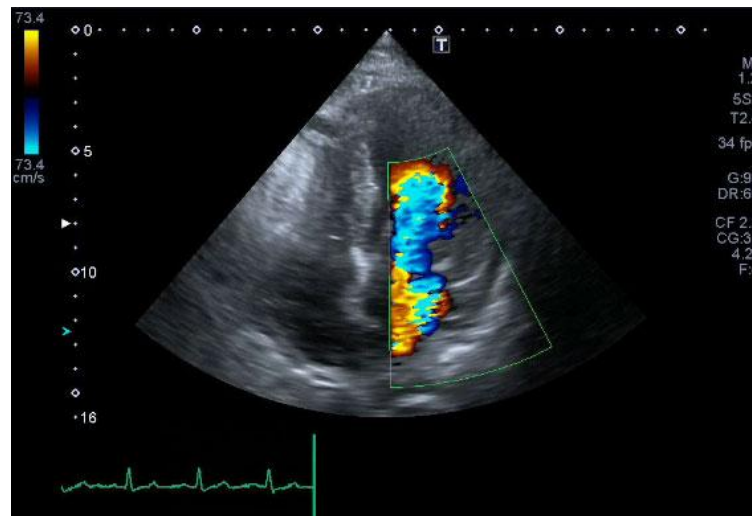


Figure 3. Moderate-to-severe mitral valve insufficiency, severe mitral regurgitation.

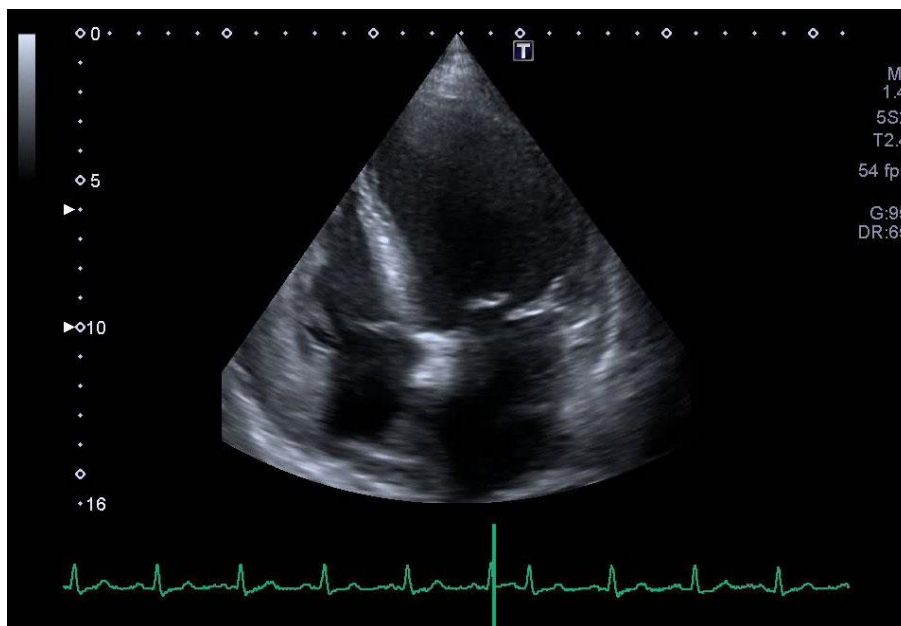


Figure 4. Ruptured chordae tendinae of the posterior mitral leaflet.

Angiography showed 40% stenosis of the proximal left anterior descending artery and 40% stenosis of the proximal segment of the right coronary artery. Multidetector computed tomography with angiography of the pulmonary arteries revealed the presence of cardiomegaly, pulmonary arterial hypertension and moderate bilateral hydrothorax. Convincing evidence for pulmonary embolism at the time of the study hasn't been identified (figure 4).

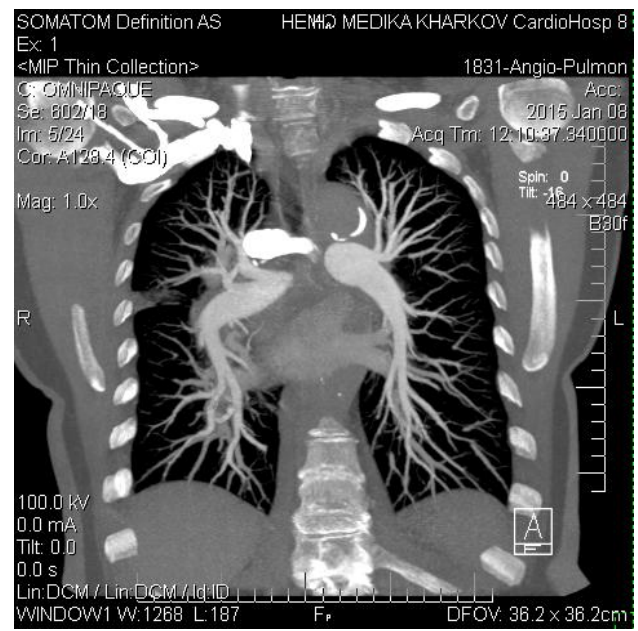
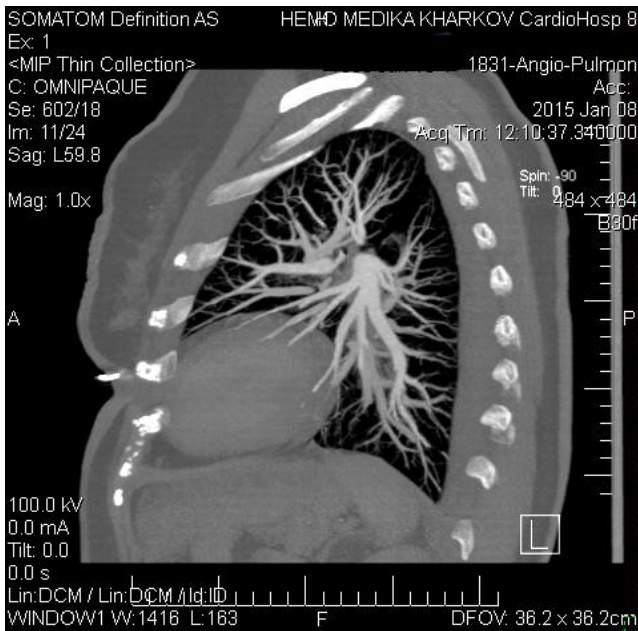


Figure 5. Angiography of the pulmonary artery and its branches showed no pulmonary embolism.

### Questions, problems or possible differential diagnosis

The patient had aortic stenosis, but it was slightly expressed and could not cause a substantial heart chamber enlargement, severe left ventricular failure, dyspnea, double-sided hydrothorax, double-sided congestive pneumonia. In addition there were particular auscultation pictures - systolic murmur mainly in the mitral valve with the left axilla irradiation. The presence of the patient heart chamber dilatation because of ischemic cardiomyopathy was excluded during coronary angiography –no severe and hemodynamically significant coronary artery lesions revealed.

The patient presented with the signs of pulmonary hypertension (73 mm Hg) with the sudden appearance of dyspnea and required differential diagnosis with thromboembolism of pulmonary artery small branches. We conducted angiography of the pulmonary artery and revealed no pulmonary embolism. Patient had chronic obstructive pulmonary disease, but after a week of bronchodilator therapy, dyspnea decreased, but remained.

### Answers and discussion

The diagnosis of acute chord rupture of the mitral valve posterior leaflet is usually difficult to quickly establish in patients with left ventricular dysfunction and requires very careful differential diagnosis especially in old-patients with comorbidities.

### Management

Repair procedures are based on quadrangular resection of the posterior leaflet, ring fixation of the mitral annulus, chordae transfer, sliding leaflet technique, and commissuroplasty. These techniques are often combined. Chordae tendineae rupture

can be repaired by reconstructing or replacing the chordae tendinae with or without annuloplasty, which is associated with better outcome, lower mortality, lower morbidity, and better quality of life in comparison with mitral valve replacement.

Mild chordae rupture rarely causes hemodynamic change and requires neither intervention nor treatment; however, significant rupture is usually a life-threatening emergency requiring immediate surgical intervention. Patients with acute and symptomatic severe mitral regurgitation, patients with New York Heart Association functional class II, III, and IV symptoms with normal left ventricular function, and patients with symptomatic or asymptomatic severe mitral regurgitation with mild or moderate left ventricular dysfunction are considered to have indications for mitral valve surgery. Compared with mitral valve replacement, chordae tendinae reconstruction with or without annuloplasty provides better outcome and life quality, and lower mortality and morbidity.

Patients with chronic non-ischemic severe mitral regurgitation who have NYHA functional class I symptoms and who have normal LV ejection fraction  $> 60\%$  and LV end systolic diameter  $< 45$  mm may be followed up medically at 3–6 month intervals. If such patients develop evidence of LV dysfunction, atrial fibrillation, or pulmonary hypertension (estimated pulmonary artery pressure of 50 mm Hg at rest or 60 mm Hg during exercise), the patient should be considered for cardiac catheterisation and possible mitral valve surgery, particularly if it is thought that the mitral valve can be repaired. Patients who have chronic non-ischemic severe mitral regurgitation who have class II, III, or IV symptoms should be considered for mitral valve surgery whether or not the LV function is normal (LV ejection fraction  $> 60\%$ , LV end systolic diameter  $< 45$  mm).<sup>51</sup> Whenever possible, mitral valve repair should be performed. Conversely, patients with severe symptoms and severely depressed LV function (LV ejection fraction  $< 30\%$ ) are generally best treated medically.

### **Conclusions and implications for clinical practice**

Acute chord rupture of the mitral valve posterior leaflet is rare but serious cause of severe mitral valve insufficiency, acute heart failure manifestation or chronic heart failure progression and leads to difficulties in the differential diagnosis of the reasons of heart failure. Acute chord rupture in degenerative mitral valve disease should be suspected in older patients with left ventricular dysfunction and comorbidities as a cause of heart failure. Any new onset of mitral regurgitation should be considered as chord tendinae rupture.

### **References**

1. Anderson Y. Fulminant mitral regurgitation due to ruptured chordae tendinae in acute rheumatic fever / Y. Anderson, N. Wilson, R. Nicholson, K. Finucane // *Journal of Paediatrics and Child Health*. –2008. – Vol. 44. – P.134–7.
2. Baird C.W. Mitral valve chordal rupture masquerades as endocarditis / C.W. Baird, C. Constantinou, E. Lansford, F.A. Pigula // *Pediatric Cardiology*. – 2007. –Vol. 28. –P.297–9

3. Brizzio M.E. Acute mitral regurgitation requiring urgent surgery because of chordae ruptures after extreme physical exercise: case report / M.E. Brizzio, A. Zapolanski // *Heart Surgery Forum*. – 2008. –Vol. 11. – E255–E256.
4. Gabbay U. The underlying causes of chordae tendinae rupture: a systematic review / U. Gabbay, C. Yosefy // *International Journal of Cardiology*. – 2010. – Vol. 143, Suppl.2. – P.113–118.
5. Juang J.J. Rupture of mitral chordae tendinae: adding to the list of hypertension complications / J.J. Juang, S.R. Ke, J.L. Lin et al. // *Heart*. – 2009. –Vol. 95. –P.976–9.
6. Kaymaz C. Differentiating clinical and echocardiographic characteristics of chordal rupture detected in patients with rheumatic mitral valve disease and floppy mitral valve: impact of the infective endocarditis on chordal rupture / C. Kaymaz, N. Ozdemir, M. Ozkan // *European journal of echocardiography*. – 2005. – Vol. 6. – P.117–26.
7. Leal J.C. Echocardiographic evaluation of patients submitted to replacement of ruptured chordae tendinae / J.C. Leal, Jr. F. Gregori, L.E. Galina, R.S. Thevenard, D.M. Braile // *The Revista Brasileira de Cirurgia Cardiovascular*. – 2007. – Vol. 22. – P.184–91.
8. Lin T.H. Association between hypertension and primary mitral chordae tendinae rupture / T.H. Lin, H.M. Su, W.C. Voon et al. // *The American Journal of Hypertension*. – 2006. Vol. 19. – P.75–9.
9. Lorusso R. Mitral valve surgery in emergency for severe acute regurgitation: analysis of postoperative results from a multicentre study / R. Lorusso, S. Gelsomino, G. Cicco et al. // *European Journal of Cardio-Thoracic Surgery*. – 2008. – Vol.33. – P.573–82.
10. Luo X.L. Clinical and echocardiographic characteristics of mitral chordal rupture from 292 hospitalized patients / X.L. Luo, S.B. Qiao, J.S. Yuan et al. // *Zhonghua Xin Xue Guan Bing Za Zhi*. – 2009. – Vol. 37(3). – P.253 – 6.
11. Morris A.L. Hypertrophic obstructive cardiomyopathy complicated by ruptured chordae tendinea to the posterior mitral leaflet and severe congestive heart failure / A.L. Morris, I. Moheb // *The Canadian Journal of Cardiology*. – 2009. – Vol. 25(7). – e259–e260.
12. Simmers T.A. Traumatic papillary muscle rupture / T.A. Simmers, H.W. Meijburg, A.B. Rivière // *Annals of Thoracic Surgery*. – 2001. Vol. 72. – P.257–9.