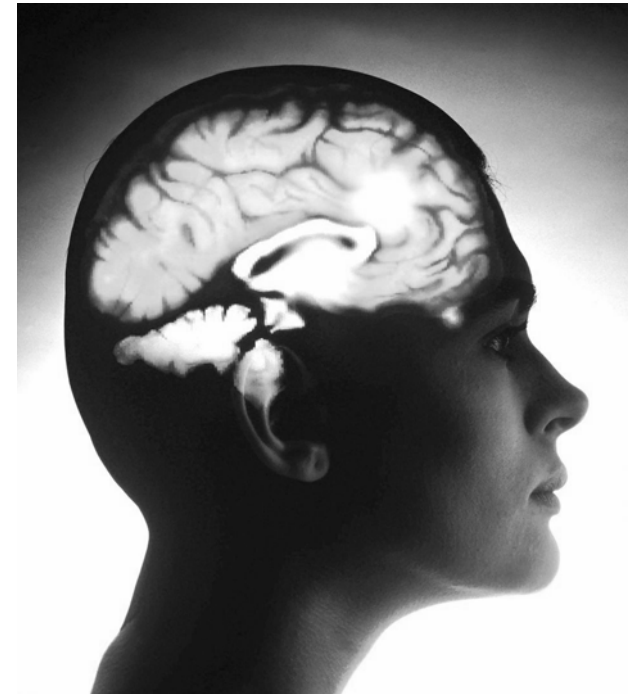


MINISTRY OF PUBLIC HEALTH OF UKRAINE  
KHARKIV NATIONAL MEDICAL UNIVERSITY

**DIFFERENTIAL DIAGNOSTIC OF INFECTIOUS  
DISEASES WITH MENINGEAL SYNDROME**



KHARKIV 2008



*Учбове видання*

**ДИФЕРЕНЦІЙНА ДІАГНОСТИКА ІНФЕКЦІЙНИХ ЗАХВОРЮВАНЬ З  
МЕНІНГЕАЛЬНИМ СИНДРОМОМ**

*Методичні вказівки  
для студентів V – VI курсів*

Складачі: Козько Володимир Миколайович  
Кацапов Дмитро Володимирович  
Бондаренко Андрій Володимирович  
Краснов Максим Ігорович  
Граділь Григорій Іванович

Відповідальний за випуск: Козько В.М.

Редактор: Е.С. Дєпрінда  
Комп'ютерна верстка: Д.В. Кацапов

План 2008, поз. \*\*.   
Помп. к печ. Формат А5. Папір типогр. Різографія.   
Усл. печ. л. Уч.-изд. л. . Тираж 300 екз. Зак. № .

---

**ХНМУ, 61022, пр. Леніна, 4  
Редакційно – видавничий відділ**

МІНІСТЕРСТВО ОХОРОНИ ЗДОРОВ'Я УКРАЇНИ  
ХАРКІВСЬКИЙ НАЦІОНАЛЬНИЙ  
МЕДИЧНИЙ УНІВЕРСИТЕТ

**ДИФЕРЕНЦІЙНА ДІАГНОСТИКА ІНФЕКЦІЙНИХ ЗА-  
ХВОРЮВАНЬ З МЕНІНГЕАЛЬНИМ СИНДРОМОМ**

**Методичні вказівки для іноземних студентів  
медичного факультету V и VI курсів**

Затверджено  
вченою радою ХНМУ  
Протокол № від . .08

ХАРКІВ 2008

Differential diagnostic of infectious diseases with meningeal syndrome. Methodical recommendations for foreign students of medical faculty of the V and VI year (Диференційна діагностика інфекційних захворювань з менінгеальним синдромом).

V.M. Kozko, D.V. Katsapov, A.V. Bondarenko, G.I. Gradil, M.I. Krasnov. - Kharkiv: KNMU, 2008. – 20 p.

#### NORMAL VALUES OF CSF

1. General amount of CSF in ventricles of brain of adult is approximately 100-150 ml.
2. Normal pressure in horizontal position is 110-160 mm Hd..
3. Density of CSF is 1006-1007.
4. pH is – 7,4-7,6.
5. Colorless, transparent.
6. Protein amount in ventricles is 0,12-0,2 g/l, in subarachnoidal space - 0,22-0,33 g/l.
7. Normal cytositis is 3-4 cells (lymphocytes only).
8. Glucose amount is 2,22-3,33 mmol/l.
9. Chlorides – 125 mmol/l.

#### PATHOLOGICAL STATES

- I. Cell -protein dissociation (increasing of cell count with normal or slightly elevated protein amount) is typical for inflammatory diseases of nervous system. High cytositis is typical for meningitis of different origin, moderate – for arachnoiditis, encephalitis, neurosyphilis. Lymphocytic reaction is typical for serous meningitis, neutrophil – for purulent. Neutrophils in CSF are arising in CSF with presence of blood (unsuccessful lumbar puncture, subarachnoidal bleeding), sometimes – in another inflammatory diseases of nervous system (arachnoiditis, brain abscess).
- II. Protein - cell dissociation (increasing of protein amount with normal cell count) is typical for brain tumors: than closer latter to liquor reservoirs than higher protein amount. Protein amount also increased in cases of blood presence in CSF (unsuccessful lumbar puncture, subarachnoidal bleeding).

**Differential diagnostics of meningitis by CSF** **Table 2**

Clinical form	CSF pressure	Transparency	Color	Cell count in 1 mkl	General protein, g/l	Fibrin film	Glucose amount, g/l
Purulent meningitis (meningococcal, streptococcal, pneumococcal, etc.)	Elevated (more 300ml hg, or 29,4 kPa)	Dull	White – yellow (meningococcal), intensive yellow (staphylococcal), greenish (pneumococcal), blue (Ps. Aerogenosa)	Neutrophils (80-100%) from 1 to 50 000	0,8-16	Often rough sediment on bottom of test – tube	Decreased to 0,3-0,4
Viral meningitis	Elevated	Transparent	Colorless	Lymphocytes (80-100%), average 800-1000	Normal or slightly elevated, average 0,3-0,6	Rare	Normal
Tuberculous meningitis	Elevated moderately	twinkling	Colorless, sometimes xanthochromia	Prevalence of lymphocytes, 300-600	0,9-1,5	After 12-24 hr – light fibrin film on surface of CSF	Decreased to 0,1-0,2
Syphilitic meningitis	Elevated (200-300 mm hg or 19,6-29,4 kPa)	twinkling	Colorless	Lymphocytes 100-1500	0,6-1	-	Normal
Meningism (general infections, intoxications, somatic diseases)	Slightly elevated	Transparent	Colorless	Lymphocytes 0-10	Normal	-	Normal

**GENERAL STATEMENTS**

**Object of studies** – to teach students to make a diagnosis of meningococcal infection and other infectious diseases with meningeal syndrome, on the ground of anamnesis, clinical symptoms, results of laboratory tests, instrumental methods; to make a differential diagnosis of the diseases, to prescribe treatment.  
Time – 4 academic hours;

**Place of studies** - diagnostic department, department of neuroinfections, intensive care unit in infectious hospital, teaching room.

**Plan of studies:**

Introduction – 5 min.

Checking of presence – 5 min.

Checking of student’s knowledge by topics – 10 min.

Original work of students – 90 min. (examination of patients in department of neuroinfections, writing of case histories, work in reception department, or intensive care unit of infectious hospital).

Clinical analysis of patients after examination – 30 min.

Checking of practical knowledge – 15 min.

Making of preliminary diagnosis to the patients – 20 min.

Making of differential diagnosis with similar diseases – 20 min.

Prescribing of laboratory and instrumental tests – 10 min.

Making of a final diagnosis – 7 min.

Consideration of clinical cases – 15 min.

Prescribing of treatment – 5 min.

Rules of discharging patients from hospital, prognosis - 5 min.

Homework – 3 min.

Meningococcal infection is the most typical disease accompanied with meningeal syndrome and its different variants of exacerbation – carrierity of meningococci, acute nasopharyngitis, isolated pneumonia, or generalised forms – meningitis, meningococemia (typical, fulminating, chronic), meningococcal meningitis, mixed forms – meningitis + meningococemia; and rare forms – meningococcal arthritis, polyarthritis, endocarditis, iridocyclitis, etc.

State of presence and multiplication of meningococci on mucous of nose and pharynx without local changes, not penetrating into a bloodstream, is carrierity.

State of multiplication of meningococci on mucous of pharynx and penetration into regional lymph nodes, and then into bloodstream (bacteraemia) with moderate intoxication is meningococcal nasopharyngitis.

Isolated pneumonia can be diagnosed mainly during outbreaks of meningococcal infection or in cases of presence of meningococci in sputum.

Most typical form of meningococcal infection is meningitis. Penetration of pathogen mainly occurs from mucous through blood and rarely lymph, with development of bacteraemia, intoxication. Pathogen fixing on meningeal and causes inflammation, cerebral hypertension, rarely – ventriculitis, and complicates with oedema of a brain. In meningeal takes place vasodilatation, exudation, cell proliferation, with leucocytic reaction of cerebrospinal liquid, formation of paraneural infil-

trates, purulent melting. Inflammation expands by vascular spaces on brain substance (meningoencephalitis) with affection of 3, 5, 7, 8 and 12 pairs of cranial nerves. Meningea is rigid, and enlargement of brain together with increasing of cerebrospinal liquid production leads to cerebral hypertension. As a result translocation of brain may occur along cerebral axis, with inclination of medulla oblongata to foramen magnum, resulting in paralysis of respiratory and vasomotor centres. In pathogenesis of severe forms of meningococcal infection main role takes toxic shock reaction as acute vascular collapse on basis of massive intoxication. Toxaemia leads to hemodynamic disturbances with tissue microcirculation downfall, disseminated intravascular coagulation (DIC-syndrome), and acute disturbance of metabolic activity, water-electrolyte balance, and endocrine glands function. Progressing toxic shock may cause an acute affection of suprarenal glands (so-called Waterhouse-Friderecsen syndrome), affection of kidneys with acute insufficiency.

Thus, meningeal complex of symptoms with subjective (nausea, vomiting, sharp headache, dizziness, high temperature) and objective symptoms (rigidity of neck muscles, positive symptoms of Kernig, upper, medial and lower symptoms of Brudzinsky) is common as for meningism, different by etiological factors meningitis, meningococcal infection and other infectious diseases. All mentioned make difficulties in early diagnostic. Cause of mistakes is inadequate knowledge of practical doctors on checking and verification of meningeal syndrome. Meningeal syndrome - is irritation and inflammation of meningea, displayed in general and muscle-tonic symptoms:

1. Rigidity of neck muscles- impossibility or difficulty during passive attempt to bend head of a patient and touch chest with chin.
2. Kernig symptom- inability to extend patient's leg knee after bending in knee and pelvic joints.
3. Upper symptom of Brudzinsky - simultaneous bending of legs during attempt to bend neck of a patient.
4. Medial symptom of Brudzinsky - bending of legs during pressing on hypogastrium of a patient.
5. Lower symptom of Brudzinsky - simultaneous bending of one leg during passive flexing of another one in knee and pelvic joints.
6. Mendel symptom - pain during pressing on meatus.

Topical symptoms based on reflex strain of muscles (contractures) as a result of irritation of radices of spinal and cranial nerves. For their detection integrity of pyramidal way function is necessary, therefore for children younger, then 1 year and aged patients, this group of symptoms can be less detectable. Early diagnostic of meningitis and other diseases with meningeal symptoms is the most important. Definition of "early diagnostic" means diagnostic of a disease on early stage, before manifestation of clinical picture with all typical signs. During the most purulent meningitis, including meningococcal, period from onset to manifestation of bright meningeal symptoms is an average of 24 hours. Early symptoms can be observed during first hours. These are increasing headache, mainly in frontal and retroorbital

**Table 1**

**Differential diagnostics of meningitis**

Criterion	Meningococcal meningitis	Secondary meningitis	Mumps meningitis	Serous (enteroviral) meningitis	Tuberculous meningitis
Sex frequency	Male	Both	Male	Male	Both
Age prevalence	Children	Children	Children	Adults	Adults
Season (Eastern Europe)	Spring – summer	Autumn – winter	Autumn – winter	Summer – autumn	Spring – summer
Usual term of hospitalization	First 3 days	After 5 <sup>th</sup> day	After 3 <sup>rd</sup> day	Before 5 <sup>th</sup> day	After 5 <sup>th</sup> day
Gravity	Moderate	Severe	Moderate	Moderate	Moderate
Nausea, vomiting	Typical	Typical	Typical	Typical	Rare
Neck muscles rigidity	Typical	Typical	Typical	Typical	Approximately 50%
Kernig sign	Typical	Typical	Typical	Typical	Rare
Brudzinsky sign	Typical	Typical	Typical	Typical	Rare
Leucocytosis	Typical	Typical	Rare	Rare	Rare
Leucocyte reaction	Neutrophil	Neutrophil	Normal or leucopenia	Normal or leucopenia	Normal or leucopenia
ESR enlargement	Typical	Typical	Rare	Rare	Rare
Cytosis of CSF, 1/mkl	<200	<200	>500	>500	>500
Cell prevalence	Neutrophils	Neutrophils	Lymphocytes	Lymphocytes	Lymphocytes
Protein amount	High	High	Increased moderately	Increased moderately	Increased moderately

### Appendix 3

#### ADDITIONAL METHODS OF INVESTIGATION IN DISEASES WITH MENINGEAL SYNDROME

**Electroencephalography (EEG)** – method of investigation, based on registration of electric brain activity (biopotencial) for valuation of information for local and generalized changes of its function.

**Rheoencephalography (REG)** is method of diagnostics of craniovascular tonus and bloodstream, based on registration of rhythmic changes of resistance of brain tissue, resulting from pulse fluctuation of cranial vessels.

**Magnetic resonance imaging (MRI)** is method of investigation of tonus and bloodstream in cranial vessels, based on registration of rhythmic changes of resistance of brain tissue, resulting from pulse fluctuation.

**Echoencephalography** is method of ultrasound scan of brain tissue. It can be applied for detection of intracranial dislocation pathology.

**Ultrasound dopplerography (USDG)** – is method, based on Doppler effect, the matter is on registration of shift of ultrasound signal, reflecting from moving form elements of blood. Value of the shift is straight proportional to speed of bloodstream.

**Electromyography (EMG)** – is method of skeletal muscles function investigation, based on their bioelectric activity registration. Can be applied for diagnostics of CNS and peripheral nerves affection.

X – ray based methods.

**Angiography** – special method of diagnostics of brain vessels, based on injection of contrast liquids with subsequent X – ray imaging.

**Computed tomography** – registration of narrow directed beam of X – ray with highly sensitive apparatuses with computer processing.

zones, accompanied by nausea and sometimes sudden vomiting. Disease characterized with acute onset, fever up to 40°C, chill.

Meningeal syndrome includes general and envelope symptoms, which is divided on 3 groups depending on pathophysiologic mechanisms:

1 group: symptoms of hyperesthesia - general or sensor organs - hyperacusia, hyperalgesia, hyperosmia.

2 group: reactive pain phenomenons - pain during palpation of N. trigeminus exit spot projection; pain during palpation of spots of exit of N. occipitals (symptom of Kerer); symptom of Mendel.

3 group: muscular tonic strains or contractures - rigidity of neck muscles, symptoms of Kernig and Brudzinsky, symptom of Gordon (reflector extension of foot big finger during shrinking of shank muscle), symptom of Lessaje (hanging) for children.

General symptoms, like rash, are also helpful in diagnostic. Herpetic rash is common for patients with meningitis, and hemorrhagic rash of irregular form, tend to central necrosis, primary on low extremities, is typical for meningococemia from first hours.

Proper diagnostics of meningitis and differentiation between purulent and serous meningitis is almost impossible without spinal liquor analysis. Thus, pneumonia, otitis or sinusitis, mastoiditis, traumas of a skull can be complicated with secondary purulent meningitis. That is why in case of suspicion of meningitis patient must be admitted to hospital as soon as possible.

Identification of main clinical syndrome is also necessary (envelope, cramps syndrome or paralysis). Neurological criteria are important during examination of an unconscious patient in order of differential diagnosis of comas. Combination of manifest local neurological symptoms (signs of cranial nerves function affection, hemiplegia with Jackson's cramps and meningeal syndrome) is typical for cerebral coma in patients with severe meningitis. Sometimes typical "meningeal" posture is observed. But in progress of comatose status meningeal symptoms decreasing, pathological respiration rate - short equal phases of inhale alternating with phases of apnoea. long (Biott rhythm) can appear. Pathological reflexes must be checked. Symptom of Babinsky can be observed in 20-30 min. after coma development. In contrary, symptom of Rosolimo appears only in 2-3 days after affection of pyramid way. That mean, coma was consequent of local brain affection (abscess or tumour).

Typical mistakes on early stage of diagnostic with account of subjective symptoms of meningeal complex. Acute onset of disease, sharp headache, nausea, vomiting are typical for such diseases, as bacterial meningitis, influenza, food poisoning, subarachnoidal bleeding, etc. A lot of patients with meningitis are admitted to hospital with diagnosis like toxic form of influenza or influenza with haemorrhagic syndrome, especially in influenza epidemic period.

As usual, meningitis has bacterial or viral origin, and, accordingly can be purulent or serous, except of tuberculous meningitis, with is also serous. Inflammation of meningea can be primary and secondary.

Primary meningites pathogens:

1. Meningococcus spp.;
2. Enteroviruses (Coxsackie, EKHO);
3. Mumps virus;
4. Herpes viruses, cytomegalovirus;  
Secondary meningitis pathogens:
  1. Mycobacterium tuberculosis spp.
  2. Str. pneumonia;
  3. Staphylococci and Streptococci;
  4. E. Coli spp.;
  5. Klebsiella spp.
  6. Actinomyces

General for different meningitis is presence of meningeal syndrome with headache, vomiting, stiffness of muscles, Kernig and Brudzinsky symptoms and cerebrospinal fluid (CSF) changes are typical for inflammation of meninges. General symptoms of brain reaction on infection are also usually observed – loss of consciousness, cramps and hyperthermia. In case of meningitis presence of some meningeal signs (more often neck stiffness) and absence of inflammatory changes in CSF are observed.

Meningococcal meningitis is leading by incidence, lethality and variability of clinical forms. These emphasize importance of proper diagnostic and, especially differential diagnosis of the disease.

Meningococcal meningitis classified as:

- a) typical – acute
- b) severe – with oedema of brain;
- c) meningitis with ependymitis;
- d) meningitis with cerebral hypotension (in children).

Typical acute meningitis begins in a healthy person or soon after mild nasopharyngitis. Usually patients can specify not only day, but also the hour of the beginning of disease. Usually there is triad of symptoms: fever, persistent headache and vomiting. Rise of temperature is acute, up to 40 - 41°C during few hours. Headache – strong, prolonged, without typical localization, increasing from bright light, sharp noise, movements. Vomiting is usually sudden, without preceding nausea. Symptoms of general hyperesthesia can be observed – hyperacusia, photophobia, and hyperalgesia. Clonic or tonic cramps are also possible, especially in children of young age. On examination of infants: frontoculus anterior protruding and tension, symptom of Lessage (hanging), tonic or clonic cramps, mono- and hemiplegia, epilepsy –like attacks, dyspeptic disturbances (diarrhea, vomiting) can be observed.

On examination of an adult patients most important in diagnostic are meningeal symptoms that can be due to tonic muscles contraction or reactive pain phenomena. Meningeal symptoms usually rise from first day of disease and progressing. Most constant are rigidity of neck muscles, Kernig and Brudzinsky symptoms (upper, middle and lower). Increase of tonic contraction can lead to typical posture (posture of a setter) – on patient's side with thrown back head and flexed extremities.

Infusion of Glucose 10% solution in dose up to 0,25 g/kg in hour IV, together with KCl 3,7% solution 4-5 ml, insulin, MgSO<sub>4</sub> sol. 25% 7 ml, Ac. Ascorbinicum 1% 5 – 10 ml

#### **Improvement of rheological properties of blood and microcirculation.**

Heparin – in daily dose 10000 – 20000 subcutaneous, intravenous.

Pentoxifyllin (Trental) – 0,1 g (1 amp) in 250 - 500 ml of 0,9% solution Sodium chloridum or in 5 % solution of glucose

Actovegin – first dose – 10 – 20 ml, then 3 – 5 ml 1 t.d.

Verapamil 0,25% - 5 – 10 ml IV, or nifedepin, or nimodipin.

#### **Correction of acid – base status**

Sodium hydrocarbomicum – 3 – 5% solution – 50 – 100 ml under control of acid – base status.

Trisaminum – 3,66% solution 500 ml, slowly IV

Euphillin 2,4% 10 ml IV, 2-3 times per day.

#### **Decreasing of oxygen need.**

Removing of psychomotor excitement and cramps – Sodium oxibutirat 20%, or sibazon 80 – 100 mg/kg daily, or aminazin 2 – 4 mg/kg 2 – 3 t. d., or droperidol – 5 – 15 mg/kg IV.

Cranio cerebral hypothermy.

#### **Edema treatment.**

Hyperosmolar solutions – mannitol 10 – 15% 0,5 – 1,0 mg/kg IV, Rheoglumanum 400 ml slowly IV with control of haemodynamics and acid – base state.

Saluretics – frusemide 20 – 40 mg 2 – 3 t. d.

Corticosteroids - prednisolon – 60 mg, or dexametazone – 0,3 mg/kg daily dose.

Prescription of concentrated solutions for maintenance of normal oncotic pressure (albumin, serum), glucose 10%, Calcium chloride is necessary.

Prescription of corticosteroids in therapeutic doses IV.

For maintenance of rheological properties of blood – rheopolyglucin (250-400 ml IV), heparin (10 000 – 20 000 IV daily dose) is prescribed.

For central hemodynamic correction – 250 ml 10 – 20% Glucose solution IV, 0,5 – 1,0 ml of 0,06% corglicon, 4 – 16 MU of insulin, 30 – 50 ml 4% solution of Potassium chloride.

#### **Desintoxication therapy.**

Crystalloid and colloid solutions in correlation 3:1 is prescribed.

#### **Prophylactic of edema of brain.**

Main prophylactic of this severe complication is timely antibiotic and supportive treatment of the disease, in intensive care unit, if necessary. Indications for transferring a patient in intensive care unit are: inadequate movement reaction after irritation; cranial nerves function disturbance; cramps or epistatus; cerebral coma ≤ 7 pt by Glasgow coma Scale; signs of edema of brain; polyorganic failure; severe acid – base state disturbances; severe hypoxemia by visual signs or instrumental examination; hyponatraemia.

## Appendix 1

### URGENT STATES IN MENINGITIS

Urgent stages – life - threatening condition of patient, connected with disturbance of consciousness (coma), psycho – motor excitement, severe general meningeal and local neurological symptoms (vomiting, paralysis, ataxia, aphasia, severe pain syndrome) and requires immediate medical assistance. They can develop during various diseases: vascular (cerebral thrombosis), infectious (meningitis, encephalitis, brain abscess), traumatic, tumors of a brain and parasitic diseases, etc.

Stagger – sharp increasing of threshold for all irritants, unclear orientation in circumstances. Patient is sleepy, difficult in contact, answers slowed down, uncompleted.

Sopor – partial loss of consciousness, reaction on pain and strong irritants is left. Inability to contact is observed.

Coma (Greek: coma – dream, somnolence) – state loss of consciousness, connected with absence of movements, decreasing or loss reflexes and reactions on irritants, disturbance of respiration and cardio – vascular function.

Comas divided on: primary (stroke, brain tumor, encephalitis, meningitis, trauma of head); somatic (exogenous or endogenous intoxications, general infections, burns, endocrinopathies).

Depending from gravity comas divided on 3 stages: I stage – light; II stage – moderate; III stage – severe. I stage coma characterized with presence of intensive pain irritants, photoreactions, corneal and tendinal reflexes. II stage coma – loss of pain reaction, decreasing of corneal reflexes, disturbance of respiration and cardiovascular function. III stage coma characterized with loss of photoreaction, corneal and tendinal reflexes, midriasis, general atonia, sharp disturbance of respiration and cardiovascular function.

Main differential sign of primary comas – presence of local neurological symptoms: anisocoria, rotated foot, anisoreflexia, one – sided decreasing or increasing of muscle tonus, one – sided pathological reflexes. Instrumental methods (electroencephalography, computed tomography) reveal nodal affection of one cerebral hemisphere.

## Appendix 2

### TACTIC OF TREATMENT

The main directions of reanimation and intensive care are normalization of respiration, cardiovascular function, BP, homeostasis, prevention of hypoxia and edema of a brain. Care measures are important – prevention of tongue sticking and falling head back, oral cavity, nose, bronchial tract lavage; dynamic monitoring of pulse, BP, temperature, ECG, urine amount, etc. In cases of acute respiration disturbances (absence of spontaneous breathing, hypoventilation with  $pCO_2$  increasing higher than 60 mm hg, decreasing  $pO_2$  less than 60 mm Hg) – urgent intubation and artificial respiration (AR) with inhalation of humidified oxygen. Lumbar puncture is performed with therapeutic and diagnostic aim.

**Antyhypoxical therapy.**

Sometimes meningeal syndrome is dissociated – some of symptoms are missing. So called “local symptoms”, connected with spreading of inflammation on radices of cranial or spinal nerves and brain substance, can also be observed. Vegetative nervous system is often affected, that lead to red stable dermatographism.

Severe meningitis, usually accompanied by an edema of a brain and characterized with toxicosis, hyperthermia and vital functions disturbances. Confusion or loss of consciousness, psychomotor exaltation, clonic and tonic cramps, hyperemia of a face, cyanosis, arrhythmia of respiration, BP increasing usually observed. Edema of a brain can be observed from first day of disease, on 5-7 day.

Course of toxic shock syndrome divided on 3 stages (by V.I. Pokrovsky):

First stage is characterized with severe general condition, muscular and joint pain, general hyperesthesia and psychomotor excitement. Hemorrhagic rash with necrosis can be observed on skin, cyanosis of lips and nails. BP can be normal or slightly elevated, tachycardia.

In second stage consciousness of patients is tangled, skin is pale, hemorrhages and necroses are extending; cyanosis of nose, ears, feet and fingers. Cardiac sounds are muffled, tachycardia, BP decreasing to 80/50 mm. Hg, temperature is normal. In blood – decompensated acidosis, hypoxemia and hypokaliemia are typical.

In third stage hypothermia, hyperesthesia is observed, anuria. Pulse is weak, heart sounds dull, BP decreased to critical level, sometimes delirium can be observed. In this stage edema of a brain is possible, characterized with cramps and loss of consciousness.

In case of belated treatment of meningitis development of epindimitis or ventriculitis syndrome is possible. Arising of these symptoms usual on third day of the disease and characterized by somnolence, muscular contraction, psycho-mental disorders, paralysis of sphincters, cachexia and hydrocephalon development.

In case of loss of consciousness in combination with stable paralyzes, local neurologic symptoms, cranial nerves affection, or clinical picture of meningoen- cephalitis can be suspected.

Meningitis with cerebral hypotension is possible for children. Characteristic signs are toxicosis, dyspeptic syndrome (nausea, vomiting, diarrhea), on examination – sunken eyes, clean-cut features of a face, thirst, dry skin, mucous, decrease turgor of skin, muscular hypotension.

Main role in diagnostic of meningitis belongs to cerebrospinal puncture. Pressure of cerebrospinal fluid (CSF) is increased; it's purulent (turbid) or shimmering. Cell count in 1 mkl is usually thousands, in typical cases majority of them (70-80%) are neutrophils. Amount of protein is 1 – 7 g/l or more. Globulin reactions of Pandy and Nonne - Appelt are becoming positive.

For CSF analysis some methods are applied:

1. General clinical – pressure, transparency, color, cell count, amount of protein;
2. Bacterioscopy;
3. Bacteriology;
4. Immunology;
5. Biochemical.

Main role in diagnostics belongs to meningococcal antigen detection in CSF, culturing the pathogen from nasal mucous, CSF sediment. Auxiliary are bacterioscopy of CSF sediment, tick drop and smear of blood. Meningococcal antigen can be detected in Indirect Agglutination Reaction (IAR), Coagglutination Reaction, Immunoenzyme assay (IEA).

In clinical blood test – neutrophil leucocytosis, ESR increased.

Main differential signs of CSF are presented in Table 1.

It is necessary to differentiate different clinical forms of meningococcal infection from **secondary purulent meningitis** (see table 2), **pneumococcal meningitis**, widespread mostly among young children. For the last acute beginning, high temperature (up to 39°C); development of the process on a ground of acute pneumonia, sinusitis, with increasing intoxication are typical. Early loss of consciousness, tremor of limbs, cramps, signs of focal cerebral nerves affection, mono- and hemiparalysis – are symptoms of meningoencephalitis. On 1-2 day of infection symptoms of central nervous system (CNS) local affection is arising, but meningeal syndrome not fully presented. For pneumococcal meningitis exacerbations and relapses are typical. CSF is turbid, purulent, greenish and yellow color, with neutrophil leucocytosis and high protein amount, decreasing of glucose and chlorides is usual. On CSF sample microscopy extracellular diplococci can be seen.

Differential diagnosis of meningococcal meningitis with meningitis of **staphylococcal, streptococcal, salmonelous** and other can be made on basis clinical and laboratory data (see table 2).

There is a big group of infectious diseases accompanied by primary or secondary affection of meningea and clinical picture of meningitis, but with lymphocytic (serous) reaction of CSF. They raise question of differential diagnosis with purulent meningitis or other similar diseases, such as parotitis, influenza, parainfluenza, adenoviral infection, measles, poliomyelitis, lymphocytic choriomeningitis, tuberculosis, etc..

Serous meningitis is polyethyological disease of viral, bacterial or fungal, protozoa or other origin. Ethyological belonging of serous meningitis is very important for antiepidemic measures and for appropriate treatment.

On contrary of purulent bacterial or viral meningitis and meningoencephalitis **tuberculous meningitis** or meningoencephalitis has gradual onset with general weakness, subfebrile temperature, headache, insomnia. Meningeal syndrome arises on 5-6 day of disease. Then to 6-20<sup>th</sup> day temperature is increasing to 39-40°C, acute headache, vomiting, somnolence, bradycardia, and loss of consciousness can be seen. Early affection of cerebral nerves (ptosis, midriasis, strobismus) is not typical for viral meningitis. Main diagnostic criterion is CSF analysis. CSF is transparent or shimmering. Protein – cellular dissociation, lymphocytic cytolysis, decreasing of glucose and chlorides, sometimes cobweb - like film are typical. On blood sample – leucopenia or slight leucocytosis are typical in contrary of meningococcal meningitis with a high leucocytosis. On microscopy tuberculous bacteria can be seen.

**Mumps** complicated with meningitis with serous CSF reaction is very often,

## CONTROL QUESTIONS FOR THEME

1. Mention diseases with meningeal syndrome.
2. Classification of meningitis for etiology, gravity, character of CSF count.
3. Mention the symptoms, united in meningeal syndrome.
4. Early diagnostics of meningitis on preclinical stage.
5. Early diagnostics of meningococcaemia on preclinical stage.
6. General signs of serous and purulent meningitis.
7. Distinguishes between serous and purulent meningitis.
8. CSF normal counts.
9. Characteristic of CSF during meningitis and other diseases, accompanied with meningeal syndrome.
10. Differential diagnostics of meningitis with other infectious diseases, accompanied with meningeal syndrome.
11. Differential diagnostics of meningococcaemia.
12. Complications of meningitis.
13. Laboratory diagnostics of meningitis.
14. Treatment of meningitis.
15. Treatment of meningococcaemia.

It is necessary to pay attention on presence of lice on patient's skin or clothes. Positive reactions of agglutination with *Rickettsia Provaszkyi*, complement fixation reaction or indirect agglutination reaction can help confirm diagnosis.

Hemorrhagic fevers with acute onset, rash, affection of nervous system, temperature and intoxication can resemble meningococcaemia. But arising of hemorrhagic rash later – on 4-5 day of disease, much higher development of hemorrhagic fever, often with renal syndrome differs from meningococcaemia.

Allergic rash and joints affection has some similar symptoms with meningococcaemia. But rash in this case arises before onset of the disease after taking particular medicine. Rash has no typical localization, in case of serum disease – spreading from place of serum injection on whole surface of body. Rash is inching, macular, without hemorrhagic component, general intoxication and central nervous system affection are minimal.

Acute onset of measles with intoxication and rash sometimes raises question of differential diagnostics with meningococcaemia. But beginning of measles with catarrhal syndrome, arising of Koplick – Filatov spots on mucous of mouth makes it different from meningococcaemia. Rash has descending character, arises from 3<sup>rd</sup> day of disease, more often it is papulous and rarely hemorrhagic. Epidemiological data – cases of measles in surrounding or contact can help in diagnostics.

Generally, in case of rash of unclear origin doctor must remember about meningococcaemia in order of possibly early specific treatment.

In differential diagnosis of diseases with meningeal syndrome it is necessary to take into account encephalitis, abscesses and tumors of brain. Diagnostics is grounding on anamnestic data (visits in endemic regions, purulent nidi in organism), clinics (symptom of “droop head” in tick-borne encephalitis, sleepiness in epidemic encephalitis, pain and vesicular rash on affected segments in herpetic, etc.), laboratory methods of diagnostics – spinal puncture, serologic reactions or culturing of pathogen from CSF, in cases of tumors, abscesses of brain – results of echoencephalography, tomography, electroencephalography or angiography, etc..

Similar to encephalitis clinical signs are seen in encephalopathies, complicating course of various exogenic and endogenic intoxications, vascular diseases – diabetes, cirrhosis of liver, chronic nephritis, arteriosclerosis, and arterial hypertension. In these cases symptoms arising on ground of decompensation of main disease, without signs of fever, CSF count is usually normal, local nervous symptoms moderate or missing.

After differential diagnostics and making plan of laboratory tests students make final clinical diagnosis valuing gravity of course, form and etiology of disease.

in 5 – 15% of general amount of complications of the disease, mainly in winter or spring season. In past history of a patient contact with person with mumps can be observed. Clinical signs of meningitis can arise before enlargement of parotid glands (12% of cases), simultaneously (26%), after (40,5%) or even without glands affection (21%). Peripheral nervous system rarely affected during mumps meningitis. Onset of disease is acute with acute headache, multiple vomiting (70% of cases), early appearance of meningeal signs, sometimes – symptoms of brain tissue affection. CSF is transparent or twinkling, protein level elevated. Lymphocytic reaction of CSF is typical. Clinical convalescence comes earlier than CSF cellular count (on 3 – 4 week of disease). Course of mumps can be accompanied with multiple complications, very often – pancreas affection. Attacks of abdominal pain (mainly around navel), sometimes encircle, nausea, repeated vomiting are typical. Elevation of amylase level can be observed during mumps independently of presence of pancreatitis, that is why diastase serum level must be checked additionally. Method of indirect agglutination can be used for detection of specific mumps antibodies serum level. 4 – times increasing of latter in dynamics of disease are diagnostic. Reaction of complement fixation can be used also.

**Enteroviral meningitis** takes second place in a group of viral meningites. Etiological agents are **Coxsackie** A group (24 serotypes), B group (6 serotypes), rarely **ECHO** – viruses (36 serotypes). Morbidity of enteroviral meningitis is increasing in spring, summer and autumn seasons. For the diseases is typical two or three wave of fever with 1-2 day intervals. Meningeal syndrome is incomplete and unstable. But some typical symptoms of enteroviral infection – muscular pain, rash, can help verify diagnosis. CSF is transparent, colorless, lymphocytic pleocytosis with normal amount of protein and glucose. Some methods of virus detection in CSF, blood, pharyngeal and nasal smears together with serological methods antibodies assay (indirect haemagglutination, immuno - enzyme assay) are also useful in diagnostics.

In epidemic period of **influenza** meningitis can be complication of the disease. Meningitis arises on ground of typical intoxication and fever, or in convalescence period. Frequent symptoms - persistent headache, vomiting, photophobia, hyperesthesia, meningeal signs are positive. Severe influenza can be complicated with meningoencephalitis. In such cases symptoms of 3, 4, 5, 6 pairs of cranial nerves affection are observed. CSF is transparent, colorless, with moderate lymphocytic pleocytosis. Additional methods – immune fluorescent microscopy with monoclonal influenza antibodies (positive result in 3-4 hrs.) and serological diagnostics (indirect haemagglutination reaction, complement fixation reaction) can be performed.

Meningeal syndrome can accompany course of **leptospirosis**. On ground of typical symptoms – muscular pain, mainly in low extremities (shins, thigh), liver and spleen enlargement, jaundice, positive Pasternatsky symptom, renal insufficiency, fever, can arise vomiting, hyperesthesia, headache. Anamnestic data – contact with animals, swimming in reservoirs, staying in endemic regions, can help verify a diagnosis. Leptomeningitis can be with serous or purulent (neutrophil) re-

action of CSF. Etiology are verified by microscopy of blood, CSF, urine, later – by diagnostic elevation of antibodies titer in dynamics of disease (reaction of leptospira agglutination, reaction of micro agglutination).

Thus, in diagnostics of serous meningitis epidemiological, anamnestic data, season of a disease, typical symptoms must be taken into account, e.g. herpetic tonsillitis with muscular pain, preceding enteroviral meningitis, saliva glands affection in mumps meningitis, etc.

Meningococcaemia (severe meningococcal sepsis) in first hours can also give lymphocytic reaction of CSF. Meningococemia may be isolated or combined with meningitis. In such cases meningeal syndrome is accompanied by septic symptoms and development of specific rash on skin in term from first hours to one day of disease. Meningococcaemia is divided on acute (typical), severe (atypical) and rarely chronic. Onset is usually acute with chill, muscular pain, weakness, and high temperature up to 40-41°C, during 2-3 days. Temperature character is continua, hectic or remittent. On examination – tachycardia, tachypnoe, sometimes BP decreasing can be observed. Most typical symptom is development of rash, beginning on 5 – 15 hours of disease. It is star – like shape, hemorrhagic, pretty large and solid elements, some – with central necrosis. By character it can vary from petechial to large, or even hemorrhages, mainly on low extremities, buttocks, trunk. In some cases papulous character of rash can be observed. Typical hemorrhages in sclera, conjunctivas, myocardium, kidneys, suprarenal glands, joints (large or medium) also can be affected. Arthritis or polyarthritis arises on 1 – 2 week of disease, and to convalescence period joints function recovers.

Typical acute meningococcaemia can be mild (3-5%), moderate (40-60%) or severe (30-40%).

Severe meningococcaemia, or severe meningococcal sepsis is a very grave form of meningococcal infection, toxic chock by nature. Latter can be divided on 3 stages: compensated, subcompensated and decompensated.

Onset is usually acute with chill, high temperature up to 40-41°C, abundant hemorrhagic rash with central necrosis, can merge up to so called “mortal spots”. Cardio-vascular insufficiency is increasing, BP is reducing to 0 mm Hg, weak pulse, and dull heart sounds. Psycho – emotional status changes from excitement, cramps to prostration and loss of consciousness. Vomiting and diarrhea with significant mixture of blood is also possible. Development of oliguria, anuria is worsening a prognosis. Meningeal signs can be harshly positive. With time arise hypothermia, anesthesia, metabolic acidosis, and hypoxemia arise. In blood analysis: hyperleucositosis, neutrophil reaction, left formula shift up to myelocytes, aneosinophilia, platelets decrease, ESR acceleration can be seen.

Chronic meningococemia is quite rare form with wave – like course (from weeks to years) and alteration of exacerbations and periods of relief. Prognosis is usually good.

Differential diagnosis of meningococcaemia should be preformed with sepsis and other diseases manifesting with rash, fever and severe intoxication.

Similar symptoms of meningococcaemia and septicemia are high, intermittent

temperature, significant intoxication, enlargement of liver and spleen, affection of joints, neutrophil leucocytosis, and ESR elevation. But temperature during septicemia has wave-like character; pustular and hemorrhagic rash without typical localization is arising to the end of first week. In contrary, for meningococcaemia is typical star-like hemorrhagic rash with central necrosis, arising on first day of disease. Hemorrhages on conjunctives, liver and spleen enlargement, repeated chills with profuse sweating, jaundice, and hypochromic anemia – are signs that also distinguish septicemia from meningococcaemia. Very important diagnostic procedures – spinal puncture with CSF analysis, culturing of blood, CSF, urine or septic nidi.

Presence of hemorrhagic rash in meningococcaemia demands differential diagnostics with thrombocytopenic purpura (Werlgoﬀ’s disease), hemorrhagic vasculitis (disease of Schönleinh - Genoch).

But onset of thrombocytopenic purpura is gradual, with following chronic course. Temperature is not typical, rash is hemorrhagic from small petechiae to big echymoses arises on 1-2 day of disease, on front surface of trunk, flexor surfaces of extremities, lasting for long time. Hemorrhages in mucous layer of mouth, conjunctivas, nasal bleeding, sometimes profuse, are frequent; but joints affection is usually absent. In blood test – insignificant leucocytosis, hypochromic anemia is typical.

Onset of hemorrhagic vasculitis is also acute, but course – gradual with relapses. Temperature can be high. Hemorrhagic, papulous, urticaria or erythematous rash arises on 1-3 day of disease on extending surfaces of extremities, buttocks, around joints, remains for 2-3 weeks. Arthritis, spleen enlargement, gastrointestinal bleeding, and hemorrhagic nephritis are possible. Nervous system affection is possible only in case of subarachnoidal hemorrhage. In blood test – insignificant leucocytosis is usual.

Leptospirosis also has some similar symptoms with meningococcaemia: acute onset, high intoxication, hemorrhagic rash, in blood test leucocytosis and increase of ESR. But pain in small of a back, shin muscles, high temperature during 5-7 days, hemorrhagic rash, arising on 3 – 4 day of disease on lateral surfaces of trunk, armpits, small petechial, but without necrosis, renal syndrome differs leptospirosis. Additional epidemiological data – contact with animals (mainly rodents), swimming or fishing in standing or boggy reservoirs, together with laboratory tests – bacteriologic and serologic (Agglutination and lysis reaction) can help to verify diagnosis properly.

Hemorrhagic, petechial rash, high temperature, severe intoxication and symptoms of meningoencephalitis, typical for typhus exanthematicus (louse-borne), resembles course of meningococcaemia. But for typhus exanthematicus typical long fever with “fits” on 4<sup>th</sup> and 8<sup>th</sup> day of disease is typical. Petechial rash arises on 5-6 day of the disease, not on 1<sup>st</sup>, like in meningococcaemia. Typical localization is back, internal surface of arms and legs. Symptoms of Rosenberg, Kiari-Avcin, Merchinson, and Govorov-Godel’e are typical for typhus exantematicus and not presented in meningococemia.

Some aged patients might already have typhus exanthematicus decades before.