

AZƏRBAYCAN RESPUBLİKASI SƏHIYYƏ NAZİRLİYİ

AZƏRBAYCAN  
TİBB JURNALI

AZERBAIJAN MEDICAL JOURNAL  
АЗЕРБАЙДЖАНСКИЙ МЕДИЦИНСКИЙ ЖУРНАЛ

*Rüblük elmi-praktik jurnal 2024, № 2*

1925-ci ildən nəşr edilir

REDAKSİYA HEYƏTİ

**Rafiq Məmmədhasənov** (*baş redaktor*)  
**Fuad İslamzadə** (*baş redaktor müavini*)  
Cəmil Əliyev, Elmar Qasimov,  
Əhliman Əmiraslanov, İvan Dedov, Mehmet Haberal

EDITORIAL STAFF

**Rafiq Mammadhasanov** (*Editor-in-Chief*)  
**Fuad Islamzada** (*Deputy Editor-in-Chief*)  
Ahliman Amiraslanov, Elmar Gasimov,  
Jamil Aliyev, Ivan Dedov, Mehmet Haberal

BAKİ

---

---

## REDAKSIYA ŞURASI

Adil Baxşəliyev (Bakı, Azərbaycan)  
Cəbrayıl Məmmədov (Bakı, Azərbaycan)  
David Virsaladze (Tbilisi, Gürcüstan)  
Əlihüseyn Hidayətov (Bakı, Azərbaycan)  
Əzizağa Talışinski (Bakı, Azərbaycan)  
Fariz Babayev (Bakı, Azərbaycan)  
Məmməd Nəsirov (Bakı, Azərbaycan)  
Nadejda Demixova (Sumı, Ukrayna)  
Niyazi Novruzov (Naxçıvan, Azərbaycan)  
Paşa Musayev (Bakı, Azərbaycan)  
Rauf Şahbazov (Sirakuz, ABŞ)  
Rəna Şirəliyeva (Bakı, Azərbaycan)  
Rizvan Abdullayev (Xarkov, Ukrayna)  
Sabir Əliyev (Bakı, Azərbaycan)  
Mansur Bünyatov (Bakı, Azərbaycan)  
Vaqif Şadlinski (Bakı, Azərbaycan)  
Valentin Fadeyev (Moskva, Rusiya)  
Yaqub Qurbanov (Bakı, Azərbaycan)

## EDITORIAL BOARD

Adil Bakhshaliyev (Baku, Azerbaijan)  
Jabrail Mammadov (Baku, Azerbaijan)  
David Virsaladze (Tbilisi, Georgia)  
Alihuseyn Hidayatov (Baku, Azerbaijan)  
Azizagha Talishinskiy (Baku, Azerbaijan)  
Fariz Babayev (Baku, Azerbaijan)  
Mammad Nasirov (Baku, Azerbaijan)  
Nadiia Demikhova (Sumy, Ukraine)  
Niyazi Novruzov (Nakhchivan, Azerbaijan)  
Pasha Musayev (Baku, Azerbaijan)  
Rauf Shahbazov (Syracuse, USA)  
Rana Shiraliyeva (Baku, Azerbaijan)  
Rizvan Abdullayev (Kharkiv, Ukraine)  
Sabir Aliyev (Baku, Azerbaijan)  
Mansur Bunyatov (Baku, Azerbaijan)  
Vagif Shadlinski (Baku, Azerbaijan)  
Valentin Fadeyev (Moscow, Russia)  
Yagub Gurbanov (Baku, Azerbaijan)

Azərbaycan Respublikası  
Mətbuat və İnformasiya Nazirliyində  
qeydə alınmışdır. Şəhadətnamə № 354

Redaksiyanın ünvanı: Azərbaycan,  
Bakı – AZ1122, H.Zərdabi küç., 96

**ISSN 0005-2523**

Tel.: (+99450) 371-66-04

E-mail: [tibbjurnali@gmail.com](mailto:tibbjurnali@gmail.com)

[www.azmedjournal.com](http://www.azmedjournal.com)

Azərbaycan Tibb Jurnalında  
dərc olunan məqalələr haqqında  
**Elsevier EMBASE**  
**(Excerpta Medica), SCOPUS və**  
**eLIBRARY.RU**  
biblioqrafik dərgilərində  
məlumat verilir

**V.V.Şinder, L.O.Herasimenko, P.V.Kidon, V.V.Borisenko, O.A.Kazakov, Yu.O.Fisun, R.İ.İsakov, D.S.Avetikov**

Kəllə və boyun deformasiyası olan xəstələrin fərdi-psixoloji xüsusiyyətləri, psixosial dezadaptasiya, həyacanlanma, depressiya, treslə əlaqəli pozuntular və onların korreksiyası

#### **EKSPERİMENTAL VƏ NƏZƏRİ TƏBABƏT**

**G.Ə.Hüseynova**

Öz boyu hündürlüyündən səth üzərinə yıxılmalar zamanı baş verən kəllə-beyin travmalarının xüsusiyyətləri

**A.İ.Qədimli, T.H.Süleymanova, C.İ.İsayev**

Azərbaycanda yayılan bəzi Acıçiçək növlərinin antibakterial və antifungal təsir xüsusiyyətləri

**D.İ.Ağayev, R.M.Meybəlizada, Ə.A.Aydınli**

Atrofiyaya uğramış çənələr üçün dental implantasiya üsulunun seçimi

**S.V.Bondarenko, S.A.Dubina, S.İ.Serbin,**

**Ye.V.Stesyuk, V.M.Filenko, Ya.A.Tarassenko,**

**O.A.Tixonova, M.N.Koptev**

Yetkin yaşlı insanlarda kəllənin parametrlərinin və beyinin yan mədəciklərinin fərdi xüsusiyyətləri, onların venoz-likvor əlaqələrinin tiplərinə görə fərqləri

**V.H.Hryn, N.L.Svintsitska, R.L.Ustenko, A.V.Pilyugin,**

**O.S.Maksimenko, İ.L.Fedorçenko, A.L.Katsenko**

Ağ siçovulların nazik bağırsaqlarında limfoid düyünlərin neogenesinin geniş təsir spektrli antibiotiklər vasitəsilə induksiyası

**V.P.Krışen, A.V.Kudryavtsev, N.N.Nor**

Eksperimental şəraitdə müxtəlif implant tiplərinin qarın divarı toxumalarına təsiri

#### **GİGİYENA, EPİDEMİOLOGİYA VƏ SƏHİYYƏ TƏŞKİLİ**

**İ.S.Babaxanov**

İnsultun tezliyi, strukturu, risk amilləri və onların nevroloji simptomlarla əlaqəsi

**A.İ.Quliyeva**

Dağınıq skleroz xəstəliyinin klinik-epidemioloji xüsusiyyətləri və müalicəsinin nəticələri

**S.A.Atakişizadə, K.Ə.Cəfərova, L.M.Qurbanova,**

**İ.A.Kərimova**

Müalicə müəssisələrində cərrahi yara infeksiyaları törədicilərinin xüsusiyyətləri

**S.A.Muradova, S.F.Qurbanova, G.M.Seyidova,**

**C.X.Talıbova**

Maya və mayabənzər göbələciklərdə endobiontun rastgəlinmə tezliyi

**R.R.Abdullaiev, E.I.Grechanik, R.Ya.Abdullaiev,**

**M.M.Xaustov, N.F.Posoxov, T.A.Dudnik,**

**A.G.Kiriçenko, N.V.Tomax**

Döyüş zamanı alınan döş qəfəsi xəsarətlərinin diaqnostikasında rentgenoqrafiya və ultrasəs müayinəsinin nəticələrinin müqayisəli qiymətləndirilməsi

#### **KLİNİK PRAKTİKADAN MƏLUMAT**

**Eynar Berdeli, Xhini Rizaj, Erda Qorri, Mustafa Can Akar**

Nəhənghüceyrəli qranulomanın minimal invaziv müalicəsi: klinik müşahidə

#### **YUBİLEY**

**MURAD QIYAS OĞLU MƏMMƏDOV – 70**

**117 V.V.Shynder, L.O.Herasymenko, P.V.Kydon, V.V.Borysenko, O.A.Kazakov, Yu.O.Fysun, R.I.Isakov, D.S.Avetikov**

Individual psychological characteristics, psychosocial disadaptation, anxiety, depression, stress-related disorders in patients with defects and deformations of the head and neck and their psychocorrection

#### **EXPERIMENTAL AND THEORETICAL MEDICINE**

**125 G.A.Huseynova**

Features of craniocerebral traumas occurring during a “fall from own height”

**131 A.I.Gadimli, T.H.Suleymanova, J.I.Isaev**

Study of antimicrobial and antifungal properties of some species of *Gentiana* L. distributed in Azerbaijan

**136 D.I.Aghayev, R.M.Meybalizada, A.A.Ayidinli**

Choosing the optimal method of dental implantation for atrophied jaws

**141 S.V.Bondarenko, S.A.Dubina, S.I.Serbin, Ye.V.Stetsuk,**

**B.M.Fylenko, Ya.A.Tarassenko, O.A.Tikhonova,**

**M.N.Koptev**

Individual parameter differences skull and lateral ventricles with the types of venous-liquor relationship in people of mature age

**148 V.H.Hryn, N.L.Svintsytska, R.L.Ustenko, A.V.Piliuhin,**

**O.S.Maksymenko, I.L.Fedorchenko, A.L.Katsenko**

Neogenesis of lymphoid nodules of small intestine of white rats induced by a broad-spectrum antibiotic

**155 V.P.Kryshen, A.V.Kudriavtsev, N.N.Nor**

Effects of various implant types on abdominal wall tissue: an experimental study

#### **HYGIENE, EPIDEMIOLOGY AND HEALTH ORGANIZATION**

**162 I.S.Babakhanov**

Frequency, structure and risk factors for stroke and Their relationship with neurological symptoms

**168 A.İ.Guliyeva**

Clinical and epidemiological characteristics and results of treatment of multiple sclerosis

**174 S.A.Atakishizade, K.A.Jafarova, L.M.Gurbanova,**

**I.A.Kerimova**

Characteristics of causative agents of surgical wound infections in medical institutions

**178 S.A.Muradova, S.F.Qurbanova, G.M.Seyidova,**

**C.X.Talıbova**

Frequency of endobiont in yeast and yeast-like fungi

**185 R.R.Abdullaiev, E.I.Grechanik, R.Ya.Abdullaiev,**

**M.M.Khaustov, N.F.Posoxov, T.A.Dudnik,**

**A.G.Kirichenko, N.V.Tomakh**

Comparative assessment of the results of radiography and ultrasonography in the diagnosis of combat chest injuries

#### **INFORMATION FROM CLINICAL PRACTICE**

**192 Eynar Berdeli, Xhini Rizaj, Erda Qorri, Mustafa Can Akar**

Minimal invasive treatment of giant cell granuloma: Casereport

#### **JUBILEE**

**196 MURAD GIYAS MAMMADOV – 70**

## DÖYÜŞ ZAMANI ALINAN DÖŞ QƏFƏSİ XƏSARƏTLƏRİNİN DİAQNOSTİKASINDA RENTGENOQRAFIYA VƏ ULTRASƏS MÜAYİNƏSİNİN NƏTİCƏLƏRİNİN MÜQAYİSƏLİ QIYMƏTLƏNDİRİLMƏSİ

R.R.Abdullayev<sup>1</sup>, E.I.Grechanik<sup>2</sup>, R.Ya.Abdullaiev<sup>1</sup>, Xaustov M.M.<sup>1</sup>,  
N.F. Posoxov<sup>3</sup>, T.A.Dudnik<sup>4</sup>, A.G.Kiriçenko<sup>5</sup>, N.V.Tomax<sup>5</sup>

<sup>1</sup>Xarkov Milli Tibb Universiteti, Xarkov, Ukrayna; <sup>2</sup>“Baş Hərbi Klinik Hospital” Milli Klinik Hərbi-Tibb Mərkəzi, Kiyev, Ukrayna; <sup>3</sup>Ukrayna Milli Tibb Elmləri Akademiyası Nevrologiya, Psixiatriya və Narkologiya İnstitutunun Neyrocərrahlik şöbəsi, Xarkov, Ukrayna; <sup>4</sup>Poltava Dövlət Tibb Universiteti, Poltava, Ukrayna; <sup>5</sup>Ukrayna Səhiyyə Nazirliyinin Tibbi və Sosial Əlillik Problemləri üzrə Ukrayna Dövlət Tədqiqat İnstitutu

**Xülasə.** Məqalədə döyüş zamanı alınan döş qəfəsi xəsarətlərinin diaqnostikasında rentgenoqrafiya və ultrasəs müayinəsinin nəticələrinin müqayisəli qiymətləndirilməsi məqsədilə aparılmış tədqiqat işi haqqında məlumat verilmişdir. Tədqiqata 94 xəstə cəlb edilmişdir. Göstərilmişdir ki, pnevmotoraks 45 (47,9%), plevra efüzyonu 36 (38,3%), qabırğa sınığı 34 (36,2%), perikardial efüzyon 11 (11,7%) xəstədə qeydə alınıb. Ultrasonoqrafiyanın həssaslığı pnevmotoraksın diaqnostikasında 89,7%, spesifikliyi – 83,3%, dəqiqliyi – 88,9%, qabırğa sınığında müvafiq olaraq – 90,3%, 66,7% və 88,2% təşkil edib.

Əldə edilmiş məlumatlara görə, pnevmotoraksın və qabırğa sınığının diaqnostikasında ultrasonoqrafiya yüksək həssaslığa, spesifikliyə və dəqiqliyə malikdir. Ultrasəs müayinəsi travma nəticəsində yaranan istənilən həcmdə plevral və perikardial eksudatın diaqnostikası üçün dəqiq və əlverişli üsuldür.

**Açar sözlər:** rentgenoqrafiya, ultrasonoqrafiya, döş qəfəsinin döyüşlə əlaqəli zədələnməsi

**Ключевые слова:** рентгенография, ультрасонография, боевая травма грудной клетки

**Key words:** radiography, ultrasonography, combat chest injuries

## COMPARATIVE ASSESSMENT OF THE RESULTS OF RADIOGRAPHY AND ULTRASONOGRAPHY IN THE DIAGNOSIS OF COMBAT CHEST INJURIES

R.R.Abdullaiev<sup>1</sup>, E.I.Grechanik<sup>2</sup>, R.Ya.Abdullaiev<sup>1</sup>, M.M.Khaustov<sup>1</sup>,  
N.F.Posoxov<sup>3</sup>, T.A.Dudnik<sup>4</sup>, A.G.Kirichenko<sup>5</sup>, N.V.Tomakh<sup>5</sup>

<sup>1</sup>Kharkiv National Medical University, Kharkiv, Ukraine; <sup>2</sup>National Military Medical Clinical Center "Main Military Clinical Hospital", Kyiv, Ukraine; <sup>3</sup>Institute of Neurology, Psychiatry and Narcology of the National Academy of Medical Sciences of Ukraine" State Institution, Kharkiv, Ukraine; <sup>4</sup>Poltava State Medical University, Poltava, Ukraine; <sup>5</sup>Ukrainian State Research Institute of Medical and Social Disability Problems of the Ministry of Health of Ukraine

**Summary.** The article presents the results of a comparative assessment of X-ray and ultrasound examinations in the diagnosis of chest wounds received during combat operations in 94 patients. It was shown that pneumothorax was registered in 45 (47.9%), pleural effusion – in 36 (38.3%), rib fracture – in 34 (36.2%), pericardial effusion – in 11 (11.7%) patients. The sensitivity of ultrasound in diagnosing pneumothorax was 89.7%, specificity – 83.3%, specificity – 88.9%, and for rib fractures – 90.3%, 66.7% and 88.2%, respectively.

According to the results, ultrasound has high sensitivity, specificity and accuracy in the diagnosis of pneumothorax and rib fractures. Ultrasound is an accurate and useful method for diagnosing pleural and pericardial effusions of any size caused by trauma.

In terms of frequency of occurrence, chest injuries during combat occupy a leading place. According to a number of authors, mortality from general chest trauma is 8.6–

16.0% [1, 2]. The consequences of thoracic injuries are fractures of the chest bones, the appearance of pleural and pericardial effusion, and pneumothorax [3]. Thanks to improve-

ments in modern body armor, blunt chest injuries are much more common during combat than penetrating injuries [4, 5]. Modern body armor is capable of protecting the body from high-speed (>300 m/s) shots [6 – 8].

As you know, radiography is the most commonly used method for diagnosing pathologies of the chest organs. However, according to some authors, the sensitivity of the method in diagnosing damage to the pleura, pulmonary parenchyma, heart and large vessels is not high [9]. In recent years, computed tomography (CT) has become the main method (gold standard) for diagnosing pathologies of the chest organs of various types [10]. Compared with conventional radiography, CT is better at detecting pulmonary contusions, pneumothorax, rib fractures and injuries to large vessels [11]. The presence of high radiation exposure to the patient and the high cost of the study are considered relative disadvantages of the method [12].

Ultrasound examination differs from x-ray methods in accessibility, low cost, and the absence of ionizing radiation. Ultrasound can also provide information about the presence of rib fractures, pleural and pericardial effusions, thereby reducing the number of chest x-rays performed in intensive care units. However, there is still a pessimistic attitude among doctors regarding the possibility of ultrasound for assessing chest pathologies [13, 14].

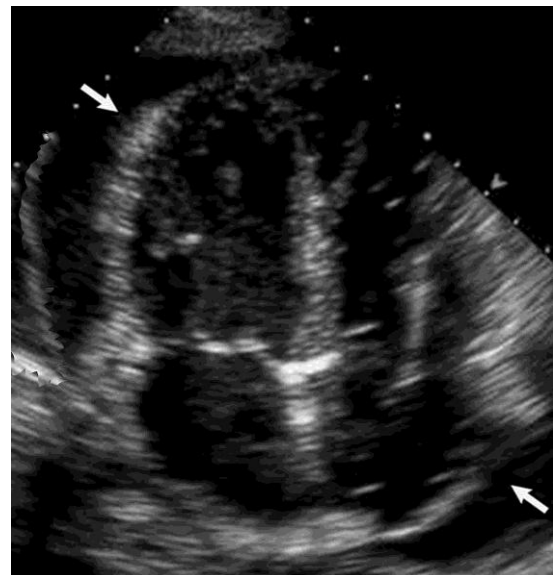
The purpose of the study is a comparative assessment of the capabilities of radiography and ultrasonography in the diagnosis of injuries to the chest organs resulting from combat trauma.

**Material and methods.** A comparative analysis of the results of radiography and ultrasonography of the chest organs was carried out in 94 patients with blunt trauma received during combat operations. The types of injuries were determined using computed tomography (CT), which is considered the gold standard for assessing chest pathologies. The age of the patients ranged from 28-46 years (mean 38±4 years). X-rays were performed in anterior and lateral projections, with patients in a vertical or horizontal position. Ultrasonography was performed on a Philips HD 11 ultrasound machine using various sensors in the frequency mode 5-10 and 2-5 MHz.

Statistical analysis was performed using the

nonparametric Mann-Whitney method. The sensitivity, specificity, and accuracy of radiography and ultrasonography in diagnosing various types of chest injuries were determined.

**Results and discussion.** In 36 (38,3%) cases the injury was right-sided, in 32 (34,0%) – left-sided, in 26 (27,7%) – bilateral. Pneumothorax was recorded in 45 (47,9%) cases, pleural effusion – in 36 (38,3%), rib fracture – in 34 (36,2%), pericardial effusion – in 11 (11,7%) cases. In 32 cases there was a combined injury. In 27 cases, pneumothorax, and in 5 cases, pericardial effusion was combined with rib fracture (Table 1). Effusion in the pericardium was not determined radiologically, but in all cases was confirmed by USG.



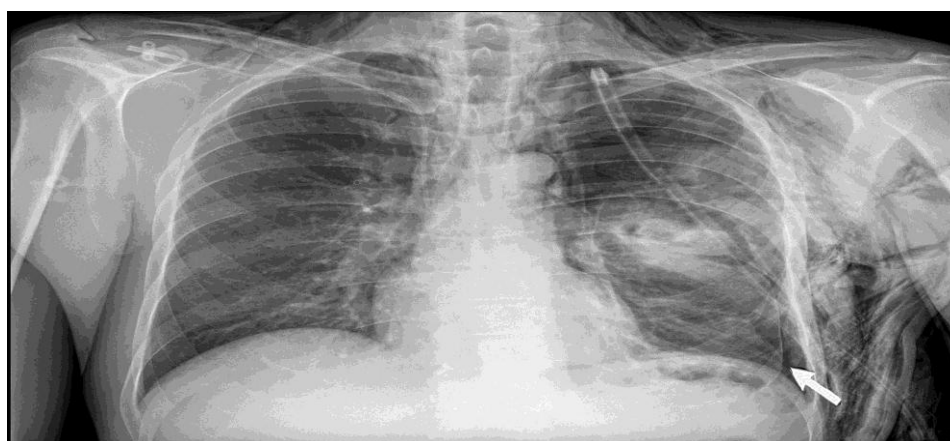
**Fig. 1.** 4-chamber apical view of the heart. Arrows show pericardial effusion in a patient due to blast combat trauma.

**Table 1** presents the results of radiography and USG in the diagnosis of pneumothorax, which was detected by CT. In 23 cases, the results of radiography were true positive (TP), in 9 cases false negative (FN), in 11 cases true negative (TN), in 2 cases false positive (FP). The sensitivity of radiography was 71.9%, the specificity was 84.6%, and the accuracy was 75.6%. In 35 cases, the results of USG were TP, in 4 cases FN, in 5 cases TN and in 1 case FP. The sensitivity of USG was 89.7%, specificity – 83.3%, accuracy – 88.9%, respectively (**Table 1**).

**Table 1. Results of radiography and USG in the diagnosis of pneumothorax**

Pneumothorax, diagnosed by CT (n=45)							
X-ray				USG			
Yes		No		Yes		No	
32		13		39		6	
TP	FN	TN	FP	TP	FN	TN	FP
23	9	11	2	35	4	5	1
Sensitivity		71,9%		Sensitivity		89,7%	
Specificity		84,6%		Specificity		83,3%	
Accuracy		75,6%		Accuracy		88,9%	

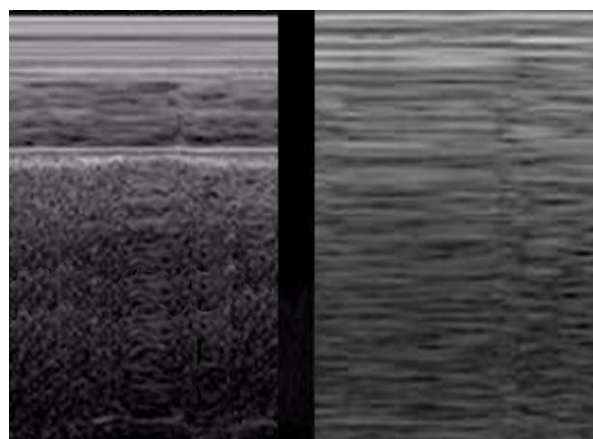
**Note:** TP – true positive, FN – false negative, TN – true negative, FP – false positive.



**Fig. 2.** The arrow shows a local absence of the vascular pattern and separation of the pleural layers, which indicates a small pneumothorax

The radiological sign of pneumothorax is the loss of the pulmonary pattern between the collapsed lung or its lobe and the parietal layer of the pleura. A large pneumothorax is characterized by a wide separation of the parietal and visceral layers of the pleura in the form of a wide vertical zone with the complete disappearance of the X-ray vascular pattern (Fig. 2).

Ultrasound diagnosis of pneumothorax was carried out using linear or convex sensors in M and B modes. In the absence of pneumothorax during inspiration, the visceral pleura shifts (slides) in the caudal direction and a small dotted image is formed on the screen, called the “sea shore” sign. Diagnosis of pneumothorax is based on identifying the “barcode” symptom, which is formed by the absence of sliding of the visceral pleura during the patient’s inhalation. The appearance of this symptom is based on the reverberation effect (Fig. 3).



**Fig. 3.** Ultrasound diagnosis of pneumothorax in M-mode. On the left side of the echogram, the “sea shore” symptom is recorded in the form of granular inclusions, on the right side – the “barcode” symptom in the form of horizontally located linear inclusions, which is formed during inspiration due to the lack of sliding of the visceral pleura in the zone of pneumothorax

**Table 2. Results of radiography and USG in the diagnosis of pleural effusion**

Pleural effusion, diagnosed by CT (n=36)							
X-ray				USG			
Yes		No		Yes		No	
32		4		35		1	
TP	FN	TN	FP	TP	FN	TN	FP
29	3	3	1	34	1	1	0
Sensitivity		90,6%		Sensitivity		97,1%	
Specificity		75,0%		Specificity		100,0%	
Accuracy		88,9%		Accuracy		97,2%	

**Note:** TP – true positive, FN – false negative, TN – true negative, FP – false positive

**Table 3. Results of radiography and USG in the diagnosis of fractured ribs**

Fractured ribs, diagnosed by CT (n=34)							
X-ray				USG			
Yes		No		Yes		No	
33		1		31		3	
TP	FN	TN	FP	TP	FN	TN	FP
32	1	1	0	28	3	2	1
Sensitivity		97,0%		Sensitivity		90,3%	
Specificity		100,0%		Specificity		66,7%	
Accuracy		97,1%		Accuracy		88,2%	

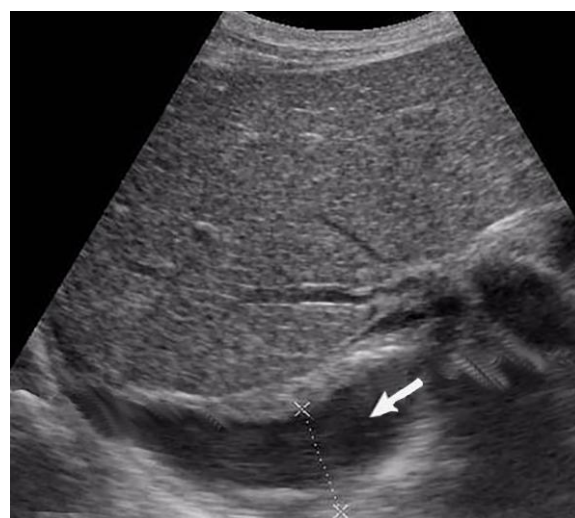**Note:** TP – true positive, FN – false negative, TN – true negative, FP – false positive

**Table 2** presents the results of radiography and USG in the diagnosis of pleural effusion. In 29 cases, the X-ray results were true positive, in 3 cases false-negative, in 3 cases true-negative, in 1 case false-positive. The sensitivity of radiography was 90.6%, the specificity was 75.0%, and the accuracy was 88.9%. In 34 cases, the results of USG were TP, in 1 case FN, in 1 case TN. The sensitivity of USG was 97.1%, specificity – 100.0%, accuracy – 97.2%, respectively (**Table 2**).

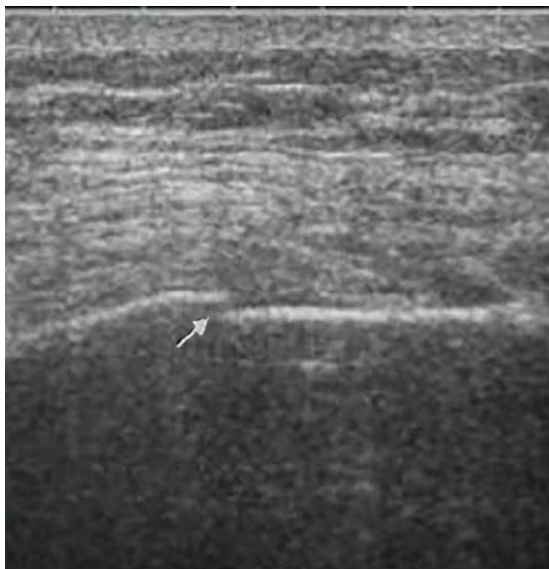
Ultrasound examination allows to detect a minimal amount of effusion in the pleural sinus, which is not determined radiographically, especially in the supine position of the patient. Hemothorax differs from hydrothorax by the presence of hyperechoic inclusions (Fig. 4).

**Table 3** presents the results of radiography and USG in diagnosing of rib fractures. In 32 cases, the X-ray results were true positive, in 1 case false-negative, in 1 case true-negative. The sensitivity of the method was 97.0%, specificity - 100.0%, accuracy - 97.1%. In 28 cases, the results of USG were true positive, in 3 cases

false-negative, in 2 cases true-negative and in 1 case false-positive. The sensitivity of USG was 90.3%, specificity – 66.7%, accuracy – 88.2%, respectively (**Table 3**).



**Fig. 4.** A right-side hemothorax (arrow) in the pleural sinus is caused by blunt chest trauma



**Fig. 5.** Ultrasound visualization of a rib fracture in the form of interruption of its image and divergence of fragments (arrow)

**Discussion.** Considering that CT is currently the gold standard for diagnosing chest injuries, the results of radiography and ultrasonography are compared with tomography data [15]. Pneumothorax is recognized as the second leading cause of preventable death on the battlefield after blood loss [16]. According to Tran J. et al. (2021) thoracic trauma accounts for approximately 25% of all trauma-related mortality, and of these cases, almost 50% of patients experience pneumothorax [17].

A study by Y M. ousefifard et al (2016) showed that the sensitivity of ultrasound in diagnosing pneumothorax was 94%, and the specificity was 98% [18]. In our study, pneumothorax was diagnosed in 45 patients using CT. According to our data, the sensitivity of ultrasound in diagnosing pneumothorax was 89.7%, specificity 83.3%.

Ultrasound accurately detects minimal

volumes of pleural effusion and fluid volumes up to 5 ml can be visualized, but a minimal volume of 20 ml is more reliably detected, and ultrasound is 100% sensitive for effusions >100 ml [19]. In our study, 36 patients had pleural effusions. In the diagnosis of pleural effusion, the sensitivity of ultrasound was 97.1% and the specificity was 100.0%.

Sabri Y.Y., et al. (2018) analyzed the results of ultrasound in 9 patients in whom CT was diagnosed with rib fractures. According to the authors, the accuracy of ultrasound was 88.9% [20]. We studied the results of ultrasound in 34 patients with rib fractures, and the accuracy of the method was 88.2%.

Ultrasound visualization of pericardial effusion in all 11 cases coincided with the results of computed tomography. The results of our studies once again confirm the high role of ultrasonography in assessing complications of blunt chest trauma and demonstrate sufficient sensitivity, specificity and accuracy in the diagnosis of pneumothorax and rib fractures. In addition, in identifying minimal pleural and pericardial effusions, the method is the most acceptable for both primary and final diagnosis.

## Conclusions

1. Despite the limited use of ultrasonography in assessing complications of blunt chest trauma, the method has sufficient sensitivity, specificity and accuracy in the diagnosis of pneumothorax and rib fractures.

2. Ultrasonography is an accurate method for diagnosing pleural and pericardial effusion of any volume resulting from trauma.

## Conflict of interest

*The authors declared no potential conflicts of interest with respect to the research, authorship, and/or publication of this article.*

## REFERENCES

1. Durso A.M., Caban K., Munera F. Penetrating thoracic Injury // Radiol Clin North Am 2015; 53(4): 675–93. vii-viii.
2. Edgecombe L., Sigmon D.F., Galuska M.A., Angus L.D. Thoracic trauma. In: *StatPearls*. Treasure Island (FL): StatPearls Publishing; May 29, 2022.
3. Schoenfeld A.J., Dunn J.C., Bader J.O., Belmont P.J. Jr: The nature and extent of war injuries sustained

- by combat specialty personnel killed and wounded in Afghanistan and Iraq, 2003–2011 // *J Trauma Acute Care Surg* 2013; 75(2): 287–91.
4. Lichtenberger J.P., Kim A.M., Fisher D. et al. Imaging of combat-related thoracic trauma — review of penetrating trauma // *Mil Med*. 2018;183(3-4):e81-e88.
  5. Lurin I., Khoroshun E., Negoduiko V., Makarov V., Shypilov S., Boroday V., Gorobeiko M., Dinets A. Retrieval of ferromagnetic fragments from the lung using video-assisted thoracoscopic surgery and magnetic tool: a case report of combat patient injured in the war in Ukraine. *International Journal of Emergency Medicine* (2023) 16:51. <https://doi.org/10.1186/s12245-023-00527-8>.
  6. Yakovenko V.V., Grechanik E.I., Abdullayev R.Ya., Bychenkov V.V., Gumenyuk K.V., Sobko I.V. Modeling of the influence of fragments of ammunition on the biological tissue of a military in protective elements of combat equipment // *Azerbaijan Medical Journal (ATJ)*, 2020, №4, pp. 107-115.
  7. Klausner M.J., McKay J.T., Bebarta V.S. et al. Warfighter personal protective equipment and combat wounds // *Med J (Ft Sam Houst Tex)*. 2021(Pb 8-21-04/05/06):72-77.
  8. Tertyshnyi S. V., Lurin I. A., Khomenko I. P., Gumeniuk K. V., Shapovalov V. Yu., Nehoduiko V.V., Gorobeiko M., Dinets A. A new approach for reconstruction of the gunshot defect of the flexor surface of the ungual (distal) phalanx by the proper transverse branch of the digital artery: a case report of combat patient injured in the Russo-Ukrainian war // *Scandinavian Journal of Trauma, Resuscitation and Emergency Medicine* (2023) 31:64. <https://doi.org/10.1186/s13049-023-01139-0>.
  9. Abdalla W., Elgendy M., Abdelaziz A.A., Ammar M.A. Lung ultrasound versus chest radiography for the diagnosis of pneumothorax in critically ill patients: A prospective, single-blind study // *Saudi J Anaesth* 2016;10:265-9. DOI: 10.4103/1658-354X.174906.
  10. Singleton J.A., Gibb I.E., Bull A.M., Mahoney P.F., Clasper J.C. Primary blast lung injury prevalence and fatal injuries from explosions: insights from postmortem computed tomographic analysis of 121 improvised explosive device fatalities // *J Trauma Acute Care Surg* 2013; 75(2 Suppl 2): S269–74.
  11. Moussavi N., Davoodabadi A.H., Atoof F., Razi S.E., Behnampour M., Talari H.R. Routine chest computed tomography and patient outcome in blunt trauma // *Arch Trauma Res* 2015; 4(2): e25299.
  12. Palas J., Matos A., Mascarenhas V., Herédia V., Ramalho M. *Radiology research and practice*; 2014. 12p. Article ID 864369.
  13. Soult M.C., Weireter L.J., Britt R.C., Collins J.N., Novosel T.J., Reed S.F., Britt L.D. Can routine trauma bay chest x-ray be bypassed with an extended focused assessment with sonography for trauma examination? // *Am Surg* 2015;81:336-40;
  14. Wongwaisayawan S., Suwannanon R., Sawatmongkornkul S., Kaewlai R. Emergency thoracic US: the essentials // *RadioGraphics* 2016;36:640–59.
  15. Pinki K. Comparative analysis of efficacy of chest X-ray and chest CT scan in patients with chest trauma: a retrospective study // *Int J Contemporary Med Surg Radiol* 2017; 2 (2): 62–4.
  16. Daurat A., Millet I., Roustan J-P., Maury C. et al. Thoracic trauma severity score on admission allows to determine the risk of delayed ARDS in trauma patients with pulmonary contusion // *Injury* 2016;47(1):147–53
  17. Tran J, Haussner W, Shah K. Traumatic Pneumothorax: a review of current diagnostic practices and evolving management // *J Emerg Med*. 2021;61(5):517-528.
  18. Yousefifard M., Baikpour M., Ghelichkhani P. et al. Screening performance characteristic of ultrasonography and radiography in detection of pleural effusion; a meta-analysis // *Emerg (Tehran)* 2016;4:1–10.
  19. Soni N.J., Franco R., Velez M.I., Schnobrich D., Dancel R., Restrepo M.I., Mayo P.H. Ultrasound in the diagnosis & management of pleural effusions // *J Hosp Med*. 2015 Dec;10(12):811–6.
  20. Sabri Y.Y., Hafez M.A.F., Kamel K.M., Abbas D.D. Evaluating the role of ultrasound in chest trauma: Common complications and computed tomography comparative evaluation. *The Egyptian Journal of Radiology and Nuclear Medicine*. 2018. Volume 49, Issue 4, December 2018, Pages 986-992. <https://doi.org/10.1016/j.ejrnm.2018.06.006>.

## СРАВНИТЕЛЬНАЯ ОЦЕНКА РЕЗУЛЬТАТОВ РЕНТГЕНОГРАФИИ И УЛЬТРАСОНОГРАФИИ В ДИАГНОСТИКЕ БОЕВЫХ ТРАВМ ГРУДНОЙ КЛЕТКИ

Р.Р.Абдуллаев<sup>1</sup>, Е.И.Гречаник<sup>2</sup>, Р.Я.Абдуллаев<sup>1</sup>, М.М.Хаустов<sup>1</sup>,  
Н.Ф.Посохов<sup>3</sup>, Т.А.Дудник<sup>4</sup>, А.Г.Кириченко<sup>5</sup>, Н.В.Томах<sup>5</sup>

<sup>1</sup> Харьковский национальный медицинский университет, Харьков, Украина;

<sup>2</sup>Национальный военный медицинский клинический центр «Главный военный клинический госпиталь»,  
Киев, Украина;

<sup>3</sup>Отделение нейрохирургии «Института неврологии, психиатрии и наркологии Национальной  
академии медицинских наук Украины».

<sup>4</sup>Полтавский государственный медицинский университет, Полтава, Украина

<sup>5</sup>Украинский государственный научно-исследовательский институт медико-социальных проблем  
инвалидности Министерства здравоохранения Украины

**Резюме.** В статье представлены результаты сравнительной оценки рентгенологического и ультразвукового исследования при диагностике ранений грудной клетки, полученных во время боевых действий у 94 больных. Показано, что пневмоторакс зарегистрирован у 45 (47,9%), плевральный выпот – у 36 (38,3%), перелом ребер – у 34 (36,2%), перикардальный выпот – у 11 (11,7%) больных. Чувствительность ультразвукового исследования в диагностике пневмоторакса составила - 89,7%, специфичность – 83,3%, точность – 88,9%, при переломе ребер – 90,3%, 66,7% и 88,2%, соответственно.

По мнению авторов, в диагностике пневмоторакса и переломов ребер УЗИ обладает высокой чувствительностью, специфичностью и точностью. Ультразвуковое исследование является точным методом диагностики плеврального и перикардального выпота любого объема, вызванного травмой.

### **For correspondence:**

**Abdullaiev Ruslan Rizvanovich**, Department of Radiology of Education and Research Institute for Postgraduate Education of Kharkiv National Medical University, Kharkiv, Ukraine

**E-mail:** ry.abdullaiev@kntmu.edu.ua