



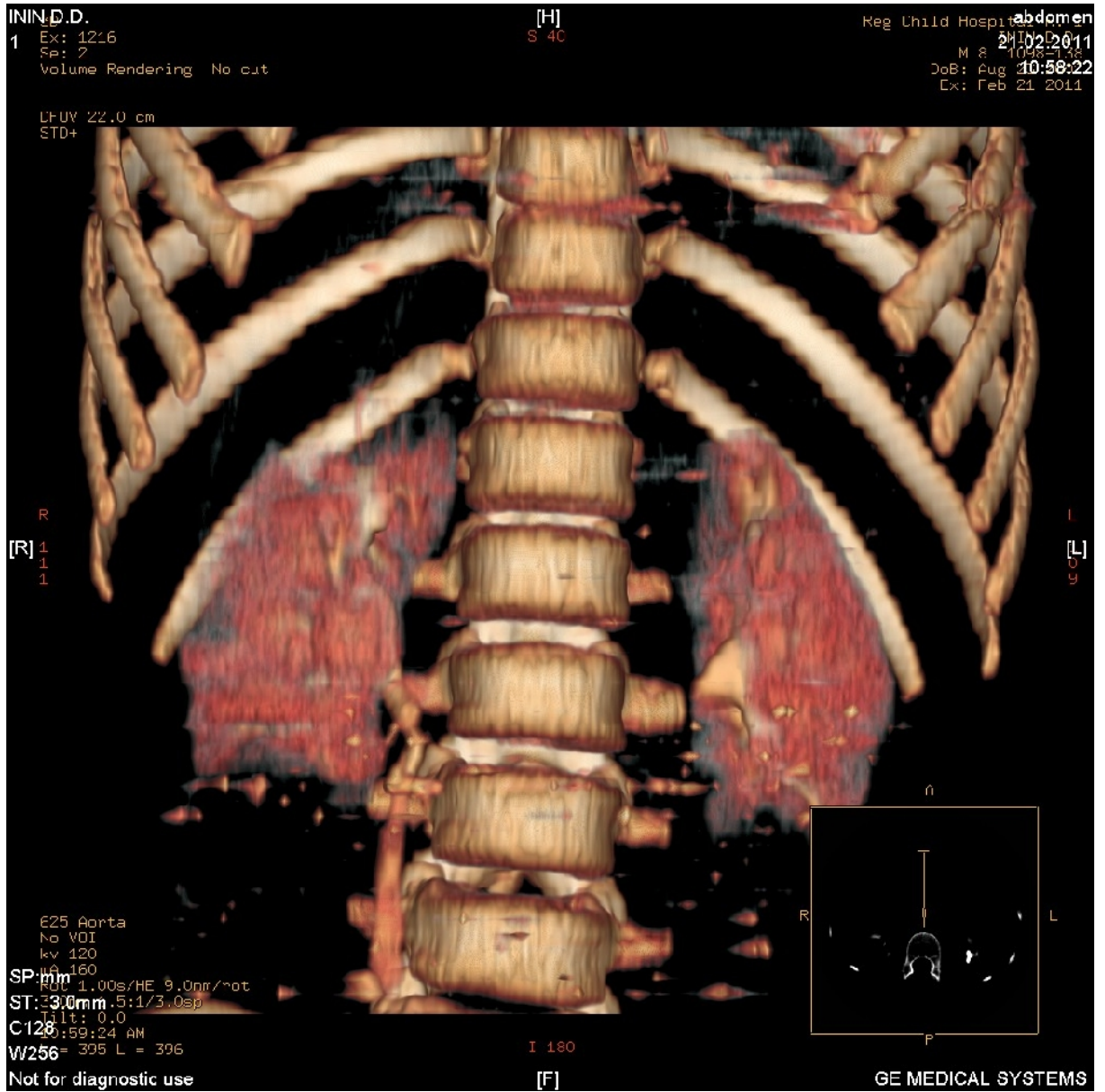




, 10-12 –  
, 3  
, 5 . , 16  
–

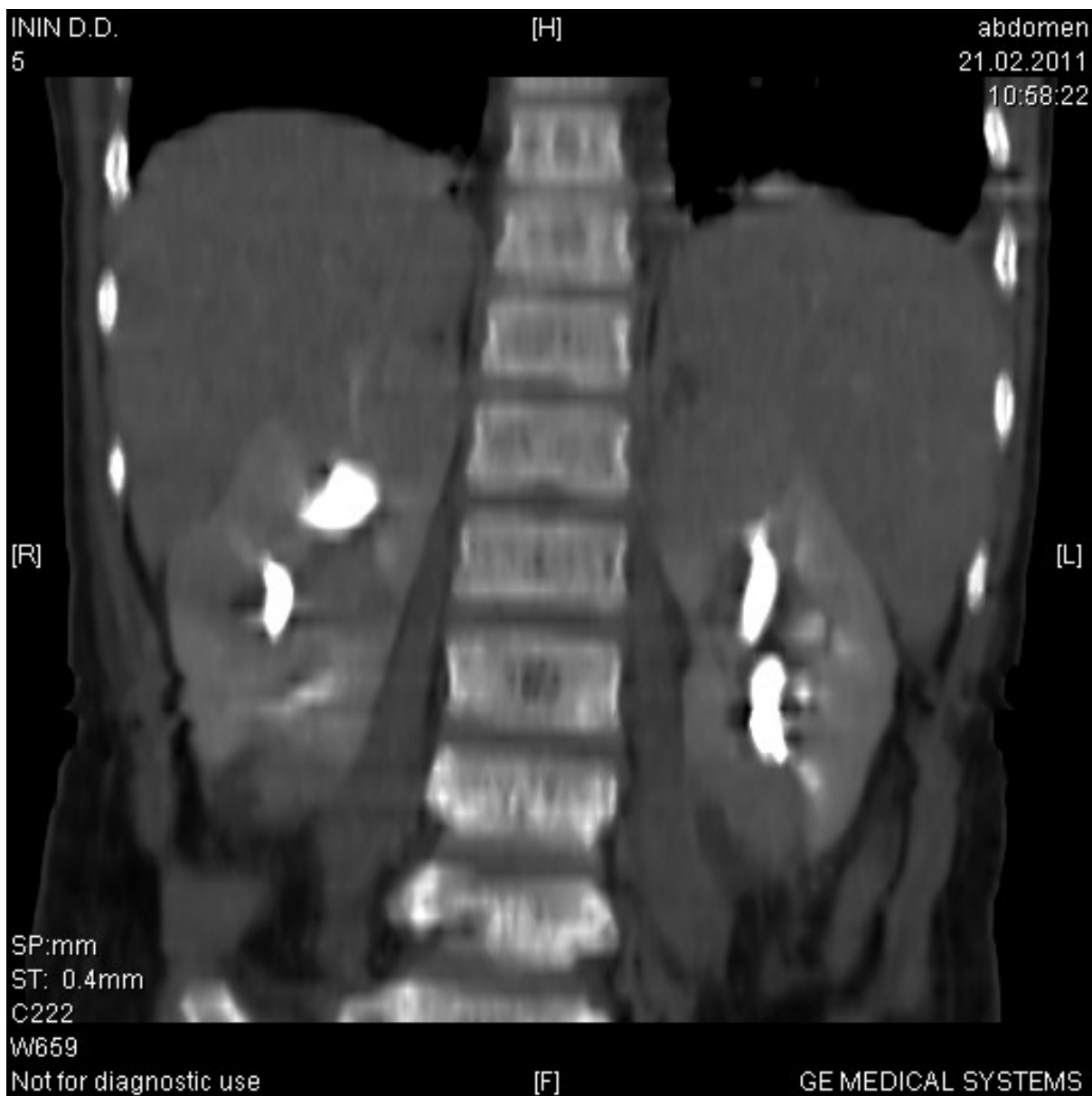- 1.
- 2.
- 3.
- 4.
- 5.

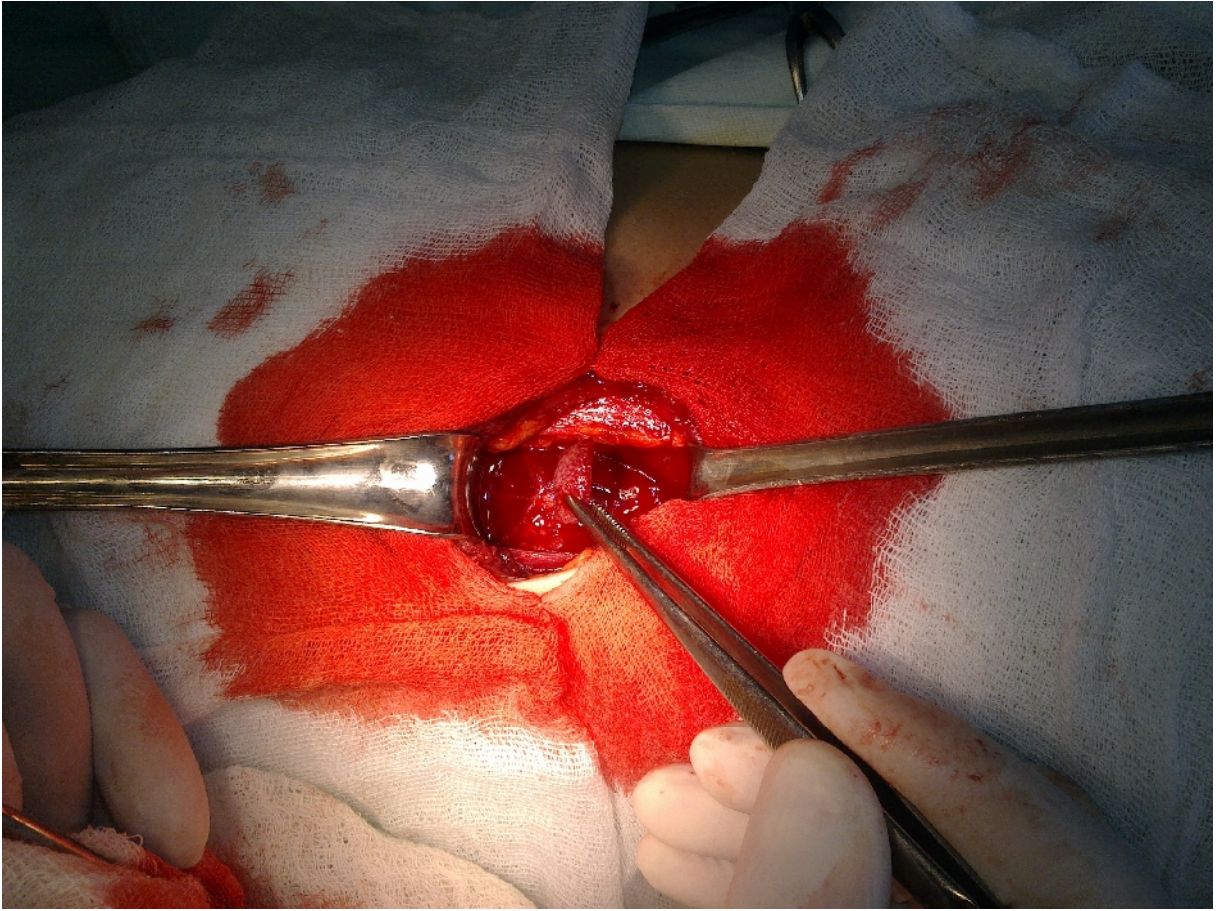
1. . . ( . ) . , , 1996. – 286 .
2. . . , . . . - . . . , 1986. – 496 .
3. : / . . . . – . : - , 2009. – 1024 .
4. Hohenfellner M., Santucci R.A.. Emergencies in Urology / Springer-Verlag Berlin Heidelberg, 2007. – 675p.
5. Pediatric urology / [edited by] John P. Gearhart, Richard C. Rink, Pierre D.E. Mouriquand. – Saunders – Elsevier, 2010. – 845p.



.1 -

(3D)





.3 -

## **Favorable outcome of the treatment of multiple carbuncles of both kidneys in a child**

Lapshin V.V., Davidenko V.B., Shttyker S.Yu.

Kharkiv national medical university

**Summary.** In the article a case of successful treatment of a child in urosepsis state, induced by bilateral multiple carbuncles of kidneys, is presented. Doppler ultrasound and computed tomography are supposed to be cardinal diagnostic possibilities. Timely diagnosis and extensive drainage operation using renal decapsulation constitute guarantee of success.

**Key words:** carbuncle of kidney, Doppler ultrasound, computed tomography, urosepsis.