



Wiadomości Lekarskie

Official journal of the Polish Medical Association



Memory of
dr Władysław
Biegański

VOLUME LXXV, ISSUE 1 PART 2, JANUARY 2022

Since 1928



ALUNA Publishing House

CONTENTS

ORIGINAL ARTICLES

- Lubov M. Matvieienko, Rostyslav Y. Matvieienko, Olena O. Fastovets
EFFECTS OF STRONTIUM RANELATE ON ALVEOLAR BONE IN RATS WITH EXPERIMENTAL DIABETES MELLITUS 151
- Iuliia G. Romanova, Olena L. Zolotukhina, Georgy O. Romanov, Stanislav A. Shnaider, Iryna M. Tkachenko
STATE OF MICROCIRCULATION AND FREE-RADICAL PROCESSES OF PERIODONTAL TISSUES IN SMOKING DEPENDENT PATIENTS WITH CHRONIC GENERALIZED PERIODONTITIS ASSOCIATED WITH CHRONIC HYPERACID GASTRITIS 156
- Luma Essa Hamodi, Alaadin Sahham Naji, Sajidah Hussein Ismael
FACTORS ASSOCIATED WITH ANEMIA IN WOMEN OF REPRODUCTIVE AGE IN IRAQI FEMALES SAMPLE 164
- Mykhailo S. Myroshnychenko, Tetiana M. Moiseienko, Inna I. Torianyk, Victoria Yu. Ivannik, Natalia G. Popova, Ivan V. Mozhaiev, Tetiana V. Chastii, Valerii V. Minukhin, Pavlo A. Leontiev, Tetiana P. Osolodchenko, Kyrylo Yu. Parkhomenko
SEBORRHEIC KERATOSIS: CURRENT STATE OF THE PROBLEM 172
- Svetlana Bychkova, Oleg Bychkov, Galyna Osyodlo, Victoria Khomaziuk, Anatoliy Kazmirchuk, Tetiana Ostashevska, Alina Tarasiuk
THE MAIN EPIDEMIOLOGICAL AND DIAGNOSTICAL FEATURES OF CHRONIC OBSTRUCTIVE PULMONARY DISEASE IN SERVICEMEN OF THE ARMED FORCES OF UKRAINE IN THE CONDITIONS OF JOINT FORCES OPERATION 176
- Sergii O. Siromakha, Yuliia V. Davydova, Vitalii I. Kravchenko, Vasyl V. Lazoryshynets
CARDIOPULMONARY BYPASS IN PREGNANCY. A SINGLE-CENTER EXPERIENCE 181
- Vasyl Miskiv, Oxana Zhurakivska, Haliia Kulynych, Mariana Kulynych-Miskiv, Olga Antimis, Ulyana Dutchak
AGE FEATURES OF THE STRUCTURE OF THE BLOOD VESSELS OF THE SOME DIGESTIVE GLANDS AND ITS RESTRUCTURING IN THE INITIAL STAGES OF EXPERIMENTAL DIABETES MELLITUS 187
- Dmytro G. Konkov, Aliaksei Y. Zhurauleu, Oksana M. Honcharenko, Tetiana V. Lobastova, Taras V. Shevchuk
THE CLINICAL ASSESSMENT OF THE CERVICAL PERFORATED PESSARY FOR THE PREVENTION OF PRETERM LABOR IN WOMEN WITH PRIOR PRETERM BIRTHS 191
- Maksym Nazarevych, Roman Ohonovskyi, Khrystyna Pohranychna, Oleh Mokryk, Yuriy Melnychuk, Andriy Stasyshyn
FREQUENCY AND NATURE OF DISORDERS IN PSYCHO-EMOTIONAL AND AUTONOMIC SYSTEMS IN PATIENTS WITH MIDDLE FACIAL INJURY 197
- Anzhelika L. Filipyuk, Nataliya S. Bek, Valentyna O. Sklyarova, Ihor T. Filipyuk, Zoryana O. Huk-Leshnevskva, Iryna B. Zhakun
LOW SERUM BILIRUBIN LEVELS IN WOMEN WITH THE ANTIPHOSPHOLIPID SYNDROME 203
- Nadiia Masik, Sergiy Nechiporuk, Anastasiya-Aleksandra Fomina
INFLUENCE OF INTERVAL NORMOBARIC HYPOXYTHERAPY ON THE PROCESSES OF ISCHEMIC PRECONDITIONING IN THE MYOCARDIUM OF PATIENTS WITH CHRONIC OBSTRUCTIVE PULMONARY DISEASE 209
- Tamila V. Sorokman, Snizhana V. Sokolnyk, Pavlo M. Moldovan, Nadiia Ya. Chernei, Valentuna G. Ostapchuk
IMPROVEMENT OF ERADICATION THERAPY IN CHILDREN WITH DUODENAL ULCER ASSOCIATED WITH HELICOBACTER PYLORI 215
- Oleksiy Oparin, Liudmyla Khomenko, Yuliia Dvoyashkina, Olena Sergienko, Maryna Kochueva, Olga Morozova, Sergey Pavlov
MECHANISMS OF THE FORMATION OF MOTOR-SECRETORY DISORDERS IN PATIENTS WITH GERD WITH CONCOMITANT AIT 223
- Yulia Lysokon, Yurii L. Bandrivskyi, Mykhailo A. Luchynskyi
ANALYSIS OF THE RESULTS OF TREATMENT OF DESTRUCTIVE FORMS OF APICAL PERIODONTITIS WITH OSTEOTROPIC DRUGS IN A SHORT TERM 228
- Iryna S. Lembyrk, Oksana V. Tymoshchuk, Lesia Ya. Ivanyshyn, Oksana V. Kuzenko, Inna V. Shlimkevych, Olena A. Holodnykh
CHARACTERISTICS OF CERTAIN INDICES OF MINERAL METABOLISM IN CHILDREN WITH KIDNEY CALCULI 232
- Vitaliy N. Seredyuk, Igor P. Vakaliuk, Nestor M. Seredyuk, Sergiy V. Fedorov, Mykola M. Ostrovskyi
CLINICAL PECULIARITIES AND PATHOGENETIC DETERMINANTS OF DEVELOPMENT AND PROGRESSION OF CHRONIC PULMONARY HEART WITH ARTERIAL HYPERTENSION 237
- Volodymyr Shaprinshkiy, Andriy Verba, Tetiana Formanchuk, Andrii Formanchuk, Oleksandr Chernychenko
SURGICAL TREATMENT OF ECHINOCOCCOSIS OF THE LIVER AND ITS COMPLICATIONS 244

ORIGINAL ARTICLE

SEBORRHEIC KERATOSIS: CURRENT STATE OF THE PROBLEM

DOI: 10.36740/WLek202201204

Mykhailo S. Myroshnychenko¹, Tetiana M. Moiseienko², Inna I. Torianyuk², Victoria Yu. Ivannik², Natalia G. Popova¹, Ivan V. Mozhaiev², Tetiana V. Chastii², Valerii V. Minukhin², Pavlo A. Leontiev¹, Tetiana P. Osolodchenko², Kyrylo Yu. Parkhomenko³¹KHARKIV NATIONAL MEDICAL UNIVERSITY, KHARKIV, UKRAINE²STATE INSTITUTION «INSTITUTE OF MICROBIOLOGY AND IMMUNOLOGY NAMED BY I.I. MECHNIKOV NATIONAL ACADEMY OF MEDICAL SCIENCES OF UKRAINE», KHARKIV, UKRAINE³KHARKIV MEDICAL ACADEMY OF POSTGRADUATE EDUCATION, KHARKIV, UKRAINE**ABSTRACT****The aim** is to identify age, gender, clinical and morphological features of seborrheic keratosis.**Material and methods:** The study used biopsy material from 196 patients with a clinical diagnosis of "Seborrheic keratosis". In all cases, when studying directions for pathohistological examination, the authors analyzed gender and age characteristics, as well as localization of seborrheic keratosis. The resulting material was fixed in a 10% solution of neutral formalin (pH 7.4) for 24–48 hours. The procedure was carried out according to the generally accepted technique and the material was embedded in paraffin. Sections of 4–5×10⁻⁶m thick were made from paraffin blocks for staining with hematoxylin and eosin. The microspecimens were examined using an Olympus BX-41 microscope (Japan).**Results:** The study revealed a modern feature of seborrheic keratosis – "rejuvenation" of this tumor, as evidenced by its predominant development in patients aged 31 to 50 years. Seborrheic keratosis is more common in men, and is localized mainly on the skin of the face, scalp, neck and back. When diagnosing seborrheic keratosis, the author notes a significant discrepancy between clinical and morphological diagnoses, which actualizes the problem of improving the available clinical research methods and emphasizes the importance of morphological research. Hyperkeratotic and acanthotic histological variants of seborrheic keratosis are the most common. The case of seborrheic keratosis with malignancy and transformation into squamous cell carcinoma, identified by the author, should develop oncological alertness in doctors and patients.**Conclusions:** The study revealed age, gender, clinical and morphological features of seborrheic keratosis, which will contribute to a better understanding of this pathology by the doctors of various specialties, and improve the treatment and diagnostic process.**KEY WORDS:** seborrheic keratosis, age, gender, clinical and morphological features

Wiad Lek. 2022;75(1 p.2):172-175

INTRODUCTION

Seborrheic keratosis is a common skin tumor of epithelial origin [1]. It accounts for 20 to 61.7% of cases among all skin tumors [2]. This tumor develops in both men and women, mainly of middle and elderly age [3].

To date, there are many etiopathogenetic factors leading to the development of seborrheic keratosis. The main factors include excessive insolation, human papillomavirus, genetic predisposition, immunological and metabolic disorders, exposure to chemical reagents, radiation therapy in patients with malignant tumors etc. [4-6]. Scientists have proven the relationship between the development of seborrheic keratosis of multiple localization and the presence of malignant tumors of internal organs in a patient [7].

Seborrheic keratosis can occur anywhere on the skin except palms and soles. A few cases of this pathology on the mucous membranes of the genitals and conjunctiva have been described in literature [7].

Seborrheic keratosis at an early stage is manifested by yellow-brown spots, which gradually turn into bulging plaques. The latter have a soft consistency, a rough greasy surface, varying in size (from a few millimeters to several centimeters). Over the years, these formations increase in the size and number [8].

The diagnosis of seborrheic keratosis is a difficult task for the clinician, given the variety of clinical signs of this pathology. Here, morphological research methods play an important role in the diagnosis of seborrheic keratosis [9].

THE AIM

The purpose is to identify age, gender, clinical and morphological features of seborrheic keratosis.

MATERIALS AND METHODS

The study used biopsy material from 196 patients with a clinical diagnosis of "Seborrheic keratosis". In all cases, when studying directions for pathohistological examination, the authors analyzed gender and age characteristics, as well as localization of seborrheic keratosis. The resulting material was fixed in a 10% solution of neutral formalin (pH 7.4) for 24–48 hours. The procedure was carried out according to the generally accepted technique and the material was embedded in paraffin. Sections of 4–5×10⁻⁶m thick were made from

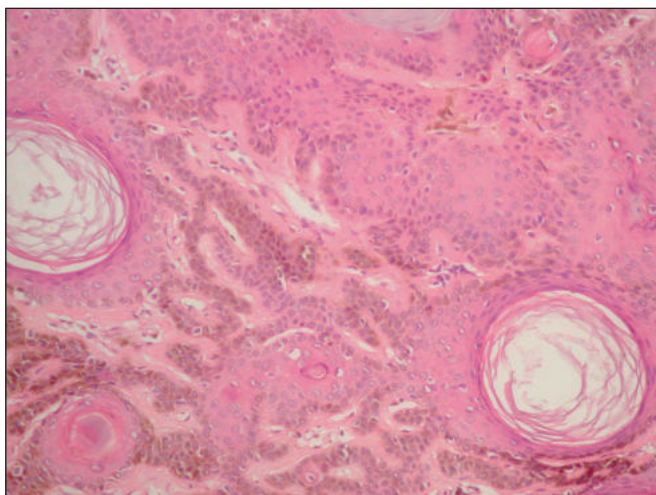


Fig. 1. Hyperkeratotic variant of seborrheic keratosis. Melanin in the tumor parenchyma. Hematoxylin and eosin staining, $\times 200$.

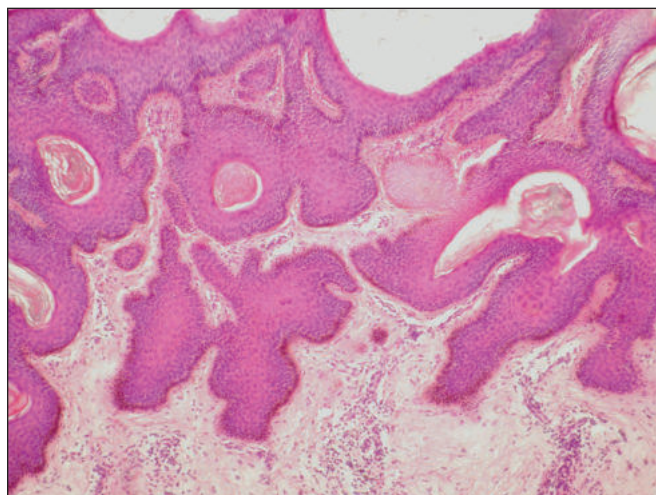


Fig. 2. Acanthotic variant of seborrheic keratosis. Hematoxylin and eosin staining, $\times 100$.

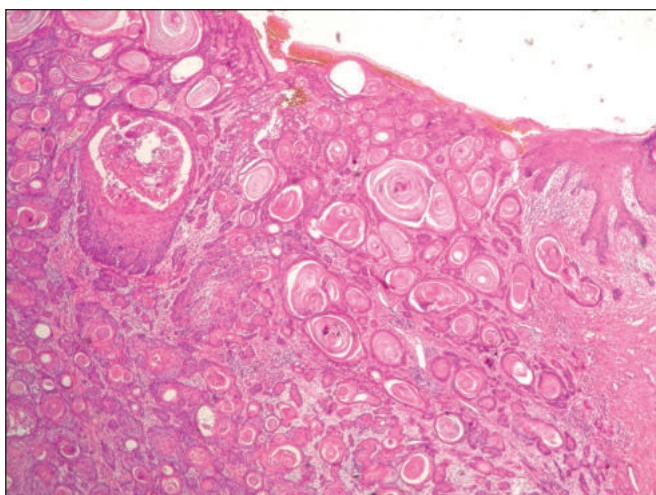


Fig. 3. Squamous cell carcinoma of the skin. Hematoxylin and eosin staining, $\times 40$.

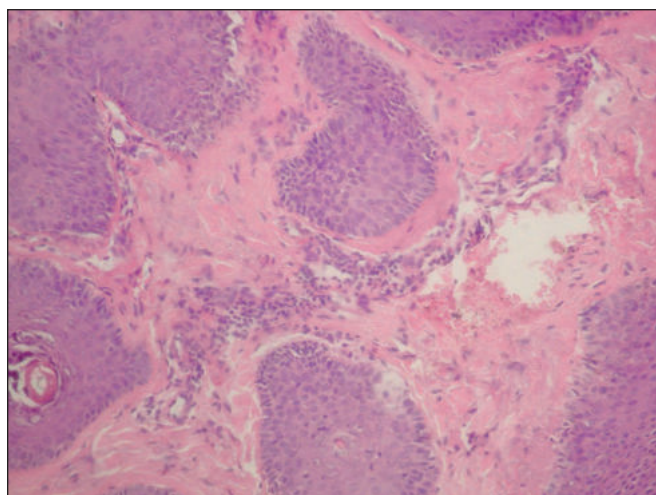


Fig. 4. Lymphoid-histiocytic infiltration with an admixture of a few neutrophilic leukocytes in the stroma of the acanthotic variant of seborrheic keratosis. Hematoxylin and eosin staining, $\times 200$.

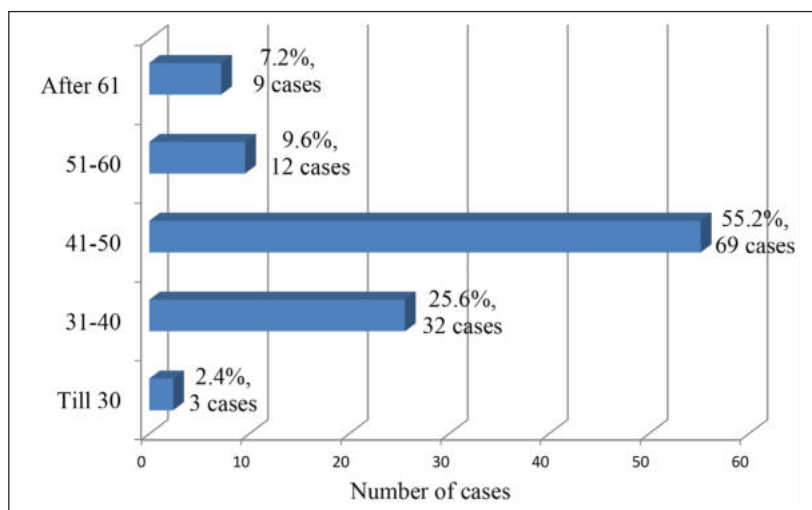


Fig. 5. Age characteristics of seborrheic keratosis.

paraffin blocks for staining with hematoxylin and eosin. The microspecimens were examined using an Olympus BX-41 microscope (Japan).

RESULTS AND DISCUSSION

Among all cases of clinically diagnosed seborrheic keratosis, morphological examination of biopsy material in

Table 1. Topographic features of seborrheic keratosis.

Localization	Number of cases	
	Absolute	Relative (%)
Face	27	21.6
Scalp	24	19.2
Neck	28	22.4
Back	26	20.8
Chest	15	12.0
Upper limbs	4	3.2
Lower limbs	1	0.8

71 cases (36.2%) revealed a discrepancy between clinical and morphological diagnoses. Among these cases, 35 patients (49.3%) had an intradermal or mixed nevus, 24 patients (33.8%) had squamous cell papilloma, 7 patients (9.9%) had basalioma of various histological variants, and 5 patients (7.0%) had condyloma. The cases, identified by us, with a discrepancy between clinical and morphological diagnoses emphasize, firstly, the need to improve existing clinical research methods, and secondly, the importance of morphological research in the diagnosis of this pathology.

According to the literature, there are three main types of cells in seborrheic keratosis: basaloid keratinocytes, spiny keratinocytes and melanocytes. Hyperkeratosis, acanthosis, papillomatosis, as well as horny cysts are found in varying degrees of severity in seborrheic keratosis [10]. The latter are pathognomonic for seborrheic keratosis. The cysts surrounded by spiny cells on the outside, flatten towards the center, lose nuclei and turn into horny masses.

There is no unified morphological classification of seborrheic keratosis in the literature. Most scientists identify six histological variants of this tumor: acanthotic; adenoid, or reticular; hyperkeratotic, or papillomatous; clonal; inflammatory; irritated [10].

In our study, 125 cases (63.8%) were clinically and morphologically diagnosed with seborrheic keratosis of various histological variants (hyperkeratotic, acanthotic, adenoid, irritated, seborrheic keratosis with malignancy and transformation into squamous cell carcinoma).

The hyperkeratotic variant of seborrheic keratosis, detected in 59 cases (47.2%), was characterized by moderate hyperplasia of the integumentary epithelium with severe papillomatosis and hyperkeratosis (Fig. 1). The signs of acanthosis were moderately pronounced. A frequent histological finding in this variant of the tumor was the presence of horny cysts filled with horny masses.

In 46 cases (36.8%), we identified an acanthotic variant of seborrheic keratosis, characterized by moderately pronounced processes of hyperkeratosis, papillomatosis and pronounced signs of acanthosis (Fig. 2). The latter were characterized by the formation of thickened acanthotic cords, which spread into the deep parts of the dermis. In addition, this variant of seborrheic keratosis had a significant number of horny cysts.

The adenoid variant of seborrheic keratosis was found in 16 cases (12.8%). This variant of the tumor had moderately expressed hyperplasia of the epithelium, hyperkeratosis, papillomatosis

and severe acanthosis. The latter showed the presence of thin, in places two-row, intertwining epithelial cords, which anastomosed among themselves. There were hardly any horny cysts.

In 3 cases (2.4%), we determined an irritated variant of seborrheic keratosis, characterized by cells polymorphism, presence of hyperchromic nuclei in tumor cells and mitotic figures, formation of foci of squamous cell differentiation, which resembled horny pearls in squamous cell carcinoma.

The benign nature of seborrheic keratosis does not exclude the possibility of its malignant transformation [11]. In our study, there was 1 case (0.8%) of hyperkeratotic variant of seborrheic keratosis with malignancy and transformation into squamous cell carcinoma (Fig. 3).

The literature describes isolated cases of malignant transformation of seborrheic keratosis [12]. Basal cell carcinoma, squamous cell carcinoma and melanoma associated with seborrheic keratosis may arise from the basaloid cells, squamous cells and melanocytes that are contained in seborrheic keratosis [13].

In their study, Smolyannikova V.A. et.al, found a malignant transformation of the irritated variant of seborrheic keratosis due to an increase in the expression of p53, p16 and activation of the proliferative potential of cells [11].

In all histological variants of seborrheic keratosis, focal lymphoid-histiocytic infiltration with an admixture of a few neutrophilic leukocytes was determined in the tumor stroma and the adjacent dermis (Fig. 4). This infiltration was often found around the vessels. In the tumor parenchyma, the melanin pigment varied from almost complete absence to a strong degree of expression (Fig. 1), which coincides with the literature data [8].

Thus, among all histological variants of seborrheic keratosis, a significant number of cases (105, 84.0%) accounted for hyperkeratotic and acanthotic variants. In our study, there were no cases with clonal and inflammatory variants of seborrheic keratosis.

Recent studies have found no gender differences in the incidence of seborrheic keratosis [14, 15]. In our case, seborrheic keratosis was more common ($p < 0.05$) in men (75 cases, 60.0%) than in women (50 cases, 40.0%).

When analyzing the age of patients diagnosed with seborrheic keratosis, the author noted that this pathology often developed at the age of 31 to 50 years (101 cases, 80.8%) (Fig. 5). Our data on the age characteristics of patients with seborrheic keratosis indicate the "rejuvenation" of this pathology. For many years, scientists have associated the development of seborrheic keratosis with the aging of the human body and considered its manifestations from the standpoint of involutive skin changes [16].

Analysis of seborrheic keratosis location showed its frequent development on the skin of the face, scalp, neck and back (105 cases, 84.0%) (Table 1).

Seborrheic keratosis, according to the literature, is more often localized on the skin (face, head, neck, upper limbs) which is often exposed to the sun [16].

CONCLUSIONS

1. The study revealed a modern feature of seborrheic keratosis – "rejuvenation" of this tumor, as evidenced

by its predominant development in patients aged 31 to 50 years. Seborrheic keratosis is more common in men, and is localized mainly on the skin of the face, scalp, neck and back.

2. When diagnosing seborrheic keratosis, the author notes a significant discrepancy between clinical and morphological diagnoses, which actualizes the problem of improving the available clinical research methods and emphasizes the importance of morphological research. Hyperkeratotic and acanthotic histological variants of seborrheic keratosis are the most common. The case of seborrheic keratosis with malignancy and transformation into squamous cell carcinoma, identified by the author, should develop on-cological alertness in doctors and patients.

REFERENCES

1. Wollina U. Seborrheic keratoses – the most common benign skin tumor of humans. Clinical presentation and an update on pathogenesis and treatment options. *Open Access Macedonian Journal of Medical Sciences*. 2018;6(11):2270-2275.
2. Pisklakova TP, Kostenko EI, Telesheva LF. Seborejnyj keratoz: klinicheskie osobennosti i asociacija s virusom papillomy cheloveka roda β [Seborrheic keratosis: clinical characteristics and an association with the β -genus human papillomavirus]. *Almanac of Clinical Medicine*. 2017;45(2):118-126. (Ru)
3. Makurina GI, Fen SV, Cherneda LO. Dermatoskopichni ta morfologichni osoblyvosti dejakyh klinichnyh variantiv seborejnego keratozu [Dermatoscopic and morphological features of some clinical variants of seborrheic keratosis]. *Ukrainian Journal of Dermatology, Venereology and Cosmetology*. 2020;3(78):69-74. (Ua)
4. Hafner C, Hafner H, Groesser L. Genetische Grundlagen seborrhoischer Keratosen und epidermaler Nävi [Genetic basis of seborrheic keratosis and epidermal nevi]. *Pathologe*. 2014;35(5):413-23.
5. Chagas DF, Diniz LM, Badaró BA, Lucas EA. Multiple seborrheic keratoses in a previously irradiated site. *Anais brasileiros de dermatologia*. 2020;95(6):771-773.
6. Heidenreich B, Denisova E, Rachakonda S, Sanmartin O, Dereani T, Hosen I, Nagore E, Kumar R. Genetic alterations in seborrheic keratoses. *Oncotarget*. 2017;8(22):36639-36649.
7. Aleksandrova AK, Smolyannikova VA. Seborejnyj keratoz: sovremennye predstavlenija o patogeneze [Seborrheic keratosis: current concepts of pathogenesis]. *Vestnik Dermatologii i Venerologii*. 2014;4:28-34. (Ru)
8. Alexandrova AK, Smolyannikova VA. K voprosu o morfologicheskikh osobennostjakh seborejnego keratoza [On the question of morphological features of seborrheic keratosis]. *Clinical and experimental morphology*. 2019;8(2):21-27. (Ru)
9. Minagawa A. Dermoscopy-pathology relationship in seborrheic keratosis. *Journal of Dermatology*. 2017;44(5):518-524.
10. Alexandrova AK, Smolyannikova VA. Osobennosti pigmentacii seborejnego keratoza [On the peculiarities of seborrheic keratosis pigmentation]. *Vestnik Dermatologii i Venerologii*. 2019;95(3):10-15. (Ru)
11. Smolyannikova VA, Aleksandrova AK. Narushenija jekspressii belkov-reguljatorov kletchnogo cikla pri seborejnom keratoze [Impaired expression of cell-cycle regulatory proteins in seborrheic keratosis]. *Archive of Pathology*. 2020;82(2):30-34. (Ru)
12. Bedir R C, Gucer H, Sehitoğlu I. Basal cell carcinoma arising within seborrheic keratosis. *Journal of Clinical and Diagnostic Research*. 2014;8(7):YD06-YD07.
13. Cimpean I, Theate I, Vanhooteghem O. Seborrheic keratosis evolution into squamous cell carcinoma: a truly modified sun-related tumor? A case report and review of the literature. *Dermatology Reports*. 2019;11(1):7999. doi: 10.4081/dr.2019.7999.
14. Del Rosso JQ. A closer look at seborrheic keratoses: patient perspectives, clinical relevance, medical necessity, and implications for management. *Journal of Clinical and Aesthetic Dermatology*. 2017;10(3):16-25.
15. Sun MD, Halpern AC. Advances in the etiology, detection and clinical management of seborrheic keratoses. *Dermatology*. 2021. doi: 10.1159/000517070
16. Roh NK, Hahn HJ, Lee YW, Choe YB, Ahn KJ. Clinical and histopathological investigation of seborrheic keratosis. *Annals of Dermatology*. 2016;28(2):152-158.

ORCID and contributionship:

Mykhailo S. Myroshnychenko: 0000-0002-6920-8374^{A, D}
 Tetiana M. Moiseienko: 0000-0003-2069-9616^{A, D}
 Inna I. Torianyk: 0000-0001-6843-8808^B
 Victoria Yu. Ivannik: 0000-0002-8688-6732^C
 Natalia G. Popova: 0000-0002-2083-0402^E
 Ivan V. Mozhaiev: 0000-0003-2704-0232^F
 Tetiana V. Chastii: 0000-0002-4745-5737^E
 Valerii V. Minukhin: 0000-0002-9682-9686^B
 Pavlo A. Leontiev: 0000-0002-2321-244X^C
 Tetiana P. Osolodchenko: 0000-0001-7258-3880^F
 Kyrylo Yu. Parkhomenko: 0000-0002-0004-2417^E

Conflict of interest:

The Authors declare no conflict of interest.

CORRESPONDING AUTHOR

Mykhailo S. Myroshnychenko

Department of General and Clinical Pathophysiology,
 Kharkiv National Medical University
 str. Svetlaja27A, apt. 70, 61129, Kharkiv, Ukraine
 tel: +380501699763, +380961033038
 e-mail: msmartyshnychenko@ukr.net

Received: 10.08.2021

Accepted: 25.11.2021

A - Work concept and design, B – Data collection and analysis, C – Responsibility for statistical analysis,
 D – Writing the article, E – Critical review, F – Final approval of the article



Article published on-line and available in open access are published under Creative Common Attribution-Non Commercial-No Derivatives 4.0 International (CC BY-NC-ND 4.0)