

## CEREBRAL VENOUS DYSIRCULATION IN PATIENTS WITH CERVICOGENIC HEADACHE

Valeriy Kalashnikov

MD, PhD, Associate Professor, Kharkiv National Medical University, Ukraine

e-mail: dr.valkalash@gmail.com, orcid.org/000-0002-7012-1698

### Summary

Clinical and Doppler examination of 146 patients was carried out young age (18–44 years, including men – 75, women – 71) with cervicogenic headache. All patients were divided into two clinical groups: group 1 – cervicocranialgia – 82 patients; group 2 – posterior cervical sympathetic Barre-Lieou syndrome – 64 patients. By help triplex transcranial scanning has been studied high- speed blood flow indicators in the supraocular and vertebral veins, basal veins of Rosenthal, sinus rectus, as well as reactivity coefficients in the vertebral veins, basal veins of Rosenthal and direct sinus at applications and orthostatic and antiorthostatic functional loads. All patients were determined Doppler and signs of cerebral venous dyscirculation, mainly in the vertebral veins. Signs of venous dyscirculation were manifested in the vertebral veins and sinus rectus in patients with cervicocranialgia, as well as in vertebral veins in patients with Barre-Lieou syndrome. Leading pattern there was a violation of autoregulation of cerebral venous blood flow hyporeactivity to orthostatic and antiorthostatic loading in the vertebral veins, more pronounced in patients with cervicocranialgia. Easy hyperreactivity to antiorthostatic load on the basal veins of Rosenthal and sinus rectus in patients of both groups indicates a violation of the neurogenic mechanism in the regulation of venous blood flow.

**Key words:** cervicocranialgia, Barre-Lieou syndrome, vertebral vein, basal vein of Rosenthal, sinus rectus, autoregulation of venous blood flow, orthostatic load, anti-orthostatic load.

DOI <https://doi.org/10.23856/6426>

### 1. Introduction

Cervicogenic headache (CH) or pain caused by the pathology of the cervical spine, as a rule, unilateral, cervical-occipital localization, clearly associated with movements in the cervical region (turns, tilts of the head, uncomfortable posture, etc.) (Barmherzig *et al.*, 2019). Most often, CH occurs with pathological changes in the cervical spine of a degenerative-dystrophic genesis (dystrophic processes in the discs, instability of the cervical region, unvertebral arthrosis), which lead to compression or irritation of sensitive nerve roots, sympathetic nerves of the muscles of the neck and occipital region, which can to appear as a substrate of pain (Fredriksen *et al.*, 2015). Also of importance is the fact that the switching of sensitive neurons of the cervical segments (C1–C3) are located in the brain stem next to the nucleus of the trigeminal nerve, which carries out sensitive innervation of the face and part of the head (Bogduk, 2014; Nosedá *et al.*, 2019).

The pathophysiological basis of CH is the close connections of the first three cervical sensory roots with the trigeminal nerve, which form the trigemino-cervical system (Bogduk, 2014). Not only peripheral, but also central mechanisms are involved in the implementation of CH, namely, the changed reactivity of the structures of the limbic-reticular

complex and the dysfunction of antinociceptive control (Fredriksen, 2015). The main clinical and diagnostic criteria of CH are: one-sided headache without change of side, pain starts in the neck, spreading to the eye area, forehead, temple.

In patients with vertebrogenic genesis of headache, a sharp violation of blood flow through the vertebral arteries was noted, associated with pathological violations in the bone-ligamentous apparatus of the cervical spine, and approximately half of the examined patients also observed violations of venous blood flow (Kalashnikov, 2016; Shum et al., 2017). Hemodynamic indicators mostly had a persistent asymmetry character, indirectly confirming the congenital genesis of changes in the vertebral arteries (Bulut et al., 2016; Kalashnikov, 2016). Doppler assessment of blood flow through the main arteries of the head and neck in patients with various types of headache allows to identify the cause of the origin of these pains. Vascular disorders are often the basis of various types of headache, in particular, a decrease in the adaptive capabilities of the apparatus of autoregulation of cerebral blood circulation (Kalashnikov et al., 2021; Stoyanov et al., 2022). The blood flow rate in the vessels of the carotid artery system was within normal values, and in the arteries of the vertebrobasilar system it was slightly reduced (Kalashnikov, 2016; Shum et al., 2017).

An increase in the diameters of the vertebral veins (greater than the diameter of the accompanying artery) and vertebral plexuses and an increase in the velocity parameters at the intracranial and extracranial levels with an increase in its phase were considered signs of venous outflow obstruction by the vertebral vein system. The study of the venous outflow behind the vertebral veins revealed its violation in a significant part of patients, which was manifested by the expansion of the vertebral veins with the acceleration of blood flow (Toduia et al, 2005; Verma et al., 2021).

Available publications lack data on the results of a comparative study of venous cerebral hemodynamics in patients with various types of cervicogenic headache. These papers did not study hemodynamic features in patients with cephalic syndrome in the structure of vertebrogenic pathology (Barre – Lieou syndrome, cervicocranialgia). Also, these studies did not assess autoregulation of cerebral blood flow in cerebral veins.

**Purpose of the study.** Study of cerebral venous blood flow and reactivity of venous hemodynamics in patients with cervicogenic headache.

**Materials and methods.** Clinical and Doppler examination of 146 patients with cervicogenic headache aged 18 to 44 years, in particular, men – 75, women – 71. All patients were divided into two clinical groups: group 1 – cervicocranialgia (CCA) – 82 patients; group 2 – posterior cervical sympathetic Barre-Lieou syndrome (BLS) – 64 patients. The leading clinical syndrome in the examined patients was headache in the neck-occipital region of unilateral localization, associated with movements of the cervical spine. All patients underwent magnetic resonance imaging (MRI) of the brain and cervical spine. All patients underwent a clinical and neurological examination. the diagnosis was made according to the diagnostic criteria of the International Headache Classification of the 3rd revision. The assessment of headache characteristics was carried out using a questionnaire that allows identifying the type of headache the patient has, assessing its main qualitative and quantitative characteristics, provoking factors, accompanying symptoms, methods of pain treatment, the presence of abusive factor. Cerebral veins were examined in triplex mode on an Ultima – PA ultrasound scanner (RADMIR, Ukraine). The indicators of the maximum linear velocity of blood flow ( $V_{max}$ ) in the superior ophthalmic vein (SOV) and vertebral (VV) veins, basal veins of Rosenthal (BV), sinus rectus (SR), as well as reactivity coefficients in the VV, BV and SR with the use of orthostatic (CrvvOL, CrbvOL and CrsrOL), antiorthostatic (CrvvAOL,

CrbvAOL and CrsrAOL) loads. Control group (CG) – 50 clinically healthy volunteers of both sexes of the appropriate age. Statistical analysis and processing of the material was carried out using the "Statistisa 6.0" software package, differences with CG indicators were considered statistically significant at a value of  $p < 0.05$ .

## 2. Results and discussion

### 2.1. Clinical and neurological characteristics of patients with CH

In patients with CH nature of pain is more often defined as a dull pain of medium or high intensity (group 1 – 69 (84.1%), group 2 – 43 (67.2%) patients. Less often, the pain was throbbing (7 (8.5%) and 14 (21.9%) of patients, respectively), or a shooting character (6 (7.3%) and 7 (10.4%), statistically more often observed in patients of 2 groups. Pain is mainly localized in the neck and occiput (group 1 – 55 (67.1%) of patients, group 2 – 47 (73.4%) patients, respectively) and parietal-occipital (27 (32.9%) and 17 (26.6%) regions), with predominant irradiation in the parietal-temporal (36 (43.9%) and 19 (29.7%), fronto-orbital (29 (36.6%) and 22 (34.4%), orbital (17 (19.5%) and 23 (35.9%)) area. More often it is localized on one side, it is mainly paroxysmal (59 (71.9%) and 47 (73.4%) in nature. Pain occurs more often after being in an uncomfortable position, in particular, under sleep time (group 1 – 35 (42.7%), group 2 – 23 (35.9%) patients), turns and/or head tilt (31 (37.8%) and 29 (45.3%)), in some cases when combing the hair, neck movements, may be accompanied by a burning sensation (group 1 – 22 (26.9%), group 2 – 26 (40.7%), dizziness with nausea (25 (30.5%) and 14 (21.9%)), a feeling of noise and ringing in the ears (23 (28.0%) and 14 (21.9%)), a feeling of flickering before the eyes (12 (14.6%) and 15 (23.4%)), a decrease in visual acuity and a feeling of a veil in front of the eyes (7 (8.5%) and 9 (14.1%)), a feeling of double vision in the eyes (6 (7.3%) and 7 (10.9%)).

The presence of vegetative and visual disorders associated with irritation in patients with SBL vertebral sympathetic plexus, is the main clinical difference between these variants of headache. Accompanying symptoms in the case of CH are restriction of neck movements in one or more directions (group 1 – 35 (42.7%), group 2 – 24 (37.5%) patients), neck stiffness (29 (35.4%) and 20 (31.3%), scalp paresthesia (16 (19.5%) and 22 (34.4%)), pain in the shoulder and upper arm (21 (25.6%) and 15 (23.4%)). The headache in all groups of cupir is the reception of analgesics. In the neurological status of patients with CH, signs of autonomic dysfunction prevailed (group 1 – 42 (51.2%), group 2 – 38 (59.4%), emotional lability (37 (45.1%) and 30 (46.9%), tendon hyperreflexia with expansion of reflexogenic zones (34 (41.5%) and 31 (48.4%) in the absence of focal neurological symptoms.

### 2.2. The state of venous cerebral hemodynamics in patients with cervicogenic headache

The indicators of blood flow in the main cerebral venous collectors in patients with cervicogenic headache are shown in Table 1.

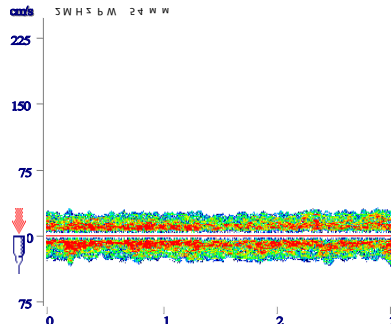
In the 1st group, the indicators of blood flow in the BV practically did not differ from the data of the CG ( $20.7 \pm 3.4$  cm/s, CG –  $18.4 \pm 4.6$  cm/s). The speed parameters of VV and SR were strengthened (VV –  $27.8 \pm 3.2$  cm/s; CG –  $20.3 \pm 4.1$  cm/s; SR –  $29.3 \pm 3.6$  cm/s, CG –  $25.2 \pm 4.2$  cm/s) (Fig. 1).

Table 1

**Hemodynamic parameters (Vmax, cm/s) in cerebral veins in patients with cervicogenic headache**

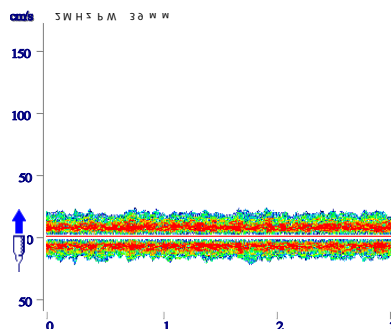
	VV	BV	SR
1 gr	27.8±3.2	20.7±3.4	29.3±3.6
2 gr	28.3±3.5 *	20.1±4.1	26.1±5.4
CG	20.3±4.1	18.4±4.6	25.2±4.2

\* p < 0.05.



**Fig. 1. Increased blood flow velocity in the SR in a patient with CCA. Vmax – 32 cm/s**

In patients of the 2nd group, there was no significant difference with CG indicators in BV and SR (BV – 20.1±4.1 cm/s; CG – 18.4±4.6 cm/s; SR – 26.1±5.4 cm/s, CG – 25.2±4.2 cm/s). Patients of the 2nd group also showed an increase in blood flow according to VV (28.3±3.5 cm/s; CG – 20.3±4.1 cm/s) (Fig. 2).



**Fig. 2. Increased blood flow velocity in VV in a patient with BLS. Vmax – 31 cm/s**

The most demonstrative differences between groups were noted in SR (29.3±3.6 cm/s in 1 group and 26.1±5.5 cm/s in 2 group).

Thus, headache in patients with CCA was mainly associated with dyscirculation along VV and SR, and in patients with BLS dyscirculation was noted along the VV.

### 2.3. Cerebral venous reactivity in patients with CH

Taking into account the peculiarities of vertebral venous hemodynamics, namely, the presence in the norm of the predominant outflow in the VV in the vertical position and its significant decrease in the horizontal position, we used orthostatic and antiorthostatic loads in the VV, BV and SR to assess the cerebral venous reactivity with the determination of the reactivity coefficients for orthostatic (CrvvOL) and antiorthostatic (CrvvAOL) loads in VV, orthostatic (CrbvOL) and antiorthostatic (CrbvAOL) loads in BV, orthostatic (CrsrOL) and antiorthostatic (CrsrAOL) loads in SR.

During the orthostatic test in VV in the group of patients with CCA and BLS, hyporeactivity was noted to CG (group 1 –  $1.53 \pm 0.06$ , CG –  $1.88 \pm 0.06$ ,  $p < 0.05$ ; group 2 –  $1.66 \pm 0.05$ , CG –  $1.88 \pm 0.06$ ,  $p < 0.05$ ). Hyporeactivity was more pronounced in patients with CCA (Table 2).

Table 2

**Indicators of venous CVR in patients with cervicogenic headache**

	<b>CrvvOL</b>	<b>CrbvOL</b>	<b>CrsrOL</b>	<b>CrvvAOL</b>	<b>CrbvAOL</b>	<b>CrsrAOL</b>
1 gr	$1.53 \pm 0.06^*$	$0.27 \pm 0.05$	$0.32 \pm 0.04$	$0.19 \pm 0.05$	$1.36 \pm 0.05$	$1.36 \pm 0.04$
2 gr	$1.66 \pm 0.05^*$	$0.29 \pm 0.04$	$0.27 \pm 0.06$	$0.20 \pm 0.04$	$1.34 \pm 0.06$	$1.38 \pm 0.07$
CG	$1.88 \pm 0.06$	$0.28 \pm 0.05$	$0.29 \pm 0.05$	$0.27 \pm 0.04$	$1.29 \pm 0.05$	$1.31 \pm 0.04$

\*  $p < 0.05$ .

Reactivity indicators during the orthostatic test in BV did not differ significantly from the data of CG (1st group –  $0.27 \pm 0.05$ , CG –  $0.28 \pm 0.05$ ; 2nd group –  $0.29 \pm 0.04$ , CG –  $0.28 \pm 0.05$ ). A similar picture was observed in the assessment of reactivity in the SR (1st group –  $0.32 \pm 0.04$ , CG –  $0.29 \pm 0.05$ ; 2nd group –  $0.27 \pm 0.06$ , CG –  $0.29 \pm 0.05$ ). By analogy with OL, conducting AOL also demonstrated hyporeactivity in VV (1st group –  $0.19 \pm 0.05$ , CG –  $0.27 \pm 0.04$ ; 2nd group –  $0.20 \pm 0.04$ , CG –  $0.27 \pm 0.04$ ). The response to AOL in BV slightly exceeded the parameters of CG and was similar in both groups (1st group –  $1.36 \pm 0.05$ , CG –  $0.29 \pm 0.05$ ; 2nd group –  $0.34 \pm 0.06$ , CG –  $0.29 \pm 0.05$ ). Mild hyperreactivity to AOL was also noted in SR (1st group –  $1.36 \pm 0.04$ , CG –  $1.31 \pm 0.04$ ; 2nd group –  $1.38 \pm 0.07$ , CG –  $1.31 \pm 0.04$ ).

The analysis of indicators of reactivity to static loads in CH demonstrated hyporeactivity to OL and AOL in VV as the leading autoregulatory pattern in both clinical groups, it is maximally expressed in patients with CCA. It was determined to be mild hyperreactivity to AOL by BV and SR in both groups. These indicators indicate a violation of the mechanisms of regulation of venous blood flow mainly according to the neurogenic circuit.

### 3. Conclusions

1. The presence of dopplerographic signs of cerebral venous dyscirculation was established with an emphasis on VV in most patients with CBG.

2. Cervicogenic headache is mainly associated with venous dyscirculation in the VV and SR in patients with CCA, as well as in the VV in patients with BLS.

3. Hyporeactivity to OL and AOL in VV was revealed, more pronounced in patients with CCA, as the leading syndrome of autoregulation with cervicogenic headache.

4. The patients of both groups have a lung installed hyperreactivity to AOL on BV and SR, which indicates a violation of the mechanisms of venous blood flow regulation, mainly according to the neurogenic circuit.

## References

1. Barmherzig R, Kingston W. (2019). *Occipital Neuralgia and Cervicogenic Headache: Diagnosis and Management*. *Curr Neurol Neurosci Rep*; 19(5):20. doi : 10.1007/s11910-019-0937-8.
2. Bogduk N. (2014). *The Neck and Headaches*. *Neurol Clin*; 32(2):471–87. DOI: <http://dx.doi.org/10.1016/j.ncl.2013.11.005>.
3. Bulut MD, Alpayci M, Senkoy E. et al. (2016). *Decreased Vertebral Artery Hemodynamics in Patients with Loss of Cervical Lordosis*. *Med Sci Monitor*; 22: 495–500.
4. Fredriksen TA, Antonaci F, Sjaastad O. (2015). *Cervicogenic headache: too important to be left undiagnosed*. *J Headache Pain*; 16:6. doi : 10.1186/1129-2377-16-6.
5. Kalashnikov VI. (2016). *Cerebral hemodynamics and cerebrovascular reactivity in patients with vertebrogenic cervicocranialgia*. *INTER COLLEGAS*;3 (4):185–189.
6. Kalashnikov VI, Stoyanov OM, Bakumenko IK, et al. (2021). *Reactivity of brain blood flow in patients with various types of headache*. *PhOL.Archives*;3:235-243. <http://pharmacologyonline.silae.it> ISSN: 1827–8620
7. Nosedá R, Melo-Carrillo A, Nir RR, et al. (2019). *Non-trigeminal nociceptive innervation of the posterior dura: implications to occipital headache*. *J Neurosci* ; 39:1867–80.
8. G, Cinnamond S, Hough D, Choy S, Whittingham W. (2017). *Doppler ultrasonography assessment of the vertebral artery in people with cervicogenic dizziness*. *J Spine* ; 6: 4.
9. Stoyanov AN Kalashnikov VI., Vastyanov RS., et al. (2022). *State of autonomic regulation and cerebrovascular reactivity in patients with headache with arterial hypertension*. *Wiad Lek*;75(9 , p2):2233–2237 DOI: 10.36740/WLek202209210
10. Todua FI, Gachechiladze DG, Beraia MV, Berulava DV. (2005). *Cerebral venous hemodynamics in chronic disorders of cerebral circulation*. *Angiol. Sosud. Khir*; 11(2): 39–43.
11. Verma S, Tripathi M, Chandra PS. (2021). *Cervicogenic Headache: Current Perspectives*. *Neurol India*; 69(Supplement): S 194–S198. doi : 10.4103/0028-3886.315992.