

**PRACTICAL SKILLS**  
**Academic discipline «Pediatric Propedeutics»**  
*Teacher's guide for the 3<sup>rd</sup> year*  
*English medium students*

**ПРАКТИЧНІ НАВИЧКИ ТА ВМІННЯ**  
**З дисципліни «Пропедевтика педіатрії»**  
**МЕТОДИЧНІ РОЗРОБКИ**  
**ДО АУДИТОРНОЇ РОБОТИ ВИКЛАДАЧІВ**

**МІНІСТЕРСТВО ОХОРОНИ ЗДОРОВ'Я УКРАЇНИ**

**Харківський національний медичний університет**

**PRACTICAL SKILLS**  
**Academic discipline «Pediatric Propedeutics»**  
*Teacher's guide for the 3<sup>rd</sup> year*  
*English medium students*

**ПРАКТИЧНІ НАВИЧКИ ТА ВМІННЯ**  
**З дисципліни «Пропедевтика педіатрії»**  
**МЕТОДИЧНІ РОЗРОБКИ**  
**ДО АУДИТОРНОЇ РОБОТИ ВИКЛАДАЧІВ**

Затверджено

Вченою радою ХНМУ

Протокол № 7 від 16.06.2016

**Харків**

**ХНМУ**

**2016**

Practical skill: Teacher's guide for the 3<sup>rd</sup> year English medium students  
/compiled by.: V.A Klymenko., O.S. Lupaltsova, D.M.Kryvorotko –  
Kharkiv: KhNMU, 2016. – 72 p.

Compiled by: Klymenko V.A.  
Lupaltsova O.S.  
D.M.Kryvorotko

**Практичні навички та вміння/** упор. В.А.Клименко, О.С.Лупальцова,  
Д.М. Криворотько– Харків, ХНМУ, 2016. – 72 с.

Упорядники: Клименко В.А.  
Лупальцова О.С.  
Криворотько Д.М.

## **Practical skill №1**

### **Measuring the pulse**

**Locations for measuring the pulse:** the two most common locations used to take a pulse are at the radial artery in the wrist and the carotid artery in the neck.

#### **Measuring the radial pulse:**

- You should place your index and middle fingers together on the wrist of patient, about 1/2 inch on the inside of the joint, in line with the index finger. You must find a pulse, count the number of beats you feel within a one minute period. Position the fingers just below the base of the thumb to take the radial pulse at the wrist (fig.1).

#### **Measuring the carotid pulse:**

- Place the tips of the index and second fingers of your hand on the side of the neck of the patient just beside the windpipe. You must place your first two fingers on either side of the neck and take the heart rate at the neck. You should be careful not too press to hard and then count the number of beats for a minute (fig.2).



Fig.1 Measuring the radial pulse




Fig.2 Measuring the carotid pulse.

The following are steps to take when measuring the pulse (table 1):

Table 1.

**Measuring of pulse**

- 1. Apply light to moderate pressure with the fingers until the blood pulsing beneath the fingers is felt. If no pulse is felt, you must move the fingers around slightly, up or down. Do not apply excessive pressure. This may compress the artery and distort the measurement.
- 2. You should count the number of beats felt in 30 seconds, using a watch or clock with a second hand. Then multiply that number by two to compute a heart rate, expressed in beats per minute. If you are taking your pulse during exercise, you may count the beats for only 10 seconds and then multiply that number by multiply by 6.
- 3. Do not use your thumb. If you do, you will feel your own pulse along with the other person's.
- 4. Checking the pulse can tell about fast of the heart beats, measuring in beats per minute, the rhythm and strength of the heartbeat.

Many things affect normal heart rate, including the age, activity level, and the time of day.

The chart that follows shows the normal range of a resting heart rate (pulse rate after resting 10 minutes) in beats per minute, according to age (table 2).

Table 2

The range of heart rate according to age

Age	Beats per minute
Newborn	120-160
First 2-3 months	140-120
7-12 months	130-120
1-2 years	90-120
3-5 years	72-110
6-7 years	70-80

## Practical skill №2

### Measuring of the blood pressure

**Locations for measuring of the blood pressure:** The standard location for blood pressure measurement is the brachial artery (fig.3). Technique of measuring of the blood pressure was illustrated in table 3.

Table 3

#### **Technique of measuring of the blood pressure**

1	Choose the right equipment:	a quality stethoscope, an appropriately sized blood pressure cuff, a blood pressure measurement instrument: an aneroid or mercury column sphygmomanometer or an automated device with a manual inflate mode.
2	For preparing the patient:	Make sure the patient is relaxed by allowing 5 minutes to relax before the first reading. The patient should sit upright with their upper arm positioned so it is level with their heart and feet flat on the floor. Remove excess clothing that might interfere with the blood pressure cuff or constrict blood flow in the arm. Be sure you and the patient refrain from talking during the reading.
3	Choose the proper blood pressure cuff size.	Most measurement errors occur by not taking the time to choose the proper cuff size. Wrap the cuff around the patient's arm and use the index line to determine if the patient's arm circumference falls within the range area. Otherwise, choose the appropriate smaller or larger cuff.
4	Place the blood pressure cuff on	Palpate/locate the brachial artery and position the blood pressure cuff so that the artery marker points to the

	the patient's arm.	brachial artery. Wrap the blood pressure cuff snugly around the arm.
5	Position the stethoscope.	On the same arm that you placed the blood pressure cuff, palpate the arm at the antecubical fossa (crease of the arm) to locate the strongest pulse sounds and place the bell of the stethoscope over the brachial artery at this location.
6	Inflate the blood pressure cuff.	Begin pumping the cuff bulb as you listen to the pulse sounds. When the BP cuff has inflated enough to stop blood flow you should hear no sounds through the stethoscope. The gauge should read 30 to 40 mmHg above the person's normal BP reading. If this value is unknown you can inflate the cuff to 160 - 180 mmHg. (If pulse sounds are heard right away, inflate to a higher pressure.)
7	Slowly Deflate the blood pressure cuff.	Begin deflation. The pressure should fall at 2 - 3 mmHg per second, anything faster may likely result in an inaccurate measurement.
8	Listen for the Systolic Reading.	The first occurrence of rhythmic sounds heard as blood begins to flow through the artery is the patient's systolic pressure. This may resemble a tapping noise at first.
9	Listen for the Diastolic Reading.	Continue to listen as the blood pressure cuff pressure drops and the sounds fade. Note the gauge reading when the rhythmic sounds stop. This will be the diastolic reading.

10	Double Check for Accuracy.	To check the pressure again for accuracy wait about five minutes between readings and taking a reading with both arms and averaging the readings. Typically, blood pressure is higher in the mornings and lower in the evenings. If the blood pressure reading is a concern or masked or white coat hypertension is suspected, a 24 hour blood pressure study may be required to assess the patient's overall blood pressure profile.
----	----------------------------	---

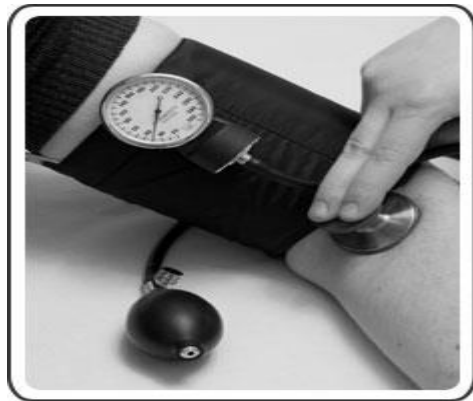

Fig. 3. Measuring Blood Pressure

Things which can alter the accuracy of readings of blood pressure:

1. Do not place the blood pressure cuff over a patient's clothing or roll a tight fitting sleeve above their biceps when determining blood pressure as either can cause elevated readings.
2. Make sure the patient has had an opportunity to rest before measuring their blood pressure.
3. If the reading is surprisingly high or low, repeat the measurement towards the end of your exam.
4. Instruct your patients to avoid any other unprescribed drug with sympathomimetic activity on the day of the measurement.

To use the blood pressure tables for children in appendix 1.

## **Practical skill №3**

### **ECG measurement**

Electrocardiography is the process of recording the electrical activity of the heart over a period of time using electrodes placed on a patient's body. These electrodes detect the tiny electrical changes on the skin that arise from the heart muscle depolarizing during each heartbeat.

The steps in setting up this basic ECG measurement are as follows:

1. Ten electrodes are used for a 12-lead ECG. The electrodes usually consist of a conducting gel, embedded in the middle of a self-adhesive pad. The most common type of electrodes for ECG application is silver/silver chloride.

2. Identify the following sites on the torso of the subject and use an alcohol swab to clean the skin beforehand. At each site, apply one of the disposable, pre-gelled ECG electrodes. Find locations as free of subcutaneous fat and muscle as possible. Don't confuse the nipples as sites. Do not remove these electrodes until the end of the lab. The names and correct locations for each electrode are as follows:

Table 3

#### **Electrode placement**

<b>Electrode name</b>	<b>Electrode placement</b>
RA	On the right arm, avoiding thick muscle
LA	In the same location where RA was placed, but on the left arm.
RL	On the right leg, lateral calf muscle.
LL	In the same location where RL was placed, but on the left leg.
V1	measures horizontally at the fourth intercostals space at the right sternal border

V2	measures horizontally at the fourth intercostals space at the left sternal border
V3	measures horizontally midway between V1 и V4
V4	measures horizontally at the fifth intercostals space at the midclavicular line
V5	measures horizontally at the fifth intercostals space at the anterior axillary line
V6	measures horizontally at the fifth intercostals space at the midaxillary line

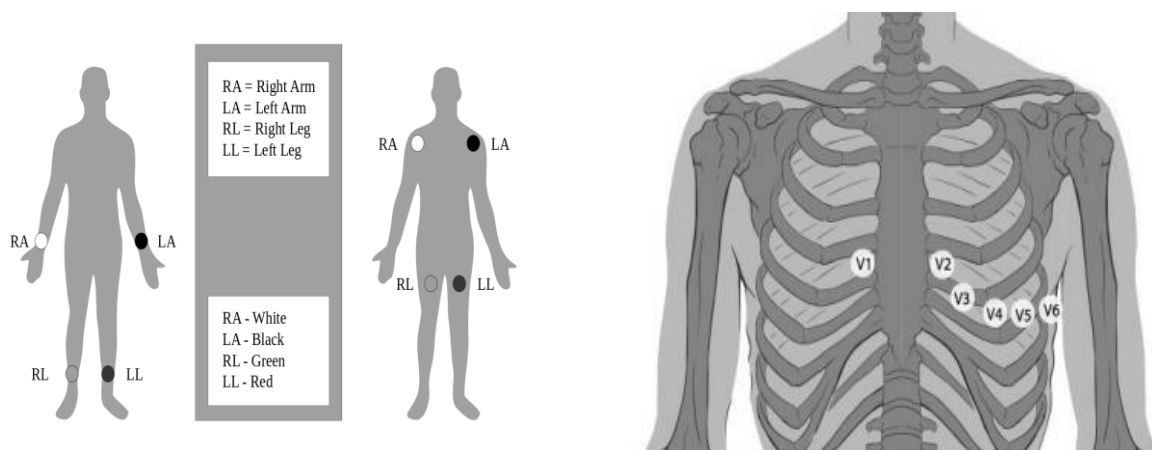


Fig.4 Electrode placement

3. The rib electrode on the right side (RL) should be the ground.
4. As before, you should make sure the subject stays quiet throughout to ensure high quality data.
5. Once you are satisfied with the signal quality, carry out the following steps:
  - a). Note the sensitivity of the ECG to motion of the subject and experiment to create the best conditions.
  - b). Save an image of the ECG on the oscilloscope using the memory function (or record with the acquisition program on the computer).
  - c). From this, compute the period and heart rate for your subject.

d). Using the acquisition program, record 10-20 seconds of a baseline ECG (be certain to record all 3 channels simultaneously so they are time aligned).

## **Practical skill №4**

### **Techniques of the intravenous injection**

**Intravenous injection** an injection made into a vein.

1. When rapid absorption is called for,
2. When fluid cannot be taken by mouth or when the substance to be administered is too irritating to be injected into the skin or muscles.
3. In certain diagnostic test and x-ray examinations a drug or dye may be administered intravenously.

### **Actions**

1. Wash hands with soap and water or alcohol hand rub. Wear a clean plastic single use apron and non-sterile gloves.
2. Tap the neck of the ampoule gently.
3. Cover the neck of the ampoule with a sterile gauze swab and snap it open
4. Inspect the solution for glass fragments, if present then discard
5. Withdraw the required amount of solution using an appropriate needle and syringe, tilting the ampoule if necessary.
6. Withdraw plunger slightly, tap syringe to dislodge any air bubbles, withdraw plunger slightly again, then carefully expel excess air to leave only the prepared intravenous drug in the syringe
7. Depress the plunger to the desired excess drug from the syringe volume to expel any
8. Remove the needle and discard in the sharps container.

Complications of the intravenous injection are as follows (table 5):

Table 5.

<b>Complications</b>	<b>Definition, Reasons, Clinically and adverse effects</b>
<b>Infiltration</b>	It is the infusion of fluid and/or medication outside the intravascular space, into the surrounding soft tissue. Generally caused by poor placement of a needle or angiocath outside of the vessel lumen. Clinically, you will notice swelling of the soft tissue surrounding the IV, and the skin will feel cool, firm, and pale. Small amounts of IV fluid will have little consequence, but certain medications even in small amounts can be very toxic to the surrounding soft tissue.
<b>Hematoma</b>	It occurs when there is leakage of blood from the vessel into the surrounding soft tissue. This can occur when an IV angiocatheter passes through more than one wall of a vessel or if pressure is not applied to the IV site when the catheter is removed. A hematoma can be controlled with direct pressure and will resolve over the course of 2 weeks.
<b>Air embolism</b>	It occurs as a result of a large volume of air entering the patient's vein via the I.V. administration set. The I.V. tubing holds about 13 CCs of air, and a patient can generally tolerate up to 1 CC per kilogram of weight of air; small children are at greater risk. Air embolisms are easily prevented by making sure that all the air bubbles are out of the IV tubing.
<b>Phlebitis and thrombophlebitis</b>	occur more frequently. Phlebitis is inflammation of the vein which occurs due to the pH of the agent being administered during the administration of the IV, while thrombophlebitis refers to inflammation associated with a thrombus. Both are

	<p>more common on the dorsum of the hand than on the antecubital facia and may occur especially in hospitalized patients where an IV may be in for several days, where use of an angiocatheter, as opposed to a needle, can increase the risk of phlebitis, as the metal needle is less irritating to the endothelium. (Needles are generally used for short term IV access of less than three hours, while angiocaths are used for longer periods of time.) The infusate itself may cause phlebitis and may be irritating to the skin. Older patients are also more susceptible to phlebitis. Treatment is generally elevating the site, providing warm compresses and administering non-steroidal agents to the patient. Anticoagulants and antibiotics are usually not required.</p>
<p><b>Extravascular injection of a drug</b></p>	<p>It may result in pain, delayed absorption and/or tissue damage (if the pH of the agent being administering is too high or too low).</p>
<p><b>An intraarterial injection</b></p>	<p>It occurs rarely, but is much more critical. The most important measure is prevention, by making sure that the needle is inserted in a vein. Remember that veins are more superficial than arteries. If you cannulate an artery, there should be a pumping of bright red blood back into your angiocath, which would not be seen when you cannulate a vein. Intraarterial injection frequently causes arterial spasm and eventual loss of limb, usually from gangrene. In the case of intraarterial injection, recognition is paramount; observe the color of the skin, observe capillary refill, and feel the radial pulse. Capillary refill, which is observed by squeezing a fingertip and then watching the red color return, is a reflection of perfusion. If capillary refill is decreased, then perfusion to that extremity is decreased.</p>

## **Practical skill №5**

### **Techniques of the intramuscular injection**

**Location of injection:** vastus lateralis muscle (0.5 mL vol.), deltoid muscle, ventrogluteal site, dorsogluteal site—not recommended for child <3 years, vastus lateralis muscle

- The **vastus lateralis site** is in the lateral middle third of the thigh between the greater trochanter and the knee. When injecting, lift the vastus lateralis muscle away from the bone.
- The **ventrogluteal site**: place the palm over the greater trochanter, form a ‘V,’ with the middle finger toward the iliac crest and the index finger toward the anterior superior iliac spine. Inject within the center of the ‘V,’ below the anterior superior iliac crest.
- The thickest part of the **deltoid muscle** is 2.5-5cm (1-3 finger breadths) below the lower edge of acromion process of the scapula over the midaxillary line.
- The **dorsogluteal site** is above an imaginary line between the greater trochanter and the posterior superior iliac crest. The injection is administered laterally and superior to this imaginary line.

### **Techniques of the intramuscular injection:**

1. Spread the skin taut, (except in vastus lateralis, which requires lifting the muscle) and insert the needle at a 90° angle.
2. Pull back plunger slightly. If blood appears, remove needle, dispose properly and prepare a new injection.
3. If no blood is present inject medication slowly.

## **Practical skill №6**

### **Techniques of the subcutaneous injection**

**Location of injection:** anterolateral thigh, upper outer Tricep area; upper buttocks, abdomen (avoid 2" radius around umbilicus)

- Raise a fold of skin between the thumb and forefinger, and insert the needle at 45-30° angle.
- Pull back plunger slightly. If blood appears in syringe, remove needle, dispose properly and prepare a new injection.
- It is not necessary to aspirate for blood return when administering insulin or heparin.

### **Techniques of the intradermal injection procedures.**

Location of injection: anterior aspect of forearm, upper chest, upper back, back of upper arm

1. Spread the skin taut, and insert the needle tip at a 10-15° angle.
2. Inject medication slowly. If a wheal does not appear, it was administered in the subcutaneous tissue.

## **Practical skill №7**

### **Techniques of the «drips intravenous infusions»**

**Indications** for IV cannulation and «drips intravenous infusions» include the following:

- Repeated blood sampling
- IV fluid administration
- IV medications administration
- IV chemotherapy administration
- IV nutritional support
- IV blood or blood products administration
- IV administration of radiologic contrast agents for computed tomography (CT), magnetic resonance imaging (MRI), or nuclear imaging



#### **For location of injection:**

- Look carefully with a tourniquet for the most suitable vein and remember that in pediatric patients the best vein may not necessarily be palpable.
- Dorsum of the non-dominant hand is preferred - the vein running between the 4th and 5th metacarpals is most frequently used.
- In addition to the usual sites, commonly used sites in children include the volar aspect of the forearm, dorsum of the foot and the great saphenous vein at ankle.
- Consider practicalities of splinting (e.g. elbow, foot in a mobile child).
- Scalp veins should only be used by more experienced doctors (shaved scalp hair re-grows very slowly).

#### **Technique:**

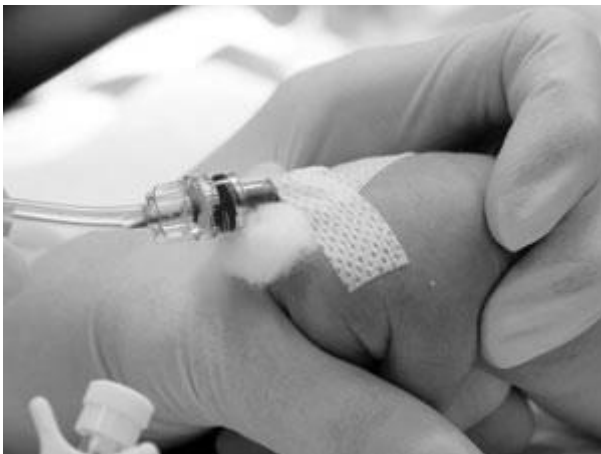- Ask the assistant to stabilise limb by holding joint above and joint below if necessary.
- If applying tourniquet, be careful of pinching skin or compressing artery.

- In infants when accessing the hand, grasp as shown; this achieves both immobilisation and tourniquet
- For inserting the cannula: decontaminate skin with alcohol wipe or alcoholic chlorhexidine 0.5% and leave to dry. Use 'no-touch' technique for insertion after decontamination.
- Insert just distal to and along the line of the vein (fig.5)
- Angle at 10-15° (fig.6)
- Advance needle and cannula slowly
- A 'flash back' of blood may not occur for small veins.
- Once in vein, advance the needle and cannula slowly a further 1-2mm along the line of the vein before advancing cannula off needle.
- Secure the hub of the cannula at the skin entry point either by holding it down or asking the assistant to place tape across.

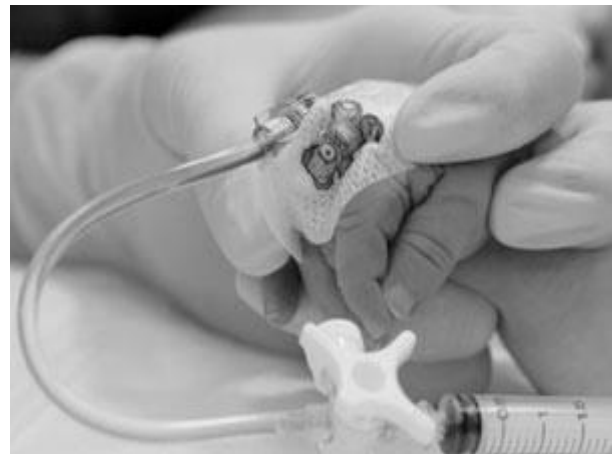	
<p><b>Fig.5.Holding an infant's hand</b></p>	<p><b>Fig. 6. Shallow angle of insertion</b></p>

- Connect the saline-filled 3-way connector to the end of the cannula by screwing it firmly on. Flush the connector tubing with more saline to confirm intravenous placement.
- In younger children use inverted cross-over straps and another tape over the top

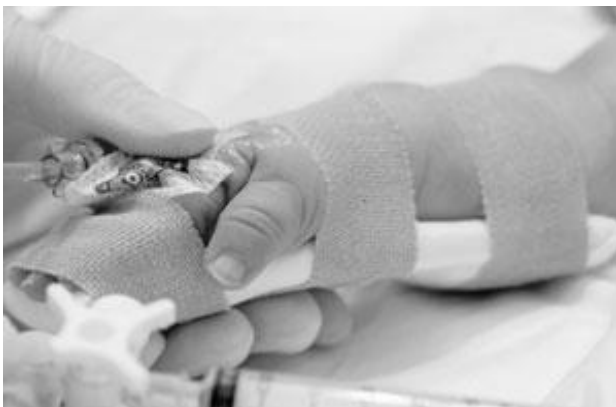- Consider placing a small piece of cotton wool ball or gauze underneath the hub of the cannula to prevent pressure areas (Fig 7)
- Place an adhesive clear plastic dressing on top (Fig 6)
- Tapes should secure the limb proximal and distal to the cannula (keeping thumb free) but not too tightly (Fig 8, 9.)
- Wrap the whole distal extremity in Tubular-Fast (Surgifix). In very young children, give consideration to bandaging the other hand as well to prevent them from removing the cannula.



**Fig 7. Pad under cannula to prevent pressure areas. IV site should remain visible**



**Fig 8. Secure with tegaderm™ so that IV site is visible**



**Fig 9. Strap so that joint is immobilised, but avoiding tapes being too tight**

## Post-Procedure Care

- Running a 'drug line' through the cannula may keep it patent for a longer period of time.
- Inspect insertion site for complications (tenderness, blockage, inflammation, discharge) hourly - check the other hand if it has also been bandaged.
- Unless complications develop, the peripheral IV should remain in situ until IV treatment complete.

### The most basic possible setup for an IV:

-IVs are most often administered by bags of fluid that come premixed. The standard sizes of these bags can range from 50 mL to 1000 mL. The bag is hung from an IV pole. The IV tubing contains several important parts (fig.10.):

- The drip chamber (fig.10., a) is located just below the IV bag; inside this chamber nurse can see the fluid drip down from the bag into the IV tubing. This is where the nurse measure the speed of a manual IV setup and look at this chamber and count the number of drops we see per minute.

- The drip chamber must always be half full. **If the** drip chamber is too full, the nurse will not be able to see the drops to count them, and so we will be unable to determine the rate at which the IV is infusing. If the drip chamber is not full enough, then this will allow air to get into the IV tubing, which means that air would get into the patient's circulatory system, which could be very dangerous, blocking a blood vessel or stopping the heart.

- The roller clamp (fig.10., b) is using for control the rate at which the IV fluid infuses. All roller clamps on a set of IV tubing should be closed before we

attach a bag of IV fluid to the top of the tubing; this ensures that no air gets into the tubing.

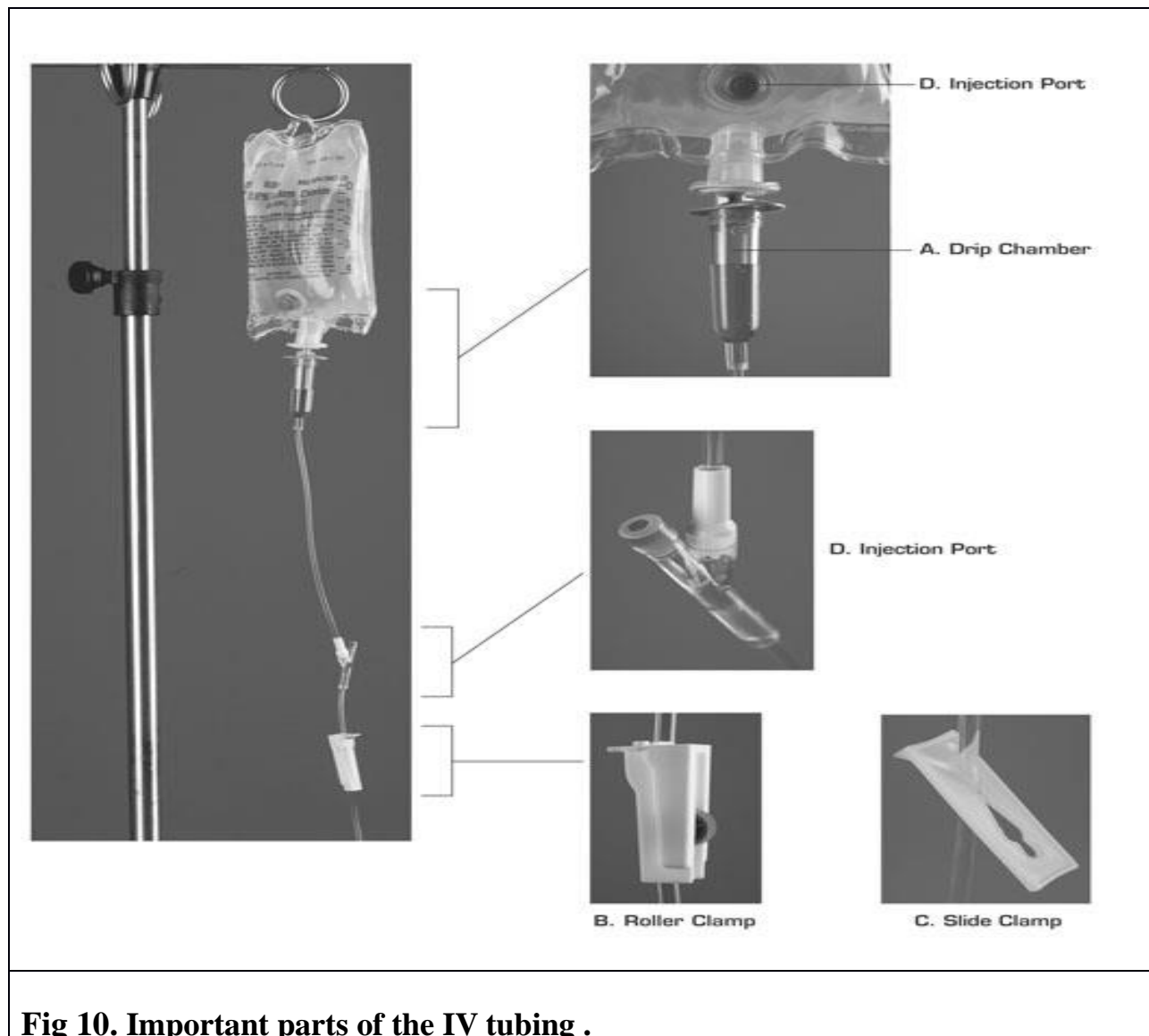
- Every IV medication will be ordered to infuse at a specific rate, and one of the major tasks of hospital nurses is to set up the IV so that it infuses at this rate and to adjust the IV periodically if the rate has changed so that it remains at the ordered rate. The rate at which an IV fluid infuses is referred to as the IV infusion rate or flow rate.

- The slide clamp (fig.10., c) is used for completely stop the IV from flowing, without having to adjust the roller clamp. This is handy for stop the IV for a moment, but nurse don't want to have to reset the flow rate by readjusting the roller clamp all over again once we start the IV up again. This works by pinching the tubing completely shut when we slide the tubing into the narrowest part of the clamp.

- The injection port (fig.10, d) is a place where medicine or fluids other than those in the current IV bag can be injected so that they will infuse into the patient's vein through the IV tubing. The injection port on the actual IV bag is used if we want to mix some kind of medication with the fluid that is in the IV bag.

- The height of the IV bag affects the infusion rate: IV infusion works because gravity pushes the fluid down through the IV tubing into the patient's vein. **The higher the bag is hung, the greater the gravitational pressure on the IV fluid to go downward through the tubing;** if the IV bag is not hung high enough, there will not be enough pressure caused by gravity to force the fluid into the vein. So, **all IV bags must be hung above the patient's heart in order for there to be enough pressure for the IV fluid to infuse.**

If the IV bag gets higher above the patient's heart, the IV infusion rate will speed up, and if the IV bag gets lower to the patient's heart, the IV infusion rate will slow down.



**Fig 10. Important parts of the IV tubing .**

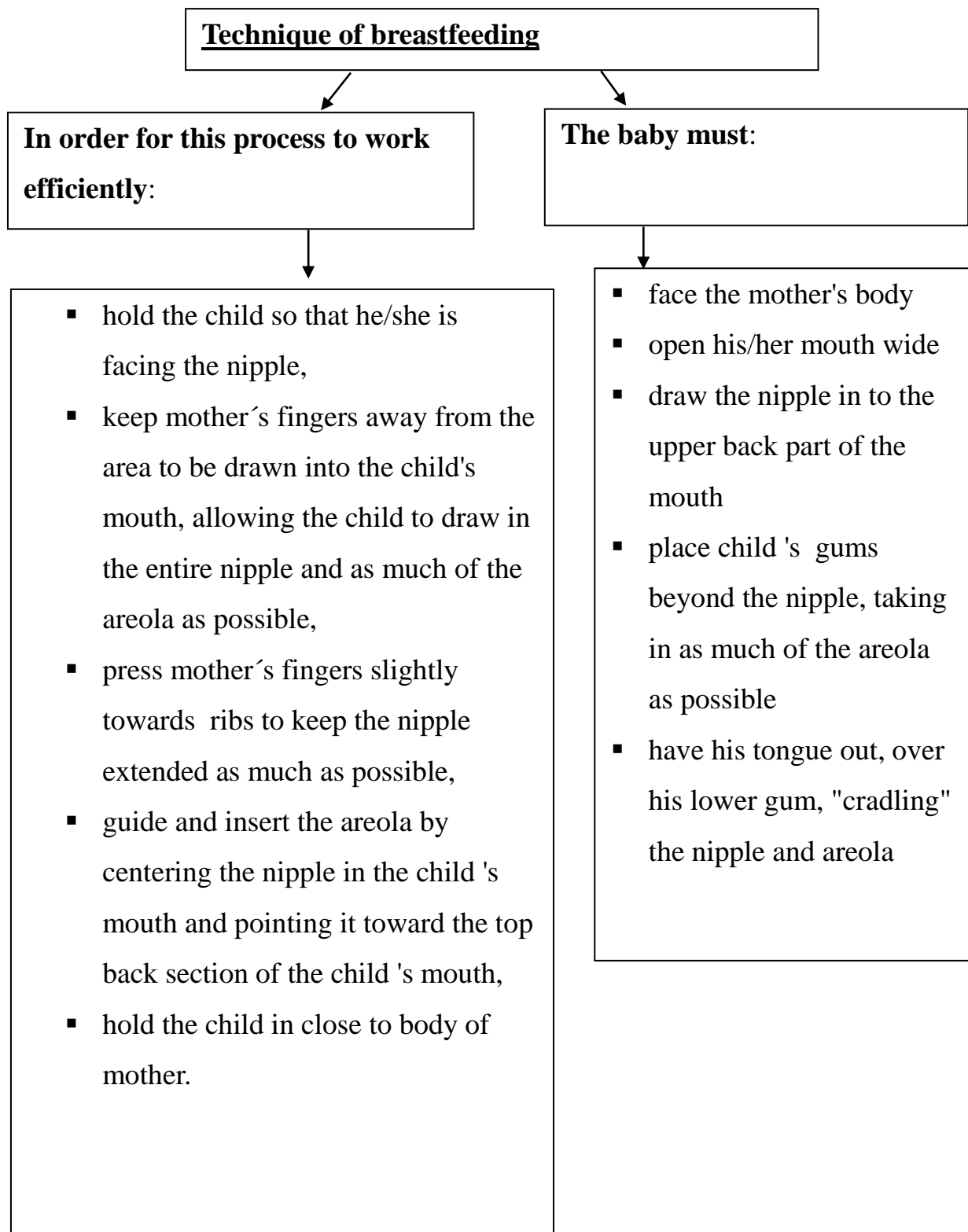
Complications of IV therapy:

- the needle can become dislodged from the vein so that the IV fluid is no longer infusing into the vein, but rather infusing into the surrounding tissue; this is called infiltration.

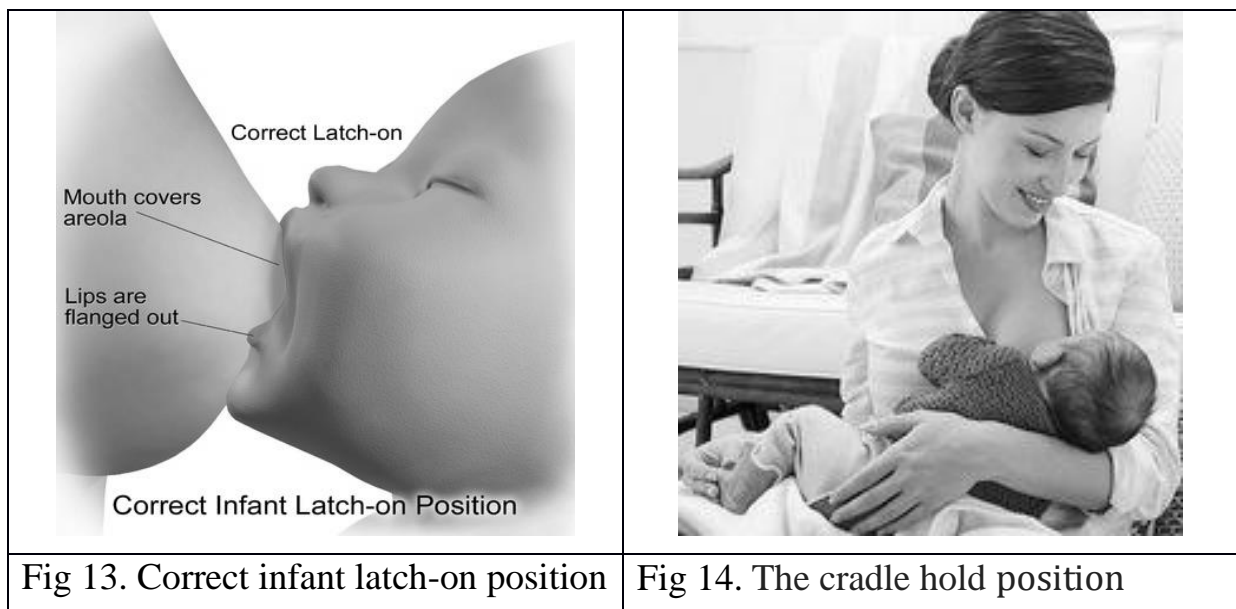
- Some of the fluid will infuse into the tissue instead of the vein, but eventually the IV will stop because the pressure from gravity will not be enough to overcome the pressure from surrounding tissue to keep additional fluid out.
- Once an IV has infiltrated, a new IV must be started in a new spot on the patient's body, and the IV must be restarted at the correct rate for the given dosage.
- Signs that an IV has infiltrated include: pain or discomfort in the area around the IV needle, swelling in the area, the area around the needle is cool to the touch,

## Practical skill №8

### Technique of breastfeeding



Correct positioning and technique for latching on are necessary to prevent nipple soreness and allow the infant to obtain enough milk. Infants can successfully latch on to the breast from multiple positions. Each child may prefer a particular position. The "football" hold places the baby's legs next to the mother's side with the baby facing the mother. Using the "cradle" or "cross-body" hold, the mother supports the baby's head in the crook of her arm. The "cross-over" hold is similar to the cradle hold, except that the mother supports the baby's head with the opposite hand. The mother may choose a reclining position on her back or side with the baby laying next to her.



The basic **technique of breastfeeding** (example, breastfeeding positions: cradle hold)) and correct infant latch-on position are illustrated (fig. 13, 14) and are as follows:

1. Cradle the infant in mother's arm, the tummy of child against mother and the head resting in the bend of mother's elbow. The ear, shoulders and hip of infant should be in a straight line.
2. Tuck the baby's lower arm out of the way, with the infant's mouth close to breast of mother.

3. Mother must support her breast with free hand; place all of mother's fingers underneath it, well away from the areola.
4. Mother should rest her thumb lightly on top of her breast above areola.
5. After lift the breast upward and lightly stroke the nipple on child's lower lip. As part of the rooting reflex, infant's mouth will open wide.
6. Mother must pull the child quickly onto the breast to latch-on when infant's mouth is opened wide, and the tongue is down. And do not lean over the child; keep her back straight, and pull the baby up to breast.
7. Basic principle of correct infant latch-on position: mouth covers areola and lips are flanged out.

For “Cross Cradle Hold position» mother must Follow the steps for cradle hold. Instead, cradle the child **with** mother's arm, infant's tummy against mother's and mother's **hand behind child's head**. Infant's ear, shoulders and hips should be in a straight line.

Football Hold position of breastfeeding

1. Position of baby so her legs and body are under mother's arm, with mother's hand holding infant's head.
2. Mother must place her fingers below the breast. Allow the baby to latch-on while pulling her in close, holding infant's head tightly against the breast.
3. Keeping the baby's body flexed at the hip with her legs tucked under mother's arm.

## **Practical skill №9**

### **Artificial tube feeding methods**

Enteral nutrition commonly called tube feeding (fig.1), refers to the delivery of nutritional formulas through a tube that has been placed into gastrointestinal tract.

#### **Planning:**

1. Expected outcomes following completion of procedure:
  - Tube is verified as placed in stomach
  - Patient has no respiratory distress (e.g., increased respiratory rate, coughing, poor color) or signs of discomfort or nasal trauma.
2. Explain procedure to patient including sensation that will be felt during insertion (for older children).
3. Explain to patient how to communicate during intubation by raising index finger to indicate gagging or discomfort (for older children).
4. Correct technique ensures placement in intended location
5. Proper irrigation clears tube of formula residue
6. Correctly placed tube causes no interference with airway.

#### **Implementation:**

1. Perform hand hygiene.
2. Position patient upright in high fowler's position (when the head of bed is elevated 80-90 degrees) unless contraindicated. If patient is comatose, raise head of bed as tolerated in semi Fowler's position with head tipped forward, chin to chest. If necessary have an assistant help with positioning of confused or comatose patients. If patient is forced to lie supine, place in reverse trendelenburg's position.

3. Determine length of tube to be inserted and mark location with tape or indelible ink.
4. Measure distance from tip to nose to earlobe to xyphoid process of sternum (fig.2).
5. Prepare nasogastric tube for intubation: inject 10 ml of water or if using stylet, make certain that it is positioned securely within tube.
6. Apply clean gloves.
7. Dip tube with surface lubricant into glass of room temperature water or apply water soluble lubricant.
8. Explain the step and gently insert tube through nostril to back of throat (posterior nasopharynx). Aim back and down toward ear.
9. Have patient flex head toward chest after tube has passed through nasopharynx.
10. Encourage patient to swallow by giving small sips of water. Advance tube as patient swallows.
11. Reemphasize need to mouth breathe and swallow during procedure.
12. Advance tube each time patient swallows until desired length has been passed.
13. Check for position of tube in back of throat with penlight.
14. Temporarily anchor tube to nose with small piece of tape.

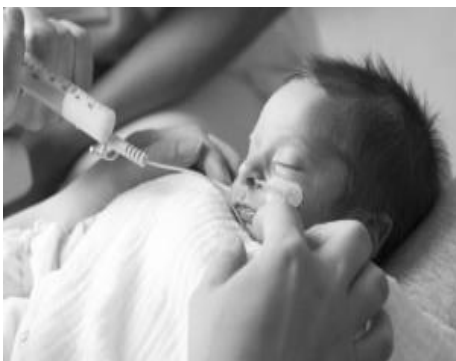

Fig.1. Artificial tube feeding methods

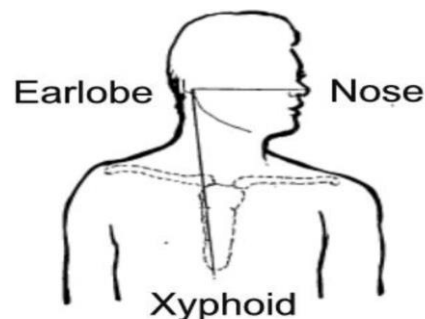
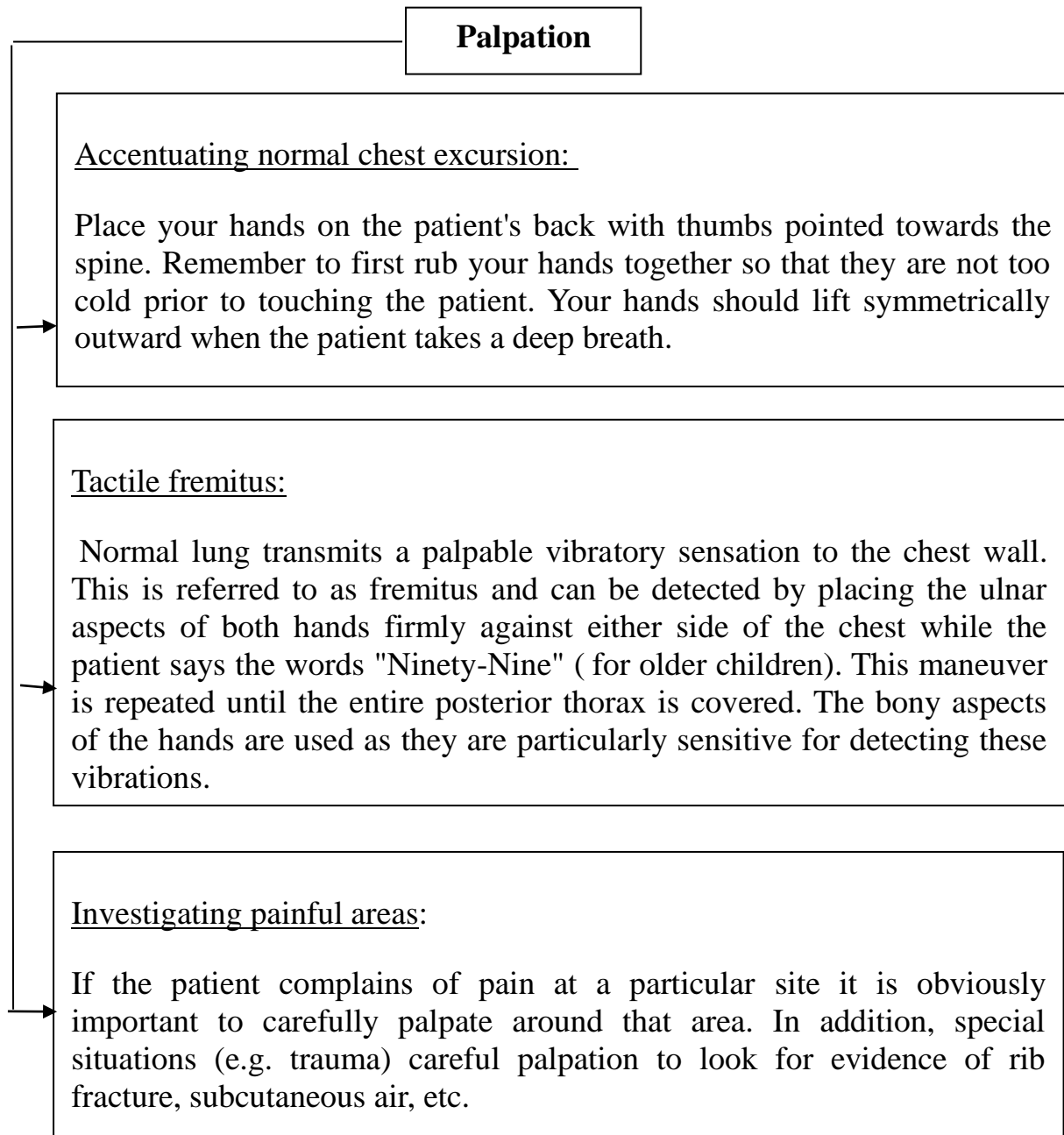


Fig.2. Measure distance from tip to nose to earlobe to xyphoid process of sternum

## Practical skill №10

### Palpation, percussion, auscultation of lungs in children in different age period.

**Palpation:** Palpation plays a role in the examination of the normal chest as the structure is covered by the ribs and therefore not palpable. But specific situations where it may be helpful include:



**Percussion:** This technique makes use of the fact that striking a surface which covers an air-filled structure (e.g. normal lung) will produce a resonant note while repeating the same maneuver over a fluid or tissue filled cavity generates a relatively dull sound. If the normal, air-filled tissue has been displaced by fluid (e.g. pleural effusion) or infiltrated with white cells and bacteria (e.g. pneumonia), percussion will generate a deadened tone. Alternatively, processes that lead to chronic (e.g. emphysema) or acute (e.g. pneumothorax) air trapping in the lung or pleural space, respectively, will produce hyper-resonant (i.e. more drum-like) notes on percussion. Initially, you will find that this skill is a bit awkward to perform. Allow your hand to swing freely at the wrist, hammering your finger onto the target at the bottom of the down stroke (table 6).

Table 6

**The technique of percussion**

<p style="text-align: center;"><b>The technique</b></p>
<p>1.If you're percussing with your right hand, stand a bit to the left side of the patient's back.</p>
<p>2. Ask the patient to cross their hands in front of their chest, grasping the opposite shoulder with each hand. This will help to pull the scapulae laterally, away from the percussion field.</p>
<p>3. Work down the "alley" that exists between the scapula and vertebral column, which should help you avoid percussing over bone.</p>

4. Press the distal phalanx of the middle finger *firmly* on the area to be percussed and raise the second and fourth fingers off the chest surface; otherwise, both sound and tactile vibrations will be blunted.

5. Use a quick, sharp wrist motion (like a catcher throwing a baseball to second base) to strike the finger in contact with the chest wall with the tip of the third finger of the other hand. The best percussion site is between the proximal and distal interphalangeal joints. The novice quickly learns to trim the fingernail to prevent personal discomfort of minor abrasions and lacerations.

6. If the sound and the vibrations produced seem suboptimal, make sure that the finger placed directly on the thorax is making very firm direct contact with the chest wall. If not, few vibrations and little sound will be produced.

7. Percuss the posterior, lateral, and anterior chest wall in such a manner that the long axis of the percussed finger is roughly parallel to the ribs. Compare one side to the other.

8. Over each area, begin percussion superiorly and extend inferiorly to identify the level of the diaphragm during quiet (tidal volume) breathing. Note the position of the diaphragm. Then ask the patient to inhale fully and "hold it"; continue to percuss inferiorly to determine the new level of the diaphragm, now during forced maximal inspiration. Then, don't forget to tell the patient to "breathe normally." The difference between the two levels is known as diaphragmatic excursion and should equal 2 to 3 cm.

9. Try to focus on striking the distal inter-phalangeal joint of your left middle finger with the tip of the right middle finger. The impact should be crisp so you

may want to cut your nails to keep blood-letting to a minimum!

10. The last 2 phalanges of your left middle finger should rest firmly on the patient's back. Try to keep the remainder of your fingers from touching the patient, or rest only the tips on them if this is otherwise too awkward, in order to minimize any dampening of the percussio notes.

11. When percussing any one spot, 2 or 3 sharp taps should suffice, though feel free to do more if you'd like. Then move your hand down several inter-spaces and repeat the maneuver. In general, percussio in 5 or so different locations should cover one hemi-thorax. After you have percussed the left chest, move your hands across and repeat the same procedure on the right side. If you detect any abnormality on one side, it's a good idea to slide your hands across to the other for comparison. In this way, one thorax serves as a control for the other. If auscultation (see below) reveals an abnormality in the anterior or lateral fields, percussio over these areas can help identify its cause.

12. The goal is to recognize that at some point as you move down towards the base of the lungs, the quality of the sound changes. This normally occurs when you leave the thorax. It is not particularly important to identify the exact location of the diaphragm, though if you are able to note a difference in level between maximum inspiration and expiration, all the better.

13. "Speed percussio" may help to accentuate the difference between dull and resonant areas.

The technique of percussio is best accomplished by the following approach in table 7:

Table 7

## Boundaries of the lung and its lobes

Lung boundaries	Front	Right lung: the 9 <sup>th</sup> rib on the axillary line, the 5 <sup>th</sup> rib on the mamillary line.  Left lung: at the level of the 9 <sup>th</sup> rib on the axillary line.
	Back	Both lungs: at the level of the spinous process of the 10 <sup>th</sup> -11 <sup>th</sup> thoracic vertebrae.
Boundaries of the pulmonary lobes	Front	Right lung: above the 4 <sup>th</sup> rib the upper lobe, below the 4 <sup>th</sup> rib the middle lobe.
	Back	Both lungs: above the scapular spine the upper lobe, below the scapular spine the lower lobe.

Points to note on percussion of the chest are as follows: resonance, dullness, pain and tenderness must be marked.

An increase in resonance may be notable when the pleural cavity contains air and the lung is collapsed toward the hilus, as in pneumothorax.

Reduction of resonance (dullness to percussion) occurs when the pleura is thickened, when the underlying lung is more solid than usually for any reason, and when the pleural cavity contains fluid.

Table 8

Percussion notes and their characteristics

	Relative intensity	Relative pitch	Relative duration	Example of location
Flatness	soft	high	short	thigh
Dullness	medium	medium	medium	liver
Resonance	loud	low	long	normal lung
Hyperresonance	very loud	lower	longer	none normally
Tympanic	loud	high	short	gastric air bubble or puffed-out cheek

## **Main principle of auscultation**

- Auscultation of the chest ideally is performed in a quiet room with the patient either sitting or standing.
- When the posterior thorax is examined, the patient's arms should be crossed anteriorly to move the scapulas laterally as much as possible.
- Comparing one side to the other is a helpful maneuver to identify the patient's "normal."
- Auscultation should be performed during tidal ventilation, deep forceful inspiration, and forceful expiration.
- It is not only intuitively obvious but rigorously proved that the intensity of breath sounds is related to flow rates; that is, the louder the sound, the greater the flow rate, all other things being equal.

The technique of auscultation in table 9.

Table 9

### **The technique of auscultation**

1. Put on your stethoscope so that the ear pieces are directed away from you. Adjust the head of the scope so that the diaphragm is engaged. If you're not sure, scratch lightly on the diaphragm, which should produce a noise. If not, twist the head and try again. Gently rub the head of the stethoscope on your shirt so that it is not too cold prior to placing it on the patient's skin.
2. The upper aspect of the posterior fields (i.e. towards the top of the patient's back) are examined first. Listen over one spot and then move the stethoscope to the same position on the opposite side and repeat. This again makes use of one lung as a source of comparison for the other. The

entire posterior chest can be covered by listening in roughly 4 places on each side. Of course, if you hear something abnormal, you'll need to listen in more places.

3. The lingula and right middle lobes can be examined while you are still standing behind the patient.

4. Prior to listening over any one area of the chest, remind yourself which lobe of the lung is heard best in that region: lower lobes occupy the bottom 3/4 of the posterior fields; right middle lobe heard in right axilla; lingula in left axilla; upper lobes in the anterior chest and at the top 1/4 of the posterior fields. This can be quite helpful in trying to pin down the location of pathologic processes that may be restricted by anatomic boundaries (e.g. pneumonia). Many disease processes (e.g. pulmonary edema, bronchoconstriction) are diffuse, producing abnormal findings in multiple fields.

5. Auscultation can give information about the character and intensity of the breast sounds, the presence or absence of any added sounds and the character of vocal resonance. The points to note on auscultation of the chest are as follows: vesicular breath sounds, bronchial breath sounds, puerile breath sounds, vocal fremitus and resonance, bronchophony, added sounds (pleural rub, wheezes, crackles).

Breath sounds have intensity and quality. The intensity (or loudness) of breath sounds may be normal, reduced or increased. By their quality, breath sounds are vesicular, bronchial or puerile.

Medical certifications of clinical examination results are given in tables 10-13.

Table 10. Characteristics of type of breathing

<p>Normal: the respiratory rate is about 14-20 per minute in normal adults and up to 44 per minute in infants.</p>
<p>Rapid shallow breathing (tachypnoea): this has a number of causes, including restrictive lung disease, pleuritic chest pain and an elevated diaphragm.</p>
<p>Rapid deep breathing (hyperpnoea, hyperventilation): this has several causes, including exercise, anxiety, and metabolic acidosis; comatose patients develop infarction, hypoxia, or hypoglycaemia affecting the midbrain or pons; Kussmaul breathing is deep breathing due to metabolic acidosis and by rate may be fast, normal or slow.</p>
<p>Slow breathing (bradypnoea): this may be secondary to such causes as diabetic coma, drug-induced respiratory depression and increased intracranial pressure.</p>
<p>Cheyne-Stokes respiration: periods of deep breathing alternate with periods of apnoea (no breathing); children and aging people normally may show this pattern in sleep; other causes include heart failure, uraemia, drug-induced respiratory depression and brain damage (typically on both sides of the cerebral hemispheres or diencephalon).</p>
<p>Ataxic breathing (Biot's respiration): this breathing is characterized by unpredictable irregularity; breaths may be shallow or deep and stop for short periods; its causes include respiratory depression and brain damage, typically at the medullary level.</p>
<p>Sighing respiration:</p>

Breathing, punctuated by frequent sighs, should alert you to the possibility of hyperventilation syndrome – a common cause of dyspnoea and dizziness; occasional sighs are normal.

**Obstructive breathing:**

in obstructive lung disease, expiration is prolonged because narrowed airways increase the resistance to air flow; its causes include asthma, chronic bronchitis, and chronic obstructive pulmonary disease.

Table 11. Characteristics of breath sounds

	Duration of Sounds	Intensity of Expiratory Sound	Pitch of Expiratory Sound	Locations Where Heard Normally
Vesicular	Inspiratory sounds last longer than expiratory ones.	Soft	Relatively low	Over most of both lungs.
Broncho-vesicular	Inspiratory and expiratory sounds are about equal.	Intermediate	Intermediate	Often in the 1 <sup>st</sup> and 2 <sup>nd</sup> interspaces anteriorly and between the scapulae.
Bronchial	Expiratory sounds last longer than inspiratory ones.	Loud	Relatively high	Over the manubrium, if heard at all.
Tracheal	Inspiratory and expiratory sounds are about equal.	Very loud	Relatively high	Over the trachea in the neck.

Table 12. Characteristics of crackles

If you hear crackles, listen carefully for the following characteristics, which are clues to the underlying condition.
Loudness, pitch/ and duration (summarized as fine or coarse crackles).
Number (few to many).
Timing in the respiratory cycle.
Location on the chest wall.
Persistence of their pattern from breath to breath.
Any change after a cough or a change in the patient's position.

Table 13. Adventitious lung sounds

Discontinuous sounds (crackles) are intermittent, nonmusical, and brief-like dots in time.
Fine crackles are soft, high-pitched, and very brief (5-10 msec).
Coarse crackles are somewhat louder, lower in pitch, and not quite so brief (20-30 msec).
Continuous sounds are > 250 msec, notably longer than crackle-like dashes in time, but do not necessarily persist throughout the respiratory cycle. Unlike crackles, they are musical.
Wheezes are relatively high-pitched (around 400 Hz or higher) and have a hissing or shrill quality.
Bronchi are relatively low-pitched (around 200 Hz or lower) and have a snoring quality.

## **Practical skill №11**

### **Exam of the heart**

#### **The technique of palpation**

1. The palm of your right hand is placed across the patient's left chest so that it covers the area over the heart. Focus on next things.

2. You should feel a point of maximum impulse related to contraction at the apex of the underlying left ventricle and where is it located. After identifying the rough position with the palm of your hand, try to pin down the precise location with the tip of your index finger. The normal sized and functioning ventricle will generate a impulse that is best felt in the mid-clavicular line, roughly at the 5th intercostal space. If the ventricle becomes dilated the point of maximum impulse is displaced laterally. In cases of significant enlargement, the point of maximum impulse will be located near the axilla.

3. Carotid Artery Palpation: This is of greatest value during the assessment of aortic valvular and out flow tract disease and should thus be performed after auscultation so that you know whether or not these problems exist prior to palpation. However, for the sake of completeness it will be described here. The carotids can be located by sliding the second and third finger of either hand along the side of the trachea at the level of the thyroid cartilage (i.e. Adams apple). The carotid pulsation is palpable just lateral to the groove formed by the trachea and the surrounding soft tissue. The quantity of subcutaneous fat will dictate how firmly you need to push. The pulsations should be easily palpable. Diminution may be caused by atherosclerosis, aortic stenosis, or severely impaired ventricular performance. Do not push on both sides simultaneously as this may compromise cerebral blood flow.

## **The technique of percussion of the heart in children.**

The absolute and comparative dullness of heart in children. Semiotics of affection and the main diseases of cardiovascular system in children.

Percussion of the heart is used for examining borders of heart dullness.

The following rules should be observed in percussion of the heart:

– the procedure is conducted from the lung to the heart, i.e. from clear to dull sounds, as it is easier in this manner to detect where the flatness begins;

– light percussion is employed, as more forceful taps produce sounds in the surrounding pulmonary tissue;

– percussion over the area of absolute dullness must be still lighter than over the area of relative dullness. The borders of relative dullness show the actual dimensions of the heart. The area of absolute dullness depends on how much of the heart is screened by the lungs. Increased absolute dullness may be due to enlargement of the heart and to collapse or displacement of the free margin of the lung. A decreased area of absolute dullness is mostly observed in emphysema of the lungs, in cases of so-called vicarious expansion, in pneumonia and also in bronchial asthma and other toxicoallergic conditions.

Borders of cardiac dullness. For greater convenience in determining the cardiac boundaries, childhood may be subdivided into three periods: from birth to 2 years, from 2 to 7 years, and from 7 to 12 years of age (See Table 14).

One should not forget that the boundaries of the heart do not depend on age alone, but also on the development and shape of the chest. The figures cited in Table 1 are merely of relative value. When examining adipose children and girls in the puberty period, use the midclavicular line instead of the mamillary one. In addition to delineation of the cardiac boundaries the transverse diameter of the heart must likewise be ascertained.

Table 14

Site of cardiac impulse and borders of cardiac dullness  
(after V. Molchanov)

	Age	0-2 years	2-7 years	7-12 years
Cardiac impulse		1-2 cm lateral of the left mamillary line	1 cm lateral of the left mamillary line	On the mamillary line or 0.5-1 cm medial of it
		The 4 <sup>th</sup> intercostal space	The 5 <sup>th</sup> intercostal space	
Absolute dullness	The upper border	The 3 <sup>rd</sup> rib	The 3 <sup>rd</sup> intercostal space	The 4 <sup>th</sup> rib
	The left (outer) border medial of impulse	Between left mamillary and parasternal lines		
		Closer to the mamillary line	In the middle	Closer to the parasternal line
	Right (inner) border	The left margin of the sternum		
The transverse diameter of the heart	2-3 cm	4 cm	5-5.5 cm	
Relative dullness	The upper border	The 2 <sup>nd</sup> rib	The 2 <sup>nd</sup> intercostal space	The 3 <sup>rd</sup> rib

The left border (lateral of impulse)	1-2 cm lateral of the left mamillary line		On the mamillary line
The right border	The right parasternal line	Slightly medial of the right parasternal line	Midway between the right parasternal line and right sternal margin, or slightly closer to the sternal margin
The transverse diameter of the heart	6-9 cm	8-12 cm	9-14 cm

### The technique of auscultation

1. Become comfortable with your stethoscope. Take the time to read the instructions for your particular model so that you are familiar with how to use it correctly.
2. Position the diaphragm over the 4th intercostal space, left midclavicular line to examine the mitral area. Listen over the left 4th intercostal space, the region of the tricuspid valve. Engage the diaphragm of your stethoscope and place it firmly over the 2nd right intercostal space, the region of the aortic valve. Then move it to the other side of the sternum and listen in the 2nd left intercostal space, the location of the pulmonic valve.
3. In each area, listen specifically for S1 and then S2. S1 will be loudest over the left 4th intercostal space (mitral/tricuspid valve areas) and S2 along the 2nd R and L intercostal spaces (aortic/pulmonic valve regions). Note that the time between S1 and S2 is shorter than that

between S2 and S1. This should help you to decide which sound is produced by the closure of the mitral/tricuspid and which by the aortic/pulmonic valves and therefore when systole and diastole occur. Compare the relative intensities of S1 and S2 in these different areas.

4. You may find it helpful to tap out S1 and S2 with your fingers as you listen, accentuating the location of systole and diastole and lending a visual component to this exercise. While most clinicians begin auscultation in the aortic area and then move across the precordium, it may actually make more sense to begin laterally (i.e. in the mitral area) and then progress towards the right and up as this follows the direction of blood flow. Try both ways and see which feels more comfortable.

5. Listen for extra heart sounds (a.k.a. gallops). An S3 is most commonly associated with left ventricular failure and is caused by blood from the left atrium slamming into an already overfilled ventricle during early diastolic filling. The S4 is a sound created by blood trying to enter a stiff, non-compliant left ventricle during atrial contraction. It's most frequently associated with left ventricular hypertrophy that is the result of long standing hypertension. Either sound can be detected by gently laying the bell of the stethoscope over the apex of the left ventricle (roughly at the 4th intercostal space, mid-clavicular line) and listening for low pitched "extra sounds" that either follow S2 (i.e. an S3) or precede S1 (i.e. an S4). These sounds are quite soft, so it may take a while before you're able to detect them. Positioning the patient on their left side while you listen may improve the yield of this exam. The presence of both an S3 and S4 simultaneously is referred to as a summation gallop.

Murmurs - these are sounds that occur during systole or diastole as a result of turbulent blood flow. Groups of murmurs:

1. Leaking backwards across a valve that is supposed to be closed. These are referred to as regurgitant or insufficiency murmurs (e.g. mitral regurgitation, aortic insufficiency).
2. Flow disturbance across a valve that will not open fully/normally. These valves suffer from varying degrees of stenosis (e.g. aortic stenosis).
3. It's worth mentioning that sometimes "flow murmurs" can occur, resulting from high output across structurally normal valves. In addition, some valves with insignificant degrees of pathology (e.g. aortic sclerosis - where the valve leaflets are slightly calcified yet function normally) generate murmurs.
4. Traditionally, students are taught that auscultation is performed over the 4 areas of the precordium that roughly correspond to the "location" of the 4 valves of the heart (i.e. aortic valve area is the 2nd Right Intercostal Space, pulmonic valve area is the 2nd left Intercostal Space, tricuspid valve area is 4th left Intercostal Space, and mitral valve area is 4th left Intercostal Space in the midclavicular line). This leads to some misperceptions. Valves are not strictly located in these areas nor are the sounds created by valvular pathology restricted to those spaces.
5. Auscultation over the carotid arteries: in the absence of murmurs suggestive of aortic valvular disease, you can listen for carotid bruits (sounds created by turbulent flow within the blood vessel) at this point in the exam. Place the diaphragm gently over each carotid and listen for a soft, high pitched sound. It's helpful if the patient can hold their breath as you listen so that you are not distracted by transmitted tracheal sounds.

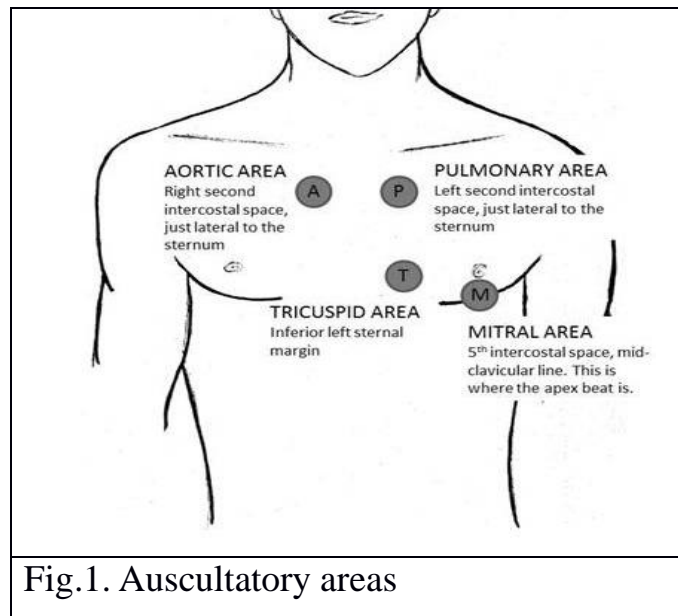
Auscultatory areas (fig.15).

Certain areas of the praecordia are customarily named according to the valve from which murmurs and sounds arise:

- the mitral area corresponds to the apex beat;
- the tricuspidal area lies just to the left of the lower sternum;
- the aortic area is to the right of the sternum in the second intercostal

space;

– the pulmonary area is to the left of the sternum in the second intercostal space.



### Heart sounds.

At the onset of ventricular systole, the mitral and tricuspid valves close consecutively to give the first heart sound. Opening of the pulmonary and aortic valves occurs next and is normally inaudible. The closure of the aortic and pulmonary valves gives rise to two components of the second sound.

It will be a sign that because of a lower pressure in the right ventricle versus the left one, closure of the pulmonary valve follows that of the aortic valve. After a brief period the mitral and tricuspid valves open inaudibly in the normal heart.

### Abnormal heart sounds.

In diseases, the following deviations from the norm may occur:

- the sounds may have a different intensity, either increased or decreased;
- the sounds may be abnormally split;
- low-frequency sounds in diastole, the 3<sup>rd</sup> or 4<sup>th</sup> sounds may be heard;

– additional high-pitched sounds, originating from abnormal valves, may be heard.

Murmurs are due to turbulence in the blood flow at or near a valve or an abnormal communication between chambers of the heart. It follows that a loud murmur may originate from a rather small orifice such as a ventricular septal defect. Equally a soft murmur may originate from a large abnormal orifice as in very severe aortic regurgitation. Not all murmurs are produced by structural disorders of the heart; they may be due to an abnormally rapid flow of blood through a normal valve. Such murmurs are called flow murmurs; it should be remembered that they do not indicate any valvular disease.

Murmurs may be systolic, diastolic or continuous throughout systole; diastolic murmurs are either pansystolic, as in mitral or tricuspid regurgitation and ventricular septal defects, or ejection ones, when they arise either from the pulmonary or aortic outflow tracts. Pansystolic murmurs start immediately with the first heart sound and continue through to the second one. Typically they have uniform intensity. By contrast, ejection systolic murmurs have a diamond-shaped configuration building to a peak in mid-systole. Ejection murmurs typically diminish before the second heart sound.

Diastolic murmurs are of two types: early diastolic murmurs start at the second heart sound and occur as a result of aortic or pulmonary regurgitation, while mid-diastolic murmurs, in which there is a short gap after the second heart sound before the beginning of the murmur, arise from the mitral or tricuspid valve. The maximum intensity point and direction of selective propagation must be noted.

The character of a murmur is now considered an unreliable guide to its origin. Rough murmurs are associated with obstruction to flow through a narrowed valve; blowing murmurs are more typical of an incompetent valve.

## Practical skill №12

### Exam of the kidney

Physical examination. Examining the patient, it is necessary to estimate the following aspects:

- consciousness;
  - response to the environment;
  - behaviour (at a renal colic the child rushes about and cannot be quiet);
  - colour of the skin;
  - position in bed (a pyoinflammatory process in the perirenal fatty body is typically demonstrated by a forced position, when the child lies sideways, his legs are bent in the knee and hip joints and are put closer to the trunk);
- oedema;
- presence of a possible asymmetry of the body in the projection of the kidneys, even of the abdomen (if a large renal tumour is present);
  - bulging of the urinary bladder above the pubis (a sign of a considerable urinary retention);
  - signs of rickets, which results from violation of the final process of vitamin D metabolism (derivation of the most active form of calciferol in the kidneys).

Palpation and percussion. Taking into account age-specific features in the position of the lower pole of the kidney, it becomes clear that normally it is possible to palpate this organ only in children of the first 2-3 years of life. Later, the kidney can be palpable only in cases of its enlargement (tumour, stones of kidneys) and ptosis.

Obraztsov-Strazhesko method (method of bimanual palpation):

- the child's position is horizontal.
- the doctor is from the right side of the patient.
- as in the already learned method of palpation of abdominal organs, the child's legs are a little bent (this movement partially relaxes muscles of the abdominal wall);
- the patient makes regular respiratory movements.

#### Palpation of the right kidney:

– the doctor's left hand is under the trunk in the projection of the right kidney (along the waist);

– the right hand of the doctor lies flat laterally from the right straight muscle of the abdomen (parallel to it), the fingers are placed slightly below the right costal arch;

– such a position having been accepted, during the process of an exhalation the right arm gradually goes deeper inward. The palm of the left hand is simultaneously raised upwards, which promotes the approximation of the kidney to the fingers of the right hand. Thus, in case of palpation of the kidneys, the left hand in the beginning feels the lower pole of the kidney. Further sliding movements estimate the size, form, mobility, morbidity, consistency and possible roughness of the wall of the kidney. The palpation of the left kidney by its technique corresponds to the above described, with one exception: the left hand will be carried on further under the trunk up to the projection of the left kidney, the right one is placed outside, in the area of the left straight abdominal muscle.

The objective sign of acquired diseases of the renal system consists in the detection of the 'pitting' oedema by palpation. Pasternatsky's symptom, defined with help of the method of slight beating as percussion, is one of the

first, quite objective in paediatrics, clinical signs of renal diseases. The essence of the method consists in the arising of pain syndrome in the location of kidneys.

Below is a variant of this technique.

The doctor places the palm of his/her left hand in a horizontal position on the loins in the projection of the kidney (it is the angle between the 12<sup>th</sup> rib and the peripheral edge of long back muscles, or the costovertebral angle).

Then with the edge or fist of his right hand the doctor makes 2-3 slight beatings on his/her left hand.

The first beating must be very slight. If the child does not react to it, i.e. pain syndrome is not present, it is possible to make 2-3 times harder beatings.

The technique is fulfilled from both sides.

The absence of pain means that Pasternatsky's symptom is negative, the presence of pain shows that the symptom is positive. In case history, it is possible to note this fact or to make accordingly a record of the other sort: Pasternatsky's symptom (–) or Pasternatsky's symptom (+). It is necessary to specify the defected side, for example: Pasternatsky's symptom (–) on the right and (+) on the left.

The kidney has segmented structure; there is no united sheath, but it is the sheath that hurts on extension (pain receptors are located on the capsule).

By the method of percussion it is possible to spot a higher boundary of the urinary bladder. Silent percussion is done along the median line of the abdomen from above the navel downwards till the appearance of a dull sound (a mark will be put above the finger- plessimeter).

The results of the percussion are as follows:

- normal, there is no dullness;
- a decrease in resonance after urination is a sign of the presence of some residual urine.

## Practical skill №13

### Exam of the Abdomen

The major components of the abdominal exam include: observation, auscultation, percussion, and palpation.

**Observation:** Much information can be gathered from simply watching the patient and looking at the abdomen. This requires complete exposure of the region in question, which is accomplished as follows:

1. Patient must lie on a level examination table that is at a comfortable height for both of you.
2. Take a spare bed sheet and drape it over their lower body such that it just covers the upper edge of their underwear (or so that it crosses the top of the pubic region if they are completely undressed).
3. The patient's hands should remain at their sides with their heads resting on a pillow. If the head is flexed, the abdominal musculature becomes tensed and the examination made more difficult. Allowing the patient to bend their knees so that the soles of their feet rest on the table will also relax the abdomen.
4. Keep the room as warm as possible and make sure that the lighting is adequate. By paying attention to these seemingly small details, you create an environment that gives you the best possible chance of performing an accurate examination.

While observing the patient, pay particular attention to:

1. Appearance of the abdomen. Distended? If enlarged, does this appear symmetric or are there distinct protrusions, perhaps linked to underlying organomegaly? The contours of the abdomen can be best appreciated by standing at the foot of the table and looking up towards the patient's head. Global abdominal enlargement is usually caused by air, fluid, or

fat. Areas which become more pronounced when the patient Valsalva are often associated with ventral hernias. These are points of weakening in the abdominal wall, frequently due to previous surgery, through which omentum/intestines/peritoneal fluid can pass when intra-abdominal pressure is increased.

2. Presence of surgical scars or other skin abnormalities.
3. Patient's movement . Those with peritonitis (e.g. appendicitis) prefer to lie very still as any motion causes further peritoneal irritation and pain. Contrary to this, patients with kidney stones will frequently writhe on the examination table, unable to find a comfortable position.

Dimensions and shape of the abdomen. Normally the abdomen is on the same level as the chest and does not protrude beyond the latter (after infancy); in infants the abdomen is slightly elevated over the level of the chest. A number of pathological deviations are at times observed in the shape and size of the abdomen. Large belly. The most frequent causes of abdominal enlargement are: (1) meteorism resulting from acute and chronic dyspepsia and persistent constipation; meteorism owing to rough food; intestinal stenosis, depending on its location, induces either general meteorism (Hirschsprung's disease, or megacolon, abdominal distention in intestinal paresis), or a local distention of the abdomen (pyloric stenosis, i.e. distention in the gastric area); (2) hypotonia of muscles of the abdominal wall and smooth muscles of the intestine observed in rickets, general muscular atrophy, so-called intestinal infantilism which is attended by chronic diarrhoea and retardation of physical development; (3) accumulation of fluid in the abdominal cavity in the form of (a) an inflammatory exudate produced by acute peritonitis or chronic tuberculous peritonitis, (b) a transudate, i.e. ascites, which appears in cases of generalized dropsy (diseases of the kidneys and heart), local circulatory disturbances in the abdominal cavity (cirrhosis of the liver; rarer in children than in adults); (4) abdominal tumours, such as those of the liver, spleen, lymph nodes of the adrenal glands; sarcoma of retroperitoneal and mesenteric lymph nodes,

kidneys, or ovaries.

The shape of the abdomen, as established during examination, is to a certain extent a clue to the cause of its enlargement.

Shape of the abdomen. In such conditions as rickets, meteorism, and ascites a uniform enlargement of the abdominal curvature is noted. In tuberculous peritonitis the median portion of the abdomen is most prominent. Unilateral enlargement of the abdomen is typical of tumours and paralyse of the abdominal muscles (infantile paralysis). In rachitic children, those with large bellies or chronic intestinal trouble a condition termed pseudoascites is observed, with ascetic percussion findings. It is caused, on the one hand, by intestinal atonia and meteorism, and on the other by a considerable accumulation of fluid in the intestine. Differentiation from true ascites is established by the instability of the percussive dullness and of fluctuation and disappearance of the dullness after evacuation of the intestine.

Scaphoid, or navicular, abdomen is a belly with sunken walls, presenting a concavity; it is seen in starvation, in underfed children, in dysentery, pylorostenosis, tuberculous meningitis.

Other findings, besides size and shape, that are ascertained by examination of the abdomen, include intestinal peristalsis, the condition of the navel, a possible divergence of the rectum muscles, and existence of some hernia (umbilical, inguinal).

Abdominal participation in the act of breathing is also determined by examination: in cases of inflammatory processes in the peritoneum the normal type of respiration alters and respiration becomes thoracic.

Normally, intestinal peristalsis should not be visible during examination. It is visible in children with poorly developed subcutaneous adipose tissue, in emaciated children. Peristaltic and antiperistaltic movements are seen in the epigastric and subcostal areas in infants in cases of constriction of the outlet of the stomach, pyloric spasm or stenosis. These movements occur from left to right and may be precipitated by some mechanical stimulation of the gastric

walls through the abdominal integuments.

Intussusception, or invagination or slipping of one part of the intestine into another, produces intestinal obstruction, when peristalsis of separate loops of the intestine is seen.

The condition of the navel must be attended to in the first weeks of the infant's life. Ordinarily the cord sloughs off on the 5<sup>th</sup>-7<sup>th</sup> day of life, leaving an umbilical wound with a smooth surface. The various diseases of the umbilicus include suppuration, ulceration, inflammation (omphalitis), phlegmon, granulation (frequently of a fungoid appearance), and diphtheria of the navel with a greyish film on the umbilical wound. The development of the venous network in the area of the navel is an important diagnostic factor during the first weeks of life; the condition, even if the umbilical wound has healed, may be a sign of sepsis. Faulty closure of the navel results from negligence and infection.

**Auscultation:** Auscultation of the abdomen has a relatively minor role. It is performed before percussion or palpation as vigorously touching the abdomen may disturb the intestines, perhaps artificially altering their activity and thus bowel sounds. Exam is made by gently placing the pre-warmed (accomplished by rubbing the stethoscope against the front of your shirt) diaphragm on the abdomen and listening for 15 or 20 seconds. The stethoscope can be placed over any area of the abdomen as there is no true compartmentalization and sounds produced in one area can probably be heard throughout. At this stage, practice listening in each of the four quadrants and see if you can detect any "regional variations." What exactly are you listening for and what is its significance? Next things should be noted:

1. Are bowel sounds present?
2. If present, are they frequent or sparse (i.e. quantity)?
3. What is the nature of the sounds (i.e. quality)?

As food and liquid course through the intestines by means of peristalsis noise, referred to as bowel sounds, is generated. These sounds occur quite frequently,

on the order of every 2 to 5 seconds, although there is a lot of variability. Bowel sounds in and of themselves do not carry great significance. That is, in the normal person who has no complaints and an otherwise normal exam, the presence or absence of bowel sounds is essentially irrelevant (i.e. whatever pattern they have will be normal for them). In fact, most physicians will omit abdominal auscultation unless there is a symptom or finding suggestive of abdominal pathology. However, you should still practice listening to all the patients that you examine so that you develop a sense of what constitutes the range of normal. Bowel sounds can, however, add important supporting information in the right clinical setting. In general, inflammatory processes of the serosa (i.e. any of the surfaces which cover the abdominal organs, as with peritonitis) will cause the abdomen to be quiet (i.e. bowel sounds will be infrequent or altogether absent). Inflammation of the intestinal mucosa (i.e. the insides of the intestine, as might occur with infections that cause diarrhea) will cause hyperactive bowel sounds. Processes which lead to intestinal obstruction initially cause frequent bowel sounds. Think of this as the intestines trying to force their contents through a tight opening. This is followed by decreased sound, and then silence. Alternatively, the reappearance of bowel sounds heralds the return of normal gut function following an injury. After abdominal surgery, for example, there is a period of several days when the intestines lie dormant. The appearance of bowel sounds marks the return of intestinal activity, an important phase of the patient's recovery. Bowel sounds, then, must be interpreted within the context of the particular clinical situation. They lend supporting information to other findings but are not in and of themselves pathognomonic for any particular process.

After you have finished noting bowel sounds, use the diaphragm of your stethoscope to check for renal artery bruits, a high pitched sound (analogous to a murmur) caused by turbulent blood flow through a vessel narrowed. The place to listen is a few cm above the umbilicus, along the lateral edge of either rectus muscles. However, in the right clinical setting (e.g. a patient with some

combination of renal insufficiency, difficult to control hypertension and known vascular disease), the presence of a bruit would lend supporting evidence for the existence of renal artery stenosis. When listening for bruits, you will need to press down quite firmly as the renal arteries are retroperitoneal structures. Blood flow through the aorta itself does not generate any appreciable sound. Thus, auscultation over this structure is not a good screening test for the presence of aneurysmal dilatation.

**The technique for percussion:**

1. First, remember to rub your hands together and warm them up before placing them on the patient.
2. Then, place your left hand firmly against the abdominal wall such that only your middle finger is resting on the skin.
3. Strike the distal interphalangeal joint of your left middle finger 2 or 3 times with the tip of your right middle finger, using the previously described floppy wrist action.
4. There are two basic sounds which can be elicited:
  - a) Tympanic (drum-like) sounds produced by percussing over air filled structures.
  - b) Dull sounds that occur when a solid structure (e.g. liver) or fluid (e.g. ascites) lies beneath the region being examined.
5. If percussion produces pain, which may occur if there is underlying inflammation, as in peritonitis. This would certainly be supported by other exam findings
6. The remainder of the normal abdomen is, for the most part, filled with the small and large intestines. Try percussing each of the four quadrants to get a sense of the normal variations in sound that are produced. These will be variably tympanic, dull or some combination of the above, depending on whether the underlying intestines are gas or liquid filled.
7. The stomach "bubble" should produce a very tympanic sound upon percussion over the left lower rib cage, close to the sternum.

**To determine the size of the liver, proceed as follows:**

1. Start just below the right breast in a line with the middle of the clavicle, a point that you are reasonably certain is over the lungs. Percussion in this area should produce a relatively resonant note.
2. Move your hand down a few centimeters and repeat. After doing this several times, you will be over the liver, which will produce a duller sounding tone.
3. Continue your march downward until the sound changes once again. This may occur while you are still over the ribs or perhaps just as you pass over the costal margin. At this point, you will have reached the inferior margin of the liver. The total span of the normal liver is quite variable, depending on the size of the patient.
4. The resonant tone produced by percussion over the anterior chest wall will be somewhat less drum like than that generated over the intestines. While they are both caused by tapping over air filled structures, the ribs and pectoralis muscle tend to dampen the sound.
5. Speed percussion may also be useful. Orient your left hand so that the fingers are pointing towards the patients head. Percuss as you move the hand at a slow and steady rate from the region of the right chest, down over the liver and towards the pelvis. This maneuver helps to accentuate different percussion notes, perhaps making the identification of the liver's borders a bit more obvious.
6. Percussion of the liver is performed by lightly tapping finger against finger; generally speaking, it is difficult to establish the borders of the liver owing to the thinness of its lower margin. The upper margin of the liver is defined along the mamillary line in the 5<sup>th</sup> intercostal space; the breadth of the liver increases up to the age of 12 years.
7. Acute liver enlargement (parenchymatous swelling) concomitant with insignificant induration is frequently seen in children owing to various infections and intoxications (particularly at early ages). In acute

epidemic jaundice the liver is large, firm, tender, and its margin is considerably rounded.

8. Chronic enlargement of the liver is observed:

- 1) in cirrhosis of the liver developing at an early age owing to syphilis, and in an older age as a result of polyserositis, malaria, and also concurrently with splenic enlargement, owing to different causes (hepatosplenomegaly); the liver is indurated, its margin is sharp; in syphilis, the liver is firm and knobby;
- 2) as a result of congestion of blood in the liver in cases of heart lesions, pericarditis, weak cardiac activity, during many acute infections (diphtheria, scarlet fever), and pneumonia, particularly in babies;
- 3) in tumours of the liver (sarcoma, cysts);
- 4) in liver abscesses (acute pain in the liver when it is pressed upon);
- 5) in the presence of echinococci (caseworms) in the liver, effecting considerable enlargement of the organ; palpation elicits a smooth, fluctuating cupola on the smooth surface of the liver (the caseworm); palpation is usually painless, but occasionally pain may be felt under pressure;
- 6) in congenital constriction of the cystic duct (congenital jaundice); such children usually succumb within the first three months;
- 7) in amyloid degeneration of the organs as a result of chronic suppurate processes; the liver is large and firm, but not painful, its margin is rounded; an enlarged spleen and albuminuria are concurrent findings;
- 8) in kala azar (visceral leishmaniasis);
- 9) in diseases of blood, such as leukaemia and anaemia; the spleen is enlarged, blood is changed; the liver is large, firm, and painless;
- 10)** in Banti's disease or syndrome, chronic congestive splenomegaly being with cirrhosis of the liver.

## **The technique of percussion of the spleen**

1. Note: percussion may indicate but does not confirm splenomegaly.
2. With patient supine, percuss inferior to lung resonance to map out gastric tympany (i.e. Traube's Space).
3. This area is variable; however, tympanic extending laterally makes splenomegaly less likely.
4. Dullness may indicate splenomegaly, solid gastric content, or colon content.
5. When significantly enlarged, percussion in the left upper quadrant will produce a dull tone.
6. Splenic Percussion Sign (Castell's Sign): Percuss the most inferior interspace on the left anterior axillary line (Castell's Point).
7. This is usually tympanic. Ask patient to breath deeply.
8. Remains tympanic on inspiration: Splenic Percussion Sign negative: splenomegaly less likely.
9. Shift from tympanic to dullness: Splenic Percussion Sign positive: splenomegaly more likely.
10. Splenomegaly suggested by percussion should then be verified by palpation

Percussion can be quite helpful in determining the cause of abdominal distention, particularly in distinguishing between fluid (a.k.a. ascites) and gas. Of the techniques used to detect ascites, assessment for shifting dullness is perhaps the most reliable and reproducible. This method depends on the fact that air filled intestines will float on top of any fluid that is present. Proceed as follows:

1. With the patient supine, begin percussion at the level of the umbilicus and proceed down laterally. In the presence of ascites, you will reach a point where the sound changes from tympanitic to dull. This is the intestine-fluid interface and should be roughly equidistant from the umbilicus on the right and left sides as the fluid layers out in a gravity-

dependent fashion, distributing evenly across the posterior aspect of the abdomen. It should also cause a symmetric bulging of the patient's flanks.

2. Mark this point on both the right and left sides of the abdomen.
3. Repeat percussion, beginning at the top of the patient's now up-turned side and moving down towards the umbilicus. If there is ascites, fluid will flow to the most dependent portion of the abdomen. The place at which sound changes from tympanitic to dull will therefore have shifted upwards (towards the umbilicus) and be above the line which you drew previously. Speed percussion may also be used to identify the location of the air-fluid interface.
4. Percussion of the abdomen is a means for establishing the presence of fluid accumulations in the abdominal cavity. The flat places are dull to percussion, and the area of dullness alters with change of position; therefore the patient should be percussed both while standing upright and when lying down (on his back and on a side).

**The technique of superficial abdominal palpation:**

1. First warm your hands by rubbing them together before placing them on the patient. The pads and tips (the most sensitive areas) of the index, middle, and ring fingers are the examining surfaces used to locate the edges of the liver and spleen as well as the deeper structures.
2. Palpation of the abdomen is performed with the child on his back. The examiner places his hand (which should first be warmed) flat on the abdomen and presses in with three fingers, waiting for the child to exhale and thus loosen the abdominal muscles.
3. Pressure should be as deep as possible, and the patient's attention must be somehow distracted. Palpation proceeds from the substernal area to the umbilical area, then to the right and left iliac regions. The condition of the skin, abdominal integuments, liver, stomach, and spleen is ascertained, as well as the tension of the abdominal integuments, a

possible presence of infiltrates, faecal accumulations, tumours and spastic conditions of the entire intestine or of only certain parts of it; in emaciated or tuberculous children their mesenteric lymph nodes are palpable.

4. You may use either your right hand alone or both hands, with the left resting on top of the right. Apply slow, steady pressure, avoiding any rapid/sharp movements that are likely to startle the patient or cause discomfort.
5. Examine each quadrant separately, imagining what structures lie beneath your hands and what you might expect to feel.
6. Start in the right upper quadrant, 10 centimeters below the rib margin in the midclavicular line. This should insure that you are below the liver edge. In general, it is easier to detect abnormal if you start in an area that you're sure is normal. Gently push down (posterior) and towards the patient's head with your hand oriented roughly parallel to the rectus muscle, allowing the greatest number of fingers to be involved in the exam as you try to feel the edge of the liver. Advance your hands a few cm cephalad and repeat until ultimately you are at the bottom margin of the ribs. Initial palpation is done lightly.
7. Following this, repeat the examination of the same region but push a bit more firmly so that you are interrogating the deeper aspects of the right upper quadrant, particularly if the patient has a lot of subcutaneous fat. Pushing up and in while the patient takes a deep breath may make it easier to feel the liver edge as the downward movement of the diaphragm will bring the liver towards your hand. The tip of the xyphoid process, the bony structure at the bottom end of the sternum, may be directed outward or inward and can be mistaken for an abdominal mass. You should be able to distinguish it by noting its location relative to the rib cage (i.e. in the mid-line where the right and left sides meet).

8. You can also try to "hook" the edge of the liver with your fingers. To utilize this technique, flex the tips of the fingers of your right hand (claw-like). Then push down in the right upper quadrant and pull upwards (towards the patient's head) as you try to rake-up on the edge of the liver. This is a nice way of confirming the presence of a palpable liver edge felt during conventional examination.
9. After, examine the left upper quadrant. The normal spleen is not palpable. When enlarged, it tends to grow towards the pelvis and the umbilicus (i.e. both down and across). Begin palpating near the belly button and move slowly towards the ribs. Examine superficially and then more deeply. Then start 8-10 cm below the rib margin and move upwards. In this way, you will be able to feel enlargement in either direction. You can use your left hand to push in from the patient's left flank, directing an enlarged spleen towards your right hand.
10. Examine the left and right lower quadrants, palpating first superficially and then deeper.

**The technique of deep abdominal palpation:**

1. Deep palpation of the abdomen is performed by placing the flat of the hand on the abdominal wall and applying firm, steady pressure.
2. It may be helpful to use two-handed palpation, particularly in evaluating a mass.
3. Here the upper hand is used to exert pressure, while the lower hand is used to feel.
4. One should start deep palpation in the quadrant directly opposite any area of pain and carefully examine each quadrant.
5. At each costal margin it is helpful to have the patient inspire deeply to aid in palpation of the liver, gallbladder, and spleen.
6. A stool filled sigmoid colon or cecum are the most commonly identified structures on the left and right side respectively. The smooth dome of the bladder may rise above the pelvic brim and become palpable in the mid-

line, though it needs to be quite full of urine for this to occur. Other pelvic organs can also occasionally be identified. The ovaries and fallopian tubes are not identifiable unless pathologically enlarged.

7. Abdominal tenderness is the objective expression of pain from palpation. When elicited, it should be described as to its location (quadrant), depth of palpation required to elicit it (superficial or deep), and the patient's response (mild or severe). Spasm or rigidity is the involuntary tightening of the abdominal musculature that occurs in response to underlying inflammation. Guarding, in contrast, is a voluntary contraction of the abdominal wall musculature to avoid pain. Thus, guarding tends to be generalized over the entire abdomen, whereas rigidity involves only the inflamed area. Guarding can often be overcome by having the patient purposely relax the muscles; rigidity cannot be. Rigidity is thus a clear-cut sign of peritoneal inflammation.
8. Rebound tenderness is the elicitation of tenderness by rapidly removing the examining hand. The most common error is to remove the hand very quickly with an exaggerated motion and thus startle the patient. All that needs to be done is smoothly but quickly to lift the palpating hand off the abdomen and observe for pain, facial grimace, or spasm of the abdominal wall. Both tenderness and rebound tenderness may be elicited by palpation in a different quadrant. Thus, palpation of the left lower quadrant may produce tenderness and rebound tenderness in the right lower quadrant in appendicitis (Rovsing's sign). This is called referred tenderness and referred rebound.
9. When abdominal masses are palpated, the first consideration is whether the mass is intra-abdominal or within the abdominal wall. This will tense the abdominal muscles, thus shielding an intra-abdominal mass while making an abdominal wall mass more prominent. If the mass is intra-abdominal, important points are its size, location, tenderness, and mobility.

### **The technique of palpation of the liver:**

1. Palpation of the liver should begin in the lower part of the abdomen, under the navel, in order to be able to define the margin of the liver when it is considerably enlarged and lies low in the abdominal cavity.
2. Palpation is done with tips of the fingers which are placed parallel to the right costal margin; pressure to the abdomen must be applied very carefully.
3. When palpation is conducted with the patient laying on his back, the examiner determines the extent of the liver beyond the subcostal rim, its consistency, shape, type of margin, tenderness.
4. The examination is frequently hampered by crying (when the patient is very young), and also by meteorism.
5. When the child cries loudly the physician waits, keeping his hands on the abdomen, and during inhalation he cautiously palpates the margin of the liver.
6. The surface of the liver may be smooth or knobby, its margin also varies (sharp or rounded edge, etc.), depending on the type of hepatic lesion. In infancy, the liver normally protrudes slightly from under the ribs.
7. You can also try to "hook" the edge of the liver with your fingers. To utilize this technique, flex the tips of the fingers of your right hand (claw-like). Then push down in the right upper quadrant and pull upwards (towards the patient's head) as you try to rake-up on the edge of the liver. This is a nice way of confirming the presence of a palpable liver edge felt during conventional examination.
8. Acute atrophy of the liver, as jaundice with toxicosis, is indicated by acute diminution and tenderness of the liver.

### **The technique of palpation of the spleen:**

1. Palpation is usually conducted with the child lying on his back with his legs bent, and still better when lying on his right side.
2. Palpation of the spleen should be started under the navel (like palpation

of the liver), gradually travelling upward.

3. The spleen is palpated by pressing the fingers against the abdominal wall; it moves with respiration and when the child cries loudly.
4. In order to loosen the tension of the abdominal muscles older children are asked to breathe with abdomen.
5. In young children examination of the spleen is impeded by meteorism and crying (accompanied by muscular tension of the abdomen); the child should in such cases be placed on his right side so that his trunk occupies an angle of  $45^{\circ}$  in regard to the bed; the area of the 9<sup>th</sup>-11<sup>th</sup> ribs is fixated along the axillary line with the hand, and the fingers probe for the spleen.
6. Palpation indicates: (1) the consistency of the spleen (in chronic diseases it is firmer than in acute conditions; the greatest degree of indurations is seen in amyloidosis); (2) the dimension of the spleen (determined against displacement of its margin); (3) mobility; (4) tenderness.
7. Splenomegaly (enlargement of the spleen) is observed in connection with many acute infectious diseases, chronic infections and intoxications (malaria, syphilis, leishmaniasis, tuberculosis, etc.), congestive and inflammatory processes in the liver (infectious jaundice, cirrhosis), diseases of blood (acute and chronic granulocytic leukaemia, various forms of anaemia, pseudoleukaemia), caseworm in the liver. In many diseases, enlargement of the spleen is concurrent with liver enlargement.
8. Sometimes the liver and spleen are simultaneously involved (disease of the reticuloendothelium of the liver and spleen in consequence of disturbance of lipoid metabolism and the accumulation of lipoid in the hepatic and spleen cells); at other times the reaction of the spleen is secondary to the liver lesion. In childhood, dysfunctions of the liver and spleen are usually closely interrelated. In children between 3 and 12 years of age, splenohepatomegaly (enlargement of the spleen and liver) of obscure etiology is occasionally observed.

## Blood Pressure Levels for Boys by Age and Height Percentile

Age (Year)	BP Percentile ↓	Systolic BP (mmHg)							Diastolic BP (mmHg)						
		← Percentile of Height →							← Percentile of Height →						
		5th	10th	25th	50th	75th	90th	95th	5th	10th	25th	50th	75th	90th	95th
1	50th	80	81	83	85	87	88	89	34	35	36	37	38	39	39
	90th	84	85	87	89	100	102	103	49	50	51	52	53	53	54
	95th	88	89	101	103	104	106	106	54	54	55	56	57	58	58
	99th	105	106	108	110	112	113	114	61	62	63	64	65	66	66
2	50th	84	85	87	88	90	92	92	39	40	41	42	43	44	44
	90th	87	89	100	102	104	105	106	54	55	56	57	58	58	59
	95th	101	102	104	106	108	109	110	59	59	60	61	62	63	63
	99th	109	110	111	113	115	117	117	66	67	68	69	70	71	71
3	50th	86	87	89	91	93	94	95	44	44	45	46	47	48	48
	90th	100	101	103	105	107	108	109	59	59	60	61	62	63	63
	95th	104	105	107	109	110	112	113	63	63	64	65	66	67	67
	99th	111	112	114	116	118	119	120	71	71	72	73	74	75	75
4	50th	88	89	91	93	95	96	97	47	48	49	50	51	51	52
	90th	102	103	105	107	109	110	111	62	63	64	65	66	66	67
	95th	106	107	109	111	112	114	115	66	67	68	69	70	71	71
	99th	113	114	116	118	120	121	122	74	75	76	77	78	78	79
5	50th	90	91	93	95	96	98	98	50	51	52	53	54	55	55
	90th	104	105	106	108	110	111	112	65	66	67	68	69	69	70
	95th	108	109	110	112	114	115	116	69	70	71	72	73	74	74
	99th	115	116	118	120	121	123	123	77	78	79	80	81	81	82
6	50th	91	92	94	96	98	99	100	53	53	54	55	56	57	57
	90th	105	106	108	110	111	113	113	68	68	69	70	71	72	72
	95th	109	110	112	114	115	117	117	72	72	73	74	75	76	76
	99th	116	117	119	121	123	124	125	80	80	81	82	83	84	84
7	50th	92	94	95	97	99	100	101	55	55	56	57	58	59	59
	90th	106	107	109	111	113	114	115	70	70	71	72	73	74	74
	95th	110	111	113	115	117	118	119	74	74	75	76	77	78	78
	99th	117	118	120	122	124	125	126	82	82	83	84	85	86	86
8	50th	94	95	97	99	100	102	102	56	57	58	59	60	60	61
	90th	107	109	110	112	114	115	116	71	72	72	73	74	75	76
	95th	111	112	114	116	118	119	120	75	76	77	78	79	79	80
	99th	119	120	122	123	125	127	127	83	84	85	86	87	87	88
9	50th	95	96	98	100	102	103	104	57	58	59	60	61	61	62
	90th	109	110	112	114	115	117	118	72	73	74	75	76	76	77
	95th	113	114	116	118	119	121	121	76	77	78	79	80	81	81
	99th	120	121	123	125	127	128	129	84	85	86	87	88	88	89
10	50th	97	98	100	102	103	105	106	58	59	60	61	61	62	63
	90th	111	112	114	115	117	119	119	73	73	74	75	76	77	78
	95th	115	116	117	119	121	122	123	77	78	79	80	81	81	82
	99th	122	123	125	127	128	130	130	85	86	86	88	88	89	90

## Blood Pressure Levels for Boys by Age and Height Percentile (Continued)

Age (Year)	BP Percentile ↓	Systolic BP (mmHg)							Diastolic BP (mmHg)						
		← Percentile of Height →							← Percentile of Height →						
		5th	10th	25th	50th	75th	90th	95th	5th	10th	25th	50th	75th	90th	95th
11	50th	99	100	102	104	105	107	107	59	59	60	61	62	63	63
	90th	113	114	115	117	119	120	121	74	74	75	76	77	78	78
	95th	117	118	119	121	123	124	125	79	79	79	80	81	82	82
	99th	124	125	127	129	130	132	132	88	88	87	88	89	90	90
12	50th	101	102	104	106	108	109	110	59	60	61	62	63	63	64
	90th	115	116	118	120	121	123	123	74	75	75	76	77	78	79
	95th	119	120	122	123	125	127	127	79	79	80	81	82	82	83
	99th	126	127	129	131	133	134	135	88	87	88	89	90	90	91
13	50th	104	105	106	108	110	111	112	60	60	61	62	63	64	64
	90th	117	118	120	122	124	125	126	75	75	76	77	78	79	79
	95th	121	122	124	126	128	129	130	79	79	80	81	82	83	83
	99th	129	130	131	133	135	136	137	87	87	88	89	90	91	91
14	50th	106	107	109	111	113	114	115	60	61	62	63	64	65	65
	90th	120	121	123	125	126	128	128	75	76	77	78	79	79	80
	95th	124	125	127	129	130	132	132	80	80	81	82	83	84	84
	99th	131	132	134	136	138	139	140	87	88	89	90	91	92	92
15	50th	109	110	112	113	115	117	117	61	62	63	64	65	66	66
	90th	122	124	126	127	129	130	131	76	77	78	79	80	80	81
	95th	126	127	129	131	133	134	135	81	81	82	83	84	85	85
	99th	134	135	136	138	140	142	142	89	89	90	91	92	93	93
16	50th	111	112	114	116	118	119	120	63	63	64	65	66	67	67
	90th	125	126	128	130	131	133	134	79	79	79	80	81	82	82
	95th	129	130	132	134	135	137	137	82	83	83	84	85	86	87
	99th	136	137	139	141	143	144	145	90	90	91	92	93	94	94
17	50th	114	115	116	118	120	121	122	65	66	66	67	68	69	70
	90th	127	128	130	132	134	135	136	80	80	81	82	83	84	84
	95th	131	132	134	136	138	139	140	84	85	86	87	87	88	89
	99th	139	140	141	143	145	146	147	92	93	93	94	95	96	97

BP, blood pressure

\* The 90th percentile is 1.28 SD, 95th percentile is 1.645 SD, and the 99th percentile is 2.326 SD over the mean.

For research purposes, the standard deviations in Appendix Table B-1 allow one to compute BP Z-scores and percentiles for boys with height percentiles given in Table 3 (i.e., the 5th, 10th, 25th, 50th, 75th, 90th, and 95th percentiles). These height percentiles must be converted to height Z-scores given by (5% = -1.645; 10% = -1.28; 25% = -0.68; 50% = 0; 75% = 0.68; 90% = 1.28; 95% = 1.645) and then computed according to the methodology in steps 2-4 described in Appendix B. For children with height percentiles other than these, follow steps 1-4 as described in Appendix B.

### Blood Pressure Levels for Girls by Age and Height Percentile

Age (Year)	BP Percentile ↓	Systolic BP (mmHg)							Diastolic BP (mmHg)						
		← Percentile of Height →							← Percentile of Height →						
		5th	10th	25th	50th	75th	90th	95th	5th	10th	25th	50th	75th	90th	95th
1	50th	83	84	85	86	88	89	90	38	39	39	40	41	41	42
	90th	97	97	98	100	101	102	103	52	53	53	54	55	55	56
	95th	100	101	102	104	105	106	107	56	57	57	58	59	59	60
	99th	108	108	109	111	112	113	114	64	64	65	65	66	67	67
2	50th	85	85	87	88	89	91	91	43	44	44	45	46	46	47
	90th	98	99	100	101	103	104	106	57	58	58	59	60	61	61
	95th	102	103	104	105	107	108	109	61	62	62	63	64	65	65
	99th	109	110	111	112	114	115	116	69	69	70	70	71	72	72
3	50th	86	87	88	89	91	92	93	47	48	48	49	50	50	51
	90th	100	100	102	103	104	106	106	61	62	62	63	64	64	65
	95th	104	104	105	107	108	109	110	65	66	66	67	68	68	69
	99th	111	111	113	114	115	116	117	73	73	74	74	75	76	76
4	50th	88	88	90	91	92	94	94	50	50	51	52	52	53	54
	90th	101	102	103	104	106	107	108	64	64	65	66	67	67	68
	95th	105	106	107	108	110	111	112	68	68	69	70	71	71	72
	99th	112	113	114	115	117	118	119	76	76	76	77	78	79	79
5	50th	89	90	91	93	94	95	96	52	53	53	54	55	55	56
	90th	103	103	105	106	107	109	109	66	67	67	68	69	69	70
	95th	107	107	108	110	111	112	113	70	71	71	72	73	73	74
	99th	114	114	116	117	118	120	120	78	78	79	79	80	81	81
6	50th	91	92	93	94	96	97	98	54	54	55	56	56	57	58
	90th	104	105	106	108	109	110	111	68	68	69	70	70	71	72
	95th	108	109	110	111	113	114	115	72	72	73	74	74	75	76
	99th	115	116	117	119	120	121	122	80	80	80	81	82	83	83
7	50th	93	93	95	96	97	99	99	56	56	56	57	58	58	59
	90th	106	107	108	109	111	112	113	69	70	70	71	72	72	73
	95th	110	111	112	113	115	116	116	73	74	74	75	76	76	77
	99th	117	118	119	120	122	123	124	81	81	82	82	83	84	84
8	50th	95	95	96	98	99	100	101	57	57	57	58	59	60	60
	90th	108	109	110	111	113	114	114	71	71	71	72	73	74	74
	95th	112	112	114	115	116	118	118	75	75	75	76	77	78	78
	99th	119	120	121	122	123	125	125	82	82	83	83	84	85	85
9	50th	96	97	98	100	101	102	103	58	58	58	59	60	61	61
	90th	110	110	112	113	114	116	116	72	72	72	73	74	75	75
	95th	114	114	115	117	118	119	120	76	76	76	77	78	79	79
	99th	121	121	123	124	125	127	127	83	83	84	84	85	86	87
10	50th	98	99	100	102	103	104	105	59	59	59	60	61	62	62
	90th	112	112	114	115	116	118	118	73	73	73	74	75	76	76
	95th	116	116	117	119	120	121	122	77	77	77	78	79	80	80
	99th	123	123	125	126	127	129	129	84	84	85	85	86	87	88

### Blood Pressure Levels for Girls by Age and Height Percentile (Continued)

Age (Year)	BP Percentile ↓	Systolic BP (mmHg)								Diastolic BP (mmHg)							
		← Percentile of Height →								← Percentile of Height →							
		5th	10th	25th	50th	75th	90th	95th	5th	10th	25th	50th	75th	90th	95th		
11	50th	100	101	102	103	105	108	107	80	80	80	81	82	83	83		
	90th	114	114	116	117	119	119	120	74	74	74	75	76	77	77		
	95th	118	118	119	121	122	123	124	78	78	78	79	80	81	81		
	99th	125	125	126	128	129	130	131	85	85	86	87	87	88	89		
12	50th	102	103	104	105	107	109	109	81	81	81	82	83	84	84		
	90th	116	116	117	119	120	121	122	75	75	75	76	77	78	78		
	95th	119	120	121	123	124	125	126	79	79	79	80	81	82	82		
	99th	127	127	128	130	131	132	133	88	88	87	89	89	89	90		
13	50th	104	105	106	107	109	110	110	82	82	82	83	84	85	85		
	90th	117	118	119	121	122	123	124	76	76	76	77	78	79	79		
	95th	121	122	123	124	126	127	128	80	80	80	81	82	83	83		
	99th	128	129	130	132	133	134	135	87	87	88	89	89	90	91		
14	50th	106	106	107	109	110	111	112	83	83	83	84	85	86	86		
	90th	119	120	121	122	124	125	125	77	77	77	78	79	80	80		
	95th	123	123	125	126	127	129	129	81	81	81	82	83	84	84		
	99th	130	131	132	133	135	136	136	88	88	88	90	90	91	92		
15	50th	107	108	109	110	111	113	113	84	84	84	85	86	87	87		
	90th	120	121	122	123	125	126	127	78	78	78	79	80	81	81		
	95th	124	125	126	127	129	130	131	82	82	82	83	84	85	85		
	99th	131	132	133	134	136	137	138	89	89	90	91	91	92	93		
16	50th	108	108	110	111	112	114	114	84	84	85	86	86	87	88		
	90th	121	122	123	124	126	127	128	78	78	79	80	81	81	82		
	95th	125	126	127	128	130	131	132	82	82	83	84	85	85	86		
	99th	132	133	134	136	137	138	139	90	90	90	91	92	93	93		
17	50th	108	109	110	111	113	114	115	84	85	85	86	87	87	88		
	90th	122	122	123	125	126	127	128	78	79	79	80	81	81	82		
	95th	125	126	127	129	130	131	132	82	83	83	84	85	85	86		
	99th	133	133	134	136	137	138	139	90	90	91	91	92	93	93		

BP, blood pressure

\* The 90th percentile is 1.29 SD, 95th percentile is 1.645 SD, and the 99th percentile is 2.326 SD over the mean.

For research purposes, the standard deviations in Appendix Table B-1 allow one to compute BP Z-scores and percentiles for girls with height percentiles given in Table 4 (i.e., the 5th, 10th, 25th, 50th, 75th, 90th, and 95th percentiles). These height percentiles must be converted to height Z-scores given by (5% = -1.645; 10% = -1.28; 25% = -0.68; 50% = 0; 75% = 0.68; 90% = 1.28%; 95% = 1.645) and then computed according to the methodology in steps 2-4 described in Appendix B. For children with height percentiles other than these, follow steps 1-4 as described in Appendix B.

## CONTENTS

Practical skill №1: Measuring the pulse.....	4
Practical skill №2: Measuring of the blood pressure.....	6
Practical skill №3: ECG measurement.....	9
Practical skill №4: Techniques of the intravenous injection.....	11
Practical skill №5: Techniques of the intramuscular injection....	14
Practical skill №6: Techniques of the subcutaneous and intradermal injection.....	15
Practical skill №7: Techniques of the «drips intravenous infusions».....	16
Practical skill №8: Technique of breastfeeding.....	22
Practical skill №9: Artificial tube feeding methods .....	26
Practical skill №10: Palpation, percussion, auscultation of lungs in children in different age period.....	28

Practical skill №11: Exam of the heart.....	39
Practical skill №12: Exam of the kidney.....	47
Practical skill №13: Exam of the Abdomen.....	50
Appendix 1.....	65
LITERATURE.....	71

## LITERATURE

1. Propedeutics of paediatrics / V.A.Fjoklin, V.A. Klymenko and all // Kharkiv, 2010. – 346 p.
2. Walker H.K. Clinical Methods: The History, Physical, and Laboratory Examinations. 3rd edition.// H.K. Walker, W.D. Hall, J.W. Hurst /- Boston: Butterworths, 1990.- [Access for electronic versions: <http://www.ncbi.nlm.nih.gov/books/> ]
3. Blood Pressure Tables for Children and Adolescents from the Fourth// National Heart Lung and Blood institute: report of on the diagnosis, evaluation, and treatment of high blood pressure in children and adolescents.- [Access for electronic versions: <http://www.nhlbi.nih.gov/health-pro/guidelines/current/hypertension-pediatric-jnc-4/blood-pressure-tables>]
4. Goldberg C. A Practical Guide to Clinical Medicine // C. Goldberg /UCSD School of Medicine and VA Medical Center, San Diego, California, 2015.- [Access for electronic versions: [https:// meded. ucsd.edu/ clinicalmed/vital.htm](https://meded.ucsd.edu/clinicalmed/vital.htm).
5. Madhav K. S. Pediatric and Fundamental Electrocardiography. Developments in Cardiovascular Medicine// K. Madhav S, V.Hubert; T. Cecil W. - Advances in Body Surface Potential Mapping Instrumentation.- 1997.- Vol.27.- P.315–327.
6. Practical Clinical Skills: EKG Practice Strips and Tutorials.-2016.- [Access for electronic versions: <http://www.practicalclinicalskills.com/ekg>].
7. Advanced Education // [Access for electronic versions: [http://ccnmtl.columbia.edu/projects/aegd/mod01\\_mec\\_ivcomp.html](http://ccnmtl.columbia.edu/projects/aegd/mod01_mec_ivcomp.html)].
8. Ten steps to accurate manual blood pressure measurement /[Access for electronic versions: <http://www.suntechmed.com/blog/entry/4-bp-measurement/42-10-steps-to-accurate-manual-blood-pressure-measurement>].

9. Clinical practice guidelines/ [Access for electronic versions: [http://www.rch.org.au/clinicalguide/guideline\\_index/Intravenous\\_access\\_Peripheral/](http://www.rch.org.au/clinicalguide/guideline_index/Intravenous_access_Peripheral/)].
10. Introduction to IVs: lecture / [Access for electronic versions: <http://www.cwladis.com/math104/lecture6.php>].
11. Lung exam [Access for electronic versions: <https://prohealthsys.com/resources/assessment/physical-assessment/heart-lung-abdomen/lung-exam/>].
12. Respiratory examination / [Access for electronic versions: <http://www.slideshare.net/magdisasi/respiratory-examination>].
13. Physical examination / [Access for electronic versions: <https://www.clicktocurecancer.info/physical-examination/auscultation.html>].
14. Abnormalities-in-rate-and-rhythm-of-breathing-flash-cards/ [Access for electronic versions: <https://quizlet.com/6961218/abnormalities-in-rate-and-rhythm-of-breathing-flash-cards/>].
15. Exam of the Heart / [Access for electronic versions: [http://rogerqualo.webs.com/BraveNet/PAGE\\_CLINIQUE/SemeiRevi\\_AorticDis1.html](http://rogerqualo.webs.com/BraveNet/PAGE_CLINIQUE/SemeiRevi_AorticDis1.html)].
16. Exam of the Heart / [Access for electronic versions: [http://www.jivamedia.com/optimage/education/Section\\_5-CARDIOVASCULAR.html](http://www.jivamedia.com/optimage/education/Section_5-CARDIOVASCULAR.html)].
17. Inquiry and general inspection of patients with diseases of digestive system / [Access for electronic versions: [http://intranet.tdmu.edu.ua/data/kafedra/internal/propedeutic\\_vn\\_des/classes\\_stud/en/med/medprof/ptn/Internal\\_Medicine\\_Propedeutics/3/Lesson\\_06\\_Inquiry\\_and\\_general\\_inspection\\_of\\_patients\\_with\\_diseases.htm](http://intranet.tdmu.edu.ua/data/kafedra/internal/propedeutic_vn_des/classes_stud/en/med/medprof/ptn/Internal_Medicine_Propedeutics/3/Lesson_06_Inquiry_and_general_inspection_of_patients_with_diseases.htm)].
18. Abdominal assessment/ [Access for electronic versions: <http://www.inurses.com/skills-in-nursing/abdominal-assessment>].

19. Hammoudi D.Sinoe Medical Association: surgical abdomen / [Access for electronic versions: [http://sinoemedicalassociation.org/surgery/SURGERY/Surgical Abdomen.htm](http://sinoemedicalassociation.org/surgery/SURGERY/Surgical%20Abdomen.htm)].