

**KHARKIV NATIONAL MEDICAL UNIVERSITY**

**DEPARTMENT OF PROPEDEUTICS OF INTERNAL MEDICINE N1**

# **PRACTICUM**

**in Propedeutics of Internal Medicine  
for 3<sup>rd</sup> year students of 6<sup>th</sup> medical faculty**

## **Part 1:**

**“Main methods of the patient’s examination in internal medicine”**

Student \_\_\_\_\_

Group \_\_\_\_\_

Teacher \_\_\_\_\_

\_\_\_\_\_

Practicum in Propedeutics of Internal Medicine. Part 1: "Main methods of the patient's examination in internal medicine": Method. instr. for students / Authors. T.V. Ashcheulova, O.N. Kovalyova, G.V. Demydenko, S.O. Shapovalova, O.A. Kochubiei, O.V. Honchar, S.V. Ivanchenko, A.V. Kozhemyaka, M.A. Vizir. – Kharkiv: KhNMU, 2017. – 63 c.

Authors: T.V. Ashcheulova  
O. N. Kovalyova  
A.V. Demydenko  
O.A. Kochubiei  
O.V. Honchar  
S.V. Ivanchenko  
A.V. Kozhemyaka  
M.A. Vizir

## THEMATIC PRACTICAL CLASSES PLAN of Propedeutics to Internal Medicine

### Part 1:

#### “Main methods of the patients examination in internal diseases clinics”

**Content 1.** Introduction to internal medicine. Main rules of inquiry and inspection of the patients

1. Case history scheme. Inquiry of the patient: patient's complaints, their detailed description, questioning on organs and systems.
2. Anamnesis morbi. Anamnesis vitae.
3. General inspection of the patients. Diagnostic significance of symptoms revealed during patient inspection.
4. Inspection of separate body parts: head, neck, trunk, extremities.

**Content 2.** Physical and instrumental examination methods of the broncho-pulmonary system

5. Main complaints and general inspection of the patients with respiratory organs pathology. Palpation of the chest.
6. Percussion as method of physical examination of the lungs. Comparative percussion of the lungs technique. Topographic percussion of the lungs.
7. Auscultation as method of physical examination of the lungs. Auscultation of the lungs technique. The main respiratory sounds.
8. Auscultation of the lungs: additional respiratory sounds (rales, crepitation, pleural friction sound). Laboratory sputum and pleural fluid analysis. Instrumental methods of respiratory organs examination.

**Content 3.** Physical methods of cardiovascular system examination

9. Physical methods of cardiovascular system examination. Inquiry and general inspection of the patients with cardiovascular pathology. Inspection and palpation of precordial area.
10. Percussion of the heart.
11. Auscultation of the heart. Normal heart sounds, reduplication of the sounds, additional sounds (triple rhythm, gallop rhythm). Auscultation of the heart: organic and functional heart murmurs.

**12.** Study of arterial pulse and blood pressure.

**Content 4.** Instrumental methods of cardiovascular system examination

**13.** Electrocardiographic method of cardiac function examination. Technique of ECG registration and reading.

**14.** ECG signs of hypertrophy of heart atriums and ventricles.

**15.** The main ECG syndromes of the myocardium damage (ischemia, injury, necrosis). ECG in myocardial infarction.

**16.** Electrocardiographic examination of patients with automaticity and excitability function alterations.

**17.** Electrocardiographic examination of patients with conductivity function alterations.

**Content 5.** Main examination methods of digestive organs and kidneys.

**18.** Inquiry and inspection of the patients with digestive organs diseases. Inspection and superficial palpation of the abdomen.

**19.** Deep, sliding, methodic palpation of intestines and stomach. Deep, sliding, methodic palpation of liver, spleen. Liver percussion.

**20.** Inquiry and inspection of the patients with renal diseases. Instrumental and laboratory methods of examination of urinary system.

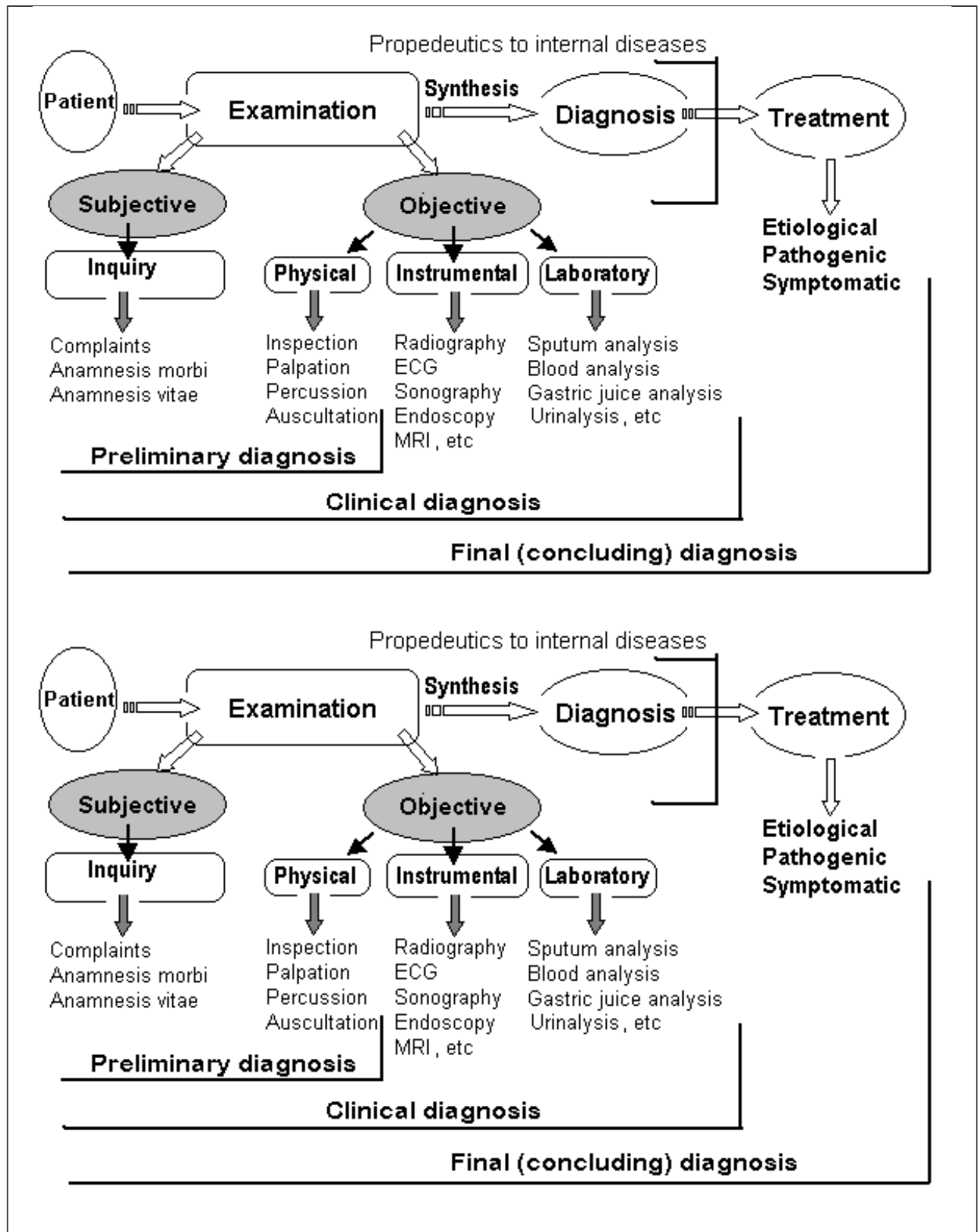
**21.** Analysis of urine

## Part 1:

### “Main methods of the patients examination in internal diseases clinics”

**Content 1.** Introduction to internal medicine. Main rules of inquiry and inspection.

**Topic 1.** Case history scheme. Inquiring of the patient



**Propedeutics** (Gk *propos* – introduction) to internal diseases is \_\_\_\_\_

**Diagnostics** (Gk *dia* – through, *gnosis* – knowledge) is \_\_\_\_\_

**Diagnosis** is \_\_\_\_\_

*Preliminary diagnosis* is based on \_\_\_\_\_

*Clinical diagnosis* is based on \_\_\_\_\_

*Final diagnosis* is based on \_\_\_\_\_

Diagnosis has the following structure:

1. \_\_\_\_\_
2. \_\_\_\_\_
3. \_\_\_\_\_

### **Symptom**

Subjective and objective symptoms are differentiated.

*Subjective symptoms* are those that \_\_\_\_\_

*Objective symptoms* are those that \_\_\_\_\_

The symptoms are divided into *pathological symptoms* (pain, elevated temperature) and *compensatory symptoms* (tachycardia, tachypnoea, hypertrophy).

According to significance symptoms can be \_\_\_\_\_.

According to time symptoms are \_\_\_\_\_.

According to prognosis symptoms are \_\_\_\_\_.

**Syndrome** is defined as \_\_\_\_\_

**Symptomocomplex** is defined as \_\_\_\_\_



|  |    |                        |
|--|----|------------------------|
| <b>Questions on organs and systems</b> | 3. | CENTRAL NERVOUS SYSTEM |
|  |    | _____                  |
|  |    | _____                  |
|  | 4. | RESPIRATORY SYSTEM     |
|  |    | _____                  |
|  |    | _____                  |
|  |    | _____                  |
|  | 3. | CARDIOVASCULAR SYSTEM  |
|  |    | _____                  |
|  |    | _____                  |
|  | 4. | DIGESTIVE SYSTEM       |
|  |    | _____                  |
|  |    | _____                  |
|  |    | _____                  |
|  | 5. | URINARY SYSTEM         |
|  |    | _____                  |
|  |    | _____                  |
|  | 8. | LOCOMOTOR SYSTEM       |
|  |    | _____                  |
|  |    | _____                  |

## Topic 2. Anamnesis morbi. Anamnesis vitae.

|                        |                        |       |
|------------------------|------------------------|-------|
| <b>Anamnesis morbi</b> | 1.                     | _____ |
|                        |                        | _____ |
|                        |                        | _____ |
|                        | 2.                     | _____ |
|                        |                        | _____ |
|                        |                        | _____ |
|                        | 3.                     | _____ |
|                        |                        | _____ |
|                        |                        | _____ |
|                        | 4.                     | _____ |
|                        |                        | _____ |
|                        |                        | _____ |
|                        |                        | _____ |
|                        |                        | _____ |
|                        |                        | _____ |
|                        | <b>Anamnesis vitae</b> | 1)    |
|                        |                        | _____ |
|                        |                        | _____ |
| 2)                     |                        | _____ |
|                        |                        | _____ |
|                        |                        | _____ |
| 3)                     |                        | _____ |
|                        |                        | _____ |
|                        |                        | _____ |
| 4)                     |                        | _____ |
|                        |                        | _____ |
|                        |                        | _____ |
|                        |                        | _____ |
|                        |                        | _____ |
|                        |                        | _____ |

### Topic 3-4. General inspection of the patients.

#### GENERAL INSPECTION

Status praesens is: \_\_\_\_\_

The criteria of patient's condition are \_\_\_\_\_

Good patient's condition is characterized \_\_\_\_\_

Satisfactory patient's condition (status morboacili) is characterized: \_\_\_\_\_

Moderate condition (status ingravescens) is characterized: \_\_\_\_\_

Severe condition (status morbogravi) is characterized: \_\_\_\_\_

Extremely Severe condition (status gravissimus) is characterized: \_\_\_\_\_

Consciousness (sensorium) may be: \_\_\_\_\_

The deranged consciousness is divided into \_\_\_\_\_

Possible causes of deranged consciousness are: \_\_\_\_\_

The forms of excited consciousness: \_\_\_\_\_

Twilight state is characterized: \_\_\_\_\_

Delirium is characterized: \_\_\_\_\_

The forms of excited consciousness are: \_\_\_\_\_

Complete the following table:

#### The forms of depressed consciousness

| Forms      | Definition | State |
|------------|------------|-------|
| Cloudiness |            |       |
| Stupor     |            |       |

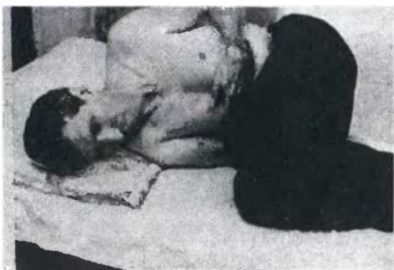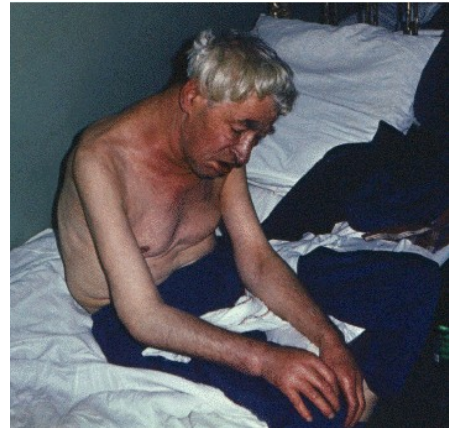**GENERAL  
INSPECTION**

|       |  |  |
|-------|--|--|
|       |  |  |
| Sopor |  |  |
| Coma  |  |  |

What kinds of coma do you know? Give examples. \_\_\_\_\_

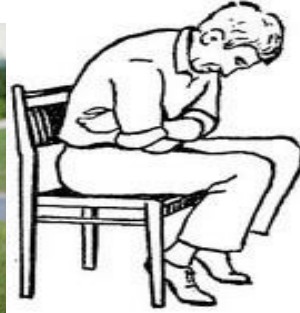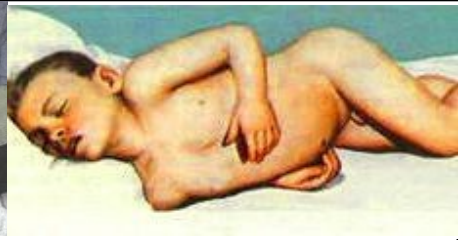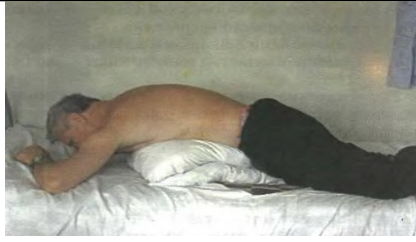\_\_\_\_\_

Define and mark the type of forced posture for each patient



\_\_\_\_\_

\_\_\_\_\_



**GENERAL INSPECTION**

**Gait.** Gait is \_\_\_\_\_

Spastic gait is characterized: \_\_\_\_\_

Paretic gait is characterized: \_\_\_\_\_

Hemiplegic/circumductive gait is characterized: \_\_\_\_\_

Doll's/puppet gait is characterized: \_\_\_\_\_

Peroneal gait is characterized: \_\_\_\_\_

Cerebellar gait (wobbly/tottering/reeling gait) is characterized: \_\_\_\_\_

Describe the face in patients with diseases of respiratory system: \_\_\_\_\_

facies pneumonica \_\_\_\_\_

facies tuberculous \_\_\_\_\_

facies asthmatica \_\_\_\_\_

facies adenoidea \_\_\_\_\_

**GENERAL  
INSPECTION**

Describe the face in patients with diseases of cardiovascular system: \_\_\_\_\_

facies aortale \_\_\_\_\_

facies mitrale \_\_\_\_\_

facies Corvisari \_\_\_\_\_

facies plethorica \_\_\_\_\_

Describe the face in patients with endocrine disorders: \_\_\_\_\_

facies acromegalica \_\_\_\_\_

–  
facies in patients with Cushing's syndrome \_\_\_\_\_

facies myxoedemica \_\_\_\_\_

–  
facies basedovica \_\_\_\_\_

Describe the face in patients with diseases of kidney: \_\_\_\_\_

facies nefritica \_\_\_\_\_

Describe the face in patients with diseases of digestive system: \_\_\_\_\_

facies Hyppocratica \_\_\_\_\_

Describe the face in patients with diseases of nervous system: \_\_\_\_\_

facies amimica \_\_\_\_\_

risus sardonicus \_\_\_\_\_

facies asymmetrica \_\_\_\_\_

Describe the face in patients with infectious disease: \_\_\_\_\_

facies fibrilis \_\_\_\_\_

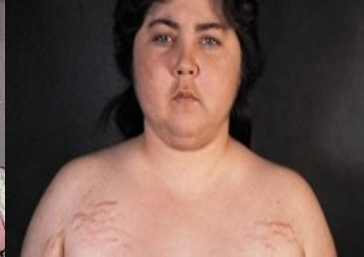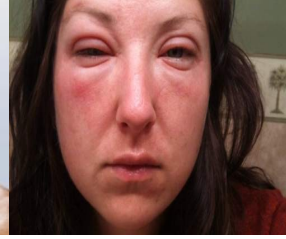
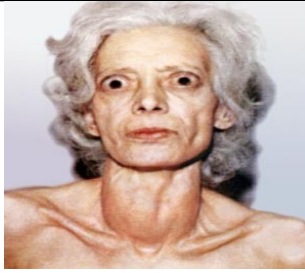facies in patients with parotitis: \_\_\_\_\_

Describe the face in patients with diseases of blood system: \_\_\_\_\_

facies anemic \_\_\_\_\_

facies as a "wax-doll" \_\_\_\_\_

Define and mark a facies in patients with different diseases



**GENERAL  
INSPECTION**

**Color of the skin.** Give examples of diseases which are characterized by the following changes in skin color:

Pale color of the skin (cutis pallida) \_\_\_\_\_

Red color of the skin (cutis rubra, erythema) \_\_\_\_\_

Cyanosis (cutis cyanotica) \_\_\_\_\_

Yellow skin and mucosa (cutis icterica, s. icterus) \_\_\_\_\_

Brown or bronze skin \_\_\_\_\_

**Eruption of the skin.** Herpetic lesions (herpes) is \_\_\_\_\_

Hemorrhage lesions are of different forms: \_\_\_\_\_

Hematoma is \_\_\_\_\_

Erythema \_\_\_\_\_

Teleangioectasia is \_\_\_\_\_

Ulcer (ulcus) is \_\_\_\_\_

Abscess is \_\_\_\_\_

Scars is \_\_\_\_\_

**Turgor and elasticity of the skin.**

Turgor (turgor) of the tissue depends on \_\_\_\_\_

**Moisture of skin: the reasons of alteration (dryness / wetness)** \_\_\_\_\_

**The skin derivatives.** The following pathological changes of nails are of great diagnostic meaning: \_\_\_\_\_

Nails in a form of "watch glass" are characterized \_\_\_\_\_

**Hair.** Abnormally excessive hair growth may be present:

Deficient hair growth is characteristic of: \_\_\_\_\_

**Subcutaneous fat.** Where to measure: \_\_\_\_\_

In normosthenic person thickness of skinfold \_\_\_\_\_

Ginoid type of obesity is characterized \_\_\_\_\_

Android type of obesity is characterized \_\_\_\_\_

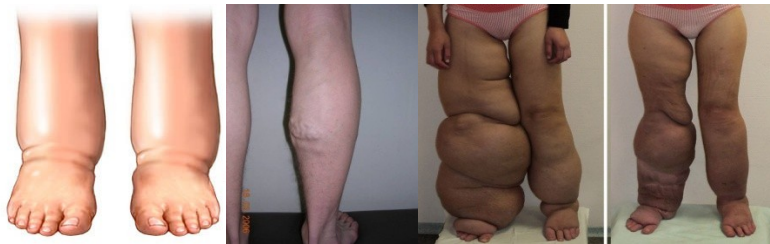**Edema.** According to the pathogenic and location factors, edema may be: \_\_\_\_\_

The main reasons of general edema are: \_\_\_\_\_

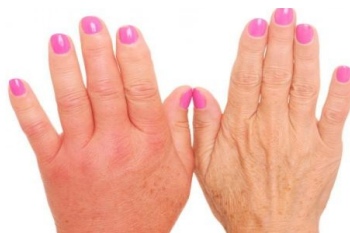General edema is characterized: \_\_\_\_\_

The main reasons of local edema are: \_\_\_\_\_

Identify and write the possible cause of edema in pictures



\_\_\_\_\_  
\_\_\_\_\_



\_\_\_\_\_  
\_\_\_\_\_

**GENERAL  
INSPECTION**

—  
**Lymph nodes.** Groups of regional lymph nodes include: \_\_\_\_\_

The examination of lymph nodes in definite order: \_\_\_\_\_

The main causes of enlargement of the lymph nodes: \_\_\_\_\_

**Diagnostic meaning of enlarged lymph nodes localization.**

| Localization    | Diseases |
|-----------------|----------|
| Occipital       |          |
| Submandibular   |          |
| Axillary        |          |
| Inguinal        |          |
| Cubital (local) |          |

**Thyroid gland.** Inspection \_\_\_\_\_

Palpation \_\_\_\_\_

**Muscular system.** \_\_\_\_\_

Development \_\_\_\_\_

sex and age correspondence \_\_\_\_\_

tenderness \_\_\_\_\_

muscular tone \_\_\_\_\_

Muscular dystrophy is \_\_\_\_\_

Causes of muscular weakness are \_\_\_\_\_

Cramps (spasmus) is \_\_\_\_\_

Paralysis is \_\_\_\_\_

**Bones and joints system.** Symmetry of joints, shape; Configuration (normal, deformed, edema);

Hyperemia of skin and local hyperthermia; Movements (active, passive, free or limited); Palpable tenderness related to passive movements (indicate joints); Crackles, fluctuation. \_\_\_\_\_

|                                  |  |
|----------------------------------|--|
| <p><b>GENERAL INSPECTION</b></p> |  |
|----------------------------------|--|

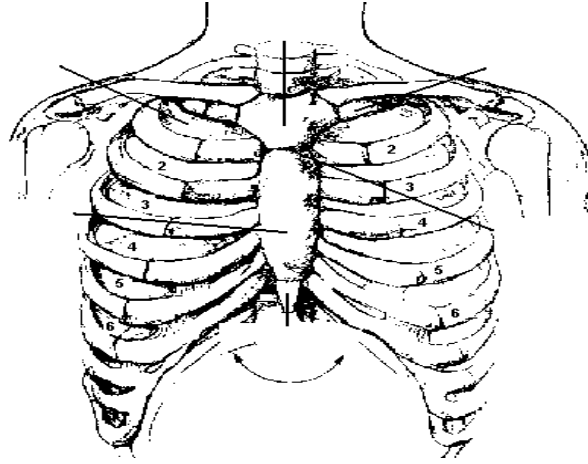
**Content 2.** Physical and instrumental examination methods of the broncho-pulmonary system **Topic 5-8.**

| <p><b>Inquiring</b></p> | <hr/> <hr/> <p>The main complaints of the patients with disease of the respiratory system are:</p> <hr/> <hr/> <hr/> <hr/> <p>Additional complaints:</p> <hr/> <hr/> <hr/> <hr/> <hr/> <hr/> <p><i>Dyspnoea:</i></p> <hr/> <hr/> <hr/> <hr/> <hr/> <hr/> <hr/> <hr/> <hr/> <hr/> <p style="text-align: center;">Conditions causing dyspnoea classified by rate of onset</p> <table border="1" style="width: 100%;"> <thead> <tr> <th style="width: 5%;">№</th> <th style="width: 45%;">Categories</th> <th style="width: 50%;">Causes</th> </tr> </thead> <tbody> <tr> <td style="text-align: center;">1.</td> <td><b>Dramatically sudden:</b> over minutes</td> <td></td> </tr> <tr> <td style="text-align: center;">2.</td> <td><b>Acute:</b> over hours</td> <td></td> </tr> </tbody> </table> | №      | Categories | Causes | 1. | <b>Dramatically sudden:</b> over minutes |  | 2. | <b>Acute:</b> over hours |  |
|-------------------------|---|--------|------------|--------|----|--|--|----|--------------------------|--|
| №                       | Categories  | Causes |            |        |    |  |  |    |                          |  |
| 1.                      | <b>Dramatically sudden:</b> over minutes  |        |            |        |    |  |  |    |                          |  |
| 2.                      | <b>Acute:</b> over hours  |        |            |        |    |  |  |    |                          |  |

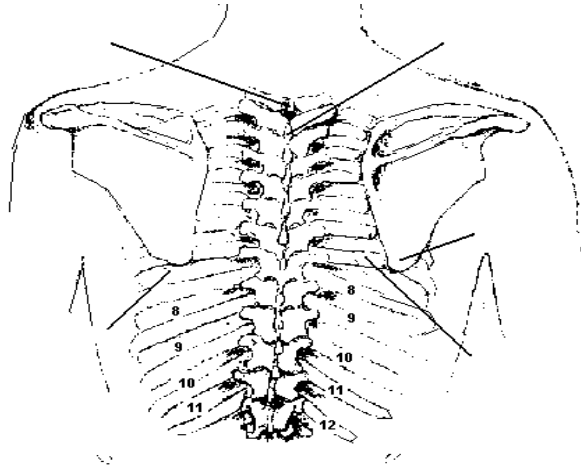


**INSPECTION  
OF THE  
CHEST**

Complete the anatomy points of the chest wall. Anterior view



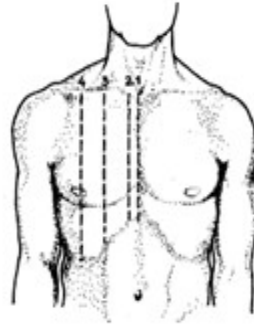
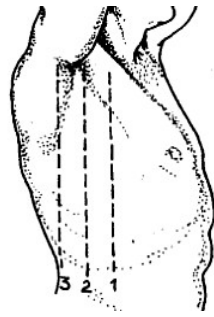
Complete the anatomy points of the chest wall. Posterior view



Write down topographical lines:

**Anterior surface:**

- 1
- 2
- 3
- 4



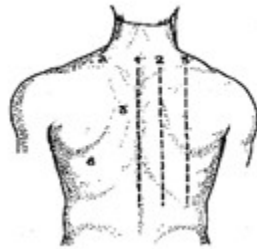
**Lateral surface:**

1

2

3

**INSPECTION  
OF THE  
CHEST**



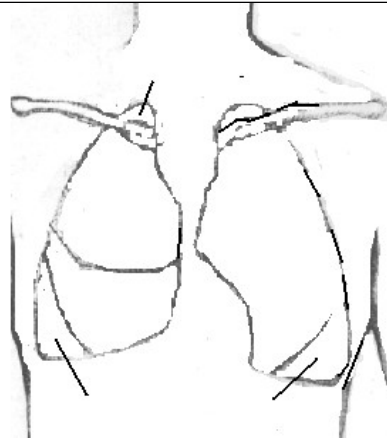
**Posterior surface:**

1

2

3

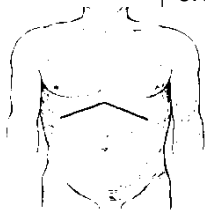
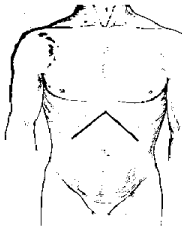
**Point apex of the lung and lobes**



Write down regions:

- \_\_\_\_\_ **region** - above clavicles;
- \_\_\_\_\_ **region** - below clavicle;
- \_\_\_\_\_ **region** - above scapulae;
- \_\_\_\_\_ **region** - between the scapulae;
- \_\_\_\_\_ **region** - below scapular;
- \_\_\_\_\_ the lowest points;
- \_\_\_\_\_ **lungs fields**.

Static inspection



Static inspection includes: \_\_\_\_\_

\_\_\_\_\_

\_\_\_\_\_

\_\_\_\_\_

The shape of the chest is described in that order: \_\_\_\_\_

\_\_\_\_\_

\_\_\_\_\_

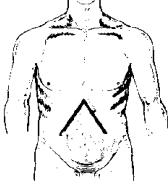


\_\_\_\_\_

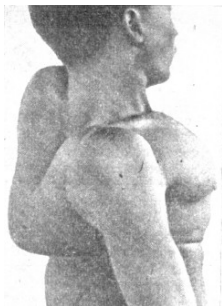3. \_\_\_\_\_

4. \_\_\_\_\_

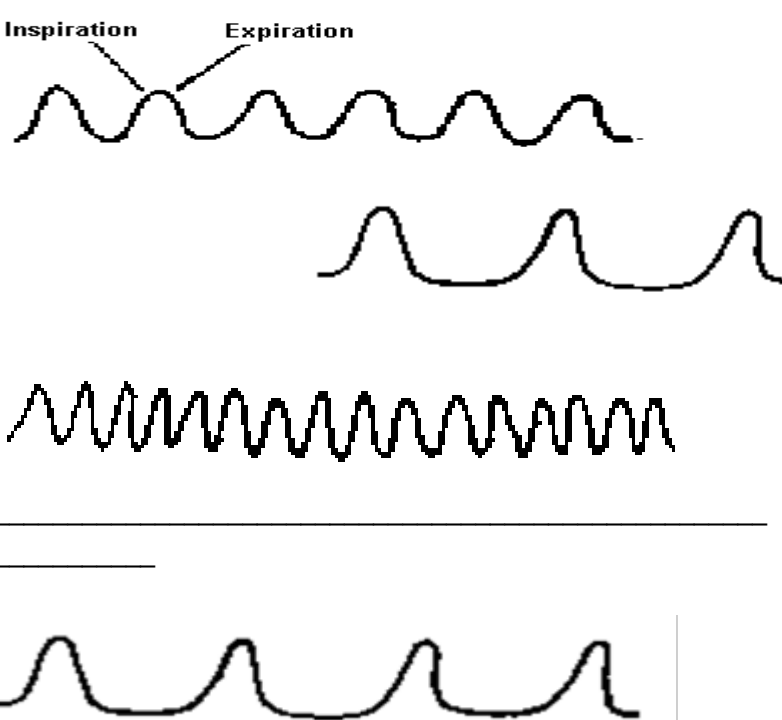
5. \_\_\_\_\_




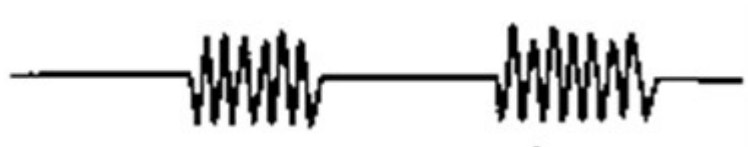
6. \_\_\_\_\_

|  |   |
|--|---|
|  | <hr/> <hr/> <p>7.</p> <p>Physiological shapes of the chest:</p> <p>1</p> <hr/> <hr/> <hr/> <hr/> <p>2</p> <hr/> <hr/>  <p>3</p> <hr/> <hr/> <hr/> <hr/> <p><i>Pathological shapes of the chest</i></p> <hr/> <hr/> <hr/> |
| <p>Static inspection</p>  | <p><i>Name and describe the shapes of the chest</i></p> <hr/>  <hr/> <hr/> <hr/>   |





|                                 |   |
|---------------------------------|---|
|                                 | <p>_____</p> <p><i>Decreased volume of the one part of the chest</i></p> <p>_____</p> <p>_____</p> <p>_____</p>   |
| Dynamic inspection of the chest | <p><i>Dynamic inspection includes</i> _____</p> <p>_____</p> <p>_____</p> <p>_____</p> <p>_____</p> <p><i>Types of respiration:</i></p> <p>_____</p> <p>_____</p> <p>_____</p> <p><i>Normal breathing rate:</i> _____</p> <p>_____</p> <p>_____</p> |
| Dynamic inspection of the chest | <p><i>Specify the breathing type</i> _____</p> <p><b>Inspiration</b>      <b>Expiration</b></p>  <p>_____</p> <p>_____</p> <p>_____</p>                         |

|                                      |  |
|--------------------------------------|--|
| <p><b>PALPATION OF THE CHEST</b></p> | <p>Describe type of breathing and pathological state, when it observed</p>  <hr/> <hr/> <hr/> <hr/>  <p>Apnea</p> <hr/> <hr/> <hr/> <hr/>  <hr/> <hr/> <hr/> <hr/>  <hr/> <hr/> <hr/> <hr/> |
|                                      | <p><b>PERCUSSION OF THE LUNGS</b></p>  |

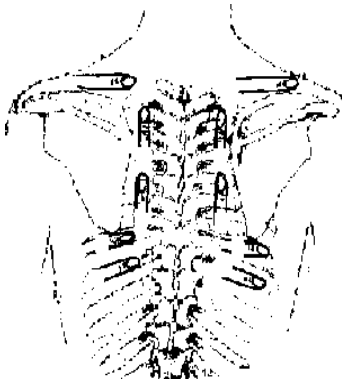
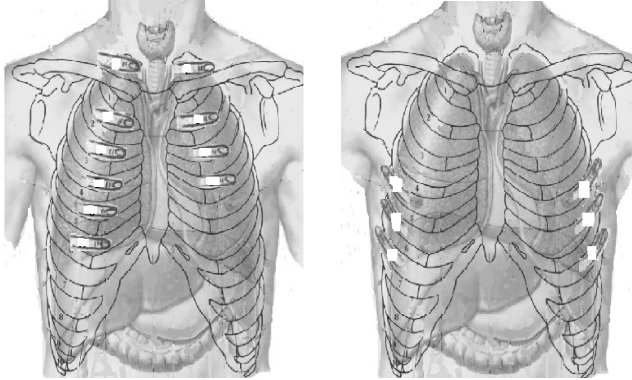
Vocal fremitus is decreased

Vocal fremitus can be absent

**PERCUSSION OF THE LUNGS**

The task of comparative percussion is

Numerate the order of comparative percussion in anterior, lateral, posterior view.



**PERCUSSION OF THE LUNGS**

Anterior view

Posterior view

Lateral

view

Comparative percussion helps to determine whether the underlying tissues are air-filled, fluid-filled, or solid. The common cause of percussion changes include:

---



---



---



---



---



---

Characteristics of the percussion sounds

| Sound                       | Relative intensity | Relative pitch | Relative duration | Example location | Pathological examples |
|-----------------------------|--------------------|----------------|-------------------|------------------|-----------------------|
| Clear pulmonary (resonance) | Loud               | Low            | Long              | Normal lungs     | ---                   |
| Intermediate                |                    | Higher         |                   |                  |                       |
| Bandbox (hyper-resonance)   |                    |                | Longer            |                  |                       |
| Dullness                    | Soft (Medium)      | High (Medium)  |                   |                  |                       |
| Tympany                     |                    |                |                   |                  |                       |
| Metallic                    |                    |                |                   |                  |                       |
| Cracked-pot                 |                    |                |                   |                  |                       |

**Intermediate** pulmonary sound causes include:

1. \_\_\_\_\_  
\_\_\_\_\_;
2. \_\_\_\_\_  
\_\_\_\_\_;
3. \_\_\_\_\_  
\_\_\_\_\_;
4. \_\_\_\_\_  
\_\_\_\_\_;
5. \_\_\_\_\_  
\_\_\_\_\_;

**Dullness** appear when solid tissue replaces air-containing lungs in conditions as:

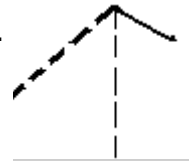
1. \_\_\_\_\_  
\_\_\_\_\_;
2. \_\_\_\_\_  
\_\_\_\_\_;
3. \_\_\_\_\_  
\_\_\_\_\_;
4. \_\_\_\_\_  
\_\_\_\_\_;

**Bandbox**

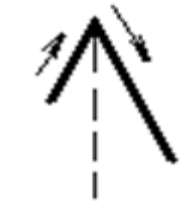**sound**

|   | <p><b>Tympany</b> suggests</p> <p>_____</p> <p><b>Topographic percussion of the lungs:</b></p> <ul style="list-style-type: none"> <li>▪ _____</li> <li>▪ _____;</li> <li>▪ _____;</li> <li>▪ _____.</li> </ul> <p><b>Lower borders of the lungs in normosthenic persons.</b></p> <table border="1" style="width: 100%; border-collapse: collapse; text-align: center;"> <thead> <tr> <th style="width: 30%;">Topographic lines</th> <th style="width: 35%;">Right lung</th> <th style="width: 35%;">Left lung</th> </tr> </thead> <tbody> <tr> <td>Parasternal</td> <td></td> <td></td> </tr> <tr> <td>Midclavicular</td> <td></td> <td></td> </tr> <tr> <td>Anterior axillary</td> <td></td> <td></td> </tr> <tr> <td>Midaxillary</td> <td>8<sup>th</sup> interspace</td> <td></td> </tr> <tr> <td>Posterior axillary</td> <td></td> <td></td> </tr> <tr> <td>Scapular</td> <td></td> <td></td> </tr> <tr> <td>Paraspinal</td> <td></td> <td></td> </tr> </tbody> </table> | Topographic lines | Right lung | Left lung                        | Parasternal                 |  |  | Midclavicular |  |  | Anterior axillary |  |  | Midaxillary | 8 <sup>th</sup> interspace |  | Posterior axillary |  |  | Scapular |  |  | Paraspinal |  |  |
|---|---|-------------------|------------|----------------------------------|-----------------------------|--|--|---------------|--|--|-------------------|--|--|-------------|----------------------------|--|--------------------|--|--|----------|--|--|------------|--|--|
| Topographic lines                       | Right lung  | Left lung         |            |                                  |                             |  |  |               |  |  |                   |  |  |             |                            |  |                    |  |  |          |  |  |            |  |  |
| Parasternal                             |   |                   |            |                                  |                             |  |  |               |  |  |                   |  |  |             |                            |  |                    |  |  |          |  |  |            |  |  |
| Midclavicular                           |   |                   |            |                                  |                             |  |  |               |  |  |                   |  |  |             |                            |  |                    |  |  |          |  |  |            |  |  |
| Anterior axillary                       |   |                   |            |                                  |                             |  |  |               |  |  |                   |  |  |             |                            |  |                    |  |  |          |  |  |            |  |  |
| Midaxillary                             | 8 <sup>th</sup> interspace  |                   |            |                                  |                             |  |  |               |  |  |                   |  |  |             |                            |  |                    |  |  |          |  |  |            |  |  |
| Posterior axillary                      |   |                   |            |                                  |                             |  |  |               |  |  |                   |  |  |             |                            |  |                    |  |  |          |  |  |            |  |  |
| Scapular                                |   |                   |            |                                  |                             |  |  |               |  |  |                   |  |  |             |                            |  |                    |  |  |          |  |  |            |  |  |
| Paraspinal                              |   |                   |            |                                  |                             |  |  |               |  |  |                   |  |  |             |                            |  |                    |  |  |          |  |  |            |  |  |
| <p><b>AUSCULTATION OF THE LUNGS</b></p> | <p style="text-align: center;"><b>AUSCULTATION OF THE LUNGS</b></p> <p>Auscultation includes:</p> <p>1.</p> <p>_____;</p> <p>2.</p> <p>_____.</p> <table border="1" style="width: 100%; border-collapse: collapse; text-align: center;"> <thead> <tr> <th colspan="2">Lung sounds</th> </tr> <tr> <th style="width: 50%;">Main respiratory (breath) sounds</th> <th style="width: 50%;">Adventitious (added) sounds</th> </tr> </thead> <tbody> <tr> <td style="height: 50px;"></td> <td></td> </tr> </tbody> </table> <p>Specify the type of breathing and its changes.</p> <div style="text-align: center;"> </div> <p><b>Pathologically decreased vesicular breathing</b> observes in:</p> <p>I. abnormal generation of breath sounds occurs in:</p>   | Lung sounds       |            | Main respiratory (breath) sounds | Adventitious (added) sounds |  |  |               |  |  |                   |  |  |             |                            |  |                    |  |  |          |  |  |            |  |  |
| Lung sounds                             |   |                   |            |                                  |                             |  |  |               |  |  |                   |  |  |             |                            |  |                    |  |  |          |  |  |            |  |  |
| Main respiratory (breath) sounds        | Adventitious (added) sounds   |                   |            |                                  |                             |  |  |               |  |  |                   |  |  |             |                            |  |                    |  |  |          |  |  |            |  |  |
|   |   |                   |            |                                  |                             |  |  |               |  |  |                   |  |  |             |                            |  |                    |  |  |          |  |  |            |  |  |

**AUSCULTATION OF THE LUNGS**



abnormal transmission of breath sounds results from:



**Pathologically increased vesicular breathing** occurs

Specify the breathing and conditions when it observed

Specify the breathing, points of auscultation, origin

**Pathological bronchial breathing** is observed in **consolidation of the pulmonary tissue** in:

in formation of an **empty cavity** in the lung communicated with a large bronchus:

**Amphoric respiration** is heard in the presence

of \_\_\_\_\_

\_\_\_\_\_

\_\_\_\_\_

**Bronchovesicular or mixed breathing** \_\_\_\_\_

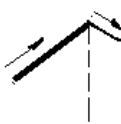


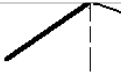
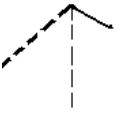

\_\_\_\_\_


\_\_\_\_\_

\_\_\_\_\_

\_\_\_\_\_

**AUSCULTATION OF THE LUNGS**

| Sound  | Duration   | Intensity of the expiratory sound | Pitch of the expiratory sound | Example location        | Pathologic example  |
|--|--|-----------------------------------|-------------------------------|-------------------------|---|
| <br>Vesicular             | Inspiratory sounds last longer than expiratory one | Soft                              | Low                           | Over most of both lungs |   |
| <br>Decreased vesicular |  |                                   |                               |                         |  |
| <br>Increased vesicular |  |                                   |                               |                         |   |
| <br>Cogwheel            |  |                                   |                               |                         |   |
|                         |  |                                   |                               |                         |   |

|   |   |                              |            |             |         |  |
|---|---|------------------------------|------------|-------------|---------|--|
| <b>SPUTUM ANALYSIS</b>                            | Bronchial   |                              |            |             |         |  |
|   |  |                              |            |             |         |  |
|   | Broncho-vesicular   |                              |            |             |         |  |
|   | <b>Adventitious (added) sounds</b>  |                              |            |             |         |  |
|   | are: _____  |                              |            |             |         |  |
|   | _____   |                              |            |             |         |  |
|   | _____   |                              |            |             |         |  |
|   | <b>Differential diagnosis of adventitious sounds</b>                              |                              |            |             |         |  |
|   | Signs   | .....rales                   | .....rales | Crepitation |         |  |
|   | Relation to the respiratory phases  | Best heard during expiration |            |             |         |  |
| Change during cough                               |   |                              |            |             |         |  |
| Pressure with the stethoscope                     |   | Without changes              |            |             |         |  |
| Breathing movement with close nose and mouth      |   |                              |            |             | Absent  |  |
| <b>SPUTUM ANALYSIS</b>                            |   |                              |            |             |         |  |
| Clinical sputum analysis includes:                |   |                              |            |             |         |  |
| _____   |   |                              |            |             |         |  |
| _____   |   |                              |            |             |         |  |
| _____   |   |                              |            |             |         |  |
| In macroscopic study assessed                     |   |                              |            |             |         |  |
| _____   |   |                              |            |             |         |  |
| <b>Sputum revealed in macroscopic examination</b> |   |                              |            |             |         |  |
| Character   | Consistency   | Color                        | Odor       | Layerness   | Disease |  |
| Mucous  |   | Glass-like                   |            |             |         |  |
| Mucopurulent                                      |   |                              | Odorless   |             |         |  |
| Purulent  |   |                              |            |             |         |  |
| Mucous  |   |                              |            | Absent      |         |  |

|                      |               |                       |          |        |   |
|----------------------|---------------|-----------------------|----------|--------|---|
| bloody               |               |                       |          |        |   |
| Muco-purulent bloody |               |                       |          |        |   |
| Bloody               | Liquid, foamy |                       | Odorless | Absent | Pulmonary hemorrhage: in tuberculosis, wounds, lung tumor |
| Serous               |               | Transparent yellowish | Odorless | Absent | Pulmonary edema   |

**Sputum elements in microscopic study**

| Cellular elements | Fibrous elements | Crystal elements |
|-------------------|------------------|------------------|
|                   |                  |                  |

**Bacterioscopic study**

---



---



---



---



---



---



---



---



---



---



---



---



---



---



---



---

| Disease          | Sputum amount | Sputum character | Macroscopic study | Microscopic study |
|------------------|---------------|------------------|-------------------|-------------------|
| Acute bronchitis |               |                  |                   |                   |

|                                   |                        |         |        |                             |  |
|-----------------------------------|------------------------|---------|--------|-----------------------------|--|
| <b>STUDY OF THE PLEURAL FLUID</b> | Chronic bronchitis     | Various |        |                             | Leucocytes – large amount; erythrocytes, macrophages |
|                                   | Bronchiectasis         |         |        |                             |  |
|                                   | Bronchial asthma       |         | Mucous |                             |  |
|                                   | Lobar pneumonia        |         |        | Fibrin clots, changed blood |  |
|                                   | Pulmonary abscess      |         |        |                             |  |
|                                   | Pulmonary tuberculosis |         |        |                             |  |
|                                   | Bronchopulmonary tumor |         |        |                             |  |

**STUDY OF THE PLEURAL FLUID**

**Macroscopic**

**study:** \_\_\_\_\_  
 \_\_\_\_\_  
 \_\_\_\_\_  
 \_\_\_\_\_

**Character.**

\_\_\_\_\_  
 \_\_\_\_\_  
 \_\_\_\_\_

*Transudates* \_\_\_\_\_  
 \_\_\_\_\_  
 \_\_\_\_\_

*Exudates* \_\_\_\_\_  
 \_\_\_\_\_  
 \_\_\_\_\_

**Transparency** \_\_\_\_\_

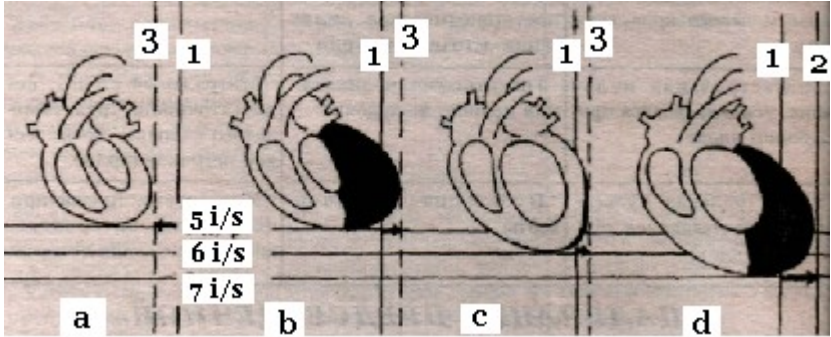
**STUDY OF THE PLEURAL FLUID**







|                             |               |
|-----------------------------|---------------|
| —                           |               |
| —                           |               |
| <b>Leucocytes</b>           |               |
| —                           |               |
| —                           |               |
| <b>Mesothelium</b>          | <b>cells</b>  |
| —                           |               |
| —                           |               |
| <b>Tumor</b>                | <b>cells.</b> |
| —                           |               |
| —                           |               |
| <b>Cytology</b>             |               |
| <b>Neutrophils</b>          |               |
| —                           |               |
| —                           |               |
| <b>Lymphocytes</b>          |               |
| —                           |               |
| —                           |               |
| <b>Eosinophils</b>          |               |
| —                           |               |
| —                           |               |
| <b>Macrophages</b>          |               |
| —                           |               |
| —                           |               |
| <b>Mesothelial</b>          | <b>cells</b>  |
| —                           |               |
| —                           |               |
| <b>Malignant</b>            | <b>cells.</b> |
| —                           |               |
| —                           |               |
| <b>Bacterioscopic study</b> |               |
| Transudates                 |               |

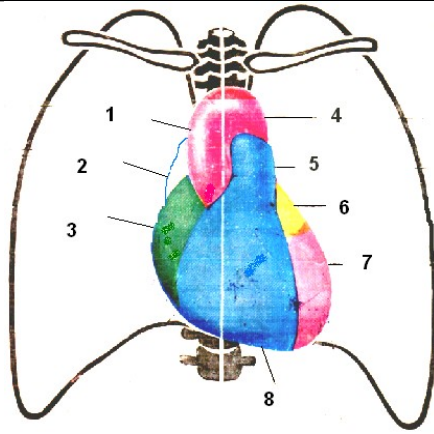


|  | Hemoptysis _____<br>_____<br>Edema _____<br>_____<br>Syncope _____<br>_____   |             |               |             |                  |  |  |                           |  |  |                        |  |  |                    |  |  |
|--|---|-------------|---------------|-------------|------------------|--|--|---------------------------|--|--|------------------------|--|--|--------------------|--|--|
| <b>GENERAL INSPECTION</b>              | Position of the patient: _____<br>_____<br>_____<br>Coloration of the skin: _____<br>_____<br>_____<br>Specific signs: _____<br><i>Facies mitrale</i> _____<br>_____<br><i>Facies Corvisarti:</i> _____<br>_____<br><i>Stokes' collar:</i> _____<br>_____<br>Edema _____<br>-<br>_____<br><table border="1" style="width: 100%; border-collapse: collapse; margin-top: 10px;"> <thead> <tr> <th style="width: 50%;"></th> <th style="width: 25%;">Cardiac edema</th> <th style="width: 25%;">Renal edema</th> </tr> </thead> <tbody> <tr> <td>Typical location</td> <td></td> <td></td> </tr> <tr> <td>Palpatory characteristics</td> <td></td> <td></td> </tr> <tr> <td>Skin in edematous area</td> <td></td> <td></td> </tr> <tr> <td>Time of appearance</td> <td></td> <td></td> </tr> </tbody> </table> |             | Cardiac edema | Renal edema | Typical location |  |  | Palpatory characteristics |  |  | Skin in edematous area |  |  | Time of appearance |  |  |
|  | Cardiac edema   | Renal edema |               |             |                  |  |  |                           |  |  |                        |  |  |                    |  |  |
| Typical location                       |   |             |               |             |                  |  |  |                           |  |  |                        |  |  |                    |  |  |
| Palpatory characteristics              |   |             |               |             |                  |  |  |                           |  |  |                        |  |  |                    |  |  |
| Skin in edematous area                 |   |             |               |             |                  |  |  |                           |  |  |                        |  |  |                    |  |  |
| Time of appearance                     |   |             |               |             |                  |  |  |                           |  |  |                        |  |  |                    |  |  |
| <b>INSPECTION OF PRECORDIAL REGION</b> | Cardiac hump _____<br>_____<br>Cardiac beat _____<br>_____<br>Apex beat _____<br>_____<br>Visible pathological pulsations _____<br>_____<br>_____   |             |               |             |                  |  |  |                           |  |  |                        |  |  |                    |  |  |

|  |   |
|--|---|
|  |   |
| <p><b>PALPATION OF PRECORDIAL REGION</b></p> | <p>Apex beat _____</p>  <p>1 - left midclavicular line; 2 – left anterior axillary line; 3 – line of displacement.<br/> <i>Sign the variants of AB location and describe their diagnostical significance:</i></p> <p>A: _____</p> <p>B: _____</p> <p>C: _____</p> <p>D: _____</p> <p>Area of the AB: _____</p> <p>Height of the AB: _____</p> |

|   | <hr/> <hr/>   |           |  |          |           |                   |  |  |   |  |  |  |  |  |                          |  |  |
|---|---|-----------|--|----------|-----------|-------------------|--|--|---|--|--|--|--|--|--------------------------|--|--|
|   | Strength of the AB: _____   |           |  |          |           |                   |  |  |   |  |  |  |  |  |                          |  |  |
|   | <hr/> <hr/>   |           |  |          |           |                   |  |  |   |  |  |  |  |  |                          |  |  |
|   | Cat's purr symptom: _____   |           |  |          |           |                   |  |  |   |  |  |  |  |  |                          |  |  |
|   | <table border="1" style="width: 100%; border-collapse: collapse; text-align: center;"> <thead> <tr> <th style="width: 30%;"></th> <th style="width: 35%;">Systolic</th> <th style="width: 35%;">Diastolic</th> </tr> </thead> <tbody> <tr> <td>Apex of the heart</td> <td></td> <td></td> </tr> <tr> <td>2<sup>nd</sup> right intercostal space</td> <td></td> <td></td> </tr> <tr> <td>2<sup>nd</sup> left intercostal space</td> <td></td> <td></td> </tr> <tr> <td>Lower right sternal edge</td> <td></td> <td></td> </tr> </tbody> </table> |           |  | Systolic | Diastolic | Apex of the heart |  |  | 2 <sup>nd</sup> right intercostal space |  |  | 2 <sup>nd</sup> left intercostal space |  |  | Lower right sternal edge |  |  |
|   | Systolic  | Diastolic |  |          |           |                   |  |  |   |  |  |  |  |  |                          |  |  |
| Apex of the heart                       |   |           |  |          |           |                   |  |  |   |  |  |  |  |  |                          |  |  |
| 2 <sup>nd</sup> right intercostal space |   |           |  |          |           |                   |  |  |   |  |  |  |  |  |                          |  |  |
| 2 <sup>nd</sup> left intercostal space  |   |           |  |          |           |                   |  |  |   |  |  |  |  |  |                          |  |  |
| Lower right sternal edge                |   |           |  |          |           |                   |  |  |   |  |  |  |  |  |                          |  |  |

|   |  |
|---|--|
| <p><b>PERCUSSION<br/>OF THE HEART</b></p> | <hr/> <hr/> <div style="text-align: center; margin: 10px 0;">  </div> <div style="margin-left: 20px;"> <p> clear pulmonary sound (lungs)</p> <p> intermediate sound (relative cardiac dullness)</p> <p> dull sound (absolute cardiac dullness)</p> </div> <p style="margin-top: 10px;">Mark the areas of different percussion sounds:</p> <p>1 - _____</p> <p>2 - _____</p> <p>3 - _____</p> |
|---|--|



Mark the structures forming the cardiac contour:

- 1 - \_\_\_\_\_
- 2 - \_\_\_\_\_
- 3 - \_\_\_\_\_
- 4 - \_\_\_\_\_
- 5 - \_\_\_\_\_
- 6 - \_\_\_\_\_
- 7 - \_\_\_\_\_
- 8 - \_\_\_\_\_

**RELATIVE  
CARDIAC  
DULLNESS**

Fill in the normal borders position:

| Borders | Location | Formed by |
|---------|----------|-----------|
| Right   |          |           |
| Upper   |          |           |
| Left    |          |           |

Dislocation of relative cardiac dullness borders:

*To the right:*

\_\_\_\_\_

\_\_\_\_\_

*To the right and upward:*

\_\_\_\_\_

\_\_\_\_\_

*To the right and upward:*

\_\_\_\_\_

\_\_\_\_\_

*To the left:*

\_\_\_\_\_

\_\_\_\_\_

*To the left and downward:*

\_\_\_\_\_

\_\_\_\_\_

*To all sides:*

\_\_\_\_\_

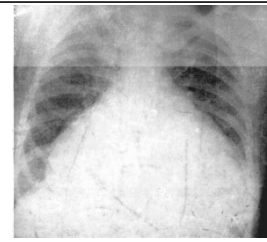
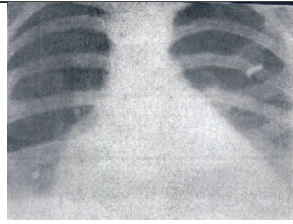
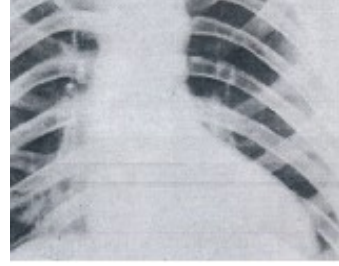
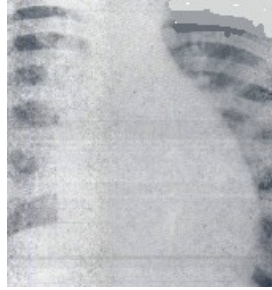
\_\_\_\_\_

Waist of the heart:

---

---

Sign the variants of cardiac contour and their diagnostical significance:



---

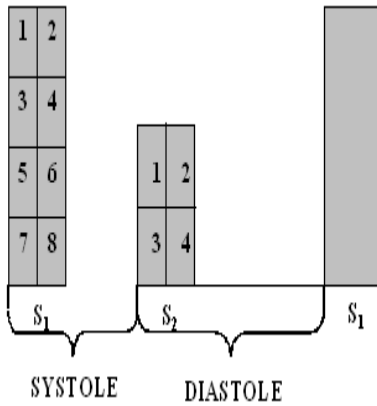
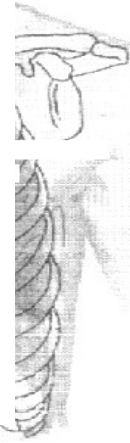---

---

**HEART  
SOUNDS**

Sign the heart valves  
projections and points of  
optimal auscultation:

- 1 - \_\_\_\_\_
- 2 - \_\_\_\_\_
- 3 - \_\_\_\_\_
- 4 - \_\_\_\_\_
- 5 - \_\_\_\_\_



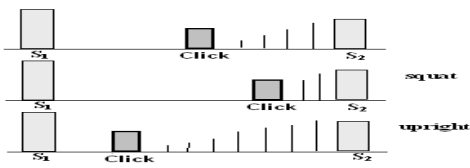
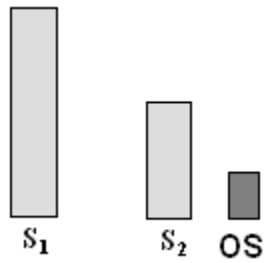
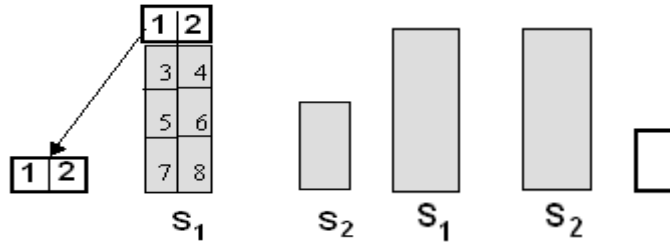
- 1 - \_\_\_\_\_
- 2 - \_\_\_\_\_
- 3 - \_\_\_\_\_
- 4 - \_\_\_\_\_
- 5 - \_\_\_\_\_
- 6 - \_\_\_\_\_
- 7 - \_\_\_\_\_
- 8 - \_\_\_\_\_

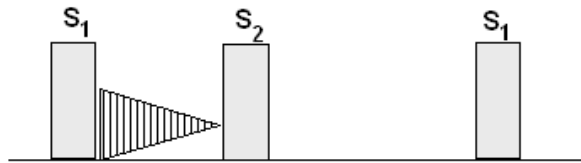
sounds:

- 1 - \_\_\_\_\_
- 2 - \_\_\_\_\_
- 3 - \_\_\_\_\_
- 4 - \_\_\_\_\_

**HEART  
MURMURS**

Sign the components of auscultation patterns with additional heart sounds and their diastolical significance:





**Holosystolic (pansystolic) murmur**

Mark the variants of heart

murmurs in relation to cardiac cycle:

---



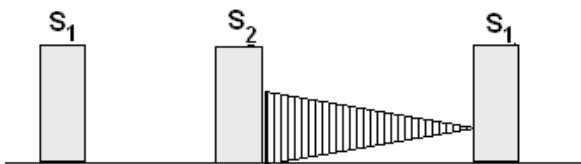
---



---



---



**Holodiastolic (pandiastolic) murmur**

---



---



---



---

Sign the diastolic significance of main variants of cardiac murmurs:

| Auscultatory areas                                 | Murmur    | Heart valvular disease |
|--|-----------|------------------------|
| Heart apex   | Systolic  | _____                  |
|  | Diastolic | _____                  |
| Second intercostal space at the right sternal edge | Systolic  | _____                  |
|  | Diastolic | _____                  |
| Second intercostal space at the left sternal edge  | Systolic  | _____                  |
|  | Diastolic | _____                  |
| Base of the xiphoid                                | Systolic  | _____                  |
|  | Diastolic | _____                  |

**ARTERIAL  
PULSE**

Fill in the table – define the characteristics that are evaluated during arterial pulse study, describe the normal findings and possible pathology:

| <b>Examination sequence</b>       | <b>Factors that cause pulse characteristics</b> | <b>Norm</b> | <b>Pathology</b> |
|-----------------------------------|---|-------------|------------------|
| <b>Symmetry</b>                   |   |             |                  |
| <b>Rhythm</b>                     |   |             |                  |
| <b>Rate (PR)</b>                  |   |             |                  |
| <b>Relation between PR and HR</b> |   |             |                  |
| <b>Tension</b>                    |   |             |                  |
| <b>Volume</b>                     |   |             |                  |
| <b>Size</b>                       |   |             |                  |
| <b>Speed</b>                      |   |             |                  |
| <b>Shape</b>                      |   |             |                  |

**BLOOD PRESSURE**

Describe the technique of blood pressure measurement, mark (with the arrows) the points of SBP and DBP detection \_\_\_\_\_

\_\_\_\_\_

\_\_\_\_\_

\_\_\_\_\_

\_\_\_\_\_

Phase I Phase II Phase III Phase IV Phase V

120 80

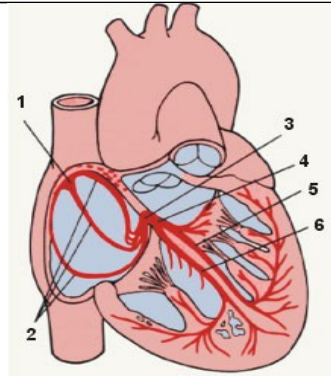
I - sounds      II - sounds and murmur      III - murmur

Finish the classification of blood pressure according to WHO (fill in the table):

| Level of blood pressure  | SBP (mmHg) | DBP (mmHg) |
|--------------------------|------------|------------|
| _____                    | < 120      | < 80       |
| _____                    | < 130      | < 85       |
| _____                    | 130-139    | 85-89      |
| <b>Hypertension:</b>     |            |            |
| <b>I grade</b> (_____)   | 140-159    | 90-99      |
| Subgroup: _____          | 140-149    | 90-94      |
| <b>II grade</b> (_____)  | 160-179    | 100-109    |
| <b>III grade</b> (_____) | ≥ 180      | ≥ 110      |
| _____                    | ≥ 140      | ≤ 90       |
| Subgroup: _____          | 140-149    | < 90       |

**Content 4.** Instrumental methods of cardiovascular system examination. ECG. **Topic 13-17.**

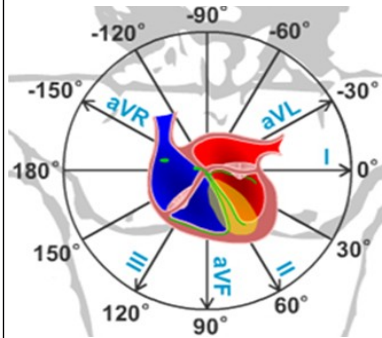
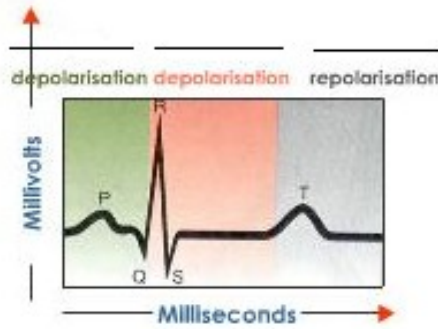
|  |   |
|--|---|
|  | ECG is _____                                    |
|  | _____   |
|  | Fill  |
|  | the parts of the conduction pathways by numbers |



1 \_\_\_\_\_ 2 \_\_\_\_\_  
 \_\_\_\_\_ 3 \_\_\_\_\_ 4 \_\_\_\_\_

5 \_\_\_\_\_  
 6 \_\_\_\_\_

\_\_\_\_\_ Automacity \_\_\_\_\_  
 \_\_\_\_\_ Conductivity \_\_\_\_\_  
 \_\_\_\_\_ Refractoriness \_\_\_\_\_  
 \_\_\_\_\_ Depolarization \_\_\_\_\_  
 \_\_\_\_\_ Repolarization \_\_\_\_\_

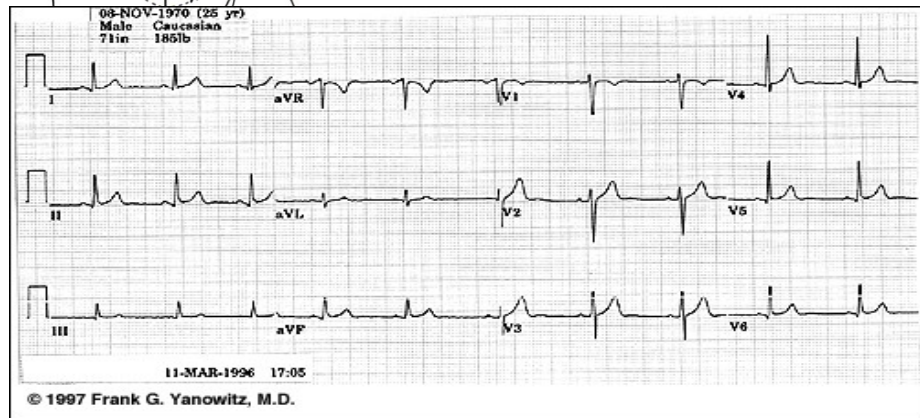
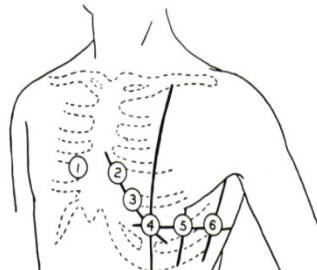


ECG Registration 12 leads:

3 \_\_\_\_\_  
 \_\_\_\_\_  
 3 \_\_\_\_\_  
 \_\_\_\_\_  
 6 \_\_\_\_\_  
 \_\_\_\_\_

V1 \_\_\_\_\_  
\_\_\_\_\_  
V2 \_\_\_\_\_  
\_\_\_\_\_  
V3 \_\_\_\_\_  
\_\_\_\_\_  
V4 \_\_\_\_\_  
\_\_\_\_\_  
V5 \_\_\_\_\_  
\_\_\_\_\_  
V6 \_\_\_\_\_  
\_\_\_\_\_

Normal ECG

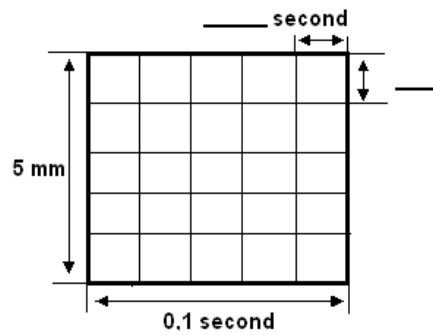
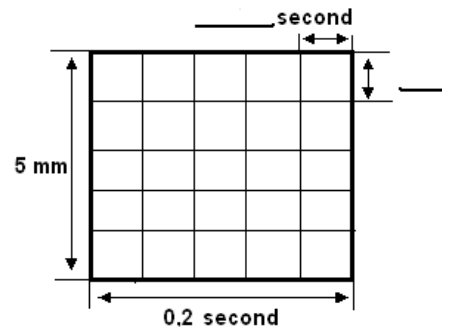
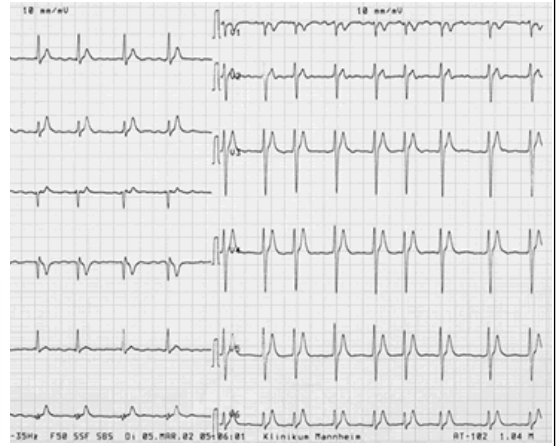
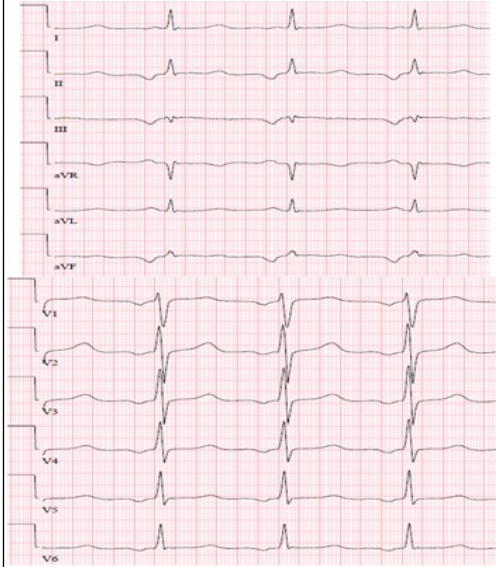


Right leads

Left leads

Speed of ECG recording \_\_\_\_\_

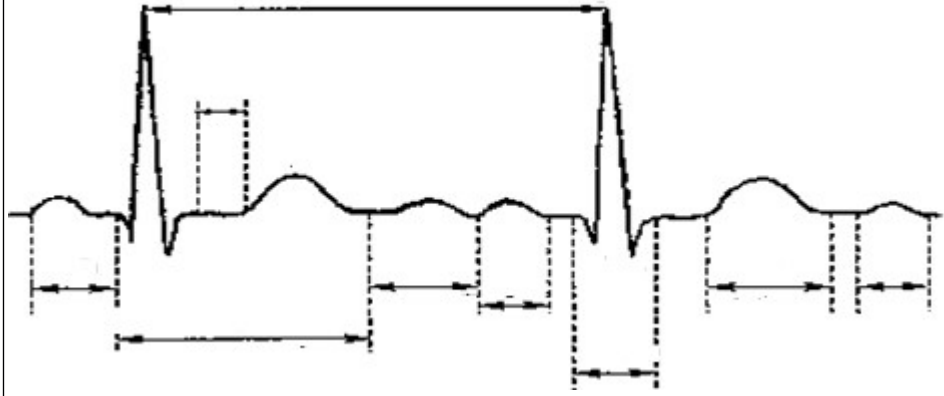
Specify the ESC recording speed \_\_\_\_\_



50 mm/sec      25 mm/sec

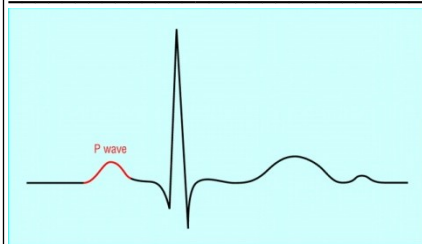
ECG

Wright down all the waves, intervals, segments on ECG



\_\_\_\_\_

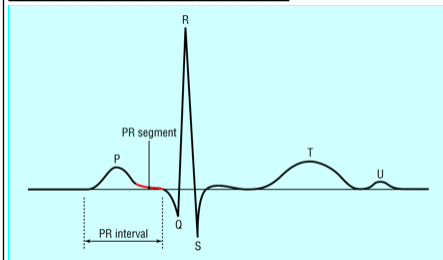
\_\_\_\_\_



P wave

\_\_\_\_\_

\_\_\_\_\_

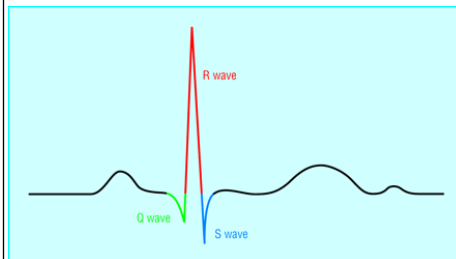


PQ segment

PQ interval

\_\_\_\_\_

\_\_\_\_\_



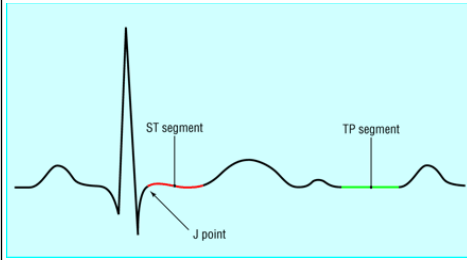
QRS complex

QRS interval

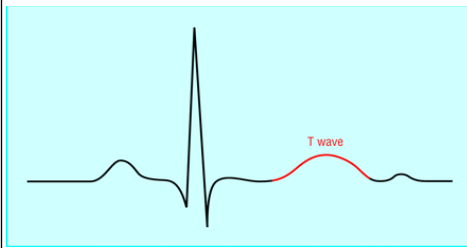
\_\_\_\_\_

\_\_\_\_\_

\_\_\_\_\_



ST segment \_\_\_\_\_

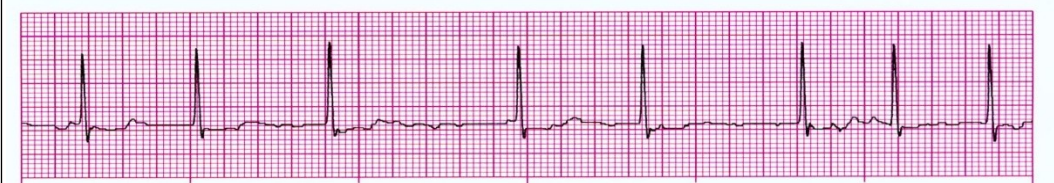
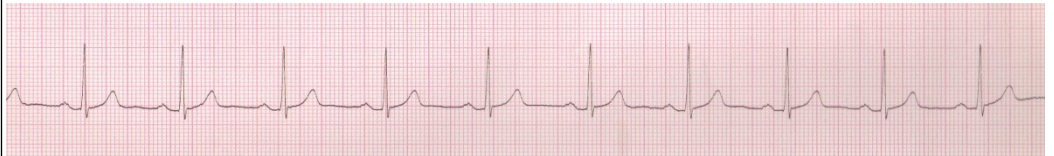

T wave \_\_\_\_\_

### Interpretation of the ECG

1. \_\_\_\_\_
2. \_\_\_\_\_
3. \_\_\_\_\_
4. \_\_\_\_\_
5. \_\_\_\_\_
6. \_\_\_\_\_
7. \_\_\_\_\_
8. \_\_\_\_\_

Determine regularity of the rhythm



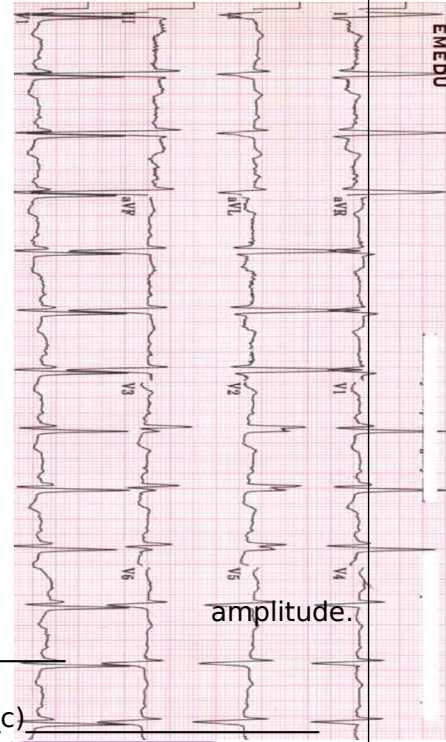
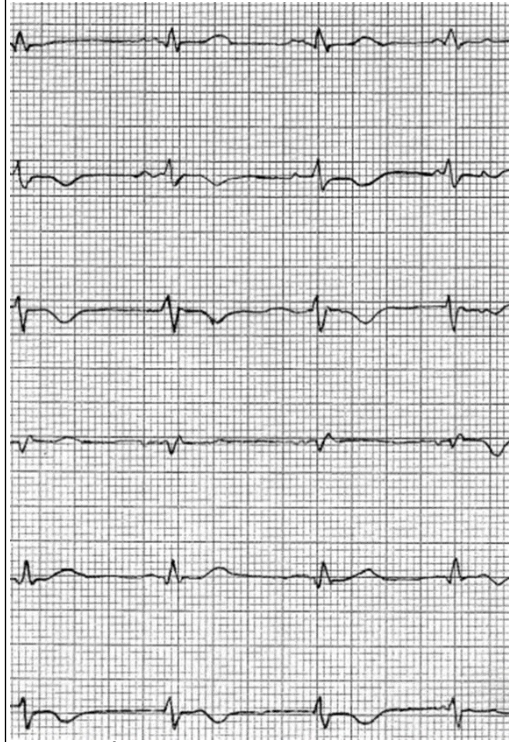
Sinus

rhythm

criteria

Nonsinus rhythm (possible types) -

Measurement of the ECG Amplitude (voltage)



Determine the left right

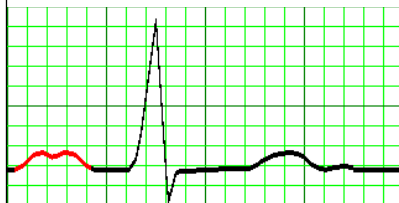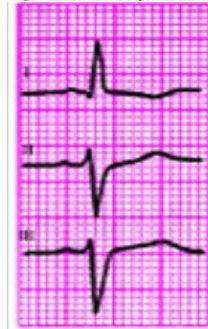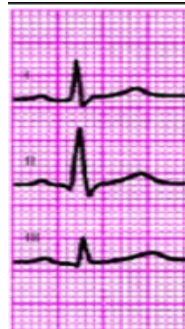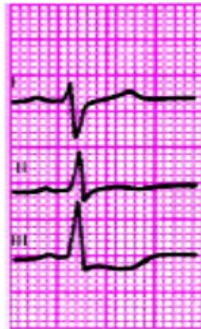
amplitude.

Specify electrical axis of the heart

a)

b)

c)



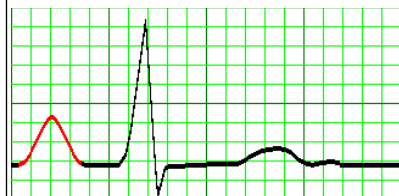
P-mitrale

\_\_\_\_\_

\_\_\_\_\_

\_\_\_\_\_

\_\_\_\_\_



P-pulmonale

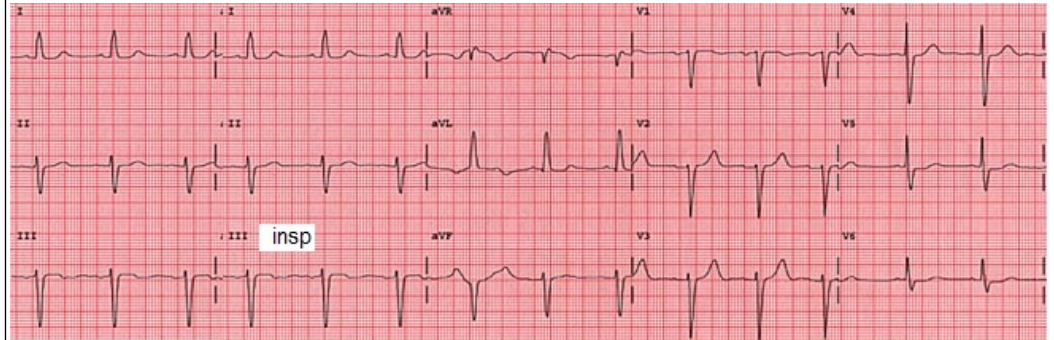
\_\_\_\_\_

\_\_\_\_\_

P-cardiale

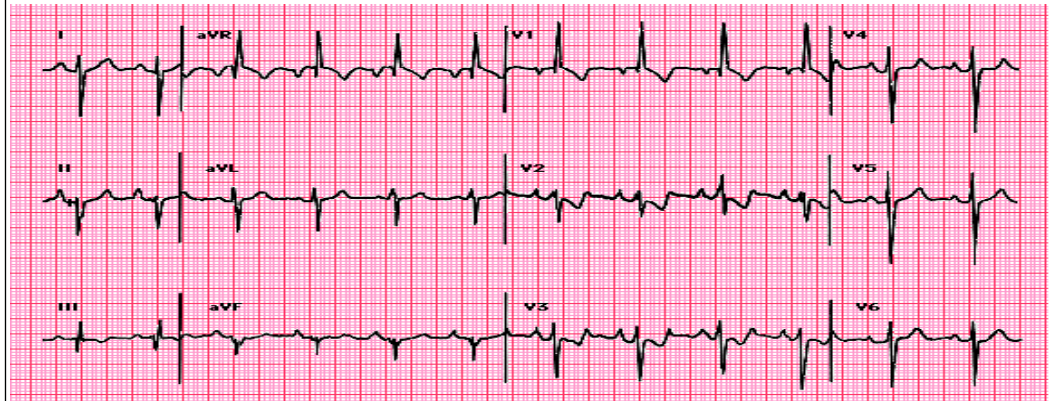
**Common signs of ventricular hypertrophy**

Left Ventricular Hypertrophy



LV Hypertrophy criteria

Right Ventricular Hypertrophy

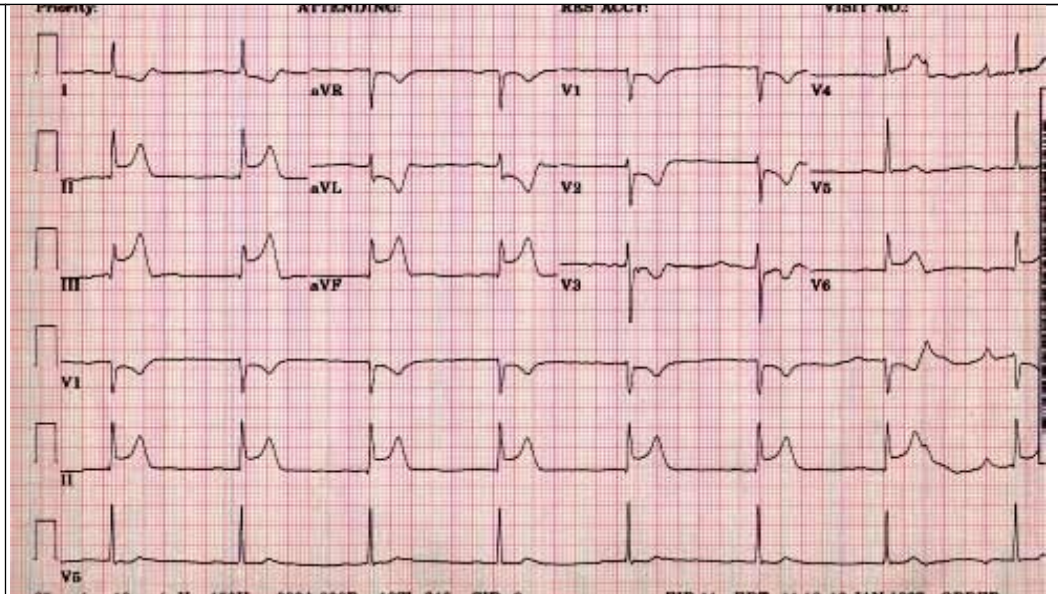


RV Hypertrophy criteria

Coronary Artery Disease

**Stages of MI:** ischemia, injury, necrosis

**Myocardial infarction:** what, when, where



Ischemia

signs \_\_\_\_\_

Injury

signs \_\_\_\_\_

Necrosis

signs \_\_\_\_\_

Stages of the myocardial infarction:

Acute \_\_\_\_\_

Evolutionary \_\_\_\_\_

Recovery \_\_\_\_\_

Stabilized \_\_\_\_\_

**Location of the myocardial infarction:**

Anterior \_\_\_\_\_

Septal \_\_\_\_\_

Posterior \_\_\_\_\_

Apical \_\_\_\_\_

Lateral \_\_\_\_\_

Diafragmal \_\_\_\_\_

**Cardiac Arrhythmias**

| Normal Sinus Rhythm  | Cardiac Arrhythmias                              |
|--|--|
| 1. The SA node is pacemaker. Heart rate: _____ beats per minute. | 1.   |
| 2. Regular cardiac rhythm:                                       | 2. _____ cardiac rhythm: the R-R intervals _____ |
| 3. The P waves originate from                                    | 3. The P waves originate from                    |
| 4. The relationship of the P wave and the QRS complex:           | 4.   |
| 5. The conduction to the ventricles is 1:1 (equal amount).       | 5.   |
| 6. Constant and normal duration of P _____                       | 6.   |

**Abnormalities of the Impulse Formation**

A. **Altered Automaticity of the Sinoatrial Node (Nomotopic Arrhythmias).**

- 1. \_\_\_\_\_
- \_\_\_\_\_ 2. \_\_\_\_\_
- \_\_\_\_\_ 3. \_\_\_\_\_
- \_\_\_\_\_ 4. \_\_\_\_\_

B. **Increased Automaticity of an Ectopic Pacemaker**

- 1. \_\_\_\_\_
- \_\_\_\_\_ 2. \_\_\_\_\_
- \_\_\_\_\_ 3. \_\_\_\_\_
- \_\_\_\_\_ 4. \_\_\_\_\_

C. **Ectopic (heterotopic) Arrhythmias caused by increased excitability of the myocardium**


- \_\_\_\_\_
- \_\_\_\_\_
- \_\_\_\_\_

II. **Abnormalities of Conduction**

- 1. \_\_\_\_\_
- \_\_\_\_\_ 2. \_\_\_\_\_
- \_\_\_\_\_ 3. \_\_\_\_\_
- \_\_\_\_\_ 4. \_\_\_\_\_
- \_\_\_\_\_ :
- \_\_\_\_\_
- \_\_\_\_\_

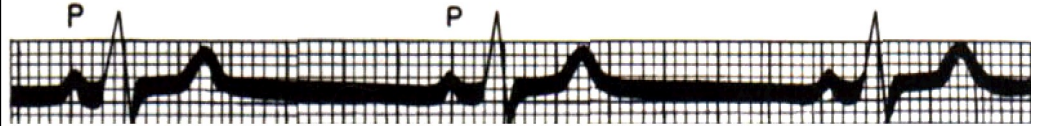
**Altered Automaticity of the Sinoatrial Node (Nomotopic Arrhythmias)**

**Sinus Tachycardia**



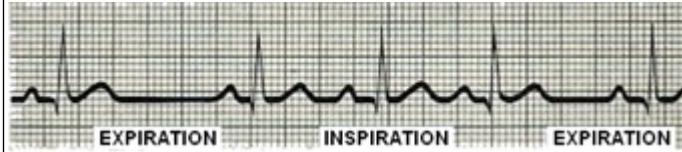
- 1. \_\_\_\_\_
- \_\_\_\_\_ 2. \_\_\_\_\_
- \_\_\_\_\_ 3. \_\_\_\_\_
- \_\_\_\_\_ 4. \_\_\_\_\_

**Sinus Bradycardia**



- 1. \_\_\_\_\_
- \_\_\_\_\_ 2. \_\_\_\_\_
- \_\_\_\_\_ 3. \_\_\_\_\_
- \_\_\_\_\_ 4. \_\_\_\_\_

**Sinus Arrhythmia**



- 1. \_\_\_\_\_
- \_\_\_\_\_ 2. \_\_\_\_\_
- \_\_\_\_\_ 3. \_\_\_\_\_
- \_\_\_\_\_ 4. \_\_\_\_\_

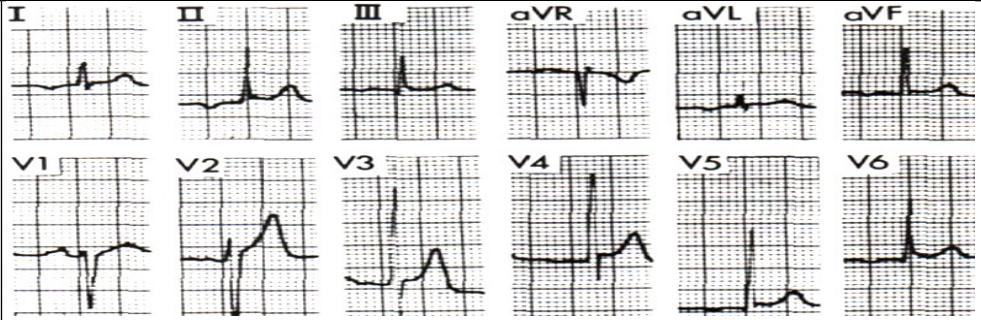
**Sick Sinus Syndrome**

- 1. \_\_\_\_\_
- \_\_\_\_\_ 2. \_\_\_\_\_
- \_\_\_\_\_ 3. \_\_\_\_\_
- \_\_\_\_\_ 4. \_\_\_\_\_

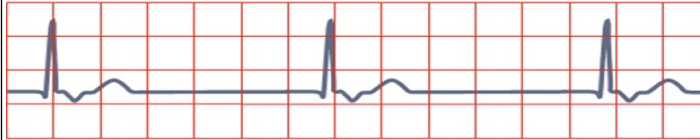
**Increased Automaticity of an Ectopic Pacemaker**

**Atrial Rhythm**

- 1. \_\_\_\_\_
- \_\_\_\_\_ 2. \_\_\_\_\_
- \_\_\_\_\_ 3. \_\_\_\_\_
- \_\_\_\_\_ 4. \_\_\_\_\_

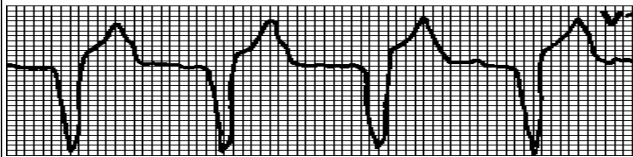


**Junctional (AV) Rhythm**



- 1. \_\_\_\_\_
- \_\_\_\_\_ 2. \_\_\_\_\_
- \_\_\_\_\_ 3. \_\_\_\_\_
- \_\_\_\_\_ 4. \_\_\_\_\_

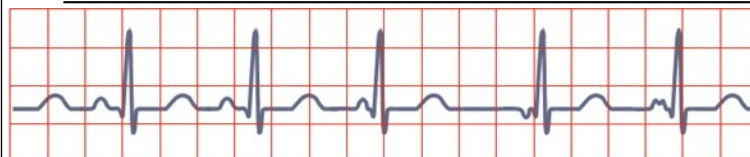
**Ventricular or Idioventricular Rhythm**



- 1. \_\_\_\_\_
- \_\_\_\_\_ 2. \_\_\_\_\_
- \_\_\_\_\_ 3. \_\_\_\_\_
- \_\_\_\_\_ 4. \_\_\_\_\_

**Wandering Pacemaker**

- 1. \_\_\_\_\_
- \_\_\_\_\_ 2. \_\_\_\_\_
- \_\_\_\_\_ 3. \_\_\_\_\_
- \_\_\_\_\_ 4. \_\_\_\_\_

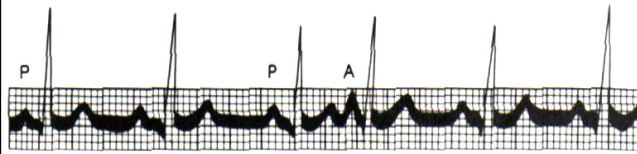


**Ectopic (heterotopic) Arrhythmias caused by increased excitability of the myocardium**



Re-entry

mechanism



**Premature Atrial Contraction**

---

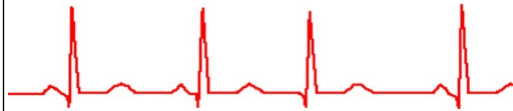---

---

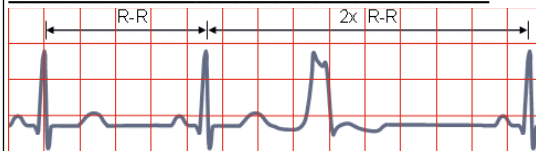
---

---

**Junctional Premature Contractions**



**Ventricular Premature Contractions**



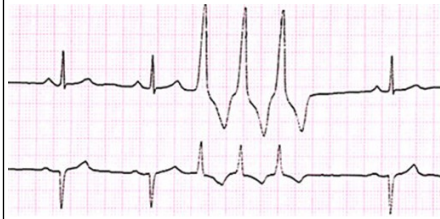**Unifocal PVC**

**Multifocal PVC**

**Ventricular bigeminy**

**Ventricular Trigeminy**

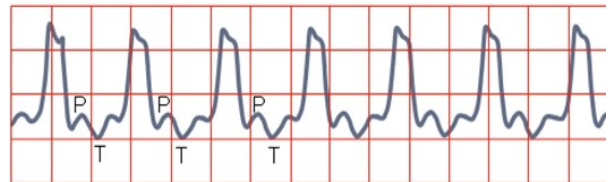
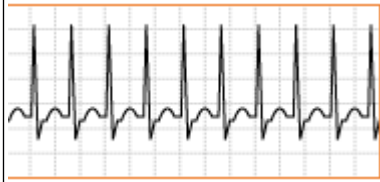
**Group Ventricular Premature Contractions**



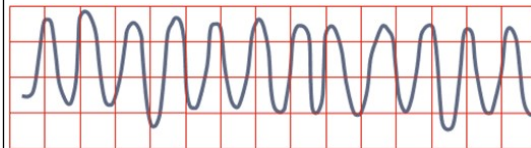
**Paroxysmal Tachycardia**

- 1 \_\_\_\_\_
- 2 \_\_\_\_\_
- 3 \_\_\_\_\_

Write down what kind of paroxysmal tachycardia is that&




**Ventricular Flutter and Fibrillation**



- 1 \_\_\_\_\_
- 2 \_\_\_\_\_
- 3 \_\_\_\_\_

**Atrial Flutter**

- 1 \_\_\_\_\_
- 2 \_\_\_\_\_
- 3 \_\_\_\_\_



**Atrial fibrillation**

- 1 \_\_\_\_\_
- 2 \_\_\_\_\_
- 3 \_\_\_\_\_



**Abnormalities of the Impulse Conduction**

**Heart block**

\_\_\_\_\_


**Incomplete block**

\_\_\_\_\_

**Complete heart block**

\_\_\_\_\_

**Sinoatrial Block**

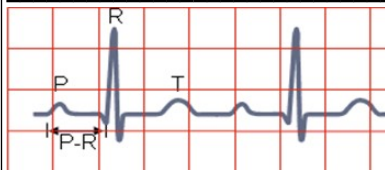

\_\_\_\_\_

**Atrioventricular Block**

\_\_\_\_\_

**The First-Degree AV Block**

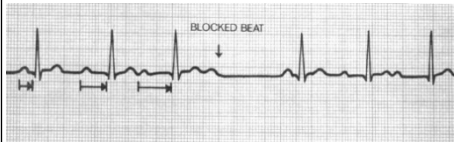


\_\_\_\_\_

**Second-Degree AV Block**

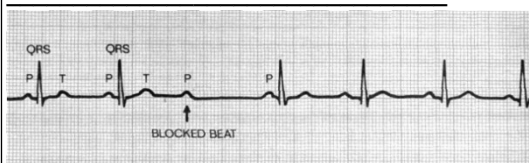
\_\_\_\_\_

Mobitz \_\_\_\_\_ (Wenchenbach) \_\_\_\_\_ type I.



\_\_\_\_\_  
\_\_\_\_\_  
\_\_\_\_\_

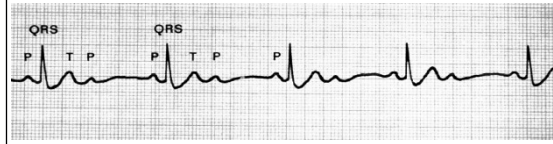
**Mobitz type II**



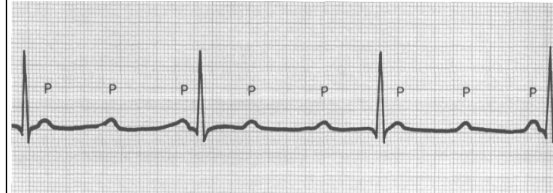
\_\_\_\_\_  
\_\_\_\_\_  
\_\_\_\_\_

Type III second-degree AV block or incomplete AV

block \_\_\_\_\_




**Third-Degree AV block** \_\_\_\_\_ or \_\_\_\_\_ complete AV block \_\_\_\_\_



**Bundle-branch block** \_\_\_\_\_

**Right BBB**

**Left BBB**



**Find out**

**Right BBB**

**And**

**Left BBB**

←

**Differences between Bundle branch block and ventricular rhythm**

---



---



---



---

**Ventricular**

**Preexcitation**

**Syndromes**

**ECG signs of CLC syndrome**

---



---

**ECG signs of WPW syndrome**

---



---

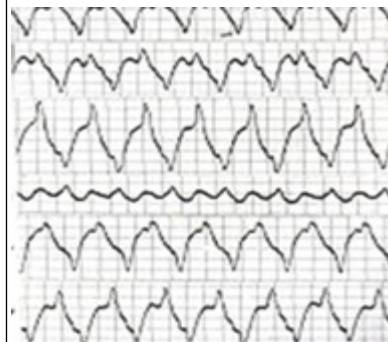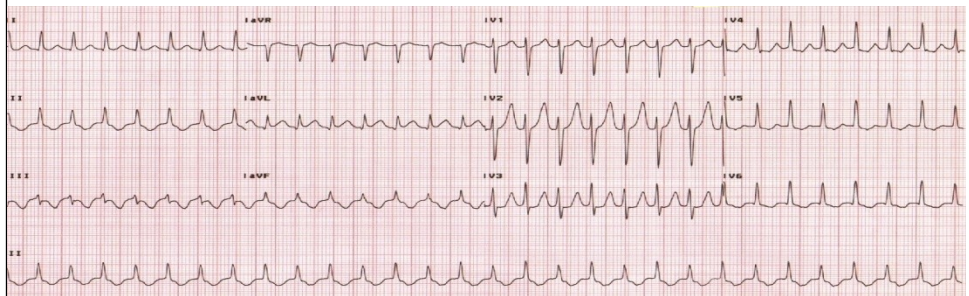
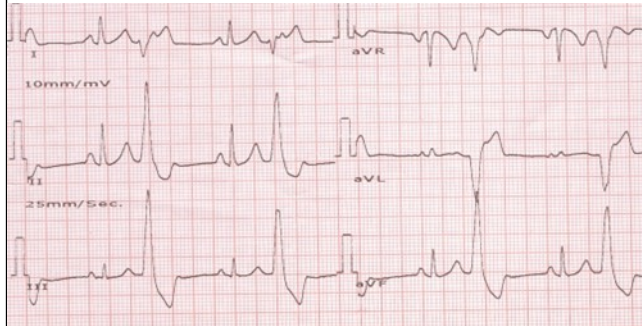
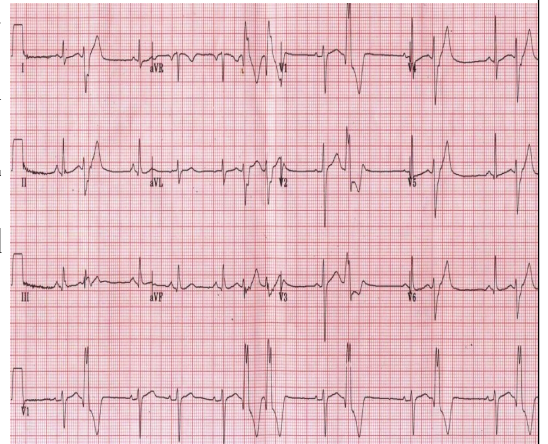
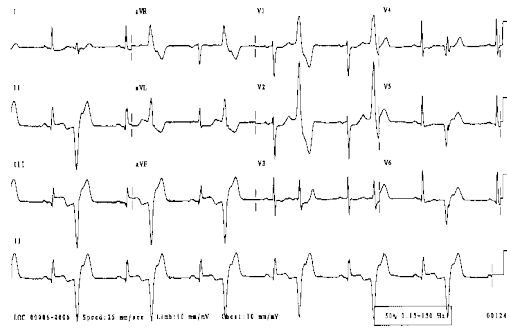
**The long QT-syndrome**

---



---

Give a conclusion about ECG

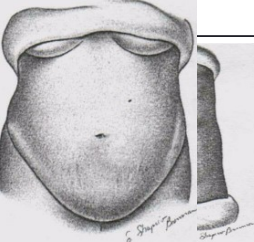


**Content 5.** Main examination methods of digestive organs and kidneys.

|   |   |   |
|---|---|---|
| <p><i>The most common complaints of the patients with the diseases of digestive organs are:</i></p> | <p>1. _____<br/>                 2. _____<br/>                 3. _____<br/>                 _____<br/>                 4. _____<br/>                 5. _____<br/>                 6. _____<br/>                 _____<br/>                 7. _____<br/>                 8. _____<br/>                 9. _____<br/>                 _____<br/>                 10. _____</p> |   |
|   | <p>Overview of approach to patients with common gastrointestinal disorders</p>  |   |
| <p><i>Site of disorder</i></p>  | <p>Common symptoms</p>  | <p>Possible physical signs</p>            |
| <p><i>Esophagus</i></p>   | <p>Dysphagia<br/>                 Odynophagia<br/>                 Heartburn, chest pain<br/>                 Hematemesis/melena</p>  |   |
| <p><i>Stomach</i></p>   |   |   |
| <p><i>Pancreas</i></p>  |   | <p>Mass<br/>                 Jaundice</p> |
| <p><i>Duodenum</i></p>  |   |   |
| <p><i>Jejunum</i></p>   |   |   |
| <p><i>Ileum</i></p>   |   |   |
| <p><i>Colon</i></p>   |   |   |
| <p><i>Rectum</i></p>  |   |   |

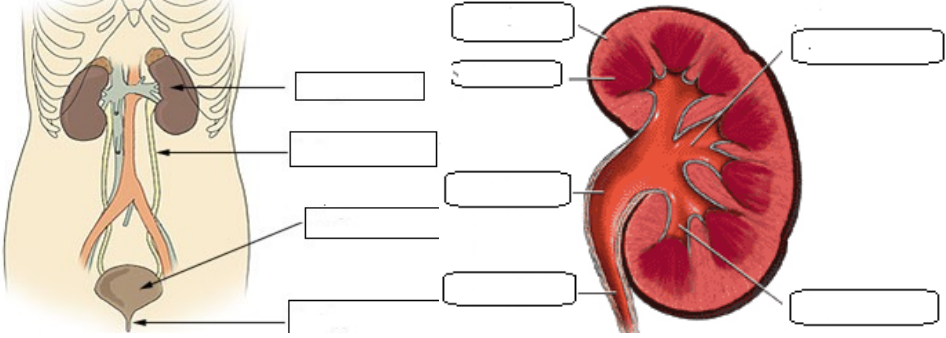
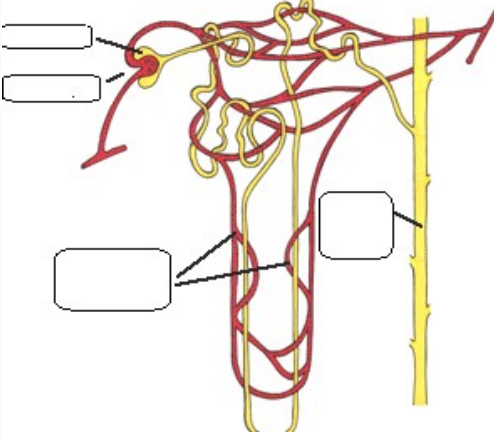
|  | Dysphagia<br><hr/> Aphagia<br><hr/> - Odynophagia<br><hr/> - Globus pharyngeus<br><hr/> - Misdirection of food<br><hr/> - Phagophobia<br><hr/> |                        |                      |                                    |
|--|--|------------------------|----------------------|------------------------------------|
|  | Dysphagia  |                        |                      |                                    |
| Process and Problem  | Timing   | Factors that Aggravate | Factors that Relieve | Associated Symptoms and Conditions |
| <b>Transfer Dysphagia,</b><br><i>due to motor disorders affecting the pharyngeal muscles</i> |  |                        |                      |                                    |
| <b>Esophageal Dysphagia Mechanical Narrowing</b>   |  |                        |                      |                                    |
| • <i>Mucosal rings and webs</i>  |  |                        |                      |                                    |
| • <i>Esophageal stricture</i>  |  |                        |                      |                                    |
| • <i>Esophageal cancer</i>   |  |                        |                      |                                    |
| <b>Motor disorders</b>   |  |                        |                      |                                    |
| Diffuse esophageal spasm   |  |                        |                      |                                    |

|             |  |  |  |  |
|-------------|--|--|--|--|
|             |  |  |  |  |
| Scleroderma |  |  |  |  |
| Achalasia   |  |  |  |  |

|   |                                   |  |  |
|---|-----------------------------------|--|--|
| <b>Regurgitation</b>  | <b>Heartburn</b>                  |  |  |
|   | <hr/> <hr/> <hr/>                 |  |  |
|   | <b>Regurgitation</b>              |  |  |
|   | <hr/> <hr/> <hr/>                 |  |  |
|   | By air<br><i>(eructation)</i>     | By food or by gas<br><i>(regurgitatio)</i>   |  |
| Cause   |                                   | Motor dysfunction of the stomach with increased formation of gas due to abnormal<br><br>or |  |
| Odour   |                                   |  |  |
| Disease   |                                   |  |  |
|   | <b>Nausea</b>                     |  |  |
|   | <hr/> <hr/> <hr/>                 |  |  |
|   | <b>Nausea can be due to</b>       |  |  |
| <b>Causes of nausea</b>   | <b>Gastric diseases</b>           | <b>Other causes</b>  |  |
|   | -                                 | -  |  |
|   | -                                 | -  |  |
|   | -                                 | -  |  |
|   | <b>Vomiting</b>                   |  |  |
| <b>Vomiting</b>   | <hr/> <hr/> <hr/>                 |  |  |
|   | <b>Vomiting etiology</b>          |  |  |
|  | Peripheral (of visceral etiology, | Hematogenic and toxic  |  |







**Topic 20-21.** Inquiry and inspection of the patients with renal diseases. Instrumental and laboratory methods of examination of urinary system.

|  |  |
|--|--|
| <p>FUNCTIONAL AND CLINICAL ANATOMY</p> | <p><b>Components of the Urinary System</b></p>  <p>Kidney anatomy</p>  |
|  | <p>The functional units of the kidney are the <i>nephrons</i></p> <p>The formation of urine :</p>  <p>1) _____</p> <p>2) _____</p> <p>3) _____</p> <p>4) _____</p> <p>_____</p> <p>_____</p> |
|  | <p>The primary urinary system functions</p> <p>_____</p> <p>_____</p> <p>_____</p> <p>_____</p>  |

|  |   |
|--|---|
|  | <hr/> <hr/> <hr/> <hr/> <hr/> <hr/> <hr/> <hr/> <hr/> <hr/> |
|--|---|

| Inquiring                        | <p>The most common complaints of the patients with renal diseases are: _____</p> <p>_____</p> <p style="text-align: center;">Pain in selected urinary diseases.</p> <table border="1" style="width: 100%; border-collapse: collapse; margin-top: 10px;"> <thead> <tr> <th style="width: 30%;">Disease</th> <th style="width: 30%;">Location<br/>Radiation</th> <th style="width: 40%;">Character</th> </tr> </thead> <tbody> <tr><td>Nephrolithiasis</td><td></td><td></td></tr> <tr><td>Pyelonephritis</td><td></td><td></td></tr> <tr><td>Renal abscess</td><td></td><td></td></tr> <tr><td>Renal infarction</td><td></td><td></td></tr> <tr><td>Nephroptosis<br/>(movable kidney)</td><td></td><td></td></tr> <tr><td>Acute<br/>glomerulonephritis</td><td></td><td></td></tr> <tr><td>Congestive kidney</td><td></td><td></td></tr> <tr><td>Cystitis</td><td></td><td></td></tr> <tr><td>Urethritis</td><td></td><td></td></tr> </tbody> </table> <p>Healthy person excretes approximately ____ liters of urine in 24 hours; urination rate is ____ times a 24 hours; ratio of daily and nightly amount of excreted urine is ____ accordingly. Urination is free and painless.</p> <p style="text-align: center;"><b>Deranged urination:</b></p> <table border="1" style="width: 100%; border-collapse: collapse; margin-top: 10px;"> <thead> <tr> <th style="width: 20%;">Term</th> <th style="width: 40%;">Definition</th> <th style="width: 40%;">Causes</th> </tr> <tr> <td style="text-align: center;">1</td> <td style="text-align: center;">2</td> <td style="text-align: center;">3</td> </tr> </thead> <tbody> <tr><td><b>Polyuria</b></td><td></td><td></td></tr> <tr><td><b>Oliguria</b></td><td></td><td></td></tr> <tr><td><b>Anuria</b></td><td></td><td></td></tr> <tr><td><b>Ishuria</b></td><td></td><td></td></tr> <tr><td><b>Nocturia</b></td><td></td><td></td></tr> <tr><td><b>Pollakiuria</b></td><td></td><td></td></tr> <tr><td><b>Ollakiuria</b></td><td></td><td></td></tr> <tr><td><b>Enuresis</b></td><td></td><td></td></tr> <tr><td><b>Dysuria</b></td><td></td><td></td></tr> <tr><td><b>Isuria</b></td><td></td><td></td></tr> <tr><td><b>Stranguria</b></td><td></td><td></td></tr> </tbody> </table> <p>Edema (varying degrees) is the common symptom, Local: edema of face (facial edema), edema around eyes (periorbital swelling), in lower extremities Generalized (_____),</p> | Disease   | Location<br>Radiation | Character | Nephrolithiasis |  |  | Pyelonephritis |  |  | Renal abscess |  |  | Renal infarction |  |  | Nephroptosis<br>(movable kidney) |  |  | Acute<br>glomerulonephritis |  |  | Congestive kidney |  |  | Cystitis |  |  | Urethritis |  |  | Term | Definition | Causes | 1 | 2 | 3 | <b>Polyuria</b> |  |  | <b>Oliguria</b> |  |  | <b>Anuria</b> |  |  | <b>Ishuria</b> |  |  | <b>Nocturia</b> |  |  | <b>Pollakiuria</b> |  |  | <b>Ollakiuria</b> |  |  | <b>Enuresis</b> |  |  | <b>Dysuria</b> |  |  | <b>Isuria</b> |  |  | <b>Stranguria</b> |  |  |
|----------------------------------|---|-----------|-----------------------|-----------|-----------------|--|--|----------------|--|--|---------------|--|--|------------------|--|--|----------------------------------|--|--|-----------------------------|--|--|-------------------|--|--|----------|--|--|------------|--|--|------|------------|--------|---|---|---|-----------------|--|--|-----------------|--|--|---------------|--|--|----------------|--|--|-----------------|--|--|--------------------|--|--|-------------------|--|--|-----------------|--|--|----------------|--|--|---------------|--|--|-------------------|--|--|
| Disease                          | Location<br>Radiation   | Character |                       |           |                 |  |  |                |  |  |               |  |  |                  |  |  |                                  |  |  |                             |  |  |                   |  |  |          |  |  |            |  |  |      |            |        |   |   |   |                 |  |  |                 |  |  |               |  |  |                |  |  |                 |  |  |                    |  |  |                   |  |  |                 |  |  |                |  |  |               |  |  |                   |  |  |
| Nephrolithiasis                  |   |           |                       |           |                 |  |  |                |  |  |               |  |  |                  |  |  |                                  |  |  |                             |  |  |                   |  |  |          |  |  |            |  |  |      |            |        |   |   |   |                 |  |  |                 |  |  |               |  |  |                |  |  |                 |  |  |                    |  |  |                   |  |  |                 |  |  |                |  |  |               |  |  |                   |  |  |
| Pyelonephritis                   |   |           |                       |           |                 |  |  |                |  |  |               |  |  |                  |  |  |                                  |  |  |                             |  |  |                   |  |  |          |  |  |            |  |  |      |            |        |   |   |   |                 |  |  |                 |  |  |               |  |  |                |  |  |                 |  |  |                    |  |  |                   |  |  |                 |  |  |                |  |  |               |  |  |                   |  |  |
| Renal abscess                    |   |           |                       |           |                 |  |  |                |  |  |               |  |  |                  |  |  |                                  |  |  |                             |  |  |                   |  |  |          |  |  |            |  |  |      |            |        |   |   |   |                 |  |  |                 |  |  |               |  |  |                |  |  |                 |  |  |                    |  |  |                   |  |  |                 |  |  |                |  |  |               |  |  |                   |  |  |
| Renal infarction                 |   |           |                       |           |                 |  |  |                |  |  |               |  |  |                  |  |  |                                  |  |  |                             |  |  |                   |  |  |          |  |  |            |  |  |      |            |        |   |   |   |                 |  |  |                 |  |  |               |  |  |                |  |  |                 |  |  |                    |  |  |                   |  |  |                 |  |  |                |  |  |               |  |  |                   |  |  |
| Nephroptosis<br>(movable kidney) |   |           |                       |           |                 |  |  |                |  |  |               |  |  |                  |  |  |                                  |  |  |                             |  |  |                   |  |  |          |  |  |            |  |  |      |            |        |   |   |   |                 |  |  |                 |  |  |               |  |  |                |  |  |                 |  |  |                    |  |  |                   |  |  |                 |  |  |                |  |  |               |  |  |                   |  |  |
| Acute<br>glomerulonephritis      |   |           |                       |           |                 |  |  |                |  |  |               |  |  |                  |  |  |                                  |  |  |                             |  |  |                   |  |  |          |  |  |            |  |  |      |            |        |   |   |   |                 |  |  |                 |  |  |               |  |  |                |  |  |                 |  |  |                    |  |  |                   |  |  |                 |  |  |                |  |  |               |  |  |                   |  |  |
| Congestive kidney                |   |           |                       |           |                 |  |  |                |  |  |               |  |  |                  |  |  |                                  |  |  |                             |  |  |                   |  |  |          |  |  |            |  |  |      |            |        |   |   |   |                 |  |  |                 |  |  |               |  |  |                |  |  |                 |  |  |                    |  |  |                   |  |  |                 |  |  |                |  |  |               |  |  |                   |  |  |
| Cystitis                         |   |           |                       |           |                 |  |  |                |  |  |               |  |  |                  |  |  |                                  |  |  |                             |  |  |                   |  |  |          |  |  |            |  |  |      |            |        |   |   |   |                 |  |  |                 |  |  |               |  |  |                |  |  |                 |  |  |                    |  |  |                   |  |  |                 |  |  |                |  |  |               |  |  |                   |  |  |
| Urethritis                       |   |           |                       |           |                 |  |  |                |  |  |               |  |  |                  |  |  |                                  |  |  |                             |  |  |                   |  |  |          |  |  |            |  |  |      |            |        |   |   |   |                 |  |  |                 |  |  |               |  |  |                |  |  |                 |  |  |                    |  |  |                   |  |  |                 |  |  |                |  |  |               |  |  |                   |  |  |
| Term                             | Definition  | Causes    |                       |           |                 |  |  |                |  |  |               |  |  |                  |  |  |                                  |  |  |                             |  |  |                   |  |  |          |  |  |            |  |  |      |            |        |   |   |   |                 |  |  |                 |  |  |               |  |  |                |  |  |                 |  |  |                    |  |  |                   |  |  |                 |  |  |                |  |  |               |  |  |                   |  |  |
| 1                                | 2   | 3         |                       |           |                 |  |  |                |  |  |               |  |  |                  |  |  |                                  |  |  |                             |  |  |                   |  |  |          |  |  |            |  |  |      |            |        |   |   |   |                 |  |  |                 |  |  |               |  |  |                |  |  |                 |  |  |                    |  |  |                   |  |  |                 |  |  |                |  |  |               |  |  |                   |  |  |
| <b>Polyuria</b>                  |   |           |                       |           |                 |  |  |                |  |  |               |  |  |                  |  |  |                                  |  |  |                             |  |  |                   |  |  |          |  |  |            |  |  |      |            |        |   |   |   |                 |  |  |                 |  |  |               |  |  |                |  |  |                 |  |  |                    |  |  |                   |  |  |                 |  |  |                |  |  |               |  |  |                   |  |  |
| <b>Oliguria</b>                  |   |           |                       |           |                 |  |  |                |  |  |               |  |  |                  |  |  |                                  |  |  |                             |  |  |                   |  |  |          |  |  |            |  |  |      |            |        |   |   |   |                 |  |  |                 |  |  |               |  |  |                |  |  |                 |  |  |                    |  |  |                   |  |  |                 |  |  |                |  |  |               |  |  |                   |  |  |
| <b>Anuria</b>                    |   |           |                       |           |                 |  |  |                |  |  |               |  |  |                  |  |  |                                  |  |  |                             |  |  |                   |  |  |          |  |  |            |  |  |      |            |        |   |   |   |                 |  |  |                 |  |  |               |  |  |                |  |  |                 |  |  |                    |  |  |                   |  |  |                 |  |  |                |  |  |               |  |  |                   |  |  |
| <b>Ishuria</b>                   |   |           |                       |           |                 |  |  |                |  |  |               |  |  |                  |  |  |                                  |  |  |                             |  |  |                   |  |  |          |  |  |            |  |  |      |            |        |   |   |   |                 |  |  |                 |  |  |               |  |  |                |  |  |                 |  |  |                    |  |  |                   |  |  |                 |  |  |                |  |  |               |  |  |                   |  |  |
| <b>Nocturia</b>                  |   |           |                       |           |                 |  |  |                |  |  |               |  |  |                  |  |  |                                  |  |  |                             |  |  |                   |  |  |          |  |  |            |  |  |      |            |        |   |   |   |                 |  |  |                 |  |  |               |  |  |                |  |  |                 |  |  |                    |  |  |                   |  |  |                 |  |  |                |  |  |               |  |  |                   |  |  |
| <b>Pollakiuria</b>               |   |           |                       |           |                 |  |  |                |  |  |               |  |  |                  |  |  |                                  |  |  |                             |  |  |                   |  |  |          |  |  |            |  |  |      |            |        |   |   |   |                 |  |  |                 |  |  |               |  |  |                |  |  |                 |  |  |                    |  |  |                   |  |  |                 |  |  |                |  |  |               |  |  |                   |  |  |
| <b>Ollakiuria</b>                |   |           |                       |           |                 |  |  |                |  |  |               |  |  |                  |  |  |                                  |  |  |                             |  |  |                   |  |  |          |  |  |            |  |  |      |            |        |   |   |   |                 |  |  |                 |  |  |               |  |  |                |  |  |                 |  |  |                    |  |  |                   |  |  |                 |  |  |                |  |  |               |  |  |                   |  |  |
| <b>Enuresis</b>                  |   |           |                       |           |                 |  |  |                |  |  |               |  |  |                  |  |  |                                  |  |  |                             |  |  |                   |  |  |          |  |  |            |  |  |      |            |        |   |   |   |                 |  |  |                 |  |  |               |  |  |                |  |  |                 |  |  |                    |  |  |                   |  |  |                 |  |  |                |  |  |               |  |  |                   |  |  |
| <b>Dysuria</b>                   |   |           |                       |           |                 |  |  |                |  |  |               |  |  |                  |  |  |                                  |  |  |                             |  |  |                   |  |  |          |  |  |            |  |  |      |            |        |   |   |   |                 |  |  |                 |  |  |               |  |  |                |  |  |                 |  |  |                    |  |  |                   |  |  |                 |  |  |                |  |  |               |  |  |                   |  |  |
| <b>Isuria</b>                    |   |           |                       |           |                 |  |  |                |  |  |               |  |  |                  |  |  |                                  |  |  |                             |  |  |                   |  |  |          |  |  |            |  |  |      |            |        |   |   |   |                 |  |  |                 |  |  |               |  |  |                |  |  |                 |  |  |                    |  |  |                   |  |  |                 |  |  |                |  |  |               |  |  |                   |  |  |
| <b>Stranguria</b>                |   |           |                       |           |                 |  |  |                |  |  |               |  |  |                  |  |  |                                  |  |  |                             |  |  |                   |  |  |          |  |  |            |  |  |      |            |        |   |   |   |                 |  |  |                 |  |  |               |  |  |                |  |  |                 |  |  |                    |  |  |                   |  |  |                 |  |  |                |  |  |               |  |  |                   |  |  |

|                           |  |
|---------------------------|--|
|                           | <p style="text-align: right;">edema of penis and scrotum</p>    |
| <p>General inspection</p> | <p><b>General condition</b> _____</p> <p><b>Consciousness</b> _____</p> <p><b>Posture</b> _____</p> <p><b>Skin</b> _____</p> <p><i>Facies nephritica</i> _____</p> <p>_____</p>  |
| <p>Palpation</p>          |  <p><i>Palpation of the kidneys according to Obraztsov-Strazhesko</i></p> <p style="text-align: right;"><i>to Obraztsov-Strazhesko</i></p> <p>Palpation of the kidneys according to S. Botkin</p> <p>Palpation is used to diagnose ptosis of the kidneys. Three degrees of the nephroptosis are differentiated</p> <p>I degree – palpable kidney (Ren palpabilis):</p> <p>_____</p> <p>_____</p> <p>II degree – movable kidney (Ren mobilis):</p> <p>_____</p> <p>_____</p>  |

|                             | <p>III degree – wandering kidney (Ren migrans)</p> <p>_____</p> <p>_____</p> <p>Palpation of the urine bladder</p> <p>In palpation you can detect following tenderness points:</p> <p>1. _____ point – the site of kidney projection, is placed in the angle between the 12th rib and the longissimus thoracis muscles;</p> <p>2. _____ point is placed at the lateral edge of the rectus abdominal muscle at the umbilicus level;</p> <p>3. _____ is placed at the intersection of linea biliaca with the vertical line passing the spina ossis pubis (pubic tubercle).</p>  |       |                        |       |             |  |  |                  |  |  |      |  |  |                    |  |  |     |  |  |                             |  |  |                |  |  |
|-----------------------------|---|-------|------------------------|-------|-------------|--|--|------------------|--|--|------|--|--|--------------------|--|--|-----|--|--|-----------------------------|--|--|----------------|--|--|
| <p>Percussion</p>           | <div style="display: flex; align-items: center;">  <div style="margin-left: 20px;"> <p>Pasternatsky's symptom.</p> <p>Pain with percussion in the costovertebral angle suggests</p> <p>_____</p> <p>_____</p> <p>_____</p> </div> </div>  |       |                        |       |             |  |  |                  |  |  |      |  |  |                    |  |  |     |  |  |                             |  |  |                |  |  |
| <p>Laboratory methods</p>   | <p>Collection of the urine _____</p> <p>_____</p> <p>_____</p> <p><b>Macroscopic study</b> includes assessment of physical properties of the urine: _____</p> <p>_____</p> <p>Clinical significance of urine color changes.</p> <table border="1" data-bbox="448 1420 1520 2078"> <thead> <tr> <th>Color</th> <th>Pathological condition</th> <th>Cause</th> </tr> </thead> <tbody> <tr> <td>Dark yellow</td> <td></td> <td></td> </tr> <tr> <td>Pale, water-like</td> <td></td> <td></td> </tr> <tr> <td>Dark</td> <td></td> <td></td> </tr> <tr> <td>Dark, almost black</td> <td></td> <td></td> </tr> <tr> <td>Red</td> <td></td> <td></td> </tr> <tr> <td>Appearance of "meat wastes"</td> <td></td> <td></td> </tr> <tr> <td>Greenish-brown</td> <td></td> <td></td> </tr> </tbody> </table> | Color | Pathological condition | Cause | Dark yellow |  |  | Pale, water-like |  |  | Dark |  |  | Dark, almost black |  |  | Red |  |  | Appearance of "meat wastes" |  |  | Greenish-brown |  |  |
| Color                       | Pathological condition  | Cause |                        |       |             |  |  |                  |  |  |      |  |  |                    |  |  |     |  |  |                             |  |  |                |  |  |
| Dark yellow                 |   |       |                        |       |             |  |  |                  |  |  |      |  |  |                    |  |  |     |  |  |                             |  |  |                |  |  |
| Pale, water-like            |   |       |                        |       |             |  |  |                  |  |  |      |  |  |                    |  |  |     |  |  |                             |  |  |                |  |  |
| Dark                        |   |       |                        |       |             |  |  |                  |  |  |      |  |  |                    |  |  |     |  |  |                             |  |  |                |  |  |
| Dark, almost black          |   |       |                        |       |             |  |  |                  |  |  |      |  |  |                    |  |  |     |  |  |                             |  |  |                |  |  |
| Red                         |   |       |                        |       |             |  |  |                  |  |  |      |  |  |                    |  |  |     |  |  |                             |  |  |                |  |  |
| Appearance of "meat wastes" |   |       |                        |       |             |  |  |                  |  |  |      |  |  |                    |  |  |     |  |  |                             |  |  |                |  |  |
| Greenish-brown              |   |       |                        |       |             |  |  |                  |  |  |      |  |  |                    |  |  |     |  |  |                             |  |  |                |  |  |

|                 |  |  |
|-----------------|--|--|
| (beer-like)     |  |  |
| Greenish-yellow |  |  |
| Whitish         |  |  |
| Milky           |  |  |

Cloudiness of the urine. \_\_\_\_\_

Smell of the urine. \_\_\_\_\_

Specific gravity of the urine is \_\_\_\_\_

**Zimnitsky's test** \_\_\_\_\_

Isothenuria is \_\_\_\_\_

Hyposthenuria is \_\_\_\_\_

**Chemical study** includes assessment of reaction of the urine (urine pH), protein, glucose, ketone bodies, and bile pigments.

Clinical significance of urine pH changes.

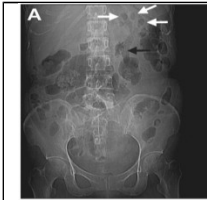
| Urine reaction                           |                        |                                  |
|--|------------------------|----------------------------------|
| Acid                                     | Neutral<br>Feebly acid | Alkaline                         |
| <i>Physiological conditions:</i>         | Norm                   | <i>Physiological conditions:</i> |
| <i>Pathological conditions: diabetes</i> |                        | <i>Pathological conditions:</i>  |

Proteinuria \_\_\_\_\_

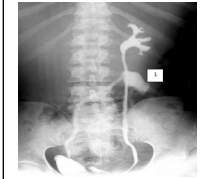Selective proteinuria

Depend on protein- amount in the urine, \_\_\_\_\_ -- 30-300 mg/24h, and proteinuria ( \_\_\_\_\_ ) – more than 300 mg/24h are distinguished.

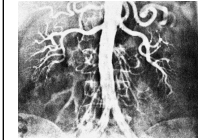
|                             |  |
|-----------------------------|--|
|                             | <p>Functional proteinuria _____</p> <p>_____</p> <p>Organic proteinuria _____</p> <p>_____</p> <p>Glycosuria _____</p> <p>_____</p> <p>Ketone bodies (acetone, acetoacetic and <math>\beta</math>2-oxybutyric acid) _____</p> <p>_____</p> <p>Bilirubin. _____</p> <p>_____</p> <p>Urobilinoids: _____</p> <p>_____</p> <p><b>Macroscopic study</b></p> <p>The presence of erythrocytes in the urine is called _____.</p> <p>Microhaematuria _____</p> <p>_____</p> <p>Macrohaematuria _____</p> <p>_____</p> <p>Leucocyturia _____</p> <p>_____</p> <p>Epithelium cells</p> <p>Tubular (renal) epithelium cells _____</p> <p>_____</p> <p>Squamous epithelium cells _____</p> <p>_____</p> <p>Cylinders (casts). _____</p> <p>_____</p> <p>Nechiporenko's method allows counting formed elements in 1 ml of urine, normally:</p> <p>o Leucocytes – _____;</p> <p>o Erythrocytes – _____;</p> <p>o Casts – _____.</p> <p>Crystals. _____</p> <p>_____</p> <p>Mucus. _____</p> <p><b>Bacterioscopic study</b></p> <p>Bacteriuria _____</p> <p>_____</p> |
| <p>Instrumental methods</p> | <p><b>Plain radiography of the urinary tract</b> _____</p> <p>_____</p> <p>_____</p>   |



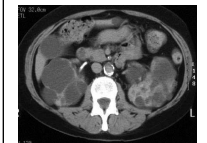Excretion urography (synonyms: intravenous pyelography; IVP; IVU) \_\_\_\_\_



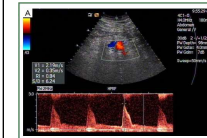Retrograde pyelography/ureterography \_\_\_\_\_



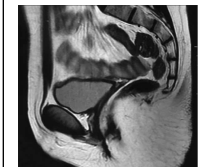
Renal arteriography. \_\_\_\_\_



Computed tomography (CT scanning) \_\_\_\_\_



Ultrasonography. \_\_\_\_\_



Nuclear renal imaging \_\_\_\_\_