

Wiadomości Lekarskie

Medical Advances

Official journal of the Polish Medical Association
Wiadomości Lekarskie has been published since 1928



Volume LXXVII, Issue 10, OCTOBER 2024

ISSN 0043-5147

E-ISSN 2719-342X

Wiadomości Lekarskie

Medical Advances

Official journal of the Polish Medical Association

Wiadomości Lekarskie has been published since 1928



Volume LXXVII, Issue 10, OCTOBER 2024



Memory of
dr Władysław
Biegański

Wiadomości Lekarskie Medical Advances is abstracted and indexed in:
PUBMED/MEDLINE, SCOPUS, EMBASE, INDEX COPERNICUS,
MINISTRY OF SCIENCE AND HIGHER EDUCATION, POLISH MEDICAL BIBLIOGRAPHY

Copyright: © ALUNA Publishing

Articles published on-line and available in open access are published under Creative Common Attribution-Non Commercial-No Derivatives 4.0 International (CC BY-NC-ND 4.0) allowing to download articles and share them with others as long as they credit the authors and the publisher, but without permission to change them in any way or use them commercially.

Distribution and Subscriptions:

Bartosz Guterman prenumerata@wydawnictwo-aluna.pl

Graphic design / production:

Grzegorz Sztank

fajne.work

Publisher:

ALUNA Publishing
29 Przesmyckiego st.,
05-510 Konstancin – Jeziorna, Poland
www.wydawnictwo-aluna.pl
www.wiadomoscilekarskie.pl
www.wiadlek.pl

Wiadomości Lekarskie

Medical Advances

Official journal of the Polish Medical Association
Wiadomości Lekarskie has been published since 1928



Editorial Team

Editor in-Chief:

Prof. Paweł Kalinski – Buffalo, USA

Honorary Editor in-Chief:

Prof. Władysław Pierzchała – Katowice, Poland

Deputy Editor in-Chief:

Prof. Waldemar Kostewicz – Warsaw, Poland
President Polish Medical Association

Statistical Editor:

Dr Lesia Rudenko – Konstancin – Jeziorna, Poland

Managing Editor:

Agnieszka Rosa – amarosa@wp.pl

International Editorial Office:

Nina Radchenko (editor) – n.radchenko@wydawnictwo-aluna.pl

International Editorial Board – in-Chief:

Marek Rudnicki Chicago, USA

International Editorial Board – Members:

Stalbek M. Akhunbaev	Bishkek, Kyrgyzstan	Jerzy Robert Ładny	Białystok, Poland
Kris Bankiewicz	San Francisco, USA	Stella Nowicki	Memphis, USA
Christopher Bara	Hannover, Germany	Alfred Patyk	Gottingen, Germany
Krzysztof Bielecki	Warsaw, Poland	Palmira Petrova	Yakutsk, Russia
Zana Bumbuliene	Vilnius, Lithuania	Waldemar Priebe	Houston, USA
Stanislav Czudek	Ostrava, Czech Republic	Maria Siemionow	Chicago, USA
Mowafaq Muhammad Ghareeb	Baghdad, Iraq	Aleksander Sieroń	Katowice, Poland
Nataliya Gutorova	Kharkiv, Ukraine	Vladyslav Smiiianov	Sumy, Ukraine
Marek Hartleb	Katowice, Poland	Tomasz Szczepański	Katowice, Poland
Roman Jaeschke	Hamilton, Canada	Andrzej Witek	Katowice, Poland
Andrzej Jakubowiak	Chicago, USA	Jerzy Woy-Wojciechowski	Warsaw, Poland
Peter Konturek	Saalfeld, Germany	Zbigniew Wszolek	Jacksonville, USA
George Krol	New York, USA	Vyacheslav Zhdan	Poltava, Ukraine

Olga M. Gorbatyuk, Dmitry S. Soleiko

Clinical and diagnostic features of Crohn's disease in young children 2015

Sukayna Jabbar Mushattat, Jabbar Abadi ALAridi, Salim Kadhim

Effect of some immunological markers on the level of anti- mullerian hormone (AMH) in women infected with *Toxoplasma gondii* 2020

Ammar Abdul Aziz Alibeg, Tuqa Salim Hussein

In silico study of new isatin- sulfonamide derivatives as carbonic anhydrase inhibitors 2027

Mushtaq Ibraheem, Saif Abdulrazaq

Molecular study of FAM20A gene and biochemical analysis for amelogenesis imperfecta patients 2033

Iyudmyla Rusyn, Oleksandr Pulyk, Myroslava Hyryavets

Correction of dysmenorrhea in teenage girls with autonomic dysfunction syndrome 2043

REVIEW ARTICLES

Kyryl G. Krymovskyy, Zinaida E. Zhehulovych, Kateryna V. Storozhenko, Yuri I. Babaskin

Nowadays and the future of the 3d digital technologies in modern orthodontics 2047

Aleksandra Kucharska-Lusina

Individual and molecular risk factors for the development of rheumatoid arthritis 2057

Myroslava V. Bielova, Viktoria I. Fridmanska, Viktoriia Yu. Svyshcho, Lesia V. Leshanych

Legal regulation of biomedical research: key principles and their implementation 2070

Roman M. Fridmansky, Andrianna Yu. Badyda, Oleksandr O. Pifko, Ihor Yu. Dir

Human rights in the context of transhumanist medicine: ethical and legal aspects 2077

Jerzy Głuszek

Novel pharmacologic approaches in resistant hypertension 2083

Tetiana Danylova, Svitlana Storozhuk, Nataliia Kryvda, Iryna Matviienko

For whom the bell tolls: The fear of death and the ways to become less afraid of it 2090

Anatolii Hrynzovskyi, Serhii V. Bielai, Vladimir S. Vasishev, Vladimir I. Pasichnik, Aleksandr M. Kernickyi, Mykola I. Tovma

Psychosocial aspects of rehabilitation of the National guard of Ukraine soldiers injured in combat 2098

CASE STUDIES

Agil N. Huseynov, Vladislav A. Malanchuk, Vyacheslav P. Maistrenko, Mykhailo S. Myroshnychenko, Olena V. Markovska, Andrii A. Boiko, Oleksii I. Hryniuk

Mine-explosive trauma of the maxillofacial region: current state of the problem and description of a case from practice 2104

Mine-explosive trauma of the maxillofacial region: current state of the problem and description of a case from practice

Agil N. Huseynov¹, Vladislav A. Malanchuk¹, Vyacheslav P. Maistrenko², Mykhailo S. Myroshnychenko³, Olena V. Markovska³, Andrii A. Boiko¹, Oleksii I. Hryniuk¹

¹BOHOMOLETS NATIONAL MEDICAL UNIVERSITY, KIEV, UKRAINE

²IRPIN MILITARY HOSPITAL, IRPIN, UKRAINE

³KHARKIV NATIONAL MEDICAL UNIVERSITY, KHARKIV, UKRAINE

ABSTRACT

Military conflicts, terrorist attacks and wars around the world pose a wide range of questions to the medical community about providing medical care to military personnel and civilians with mine-explosive trauma, which is characterized by simultaneous damage of various anatomical areas, including the maxillofacial region. The purpose of this work was to describe a case from practice of treating a patient with a mine-explosive trauma, which manifested by a fracture of the right zygomatic-orbital complex and the upper jaw on the right. Using own case from practice, the authors showed that the treatment of patients with mine-explosive trauma of the maxillofacial region is long-term, multi-stage and should take place in a specialized hospital with the involvement of a team of multidisciplinary specialists.

KEY WORDS: mine-explosive trauma, maxillofacial region, case from practice

Wiad Lek. 2024;77(9):2104-2110. doi: 10.36740/WLek/196165 DOI

INTRODUCTION

The high intensity of military conflicts and terrorist attacks in the world, the full-scale war in Ukraine have led to a significant increase in the frequency of mine-explosive traumas among military personnel and civilians [1]. Mine-explosive traumas are a common cause of loss of work ability and disability, characterized by high mortality. The frequency of losses during combat operations as a result of mine-explosive traumas reaches 25% [2].

Mine-explosive traumas occur as a result of a one-time action on the human body of damaging factors of heterogeneous characteristics caused by a mine-explosive device (shock wave, gas flame jet, ammunition fragments, toxic products of explosion and combustion, etc.) [3]. Damage caused by a mine-explosive trauma depends on the person location at the time of the explosion, the type of explosive device and its strength, the presence or absence of protective equipment [4]. Mine-explosive traumas are characterized by simultaneous injury of several organs and systems (two or three anatomical areas or more) [5]. The most common locations of injuries in mine-explosive traumas, according to various scientists, are the extremities, head

and neck, chest, abdomen, etc. [6, 7]. This category of patients is characterized by the frequent development of traumatic shock and multiple organ failure [2]. Victims of mine-explosive traumas require immediate and highly qualified medical care followed by a range of rehabilitation measures.

AIM

The purpose of this work was to describe a case from practice of treating a patient with a mine-explosive trauma, which manifested by a fracture of the right zygomatic-orbital complex and the upper jaw on the right.

CASE REPORT

Patient M., 35 years old, was admitted to the hospital on June 14, 2023. After a comprehensive examination, a comminuted fracture of the right zygomatic-orbital complex and the upper jaw on the right was diagnosed (Fig. 1). During hospitalization, the patient signed a written consent that his photographs and medical

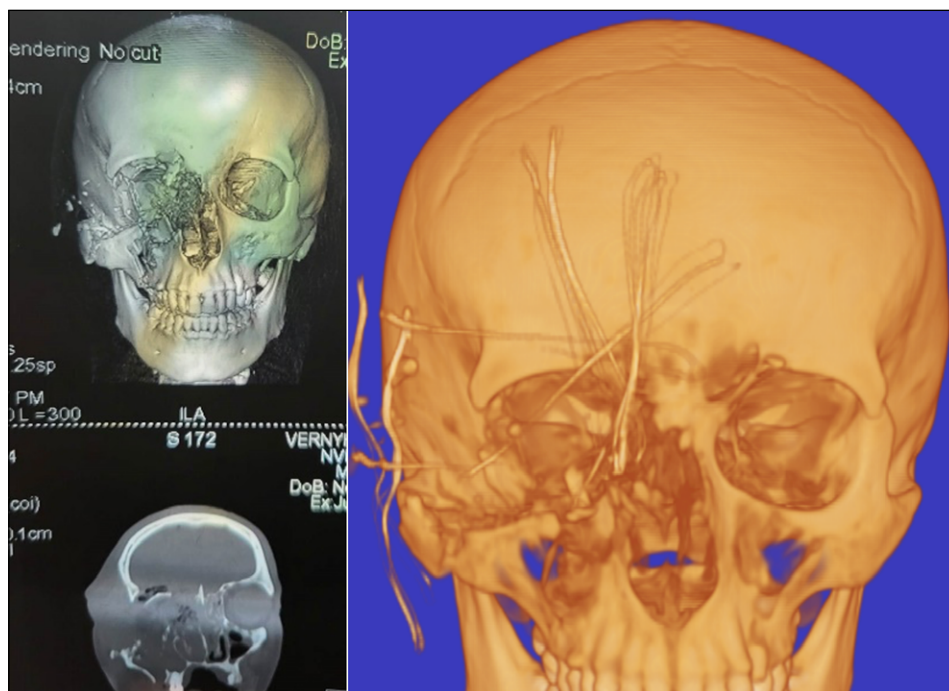


Fig. 1. 3D computed tomography of the skull of patient during hospitalization on June 14, 2023.

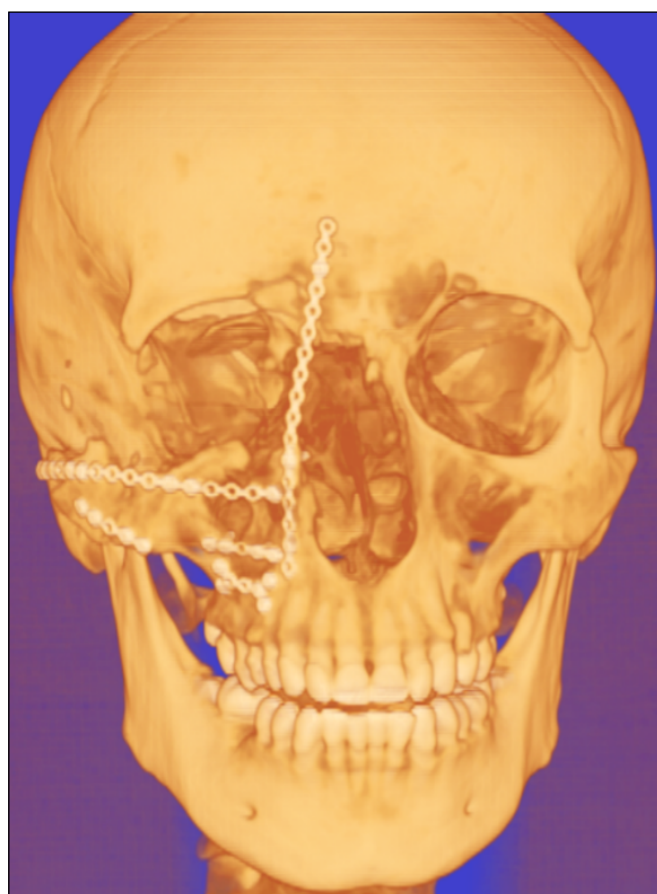


Fig. 2. 3D computed tomography of the skull of patient after surgery on June 16, 2023.

records would be analyzed and published as an article in a journal. It is known from the anamnesis that the patient received a mine-explosive trauma on June 6, 2023. At the previous stages of providing medical care

to the patient, primary surgical treatment of the wound and removal of the right eyeball were performed. On June 15, 2023, a conference of doctors was held with the participation of a neurosurgeon, a neuropathologist, an ophthalmologist, an otorhinolaryngologist, and a maxillofacial surgeon and the tactics of treatment were decided.

On June 16, 2023, the patient underwent surgery. Wound revision and reposition of bone fragments were made using intraoral and external approaches through the wound. Using microplates, metal osteosynthesis of the right zygomatic-orbital complex and the upper jaw on the right was performed in the areas of the zygomatic arch, nasolabial buttress, and anterior wall of the maxillary sinus (Fig. 2). During the revision of the wound, tissue fragments were obtained, which were subsequently subjected to morphological examination. During the survey microscopy of the latter, fragments of connective, muscle and bone tissues with pronounced dystrophic-necrotic changes, signs of circulatory disorders, and focal moderately pronounced polymorphic cellular infiltration were determined (Fig. 3). The latter was mainly represented by neutrophilic leukocytes, macrophages and lymphocytes.

Taking into account the presence of massive bone defects in patient, the method of electrical stimulation was used to activate the processes of reparative osteogenesis, the effectiveness of which was proven by us in the previously conducted morphological study of the experimental material [8, 9]. It was used an electrode for electrical stimulation, connected to the negative pole of a battery with a diameter of 8×2.5 mm (Fig. 4). The electrode was attached to the microplate, which fixed the fracture

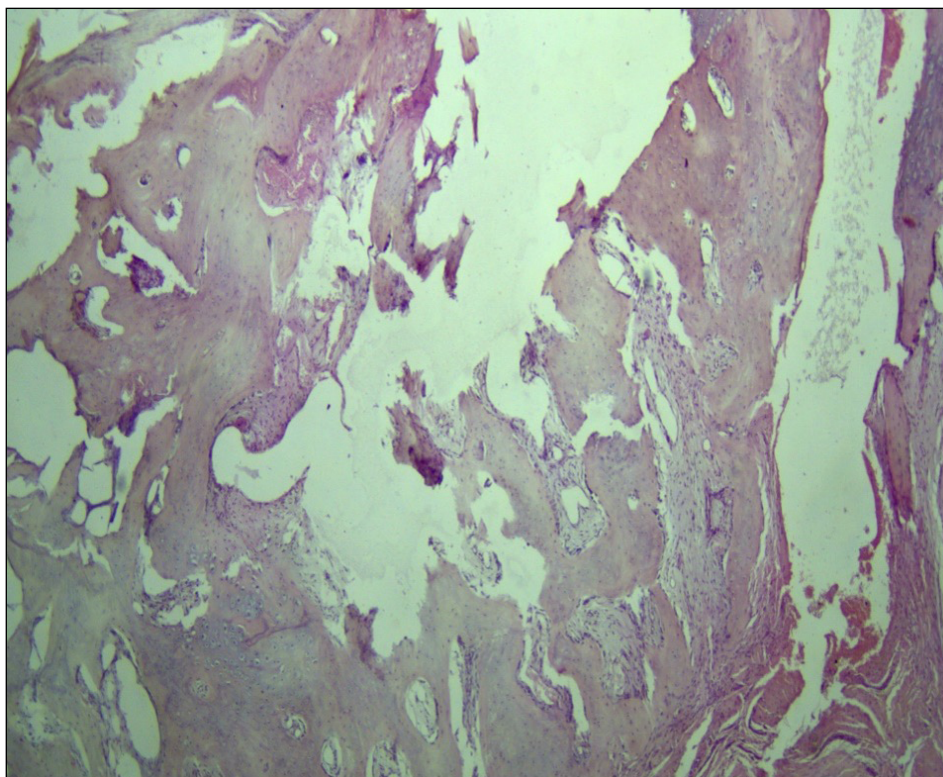


Fig. 3. Bone, muscle and connective tissue fragments with alterative, hemodynamic and inflammatory changes. Hematoxylin and eosin staining, $\times 40$.



Fig. 4. Appearance of the electrode that was used for electrical stimulation.

fragments. The battery was introduced into the oral cavity and fixed with a vicryl to the mucous membrane of the transitional fold of the upper jaw. The duration of the electrical stimulation procedure was 30 days, after which the device was removed under local anesthesia.

On June 28, 2023, the patient was discharged from the hospital for further conservative treatment in an

outpatient setting. On September 5, 2023, patient M. was re-hospitalized to the hospital with the diagnosis "Facial deformation in the area of the right zygomatic-orbital complex, bone defect of the outer edge and bottom of the orbit on the right". The patient underwent reconstruction of the orbit with the help of an individually made implant (Fig. 5-7), which was developed by

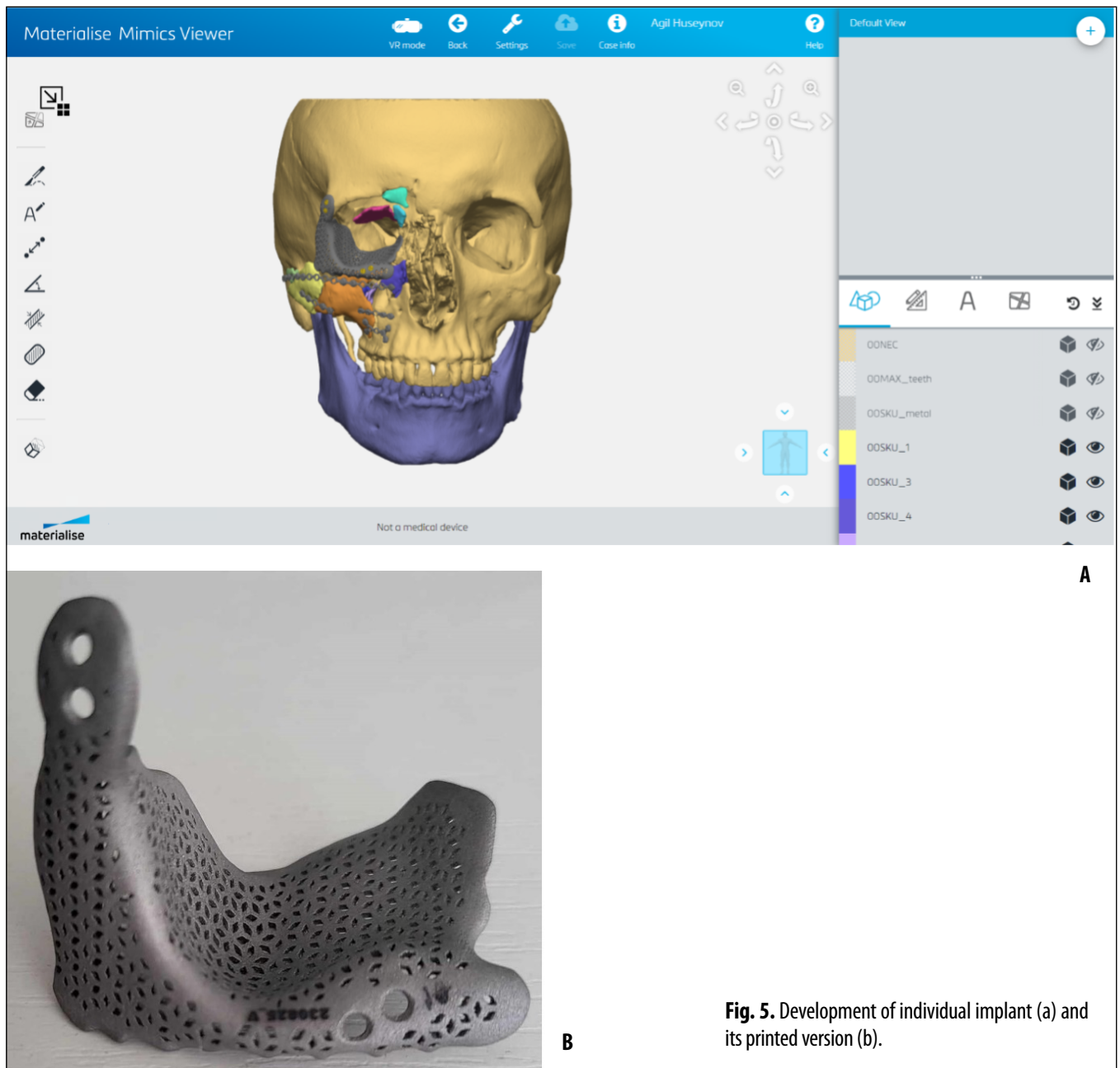


Fig. 5. Development of individual implant (a) and its printed version (b).

the engineers of the MATERIALISE company (Belgium) using the Materialise Mimics Viewer program and printed by the 3D MetalTech company (Ukraine) (Fig. 5). The microplate was removed from the nasolabial suture area before installing the implant, during which small tissue fragments were obtained and sent to the morphological study. During the morphological study of the latter, connective and lamellar bone tissue, which are the formed regenerate components, were determined (Fig. 8). The results of the morphological study of clinical material proved the effectiveness of the electrical stimulation method of the reparative osteogenesis processes, which coincides with the results of other scientists and the morphological study of the experimental material conducted by us earlier [8-11].

On December 11, 2023, patient underwent the next stage of surgical treatment, during which a bed for an eye prosthesis was formed. On January 10, 2024, ophthalmologists performed a prosthetic procedure on patient's right eye, after which he was discharged from the hospital.

After mine-explosive trauma, physical therapy is extremely important, which contributes to the physical and psychological recovery of the person and the return to a full-fledged life [12].

CONCLUSIONS

Military conflicts, terrorist attacks and wars around the world pose a wide range of questions to the medical

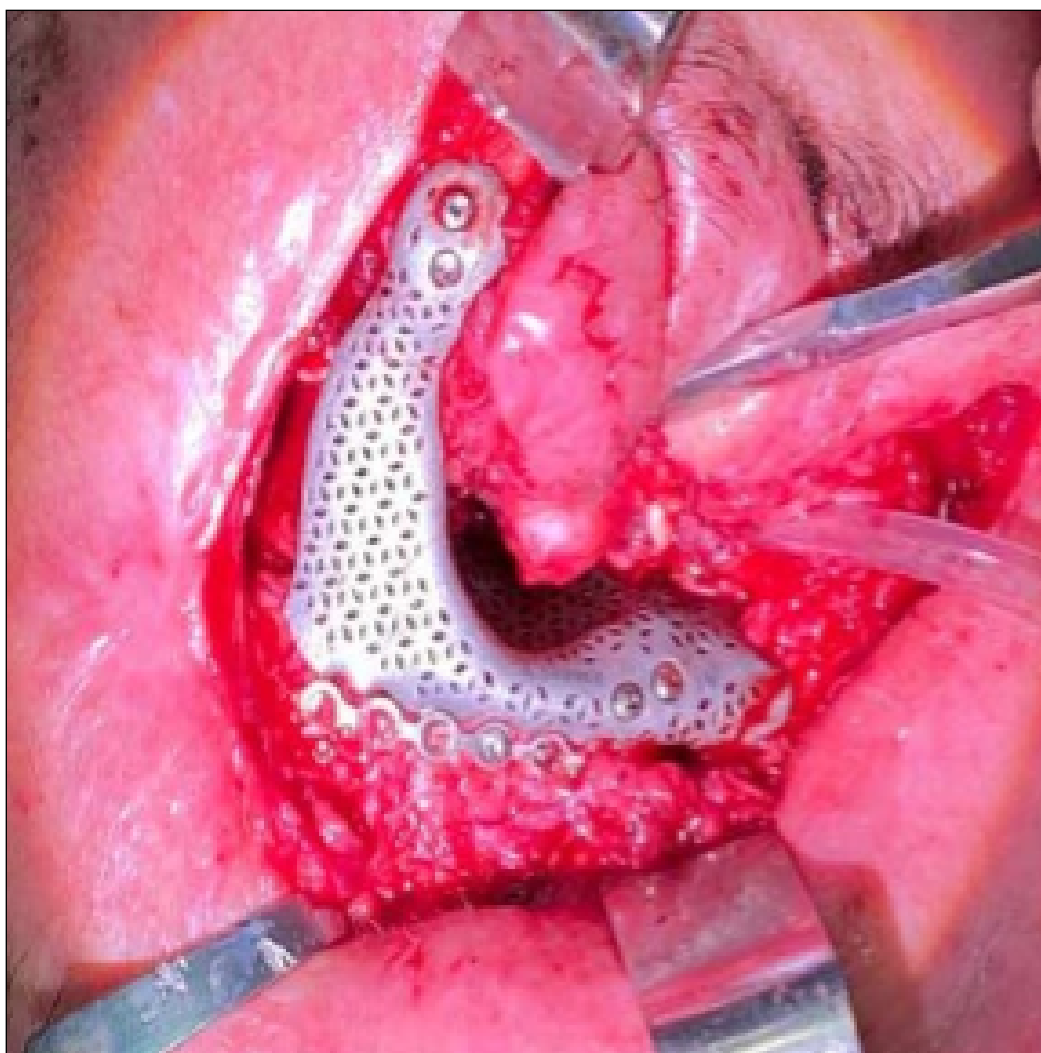


Fig. 6. View of the installed implant during the operation.

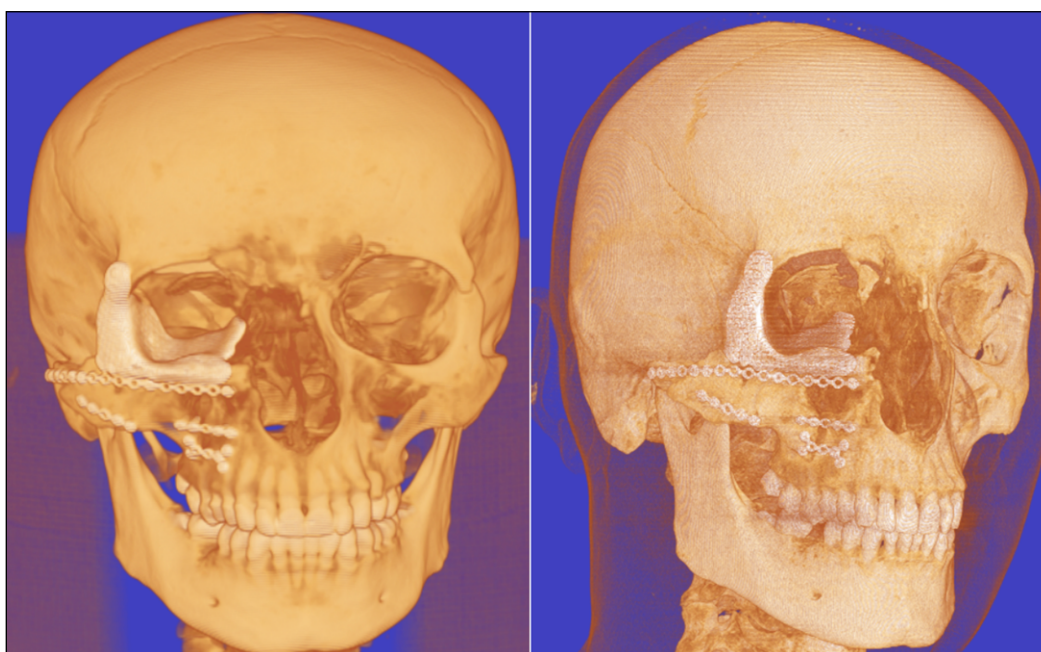


Fig. 7. 3D computered tomography of the skull of patient after the reconstruction of the orbit bottom using an individual implant.

community about providing medical care to military personnel and civilians with mine-explosive trauma, which is characterized by simultaneous damage of

various anatomical areas, including the maxillofacial region. Using own case from practice, the authors showed that the treatment of patients with mine-ex-

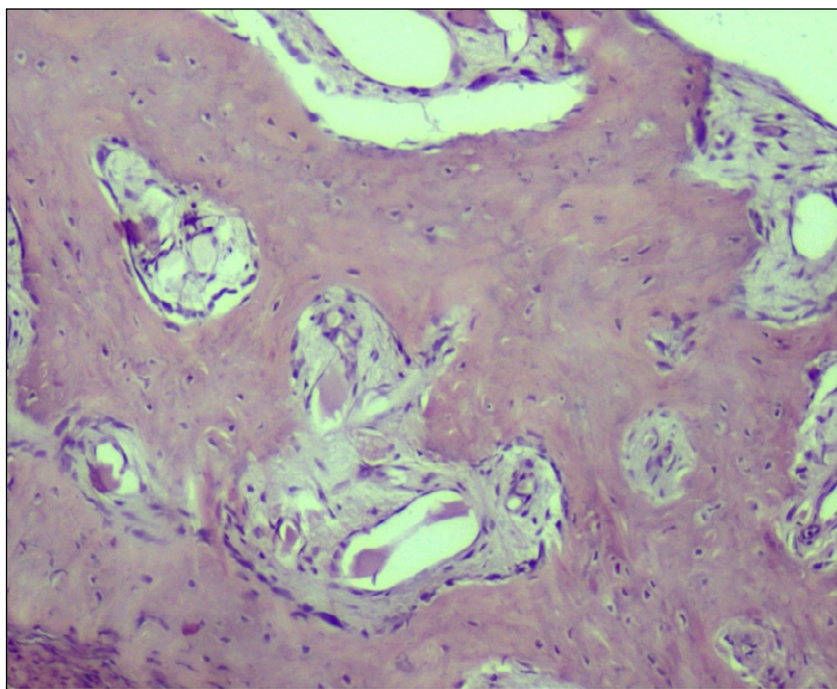


Fig. 8. Lamellar bone tissue from the area of the formed regenerate. Hematoxylin and eosin staining, $\times 400$.

plosive trauma of the maxillofacial region is long-term, multi-stage and should take place in a specialized

hospital with the involvement of a team of multidisciplinary specialists.

REFERENCES

1. Hulii MA, Soloviova VS. Personifikovana programa reabilitacii pacijenta z minno-vybuhovym poranennjam [Personalized rehabilitation program for a patient with a mine explosive injury]. *Achievements of Clinical and Experimental Medicine*. 2023;1:90-100. (Ukraine)
2. Guriev SO, Kravtsov DI, Kazachkov VYe, Ordatiy AV. Minno-vybuhova travma vnaslidok suchasnyh bojovyh dij na prykladi antyterrorystychnoi operacii na shodi Ukrainy. Povidomlennja 1. Kliniko-epidemiologichna charakterystyka postrazhdalych iz minno-vybuhovoju travmoju na rannomu hospitalnomu etapi nadannja medychnoi dopomogy [Mine-blast trauma as a result of nowadays combat: evidence from the counter terrorist operation in the eastern Ukraine. Report 1. Clinical and epidemiological characteristics of the victims with mine-blast trauma on the early hospital stage]. *Trauma*. 2015;16(6):5-8. (Ukraine)
3. Loskutov OA. Osoblyvosti antybiotykoaterapii pry minno-vybuhovij travmi [Peculiarities of antibiotic therapy for mine-explosive trauma]. *Health of Ukraine (thematic number "Surgery. Orthopedics. Traumatology. Intensive care")*. 2023;3(55):13. (Ukraine)
4. Chorna VV, Zavodiak AY, Matviichuk MV, Ivashkevych YeM, Syvak VM, Slobodian VV, Lunko OD. Tjazhkist uskodzhen pry minno-vybuhovij travmi zalezjno vid misceznahodzhenja osoby na moment vybuhu [Severity of injuries in case of mine-blast trauma depending on the location of the person at the time of the explosion]. *Ukrainian Journal of Military Medicine*. 2023;4(3):70-77. (Ukraine)
5. Pastukhova VA, Kucherenko OV. Charakter travmatychnogo uskodzhenja shkiry, etapy ii regeneracii ta osoblyvosti pry minno-vybuhovij travmi [Nature of traumatic damage to the skin, stages of its regeneration and features in mineblast injury]. *Morphologia*. 2023;17(1):5-18. (Ukraine)
6. Horachuk VV, Krut AH, Kononov OY. Availability of rehabilitation for victims of mine-explosive injury in the conditions of territorial community. *Wiad Lek*. 2024;77(5):926-931. doi: 10.36740/WLek202405107.
7. Gaida IM, Badyuk MI, Sushko Yul. Osoblyvosti struktury ta perebigu suchasnoi bojovoi travmy u vijskovosluzhbovciv Zbrojnyh Syl Ukrainy [Peculiarities of structure and current of modern combat trauma among servicemen of the Armed Forces of Ukraine]. *Pathologia*. 2018;15(1/42):73-76. (Ukraine)
8. Huseynov AN, Malanchuk VA, Myroshnychenko MS, Kapustnyk NV, Sukharieva LP, Selivanova LI. Special at-rich sequence-binding protein 2 and its role in healing of the experimental mandible bone tissue defect filling with a synthetic bone graft material and electrical stimulation impact. *Pol Merkur Lekarski*. 2024;52(4):385-391. doi: 10.36740/Merkur202404101.
9. Huseynov AN, Malanchuk VA, Myroshnychenko MS, Markovska OV, Sukharieva LP, Kuznetsova MO. Morphological characteristics of reparative osteogenesis in the rats lower jaw under the conditions of using electrical stimulation. *Pol Merkur Lekarski*. 2023;51(6):592-597. doi: 10.36740/Merkur202306102.
10. Leppik L, Oliveira KMC, Bhavsar MB, Barker JH. Electrical stimulation in bone tissue engineering treatments. *Eur J Trauma Emerg Surg*. 2020;46(2):231-244.

11. Kato K. Effects of Electrical Stimulation of the Cell: Wound Healing, Cell Proliferation, Apoptosis, and Signal Transduction. *Med Sci (Basel)*. 2023;11(1):11. doi: 10.3390/medsci11010011.
12. Odynets T, Kovalenko Ya. Fizychna terapija vijskovosluzhbovciv z naslidkamy minno-vybuchovoi travmy nyzhnih kincivok. [Physical therapy of military servants with the consequences of a mine-explosive injury of the lower extremities]. *Physical culture and sport: scientific perspective*. 2024;2(1):77-80. <https://doi.org/10.31891/pcs.2024.1.52> (Ukraine)

CONFLICT OF INTEREST

The Author declare no conflict of interest

CORRESPONDING AUTHOR

Mykhailo S. Myroshnychenko

Department of General and Clinical Pathological Physiology
named after D.O. Alpern, Kharkiv National Medical University
4 Nauky Avenue, Kharkiv, 61022, Ukraine
e-mail: msmyroshnychenko@ukr.net

ORCID AND CONTRIBUTIONSHIP

Agil N. Huseynov: 0000-0002-8633-134X **A** **D**
Vladislav A. Malanchuk: 0000-0001-8111-0436 **B**
Vyacheslav P. Maistrenko: 0009-0000-1635-3802 **E**
Mykhailo S. Myroshnychenko: 0000-0002-6920-8374 **D** **F**
Olena V. Markovska: 0000-0002-8759-4272 **B**
Andrii A. Boiko: 0000-0003-0432-5091 **E**
Oleksii I. Hryniuk: 0009-0003-5975-7665 **F**

A – Work concept and design, **B** – Data collection and analysis, **C** – Responsibility for statistical analysis, **D** – Writing the article, **E** – Critical review, **F** – Final approval of the article

RECEIVED: 05.06.2024

ACCEPTED: 03.10.2024

