

Health care ministry of Ukraine
Kharkiv National Medical University

Chair of Phthisiology and Pulmonology

PHTHISIOLOGY

Workbook for individual extra-auditorium training

IV course of higher medical foundation
dental faculty with IV level of accreditation

Student's name _____

faculty _____ **group** _____

Kharkiv ____/____

The authors: O.S. Shevchenko,
A.I. Choporova,
S.L. Matveyeva,

Approved at Chair of Phthisiology and Pulmonology
protocol № _____ 2013.

This workbook is recommended for improvement of students' individual extra-auditorium training. It presents training tasks for mastering of phthisiology educational program's data.

The workbook is created accordingly to credit-module system of education.

Authors

Module 1. General questions of phthisiology. Methods of examination of tuberculosis patient. The diagnosis of tuberculosis.

- ✓ *The definition of tuberculosis as a disease. Epidemiology of tuberculosis.*
- ✓ *The main epidemiological indexes of tuberculosis expansion.*
- ✓ *The causative organism of tuberculosis, its properties. The ways of TB infection.*
- ✓ *The peculiarities of clinical examination of tuberculosis patient.*
- ✓ *Microbiological diagnosis of tuberculosis. Fast methods of MTB finding.*
- ✓ *X-ray diagnosis of tuberculosis. Methods of x-ray investigations in phthisiology clinic. X-ray syndromes of tuberculosis. X-ray and morphological signs of tuberculosis.*
- ✓ *Tuberculin test. Case discussion.*
- ✓ *“Decried” contingents of the population who submit obligate fluorography examination.*

I level. Read the pages 15-23, 25-46, 64-68 A teaching manual in Ukrainian and English “Phthisiology” I.T. Pyatnochka, 2002 or the pages 15-41, 41-70, 75-81 A textbook for students “Phthisiology” V. I. Petrenko, 2008 and the pages 4-8, 12-14 “Phthisiology” Handbook for medical students with English medium for individual work O.S. Shevchenko with coauthors., 2011.

Answer to the question briefly in written form:

1. The definition of tuberculosis as a disease.
2. What are the main sources of tuberculosis infection?
3. What are the main modes of TB transmission and the ways of mycobacterium tuberculosis (MTB) spreading in the body?
4. What are the risk factors influence the incidence rate of tuberculosis?
5. Enumerate the epidemiological indices of tuberculosis prevalence
6. What are the social groups of high risk to develop tuberculosis?
7. What disease might promote the increase of tuberculosis incidence rate?
8. Enumerate the types of mycobacterium tuberculosis.

9. Enumerate the properties of mycobacterium tuberculosis (MTB).
10. Which phases of tuberculosis process reflect its activity?
11. Which phases of tuberculosis process correspond to his extinction?
12. What patients' complains is characteristic of tuberculous intoxication?
13. What patients' complains is characteristic of bronchi-pulmonary-pleural syndrome?
14. Enumerate compulsory and additional investigation methods in case of pulmonary tuberculosis suspicions.
15. What kind of bacterioscopy methods revealing of MTB do you know?
16. What advantages and deficiency of bacterioscopy method revealing of MTB?
17. What advantages and deficiency of bacteriological method revealing of MTB?
18. What other specimens other then sputum can be collected from a tuberculous patient?
19. What are the fast methods of MBT identification?

20. What kind of pathological shadows is characteristic for pulmonary tuberculosis?
21. What is tuberculin? 23. Enumerate the types of tuberculin.
22. Indicate the purposes of tuberculin skin test (TST) performance for teenagers and for children.
23. What is the conversion of tuberculin skin test?
24. What are the contraindications to tuberculin skin test?
25. What histological signs of tuberculosis do you know?

2 level. Solve the tests:

1. The first morphological reaction in the site of mycobacterium tuberculosis entering and multiplication will be:

- a. formation of caseous necrosis;
- b. formation of tuberculosis granulomas;
- c. formation of HeLa cells;
- d. formation of elastic fibers;
- e. formation of Boettcher's crystals

2. Tuberculosis of the respiratory organs is characterized by:

- a. the acute start of the disease;
- b. the gradual start of the disease;
- c. the asymptomatic beginning of disease.

3. The patient (40 years) complains on the cough with the sputum, weakness, fever. Physical findings: pathological changes of respiratory system are absent. Plane chest X-ray changes: cavity with peripheral inflammation is present in the right S_{1,2} and there are lesions of dissemination in both lungs. MTB are found in the sputum. The diagnosis was made: new case of PTB (15.01.2013) of right upper lobe (infiltrative one), Destr+, MTB+, M+,C+, Resist I 0, Resist II 0, Hist 0, Cat 1. Coh 1 (2013). Which method to find MTB corresponds with M+.

- a. culture method;
- b. biological test;
- c. bacteriological method;
- d. microscopy;
- e. method of pure culture.

4. The patient (30 years) was admitted at antituberculous dispensary with first diagnosed changes in the X-ray picture: the shadow with the diameter about of 1 cm, of slight intensity with unclear contours with the cavitation in the centre revealed by tomography. MTB are found in the sputum by culture method. The diagnosis of nodular tuberculosis was made. Which phases of tuberculosis X-ray changes corresponds with?

- a. phase of infiltration and dissemination
- b. phase of infiltration and cavitation
- c. phase of resolution and scarring
- d. phase of cavitation and dissemination
- e. phase of induration and resolution

5. Which X-ray sign is permitted to suppose cavity in the lung?

- a. translucency on darkening background;
- b. ring shadow;
- c. absents of bronchial -vesicular patterns in the limited areas of damaged lung;
- d. a and b are correct;
- e. all above enumerated are wrong.

6. Which method is used more often for revealing of cavitation in lung tissue?

- a. plain X-ray;
- b. tomography;
- c. target X-ray;
- d. radioscopy;
- e. bronchography

7. The patient (33 years) complains on the cough with the sputum, weakness, fever up to 37,2°C, poor appetite during 3 weeks. Physical examination did not reveal any pathological changes. What is necessary to clear during past history detailing?

- a. smoking;
- b. regimen of the work and rest;
- c. contact with tuberculous patient;
- d. going in for sport;
- e. presence of emotional lability.

8. The patient (32 years) was admitted at antituberculous dispensary with the relapse of tuberculosis. The patient's examination revealed the signs of bronchial-pulmonary syndrome. Which symptoms are characteristic for bronchial-pulmonary syndrome?

- a. fever, weakness, poor appetite, lost of weight, sweats;
- b. cough, weakness, insomnia, headache, hoarseness;
- c. cough with sputum, hoarseness, dry rales, dullness during the percussion;
- d. breathlessness, insomnia, malaise, moist rales, vocal phremitus;
- e. dyspnea, vomiting, rashes, sweats, cough, fever.

9. Which method of MTB revealing is more sensitive and specific?

- a. direct microscopy;
- b. cultural investigation;
- c. biological probe;
- d. polymerase chain reaction;
- e. immune- enzyme analysis.

10. Which method allow to determine sensitivity MTB to antituberculous drugs?

- a. bacterioscopic;
- b. bacteriological;
- c. polymerase chain reaction;
- d. immune- enzyme analysis;
- e. biological.

11. Who and when submit Mantoux test with 2 TU PPD-L?

- a. adults annually;
- b. children and teenagers quarterly;
- c. children since 12- month annually independently on results of previous probe.
- d. children, who often suffer from acute respiratory disease
- e. to all contingents of children and teenagers

12. Who does not need reexamination at phthisiologist?

- a. The person with firstly positive reaction, which unbound with BCG immunization;
- b. The person with hyperergic reaction of Mantoux test with 2 TU PPD-L;
- c. The person with increased tuberculin sensitivity (by 6 mm and more) during 1 year (at tuberculin positive child and teenagers);
- d. The person with positive Mantoux test result with 2 TU PPD-L during 1,5-2 years after; qualitative vaccination by BCG or BCG-M vaccine;
- e. The person with durable preservation tuberculin reaction papule size 12 mm and more during several years.

13. What period of time must be passed after Mantoux test with 2 TU of PPD-L till BCG vaccination is allowed to perform?

- a. in 10 days
- b. in 6 month;
- c. in 2 weeks;
- d. in 3 days;
- e. in 1 month.

14. Negative tuberculin test in a child of early age:

- a. allows to exclude primary infection;
- b. is the proof of an inefficiency of BCG vaccination;
- c. tuberculin testing is not the criteria for primary infection;
- d. allows to testify presence of active tuberculosis;
- e. allows to suspect presence of immunodeficiency.

15. The child (5 years) shows the result of Mantoux test with 2 TU of PPD-L as papule of 14 mm in the diameter. BCG scar of 7 mm is on the left arm. At the age of 4 years old Mantoux test was of 5 mm. Which definition of this Mantoux test is correct?

- a. tuberculin test conversion;
- b. hyperergic tuberculin reaction;
- c. positive reaction;
- d. increasing tuberculin sensitivity;
- e. tuberculin conversion with hyperergic reaction.

16. The child (3 years) was BCG vaccinated at maternity home. There is BCG scar on his left shoulder with the diameter of 7mm. At the age of 1 year old Mantoux test with 2TU PPD-L was of 10 mm, 2 years – 8 mm, 3 years – 14 mm. Which conclusion made on the ground of tuberculin test is correct?

- a. secondary pulmonary tuberculosis;
- b. post-BCG immunity;
- c. infectious immunity;
- d. hyperergic tuberculin reaction;
- e. tuberculin conversion with hyperergic reaction.

17. The child (4 years) was BCG vaccinated at maternity home. BCG scar is of 7 mm. At the age of 1 year Mantoux test was not done. At the age of 2 year Mantoux test result was of 8 mm, at the age of 3 year Mantoux test result was of 6 mm, at the age of 4 year Mantoux test result is 3mm.

Which conclusion must be done on the ground of Mantoux test results?

- a. TB infection;
- b. Positive tuberculin test;
- c. Tuberculin conversion;
- d. BCG-induced immunity;
- e. Negative tuberculin test.

1. a b c d e	6. a b c d e	11. a b c d e	16. a b c d e
2. a b c d e	7. a b c d e	12. a b c d e	17. a b c d e
3. a b c d e	8. a b c d e	13. a b c d e	
4. a b c d e	9. a b c d e	14. a b c d e	
5. a b c d e	10. a b c d e	15. a b c d e	

3 level. Resolve the clinical situational tasks:

1. The patient D. of 28 years old has no complains. He was in the contact with the neighbor suffering from tuberculosis. He hadn't been examined for last 3 years by X-ray. When he becomes employed focus shadowing 4 cm in diameter, middle intensity with vague contours and sickle-shaped eccentric translucency in right lung S₁ was revealed by X-ray. Blood analysis is normal. Objectively: on examination pathological changes was absent, percussively – clear vesicular resonance, on auscultation – vesicular breathing.

What signs tuberculosis suspected are present at the person?
Which investigation could confirm the diagnosis of tuberculosis?
Make an X-ray diagnosis (clinical form of tuberculosis, localization of pathology, phase of tuberculosis process)

2. The child at the age of 7 year is resides in a focus of tuberculous infection. He was vaccinated BCG in maternity house. At the age of 1 and 2 years papule of Mantoux test with 2 TU PPD-L was 10 mm and 8 mm in diameter. At the age of 3 year - 4 mm. At the age of 4, 5, 6 years – negative, at the age of 7 years - papule 17 mm. Postvaccinal scar is marked.

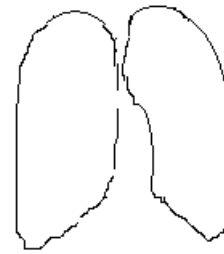
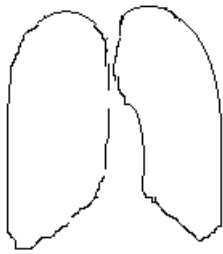
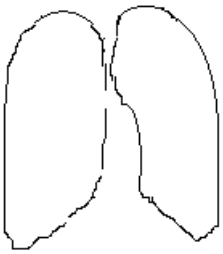
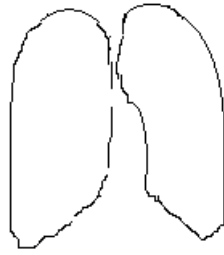
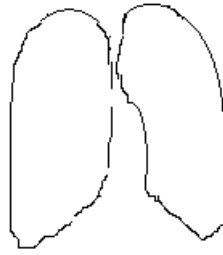
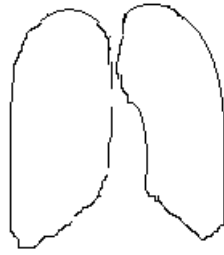
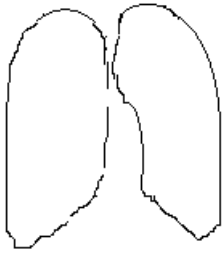
What is the nature of reaction on Mantoux test with 2 TU in 1 year?
What is the nature of reaction on Mantoux test with 2 TU in 7 year?
What is the tactics of a doctor concerning revaccination?
What is the further judgment and management of this case by doctor?

4 level.

1. Complete scheme of distinction between post-vaccination tuberculin allergy and post-infectious allergy.

Criteria	Post-vaccination tuberculin allergy	Post-infectious allergy
Time appearance of positive tuberculin reaction		
Evidence degree of tuberculin reaction		
Tuberculin reaction in dynamics		
Clinical signs of disease		
Contact with a person discharging mycobacteria		
Post-vaccination scar		
Pigmentation		

2. Draw up the X-ray view of tuberculosis changes according to radiological syndromes?



Student's subscription: _____

Module № 2. Treatment and prophylaxis of tuberculosis

- ✓ The main principles of tuberculosis patients' treatment.
- ✓ Antimycobacterial drugs. Drug resistance. Case discussion.
- ✓ Standardized regimens of tuberculosis patient treatment.
- ✓ Prophylaxis of tuberculosis. Case discussion.

1 level. Read the pages 195-221, 224-236 A teaching manual in Ukrainian and English "Phthysiology" I.T. Pyatnochka, 2002 or the pages 207-242, 263-271 A textbook for students "Phthysiology" V. I. Petrenko, 2008 and the pages 27-31, 36-40, 45-47 "Phthysiology" Handbook for medical students with English medium for individual work O.S. Shevchenko with coauthors., 2011.

Give an answer in written form to the next question:

1. Enumerate the basic principles of tuberculosis patients' treatment?
2. What are the phases of tuberculosis patients' treatment?
3. Write the classification of antimycobacterial drugs
4. What is primary and secondary drug resistance?
5. What kind of MTB resistance to the antituberculous drugs do you know?
6. Which conditions and environment factors promote TB drug resistance?
7. What are the standardized regimens of antimycobacterial chemotherapy at the initial phase according to category number? I II III IV
8. What are the criteria of TB patient recovery?

9. Give the definition of “tuberculosis prophylaxis”
10. What is the classification of tuberculosis prophylaxis?
11. What is related to sanitary prophylaxis of tuberculosis?
12. What is related to infectious control?
13. What is the BCG vaccine?
14. What is the goal for vaccination and revaccination?
15. What dose of BCG and BCG-M vaccine is used for vaccination?
16. Enumerate timely and absolute contraindications for BCG vaccination?
17. Enumerate contraindications to BCG revaccination?
18. What are the complications, which might appear after BCG vaccination or revaccination?
19. What are the aims and measures for chemoprophylaxis?
21. What population contingents should receive chemoprophylaxis?

2 level. Solve the tasks.

1. Formation of MTB resistance to antituberculosis drugs is caused by:

- natural abilities of mycobacterium tuberculosis to genetic mutations;
- inadequate treatment (including interruption) with antituberculosis drugs;
- long treatment by single antituberculosis preparations.
- all above mentioned are correct

2. The patient (36 years) was admitted at the antituberculous dispensary with the diagnosis: new case of PTB (4.11.2013) of lungs (disseminative one, phase of infiltration), Destr.+, MTB+, M+, C+, Resist. 0, Resist.11 0, Hist.0, Cat.1, Coh.4 (2013).According to Category 1 chemotherapy regimen was prescribed: isoniazid + rifampicin+ streptomycin+ pyrazinamide. The patient is alcohol abuser. Which drug as non-specific medication is the most rational one for the patient?

- Ambroscsol;
- Karsil;
- Lidase;
- Trental;
- Almagel;

3. The patient (40 years) takes the course of chemotherapy at antituberculous department with the diagnosis: new case of PTB (15.02.2013) of the upper right lobe (infiltrative one, phase of cavitation and dissemination), Destr.+, MTB+, M-, C+, Resist. -, Resist.II 0, Hist.0, Cat.1, Coh.1 (2013). 3 months after the chemotherapy had been begun the patient leaved the ward by his own decision. He did not take anti- TB drugs during following 2,5 months. Now he was admitted at the hospital again because the disease progresses.

Which chemotherapy regimen is needed for the patient?

- isoniazid + rifampicin + streptomycin + ethambutol;
- isoniazid + rifampicin + ethambutol + pyrazinamide;
- isoniazid + rifampicin + streptomycin + pyrazinamide;
- isoniazid + rifampicin +streptomycin + ethambutol + pyrazinamide;
- isoniazid + streptomycin + kanamycin.

4. The duration of hospital course of treatment of the tuberculous patient is determined by:

- clinical form of tuberculosis;
- presence destructive changes in lungs;
- massive bacteria expectoration;
- efficiency of spent medical measures;
- presence of accompanying measures.

5. What ensure the development of antituberculous immunity at BCG vaccination?

- alive MTB of vaccine strain;
- destroyed MTB of vaccine strain;
- L- shape form of vaccine strain;
- vitality products of vaccine strain;
- all above mentioned are correct.

6. To whom application of BCG-M vaccine is indicated?

- prematurely born child with body weight at delivery 2000g and more;
- prematurely born child with body weight after nourishment 2300g and before discharging from maternity hospital;
- child, who not vaccinated at maternity hospital, by medical indication after recovery in 1-6 month;
- all above mentioned are correct ;
- all above mentioned are is wrong.

7. Which size of post-vaccination scar corresponded to the presence of vaccine immunity?

- 1-2 MM;
- 3-4 MM;
- 5-7 MM;
- all above listened are correct;
- all above mentioned are wrong

8. What is the contraindication to BCG revaccination?

- a. revaccination BCG 5 years ago;
- b. positive anergia;
- c. contamination by MTB;
- d. presence of scar after previous vaccination;
- e. all listed above are correct.

9. Which variant, among listed below, does not belong to a contraindication for BCG revaccination?

- a. contamination by MTB or tuberculosis in the past;
- b. positive anergy;
- c. 1 month recovery after infectious diseases;
- d. aggravation stage of allergy disease;
- e. immunodeficiency conditions or treatment by immunosuppressant.

10. What reduces tuberculous infection spreading?

- a. timely revealing of tuberculous patients ;
- b. isolation and treatment of massive bacilli excretion persons;
- c. abolishment of infected by tuberculosis animals;
- d. antituberculosis immunization and chemoprophylaxis of contact person;
- e. all mentioned are correct.

11. What is chemoprophylaxis of tuberculosis?

- a. handling of patients' apartment by disinfection agents ;
- b. prescription of antituberculous drugs to the patients;
- c. prescription of antituberculous drugs to health person from groups of risk;
- d. all above mentioned are correct;
- e. all above mentioned are wrong.

12. Which antituberculous drugs are used at chemoprophylaxis for morbidity rate prevention?

- a. streptomycin ;
- b. isoniazid;
- c. rifampicin;
- d. ethambutol.
- e. kanamycin

13. The patient (35 years) has the diagnosis: new case of PTB (7.02.2013) of the right lung (infiltrative one) Destr.+, MTB+,M-,C+, Resist.-, Resist. 11-, Hist.0, Cat. 1, Coh.1 (2013). Bacilli excretion is scanty. The patient resides with his wife and his mother.

Which type of TB nidus the patient's residence belongs to?

- a. this residence is not TB nidus;
- b.1 type;
- c.3 type;
- d.2 type;
- e. conventional one.

14. The woman gave birth to the healthy child with 3 kg of body weight (8 balls according to Apgar's scale). Baby's father suffers from "open case" of tuberculosis (TB) and is at home now.

What is the pediatrician's management concerning the child?

- a. to vaccinate the child with BCG-1 and discharge him from the maternity home;
- b. to vaccinate the child with BCG-1, discharge him from the maternity home and to carry out the course of chemoprophylaxis;
- c. to vaccinate the child with BCG-1 and keep him at the maternity home for 1 month more;
- d. to vaccinate the child with BCG-M and discharge him from the hospital;
- e. to vaccinate the child with BCG-1, discharge him from the maternity home and to send his father to antituberculous hospital.

15. 5 kids were Mantoux tested with 2TU of PPD-L before BCG revaccination. Following results were obtained: 1st child – papule of 10 mm, 2nd child – papule of 4 mm with the vesicle in the centre, 3d child – papule of 3 mm, 4th child – hyperemia only, 5th child – injection reaction.

Which child submits to BCG revaccination? a.1st b.2nd c.3d d.4th e.5th

16. The child (6 months) was not BCG-1 vaccinated at maternity home because of acute viral infection. Now the child is well. BCG-vaccination is needed. Which investigation is needed to solve the question about BCG-vaccination?

- a. Mantoux test with 2TU of PPD-L;
- b. blood test;
- c. biochemical blood test;
- d. X- ray examination;
- e. immunological blood test.

17. In specialized maternity home department the woman suffers from “open case” of TB has the prematurely born child with body weight of 2300 g and height of 50 cm. The child is well.

What is the pediatrician’s management concerning the child?

- a. to BCG-1 vaccinate at maternity home;
- b. to BCG-M vaccinate at maternity home;
- c. to BCG-1 vaccinate during the first 2 months of life in the polyclinic;
- d. to BCG-M vaccinate during the first 2 months of life in the polyclinic;
- e. to perform chemoprophylaxis and then to BCG-1 vaccinate.

18. The child (3 months) was BCG-1 vaccinated at maternity home at birth. The child’s general state now is satisfied but vaccination complication develops – lymphadenitis (enlarged armpit lymphatic node with the abscess). Which local treatment the child is needed?

- a. local therapy only;
- b. isoniazid + local therapy only;
- c. isoniazid +rifampicin+ local therapy only;
- d. isoniazid +rifampicin;
- e. rifampicin+ local therapy.

19. The child (7 years) shows hyperergic Mantoux test result – papule of 22 mm in the diameter. This boy is in the contact with his grandmother suffers from “open case” of pulmonary TB. Course of chemoprophylaxis is needed for the boy. Which drug (or drug combination) is needed to be exploited for secondary chemoprophylaxis?

- a.isoniazid;
- b.isoniazid + ethambutol;
- c.ethambutol + pyrazinamide;
- d.rifampicin + pyrazinamide;
- e.isoniazid + PAS.

1. a b c d e	6. a b c d e	11. a b c d e	16. a b c d e
2. a b c d e	7. a b c d e	12. a b c d e	17. a b c d e
3. a b c d e	8. a b c d e	13. a b c d e	18. a b c d e
4. a b c d e	9. a b c d e	14. a b c d e	19. a b c d e
5. a b c d e	10. a b c d e	15. a b c d e	

3 level. Solve the clinical situation tasks:

1. The patient (40 years) was in contact with patient suffering from tuberculosis at the childhood. When he becomes employed shadow of darkening 2 cm in diameter with middle intensity and distinct contours is revealed by X-ray examination in the S₁ of right lung. Solitary nodular of low intensity shadow is detected at the nearest lung tissue. Any complains are absent. No pathology was revealed by physical examination. Blood analysis is normal. MTB is not revealed. The diagnosis was established: tuberculoma in the right lung S₁, MTB-.

Which category the patient must be related to?

Which chemotherapy regimen is needed for the patient at the intensive phase?

2. The girl (7 years) was BCG-1 vaccinated at birth. Mantoux test with 2 TU of PPD-L result at the age of 1, 2 and 3 years old is negative. BCG-scar on the left shoulder is absent.

What is the pediatrician's management concerning the child?

4 level. Make a plan of preventive measures at the tuberculous nidus, where patient suffering from fibrous-cavernous tuberculosis, MBT (+) resides if there are two adults and two kids in the family and if one child has positive tuberculin reaction.

Student's subscription: _____

Module № 3. Clinical classification of tuberculosis. Primary tuberculosis.

Complications of primary tuberculosis

- ✓ Clinical classification of tuberculosis. Case discussion.
- ✓ Tuberculosis of non-established localization, Tuberculosis of intrathoracic lymphatic nodes, Primary tuberculosis complex.
- ✓ Complications of primary tuberculosis. Case discussion

1 level. Read the pages 69-79 A teaching manual in Ukrainian and English “Phthiology” I.T. Pyatnochka, 2002 or the pages 92-103 A textbook for students “Phthiology” V. I. Petrenko, 2008 and the pages 52-57 “Phthiology” Handbook for medical students with English medium for individual work O.S. Shevchenko with coauthors, 2011.

Give an answer in written form to the next question:

1. What types of tuberculosis process according to classification do you know?
2. Recite the clinical forms of primary tuberculosis
3. Recite the clinical forms of secondary tuberculosis
4. Enumerate the methods of etiology confirmation of tuberculosis
5. Enumerate the complications of pulmonary tuberculosis.
6. What is the structure of tuberculosis clinical diagnosis?
7. Enumerate characteristic signs of primary tuberculosis
8. Write the definition of tuberculosis of unknown primary localization.
9. Diagnosis of the tuberculosis of unknown primary localization is based on the data:
10. Write the definition of intrathoracic lymph node tuberculosis
11. What are the X-ray forms of intrathoracic lymph node tuberculosis?

12. What complications intrathoracic lymph node tuberculosis may follow by?
13 What diseases should one differentiate intrathoracic lymph node tuberculosis from?
14. What is the primary tuberculosis complex?
15. What is the Gohn's focus?
16. What are the complications of the primary tuberculosis complex?
17. How is uncomplicated primary tubercular complex treated?

2 level. Solve the tests.

1. The patient (43 years) was examined by clinical and X-ray methods. The diagnosis: new case of PTB (21.01.2013) of upper right lobe (infiltrative one), Destr.+, MTB+, M-, C+, Resist. I -, Resist. II -, Cat.1, Coh.1(2013). Which phase of tuberculosis the meaning "Destr + " corresponds with?

- a. phase of infiltration
- b. phase of dissemination
- c. phase of induration
- d. phase of cavitation
- e. phase of resolution

2. The patient (42) complains on the fever up to 37,2 °C, weakness, sweats, cough with the sputum. Plane chest X-ray picture: infiltrate with cavitation is present in the right upper lobe, MTB were found in the sputum. Which diagnosis formulation is correct?

- a. new case of PTB (12.02.2013) of right upper lobe (infiltrative one), Destr+, MTB+, M+, C+, Hist. 0, Cat.1, Cog. 1(2013).
- b. new case of PTB (12.02.2013) of right upper lobe (infiltrative one), Destr+, MTB+, M+, C+, Resist.0, Hist.0, Cat.1, Cog. 1(2013).
- c. new case of PTB (12.02.2013) of right upper lobe (infiltrative one), Destr+, MTB+, M+, C-, Hist.0, Cat.1, Cog.1 (2013).
- d. new case of PTB(12.02.2013) of right upper lobe (infiltrative one), MTB+, M+, C+, Resist I 0, Resist. II +, Hist.0, Cat..1, Cog.1 (2013).
- e. new case of PTB(12.02.2013) of right upper lobe (infiltrative one), Destr.+, Resist. I 0, Resist. II +, Hist.0.

3. The patient (23 years) complains on the weakness, subfebrile fever, mild cough with the sputum. After clinical, laboratory and X-ray investigations the diagnosis was made: new case of PTB(17.12.2013) of both lungs (disseminative one, phase of infiltration), Destr.+, MTB+, M-, C+, Resist. I-, Resist. II-, Hist.0, Cat...., Coh. 4 (2013). Which category the patients must be related to?

- a. Category 5
- b. Category 4
- c. Category 1
- d. Category 2
- e. Category 3

4. Choose the correct formulation of primary tuberculosis:

- a. first manifestation of tuberculous changes in lungs;
- b. disease of patient infected by mycobacterium tuberculosis of human type;
- c. disease of patient with positive reaction to Mantoux test;
- d. disease of the patient due to contact with tuberculous patients;
- e. new disease in adult, who had tuberculosis in the childhood.

5. A basic cause of transition of primary infection into tuberculosis is:
 a. massive super infection; c. weakening of the post vaccination immunity;
 b. adverse premorbid conditions and frequent d. all above mentioned.
 intercurrent diseases;

6. The tuberculosis of mediastinum lymphatic nodes is most frequently complicated by:
 a. bronchial obstruction; c. hematogenic dissemination;
 b. lymphogenic dissemination; d. all variants are correct

7. What is most typical for uncomplicated primary complex:
 a. dry cough; b. productive cough; c. chest pain; d. syndrome of intoxication.

8. The primary tubercular complex is most often necessary to differentiate with:
 a. lung cancer with metastasis in lymph nodes of c. malformation of the lungs;
 lungs; d. eosinophylic infiltration.
 b. acute pneumonia;

9. The child (4 years) took the chemotherapy in pediatrician antituberculous hospital because of the diagnosis: New case of TB (9.02.2011) of tracheo-bronchial lymph nodes (small form, phase of infiltration), Destr+, MTB-, M-,C-, Resist I (0), Resist II (0), Hist 0, Cat.3, Coh.1(2011). As a result of carried treatment 2 intensive shadows are present at the right lung hilum at the X-ray picture. Which clinical variant of intrathoracic lymph nodes TB is actual?
 a. "small" one; b. caseous one ;
 d. tumor-like one; e. indurative one; c. infiltrative one.

10. The patient (10 years) was BCG-revaccinated at the age of 7 years old. At the age of 8 years old Mantoux test with 2 TU of PPD-L was 10 mm, 9 years – 8 mm, now (10 years) – 10 mm. Two months ago the child was in the contact with his grandfather suffers from "open case" of pulmonary tuberculosis. The child complains on the tiredness, malaise, weakness, his appetite is decreased. He becomes irritable. Physical findings: skin is pale and moist. Enlarged soft painless peripheral lymphatic nodes (3-5 mm) are palpable in the posterior cervical triangle region. Blood test: erythrocytes - $4,5 \times 10^{12}/l$, leucocytes - $9,2 \times 10^9/l$, stabs – 8%, ESR – 17 mm/hour. Chest X-ray picture: abnormality is absent. Which clinical form of TB the child suffers from?
 a. pulmonary nodular tuberculosis; d. tuberculosis of intra thoracic lymph nodes
 b. TB of meninges and nervous system (small form);
 c. tuberculosis of non-established localization;

11. The child 12 years old. Mantoux test shows infiltrate with diameter 17 mm. At maternity house the child was BCG vaccinated, BCG sign is 3 mm. Blood test: leucocytes – $7,4 \cdot 10^9/l$, ESR -15 mm/hour. In 3 sputum smears MTB were not found microscopically. X-ray picture: there is shadowing 4 cm*4 cm of slight intensity of the left lung and enlargement of the lung hilum due to enlargement of intrathoracic lymph nodes. The child is from the family contact with the patient suffers from pulmonary tuberculosis. Mantoux tests were negative all previous years. Which clinical form of TB the child suffers from?
 a. pulmonary nodular tuberculosis; d. TB bronchitis;
 b. primary tuberculosis complex; e. tuberculosis of intrathoracic lymph nodes
 c. tuberculosis of non-established localization; (small form).

1. a b c d e	5. a b c d e	9. a b c d e
2. a b c d e	6. a b c d e	10. a b c d e

3. a b c d e	7. a b c d e	11. a b c d e
4. a b c d e	8. a b c d e	

3 level. Solve the clinical situational tasks:

1. The child (5 years) complains on the weakness, malaise, subfebrile fever up to 37, 3-37,5°C periodically, irritability. Enlarged peripheral lymphatic nodes are palpable in the posterior cervical triangle region. Percussion and auscultation did not reveal any abnormality in lungs. Mantoux test result is 13 mm, last year – 8 mm. X-ray chest picture and medium tomogram – abnormality is absent. Blood test: leucocytes – $7,7 \times 10^9/l$, eosinophils – 3%, sticks – 6%, segments – 60%, lymphocytes – 21%, monocytes – 10%, ESR - 18 mm/hour.

Make the clinical diagnosis formulation accordingly to clinical classification?
Which chemotherapy regimen is needed for the child?

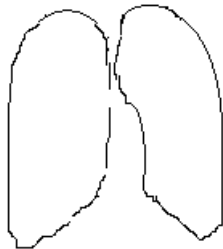
2. The child (13 years) complains on the weakness, subfebrile fever up to 37,3°C, decreased appetite, rapid fatigability, sweats loss of energy, mild cough. His father suffers from “open case” of tuberculosis. Mantoux test conversion is found with the papule of 14 mm in the diameter. Blood test: leucocytes – $10,9 \times 10^9/l$, ESR – 18 mm/hour. Physical findings failed to reveal pathology in lungs.

What diagnosis formulation is correct?
Which investigation is needed to confirm the diagnosis?

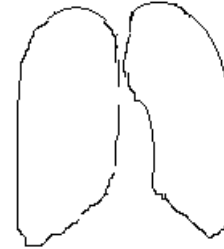
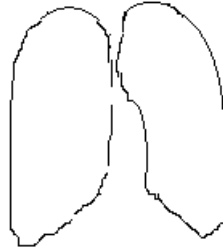
4 level.

Make a diagrammatic drawing of the X-ray shadows due to:

primary tuberculous complex



tuberculosis of intrathoracic lymphatic nodes



Infiltrative variant

Tumorous variant

Student's subscription: _____

**Module № 4. Secondary tuberculosis (pulmonary and extrapulmonary ones).
Complications of secondary clinical forms which demand urgent care.**

- ✓ Disseminated pulmonary tuberculosis. Miliary tuberculosis.
- ✓ Tuberculosis of nervous system and meninges.
- ✓ Nodular and infiltrative pulmonary tuberculosis. Caseous pneumonia. Case discussion.
- ✓ Fibrous-cavernous and cirrhotic pulmonary tuberculosis. Tuberculous pleurisy (including empyema). Case discussion.
- ✓ Diagnosis and treatment of complications of tuberculosis which demand urgent care: lung hemorrhage, spontaneous pneumothorax. Case discussion.

1 level. Read the pages 80-84, 87-104, 106-120, 127-130, 137-155, 158-163 A teaching manual in Ukrainian and English “Phthisiology” I.T. Pyatnochka, 2002 or the pages 104-116, 116-157, 142-156; 159-173, 202-205, 196-200 A textbook for students “Phthisiology” V. I. Petrenko, 2008 and the pages 60-62, 65- 67, 72-74, 81-85 Handbook for medical students with English medium for individual work O.S. Shevchenko with coauthors, 2011.

Give an answer in written form to the next question:

1. What is disseminated tuberculosis?
2. What are the forms of disseminated tuberculosis?
3. What is miliary tuberculosis?
4. What are the clinical types of miliary tuberculosis?
5. What are the characteristic symptoms of miliary tuberculosis?
6. What X-ray changes are characteristic for miliary tuberculosis?
7. What chemotherapy regimen is indicated for treatment of patients with miliary tuberculosis?
8. What are the X-ray features of subacute and chronic disseminated pulmonary tuberculosis?
9. What is tuberculosis meningitis?
10. What are the forms of tuberculosis meningitis by localization?
11. What are the clinical periods of tuberculosis meningitis?
12. What are the syndromes are characteristic for TB meningitis?

13. What cranial nerves are affected at meningeal tuberculosis?
14. Which changes of cerebrospinal fluid are characteristic for meningeal tuberculosis?
15. What is nodular tuberculosis?
16. What are the clinical and radiological types of nodular tuberculosis?
17. Give the definition of pulmonary infiltrative tuberculosis?
18. Enumerate the X-ray variants of tuberculous infiltrates.
19. What diseases pulmonary infiltrative tuberculosis must be differentiated from?
20. Give the definition of caseous pneumonia.
21. What are the typical X-ray and clinical signs of caseous pneumonia?
22. What is the treatment of caseous pneumonia?
23. Give the definition of pulmonary tuberculoma.
24. What are the clinical and x-ray signs of tuberculoma?
25. What diseases one should differentiate tuberculoma from?
26. Give the definition of fibro-cavernous pulmonary tuberculosis.

27. What forms of tuberculosis precede the fibro-cavernous one?
28. What radiological signs are characteristic for fibro-cavernous tuberculosis?
29. What is cirrhotic tuberculosis?
30. What are the X-ray signs of cirrhotic pulmonary tuberculosis?
31. What are the characteristic signs of cirrhotic tuberculosis on physical examination?
32. Give the definition to “pulmonary hemorrhage, hemoptysis”.
33. What is the pathogenesis and factors promoting hemoptysis and pulmonary hemorrhage?
34. What is the classification of hemorrhage according to their intensity?
19. What are the symptoms of hemoptysis and pulmonary hemorrhage?
20. What is haemostatic therapy aimed at?
21. What is spontaneous pneumothorax? What are the types of pneumothorax?
22. What are the clinical signs of spontaneous pneumothorax?

23. What are the causing factors of spontaneous pneumothorax at pulmonary tuberculosis?
24. What are the X-ray signs of spontaneous pneumothorax?
25. What is pleurisy classification depending on the character of exudate?
26. Enumerate the clinical and radiological signs of tuberculous pleurisy.

2 level. Solve the tests.

1. Miliary tuberculosis is characterized by:

- | | |
|--|--|
| a. scanty mycobacterium expectoration; | c. absence of mycobacterium expectoration; |
| b. poor mycobacterium expectoration; | d. periodic mycobacterium expectoration. |

2. First manifestations of acute hematogenic disseminated (miliary) tuberculosis are all listed, except for:

- | | |
|------------------------------------|---|
| a. body temperature rising; | c. strong coughs with poor sputum; |
| b. insignificant usual dry coughs; | d. manifestations of dyspnea and tachycardia. |

3. Which changes of cerebrospinal fluid more characteristic for meningeal tuberculosis?

- increasing of protein, chloride, glucose amount;
- higher cytosis (more than 1000 cells), neutrophilic character, moderate increasing amount of protein, liquid is cloudy;
- insignificant increasing amount of protein, moderate lymphocytic cytosis, glucose and chlorides in norm;
- higher rate of protein amount, moderate cytosis (200–400 cells and more), predominantly lymphocytic, decrease of glucose and chlorides)

4. Choose the correct formulation of disseminated tuberculosis of respiratory organs:

- bilateral extensive opacity in the lungs;
- total unilateral focal damage of the lungs;
- bilateral limited or widespread damage of the lungs with prevalence of foci and interstitial changes;
- unilateral focal damage of lobe of lung;
- cavernous damage of the superior lobe of one lung with focal dissemination of inferior part of both lungs.

5. To manifestation signs of acute hematogenic-disseminated (military) tuberculosis of lungs belongs all of listened below, except for:

- | | |
|---|--|
| a. rising body temperature till hectic level; | c. intensive cough with scanty sputum; |
| b. insignificant, usually dry cough; | d. occurrence of dyspnea and tachycardia |

6. In which segments of lungs focal tuberculosis is located:

- a. 3, 4, 5, 6; b. 1, 2, 6; c. 1, 2; d. 6; e. 8, 9.

7. The basic method of nodular pulmonary tuberculosis finding in adults is:
- prophylactic fluorography;
 - diagnostic fluorography;
 - tuberculin diagnosis;
 - the microbiological examination for mycobacterium expectoration;
 - radiography.
8. The most reliable method for diagnosis of destructive pulmonary tuberculosis is:
- fluorography;
 - X-ray;
 - tomography;
 - ultrasonic sound;
 - radioisotope imaging.
9. The cloud-like infiltrate is characterized by:
- clinical signs of pneumonia;
 - clinical symptoms of bronchitis;
 - absence of clinical symptoms;
 - pain on lesion side.
10. Which pathology one should differentiate tuberculous lobitis from?
- lobar pneumonia
 - lung cancer;
 - eosiniphilic pneumonia;
 - all listened above
11. Which disease one should differentiate tuberculoma from?
- peripheral cancer;
 - aspergillums;
 - with retention cyst;
 - all answers are correct.
12. Which form of pulmonary tuberculosis morphologically corresponds with thick wall cavity and nodular, infiltrative and fibrotic changes around it?
- chronic disseminated tuberculosis;
 - fibrous-nodular tuberculosis;
 - infiltrative tuberculosis;
 - fibrous-cavernous tuberculosis;
 - cirrhotic tuberculosis.
13. What character of sputum occurs more often in patient with pulmonary fibrous-cavernous tuberculosis?
- glassy;
 - mucous;
 - viscid;
 - purulent;
 - mucous-purulent.
14. Which morphological changes are not characteristic for patients with cirrhotic pulmonary tuberculosis?
- rough deform sclerosis;
 - bronchiectatic decay;
 - emphysematous bulla;
 - cavitation with sign of progression.
15. Effective medicinal means of struggle with hemoptysis are:
- intravenous introduction 10% of a solutions calcium chloride 5-10 ml;
 - the cooled alkaline solutions per os and means of struggle with cough;
 - intra muscular etamsylatum (dicinon), intra vein, vitamin C, vicasol;
 - impose right on extremities and subcutaneous introduction of oxygen
 - all above listened
16. Pulmonary hemorrhage is observed:
- at fresh, sharply proceeding forms of lesions of lungs;
 - with acute and subacute disease, with disintegration of lung tissue;
 - with chronic disease, accompanying by the cirrhosis formation in the lung tissue.
17. A principal cause of death of patients with pulmonary hemorrhage is:

- a. sharp pneumonia; b. hemorrhagic shock; c. asphyxia.

18. The basic clinical symptoms of spontaneous pneumothorax:

- a. fever, cough with sputum; c. fever, dry hoarse cough, chest pains;
 b. chest pains and dyspnea; d. chest pains hard breathing, cough with sputum.

19. With which form of pulmonary tuberculosis exudative pleurisy occurred rarely?

- a. primary tuberculosis complex; d. tuberculosis of intrathoracic lymphatic nodes;
 b. subacute disseminated tuberculosis; e. nodular tuberculosis.
 c. chronic disseminated tuberculosis;

20. What is the cause of effusion in pleural cavity at elderly age more probable?

- a. pneumonia; d. tuberculous of intrathoracic lymphatic nodes;
 b. pulmonary tuberculosis; e. sarcoidosis.
 c. malignant lung tumor;

1. a b c d e	6. a b c d e	11. a b c d e	16. a b c d e
2. a b c d e	7. a b c d e	12. a b c d e	17. a b c d e
3. a b c d e	8. a b c d e	13. a b c d e	18. a b c d e
4. a b c d e	9. a b c d e	14. a b c d e	19. a b c d e
5. a b c d e	10. a b c d e	15. a b c d e	20. a b c d e

3 level. Solve the clinical situational tasks:

1. Patient of 19 years old was admitted at the infectious hospital with diagnosis typhoid fever. He is ill during 2 weeks. 2 days ago was emerged sharp worsening of general state – body temperature was rising till 39,8°C, strong headache, nausea, fountain-like vomiting, which does not improve general condition. Objectively: severe patient's state, lies on “trigger” posture, express occipital muscle rigidity, positive Kernig's and Brudzinski symptoms. Vesicular breathing in the lungs is heard. X-ray is without pathology. Analysis of blood: leukocytes $10,5 \cdot 10^9/l$, ISR 40 mm/hour. Liquor analysis: transparent with opalescence, cytois 300 cells/mm³, glucose 1,8 mmol/l, in 12 hours thin fibrin film was deposit where MTB are found by bacterioscopy.

Formulate the diagnosis according to functional classification

Prescribe the treatment

2. The woman of 25 years old becomes ill acutely. The body temperature rising up to 39,0°-39,5°C, appeared sharp weakness, breathlessness, dry cough. Objectively is without pathology. Multiply small nodular shadows, small intensity with unclear contours, without tendency to fusion on background of washed lung pattern throughout the both lungs was revealed by X-ray.

Which clinical form of TB is detected at the woman?

Which category of the treatment this case is related to?

Prescribe the patient's treatment in intensive phase.

3. Solitary, low intensity nodular shadows with unclear contours, middle size at the apical segments of both lungs were found at the patient of 20 years old by fluorography. Complaints are absent. Objectively: without pathology. Blood analysis is normal. It was established diagnosis: pulmonary tuberculosis.

Which clinical form of pulmonary tuberculosis was found in the patient?

Prescribe the patient's treatment in the intensive phase

4. The patient of 34 years old fell ill acutely. Body temperature is rising up to 39° C, appear cough with mucous sputum up to 50 ml/day. Contact with TB patients isn't ascertaining. He has diabetes mellitus. Under whole upper lobe of right lung is revealing dullness of percussion sound, weakness of vesicular breathing with single moist rales. On X-ray: non-homogenous shadowing with partial translucency in upper lobe of right lung. MTB are found in the sputum.

Which type of TB infiltrate is found in the patient?

Formulate the diagnosis according to active classification.

5. The patient of 40 years old suffers from fibro-cavernous tuberculosis of right lung for 10 years with periodical bacilli excretion. He complains on dyspnea, weakness, sweating, subfebrile temperature, but exclude hospitalization. The pulmonary hemorrhage, blood loss 300 ml is started in the evening.

What is the management of this case?

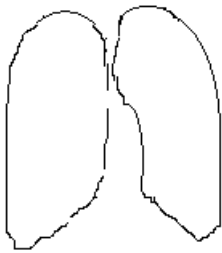
What is the urgent aid?

6. The patient N., of 54 years old suffers from pulmonary disseminated tuberculosis in the phase of destruction, MTB+. In the morning after coughing acute pain in the thorax right side and dyspnea appear. The patient is admitted at the hospital. Objectively: skin is pale, pulse 110 bit/min. Tympanic sound is revealed over the thorax right side, breathing is not conducted. Right lung is collapsed on 1/3 of his own volume, organs of mediastinum are shifted to the left.

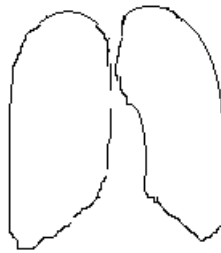
Define the diagnosis.

Which urgent care is necessary to provide for the patient?

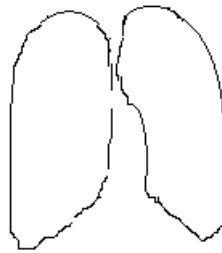
4 level. Make a diagrammatic drawing of the X-ray shadows due to:



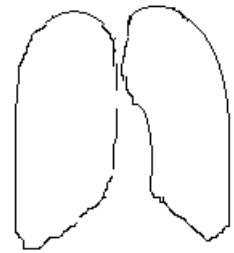
Miliary TB



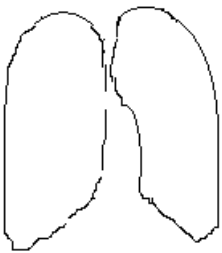
Acute disseminated



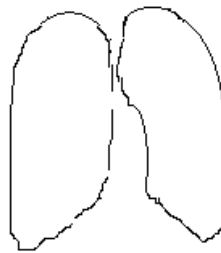
Subacute disseminated TB



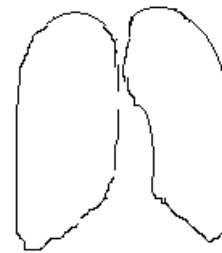
Chronic disseminated



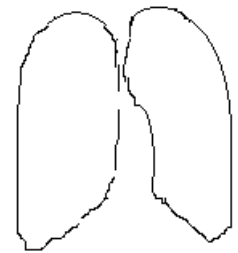
Nodular TB



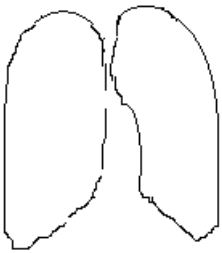
Infiltrative TB



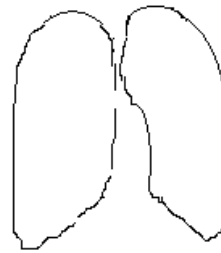
Tuberculoma



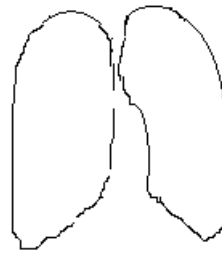
Caseous pneumonia



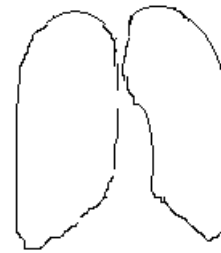Fibro-cavernous TB



Cirrhotic TB



TB pleurisy



Spontaneous pneumothorax

Student's subscription: _____

Module №5. Pulmonary tuberculosis and concomitant diseases. Organization of medical care for tuberculosis patients

- ✓ Tuberculosis of mandible- face localization: clinical pictures, diagnosis, peculiarities of treatment patients suffering from tuberculosis of mucous of mouth cavity and mandible-face bones. Case discussion.
- ✓ Co-infection: TB and HIV. Organization of medical care for tuberculosis patients. Case discussion.

1 level. Pubmed sources: 1) Monaldi Arch Tuberculosis of oral mucosa. Chest Dis. 2001 Aug; 56(4):315-7; 2) Garg RK, Singhal P. Primary tuberculosis of tongue : a case report. J Contemp Dent Pract. 2007 May 1; 8(4): 74-80. Read the pages 123-127; 179-195 A teaching manual in Ukrainian and English “Phthiology” I.T. Pyatnochka, 2002 or the pages 157-158; 182-183 A textbook for students “Phthiology” V. I. Petrenko, 2008 and the pages 90-95 “Phthiology” Handbook for medical students with English medium for individual work O.S. Shevchenko with coauthors.

Give an answer in written form to the next question:

1. Pathogenesis and pathomorphological changes in case of maxillofacial TB.
2. Give the description of lupoma.
3. Give the definition of lupus vulgaris,
4. Give the definition of miliary-ulcerative tuberculosis.
5. Give the definition scrophuloderma
6. Enumerate the diagnostic principles of maxillofacial tuberculosis.
7. What are the main principles of the maxillofacial tuberculosis treatment.
8. Give the definition of HIV-infection, enumerate its stages.
9. Give the definition of AIDS.
10. List the clinical features suspicious for HIV-infection in patients with tuberculosis.
11. What are the peculiarities of clinical course of early and late HIV/AIDS- associated tuberculosis?

12. What are the diagnostics criteria for HIV/AIDS- associated tuberculosis?
13. What are the X-ray signs of HIV/AIDS-associated tuberculosis?
14. Describe the treatment measures for patients with HIV-associated tuberculosis.

2 level. Solve the tests.

1. What is the frequency of oral tuberculosis appearance?

- a. 0.5-1.0%;
- b. 0.05-2.0%;
- c. 0.05-5.0%;
- d. 1.0-5.0%;
- e. 3.0-5.0%.

2. Which manifestation of tuberculosis of mucous membrane is observed more often?

- a. ulcer
- b. nidi
- c. tuberculoma
- d. cavern
- e. erosion

3. What is the conventional method of oral cavity tuberculosis diagnosis?

- a. sampling on MBT
- b. fluorography of the lungs
- c. bronchoscopy
- d. computer tomography
- e. consultation by phthisiatrician

4. What is the way of tuberculosis infection development in alveolar localization of jaw bones lesions?

- a. hematogenous;
- b. lymphogenous;
- c. traumatic;
- d. allergic;
- e. odontogenic.

5. What is the primary element of lupus vulgaris:

- a. cavern up to 1 cm;
- b. tuberculoma up to 2 cm;
- c. ulcer from 0.5 to 1 cm;
- d. lupoma from 1 to 3 mm;
- e. keloidal scar.

6. A patient of 47 years old suffers from destructive pulmonary tuberculosis and AIDS. What is the duration of the basic course of treatment in case of co-infection?

- a. 3 month;
- b. 6 month;
- c. 9 month;
- d. non less than 12 month.

7. What is the external appearance of ulcerative form of oral tuberculosis?

- a. shallow ulcer irregular shape with undermined borders, the bottom tuberous, covered with succulent granulation; it has purulent secretion. Surraounded surface on periphery and around sown by pink- pale and graish ulceration;
- b. limited necrosis membranous character, crateriform ulcers, surraounded by limbus with sharp objectionable odor; salivation.
- c. deep ulcers on the tongue and in the bony cage of oral cavity – covered this fat-similar fur, copper-coloured;
- d. shallow bleeding ulcers, irregular, undermined, thick margin, painful infiltration of regional lymph nodes;
- e. soft limited red color infiltration with malacia in the center.

8. What one among mentioned below is characteristic for TB at the late stage of HIV-infection?

- a. Significant intoxication over long term with negative Mantoux test;
- b. Diffused infiltration localized both in upper lobes and in middle and lower parts of lungs;
- c. Prevalent extrapulmonary involvement, intrathoracic lymphatic nodes enlargement, generalized lymphadenopathy;
- d. MBT absence in half of patients;
- e. All above mentioned ones is characteristic.

9. What are the laboratory criteria for HIV/AIDS-associated tuberculosis diagnostics?

- a. Typical blood indices;
- b. Quantitative indices of T-helpers;
- c. Changes of relations CD₄/CD₈ coefficient;
- d. Disturbance of natural immunity;
- e. Atypical indices for this disease

1. a b c d e	4. a b c d e	7. a b c d e
2. a b c d e	5. a b c d e	8. a b c d e
3. a b c d e	6. a b c d e	9. a b c d e

3 level. Solve the clinical situational tasks.

1. A 43-year-old patient fell sharply ill: body temperature rising up to 39°C, cough with mucous smear up to 50 ml a day, he had lost weight. The contact with tuberculosis patient was not revealed. He had a history of smoking for the last 20 years. He suffers from diabetes. Under whole upper part of right lung is revealed dullnesses on percussion, weakens of vesicular breathing with solitary moist rales. On X-ray there is heterogenous darkening with partial translucency in upper part of right lung was revealed. On examination his tongue had a nodular lesion (tuberculoma) on the dorsal surface near the base of the tongue. There was no cervical lymphadenopathy. A tongue biopsy revealed a tuberculous granulomatous lesion. Specimens from the lesion were also tested for mycobacterial DNA using polymerase chain reaction (PCR) that detected MBT. MBT in the sputum samples are found by culture and Ziehl-Neelsen staining.

Formulate the diagnosis according to active classification.

2. The patient A., of 30 years old suffers from HIV/AIDS during 5 years. In recent time he feels worse: rising body temperature, cough, sputum with blood admixtures, pain in the chest are appeared. The focus shadowing with unclear contours and area of translucency in S₆ of right lung is revealed. MTB are found in sputum by microscopy.

Formulate the diagnosis according to active classification.

Make up the plan of the patient's examination.
Make the plan of treatment.

4 level.

1. Make the plane of patient examination for estimation of combined pathology: pulmonary tuberculosis, complicated by TB of mandible- face localization in HIV infected persons.

Student's subscription: _____

Educational edition

PHTHYSIOLOGY

Workbook for self-students' work at home

**IV course of higher medical foundation
dental faculty with IV level of accreditation**

The compilers: Shevchenko Olga Stanislavna
Choporova Aleksandra Ivanovna
Matveyeva Svetlana Leonidovna

Responsible for the issue Choporova O.I.