

Echographic diagnosis of salivary gland tumors

R.Y. Abdullaiev¹, P.O. Korol², O.V. Shcherbina², R.R. Abdullaiev¹

¹Kharkiv National Medical University, Kharkiv, Ukraine

²Shupyk National Healthcare University of Ukraine, Kyiv, Ukraine

Для цитування: Абдуллаєв РЯ, Король ПО, Щербіна ОВ, Абдуллаєв РР. Ехографічна діагностика пухлин слинних залоз. Radiation diagnostics and radiation therapy. 2024;15(1): 15-22. <https://doi.org/10.37336/2707-0700-2024-1-2>.

Cite: Abdullaiev RY, Korol PO, Shcherbina OV, Abdullaiev RR. Echographic diagnosis of salivary gland tumors. Radiation diagnostics, radiation therapy. 2024; 15(1): 15-22. <https://doi.org/10.37336/2707-0700-2024-1-2>.

According to various authors, salivary gland tumors account for 2% to 6.5% of all head and neck neoplasms. They are characterized by a wide variety of morphological variants, degree of malignancy and clinical behavior [1, 2]. Among all tumors of the salivary glands, the proportion of parotid is about 70%, submandibular – about 10%, sublingual – less than 1%, minor salivary glands – about 20%. Almost half of minor salivary gland tumors and all sublingual gland tumors are malignant. About 50-60% of all parotid tumors are pleomorphic adenomas, 20-30% are Warthin's tumors, and about 10% are mucoepidermoid carcinomas [3-5].

About 80% of all salivary gland tumors are benign. Pleomorphic adenoma remains the most common tumor among benign neoplasms of the salivary glands, ranging from 61 to 90%. Among the histological types, mesenchymal and epithelial types of tumors predominate. Mesenchymal and epithelial types of pleomorphic adenomas dominate among women and men [6]. The most common localization of neoplasm of the major salivary glands is the parotid gland (from 40–72%), the minor salivary glands are the palatine glands (from 16–62%) [7].

Malignant tumors are observed more often among people over 40 years of age and equally in men and women, and pleomorphic adenoma among women is observed 1.4 times more often than in men [8].

Salivary gland tumors are a rare tumor formation among malignant tumors of all tissues.

The most common are malignant mucoepidermoid carcinoma, adenoid cystic carcinoma, and acinic cell carcinoma. Pleomorphic adenoma is the most recurrent form of benign salivary gland tumor. Due to their low incidence rates and complex histological patterns, they are difficult to diagnose accurately. Malignant tumors of the salivary glands are challenging in terms of differentiation because of their variability in histochemistry and translocations [9-11].

Secretory carcinoma is one of the types of malignant neoplasms of the salivary glands. There are some similarities and differences between acinic cell carcinoma and secretory carcinoma. Both of these types of carcinoma have almost identical growth patterns. Unlike acinic cell carcinoma, secretory carcinoma occurs in small areas of the gland [12].

In every third case, malignant and benign tumors of the salivary glands have a similar clinical picture. For clearly benign tumors, open biopsy is not recommended due to the risk of tumor spread. At the same time, a puncture biopsy is indicated in cases where radical surgery is expected. With a sluggish course, the tumor is often disguised as benign neoplasms and pre-operative histological diagnosis in such cases may be missed. A comprehensive consideration of the clinical picture, imaging results, cytology and/or histology allows in 90% of cases to differentiate a malignant and benign tumor [13].

Echography is the main method for diagnosing pathologies of the salivary glands [14, 15]. In case of deep tumor lesions or bone

infiltration, ultrasound examination should be supplemented with computed tomography of the neck [16].

Literature data on the possibility of echography in the diagnosis of space-occupying formations of the salivary glands and the differentiation of benign and malignant neoplasms are contradictory. According to Anto J Richie et al. (2019) the diagnostic accuracy of echography in the diagnosis of salivary gland tumors was 85.7% [17].

The purpose of this study was to determine echographic parameters for the diagnosis of salivary gland tumors.

Research material and methods. The results of echography were analyzed in 62 patients with tumors of the salivary glands aged 26-78 years (on average 51 ± 7 years), among them 37 women, 25 men. Qualitative and quantitative echographic parameters were determined. Visualization of the salivary glands was carried out using linear and microconvex sensors in the frequency range 5-12 MHz and 4-9 MHz on ultrasonic devices Ultima PA and Philips HD-11.

The study results were analyzed by the method of statistical processing of quantitative factors. Student's t-test was used to evaluate the differences in quantitative indicators between the groups. Differences at $p < 0.05$ were considered significant.

The study was conducted in accordance with the principles of bioethics set forth in the WMA Declaration of Helsinki – «Ethical principles for medical research involving hu-

man subjects» and «Universal Declaration on Bioethics and Human Rights» (UNESCO).

Results and their discussion

Patients with salivary gland tumors were divided into 3 age categories: young (≤ 44 years), middle age (45-59 years) and elderly (60-74 years). Table 1 shows the distribution of patients taking into account age and gender. As can be seen from the table, tumors of the salivary glands among young people were registered in 30 ($48.4 \pm 6.3\%$), middle-aged – in 19 ($30.6 \pm 5.9\%$), elderly – in 13 ($21.0 \pm 5.2\%$), respectively. The number of young patients was significantly greater than the number of middle-aged ($P < 0.05$) and elderly ($P < 0.001$) patients. Of the young patients, 10 ($16.1 \pm 4.7\%$) were men, 20 ($32.2 \pm 6.0\%$) were women ($P < 0.05$). These indicators for middle-aged patients were 9 ($14.5 \pm 4.5\%$) and 10 ($16.1 \pm 4.7\%$), for elderly patients – 6 ($9.7 \pm 3.5\%$) and 7 ($11.3 \pm 3.7\%$), respectively. The number of young women was significantly greater than that of middle-aged ($P < 0.05$) and elderly ($P < 0.001$) women.

The distribution of histologically diagnosed cases of salivary gland tumors is presented in Table 2. As can be seen from the table, the most frequently diagnosed pleomorphic adenoma – in 32 ($51.6 \pm 6.3\%$) cases, followed by Wartin's tumor – in 17 ($27.4 \pm 5.7\%$) cases. Mucoepidermoid carcinoma was diagnosed in 6 ($9.7 \pm 3.7\%$) cases, acinic cell carcinoma – in

Table 1. Distribution of patients based on their age and gender

Gender of patients	Age categories			Total
	Young (≤ 44 years)	Middle age (45-59 years)	Elderly (60-74 years)	
Men	10 ($16.1 \pm 4.8\%$)	9 ($14.5 \pm 4.5\%$)	6 ($9.7 \pm 3.5\%$)	25
Women	20 ($32.2 \pm 6.0\%$) $P < 0.05$ $P^* < 0.05$ $P^{**} < 0.001$	10 ($16.1 \pm 4.7\%$)	7 ($11.3 \pm 3.7\%$)	37
Total	30 ($48.4 \pm 6.3\%$) $P^* < 0.05$ $P^{**} < 0.001$	19 ($30.6 \pm 5.9\%$)	13 ($21.0 \pm 5.2\%$)	62

Note: P – comparison between men and women; P^* – comparison with middle age; P^{**} – comparison with elderly age.

Table 2. Distribution of histologically diagnosed cases of salivary gland tumors

Salivary gland tumors (n=62)				
Pleomorphic adenoma	Wartin's tumors	Mucoepidermoid carcinoma	Acinic cell carcinoma	Myoepithelial carcinoma
32 (51.6±6.3%)	17 (27.4±5.7%)	6 (9.7±3.7%)	5 (8.1±3.5%)	2 (3.2±2.2%)
P<0.01 P*<0.001 P**<0.001 P***<0.001	P*<0.01 P**<0.01 P***<0.001	–	–	–

Note: P – difference compared to Warthin's tumors; P* – difference compared with mucoepidermoid carcinoma (P<0.01), P** – difference compared with acinic cell carcinoma; P*** – difference compared to myoepithelial carcinoma.

5 (8.1±3.5%) and myoepithelial carcinoma – in 2 (3.2±2.2%) cases. The number of cases of pleomorphic adenoma was significantly higher than Warthin's tumors (P<0.01) and all types of salivary gland carcinomas (P<0.001). Warthin's tumor occurred significantly more frequently than mucoepidermoid carcinoma and acinic cell carcinoma (P<0.01), as well as myoepithelial carcinoma (P<0.001).

The echographic pattern of salivary gland tumors is characterized by polymorphism. To carry out a differential diagnosis between the benignity and malignancy of the identified formation in the salivary glands, the

following echographic criteria were developed: the shape of the tumor was defined as round-oval and irregular; contours – clear and fuzzy; echogenicity – isoechoic and hypoechoic; echostructure – homogeneous and heterogeneous; vascularization – mild, moderate and enhanced (Table 3).

As can be seen from Table 3, benign tumors in 39 (79.6±5.8%) cases had a round-oval shape, and in 10 (20.4±5.8%) cases they had an irregular shape (P<0.001). Malignant tumors in 4 (30.8±12.8%) cases were round-oval, in 9 (69.2±12.8%) cases they were irregular in shape (P<0.001). A significant (P<0.001) difference was found between benign and malignant tumors in the frequency of detection of both types of forms (Fig. 1, 2).

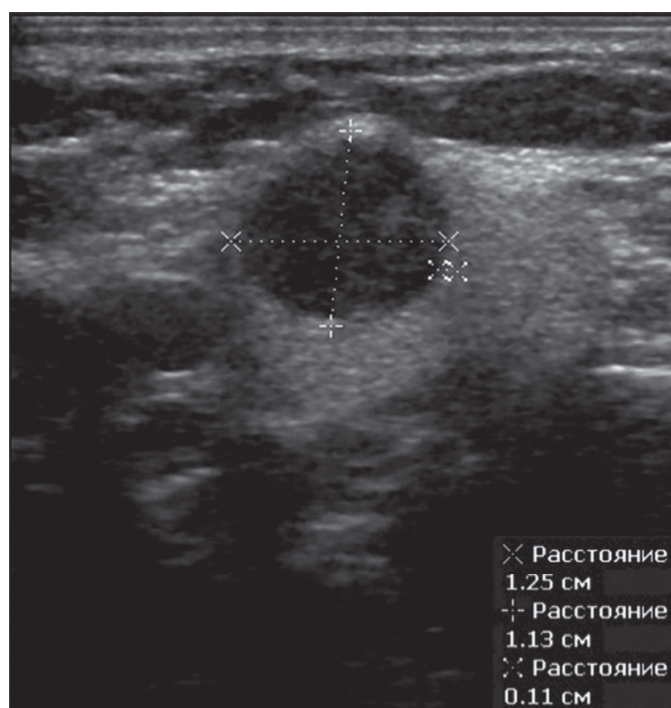


Fig. 1. Pleomorphic adenoma of the parotid salivary gland. The tumor has a round shape.

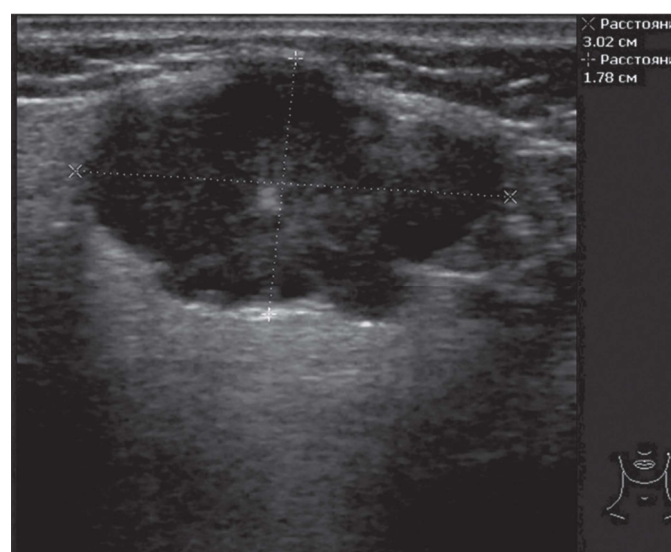


Fig. 2. Pleomorphic adenoma of the parotid salivary gland. The tumor has an irregular geometric shape.

Table 3. Echographic pattern of salivary gland tumors

Echographic pattern		Carcinoma n=13	Adenoma n=49
Form	Round-oval	4 (30.8±12,8%)	39 (79.6±5.8%) P<0,001
	Irregular shape	9 (69.2±12.8%) P<0,01	10 (20.4±5.8%)
Contours	Clear	2 (15.4±10.0%)	38 (77.6±6.0%)
	Fuzzy	11 (84.6±10.0%)	11 (22.4±6.0%)
Echogenicity	Isoechogenic	4 (30.8±12.8%)	17 (35.0±6.8%)
	Hypoechoic	9 (69.2±12.8%) P* $<$ 0.05	32 (65.0±6.8%) P* $<$ 0.01
Echostructure	Homogeneous	3 (23.1±11.7%)	35 (71.4±6.4%) P<0,001 P* $<$ 0,001
	Heterogeneous	10 (76.9±11.7%) P<0,001 P* $<$ 0.001	14 (28,6±6,4%)
Vascularization	Mild	3 (23.1±11.7%)	28 (57.1±7.1%) P<0.05
	Moderate	4 (30.8±12.8%)	16 (32.7±6.7%)
	Enhanced	6 (46.2±13.8%) P<0.05	5 (10.2±4.3%)

Note: P – difference between adenoma and carcinoma;

P* – difference inside of every type of tumors.

Clear contours of salivary gland carcinoma were observed in 2 (15.4±10.0%) cases, of benign tumors – in 37 (75.5±6.1%) cases (P<0.001), unclear contours – in 11 (84,6±10.0%) and in 12 (24.5±6.1%) cases (P<0.001), respectively. The difference between the frequency of detection of clear and unclear contours of both types of tumors had a high degree of significance (P<0.001) (Fig. 3, 4).

Both benign and malignant salivary tumors are often hypoechoic or isoechoic. Isoechoic adenomas were diagnosed in 17 (35.0±6.8%) cases, carcinomas – in 4 (30.8±12.8%) cases, hypoechoic adenomas – in 32 (65.0±6.8%), carcinomas – in 9 (69.2±12.8%) cases. As can be seen from the table, there were no signifi-

cant differences between benign and malignant tumors in their echogenicity. However, hypoechoic carcinomas and adenomas were registered significantly more often (P<0.05 and P<0.01) than isoechoic tumors of the same type (Fig. 5, 6).

The echostructure of the tumor was assessed as homogeneous and heterogeneous. Carcinomas of homogeneous structure were diagnosed in 3 (23.1±11.7%) cases, adenomas – in 35 (71.4±6.4%) cases (P<0.001), heterogeneous tumors – in 10 (76.9±11.7%) and 14 (28.6±6.4%) cases (P<0.001), respectively. As can be seen from the table, heterogeneous tumors were significantly (P<0.001) more frequently registered among carcinomas, and homogeneous tumors – among adenomas.

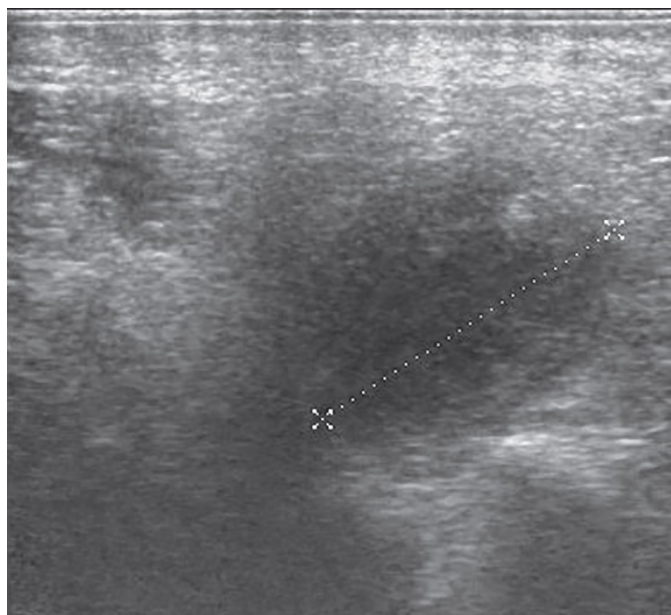


Fig. 3. Pleomorphic adenoma of the parotid gland. The contours of the tumor are fuzzy.

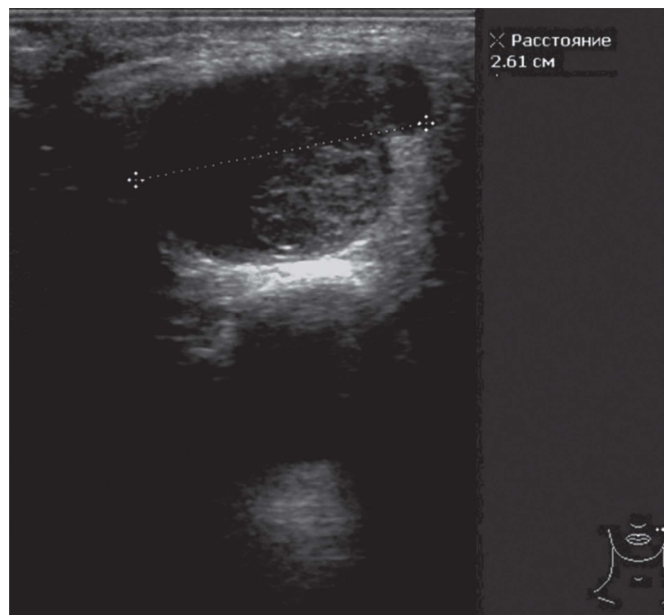


Fig. 4. Pleomorphic adenoma of the parotid salivary gland of irregular geometric shape. The contours of the tumor are clear.

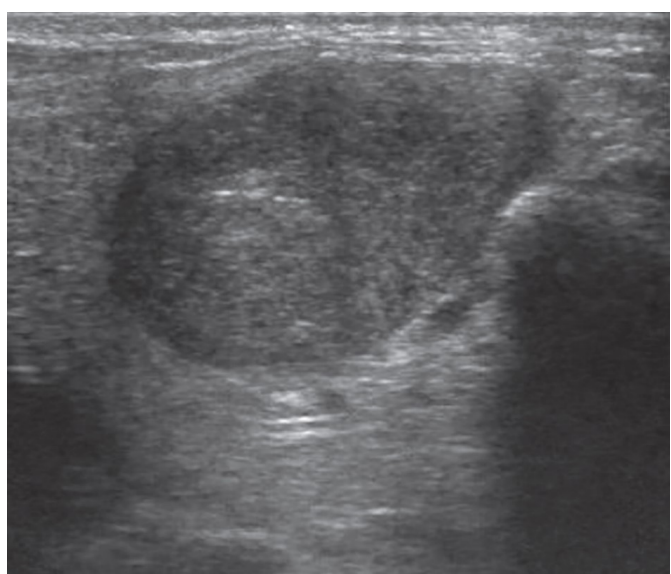


Fig. 5. Sonographic image of an oval-shaped isoechoic pleomorphic adenoma.

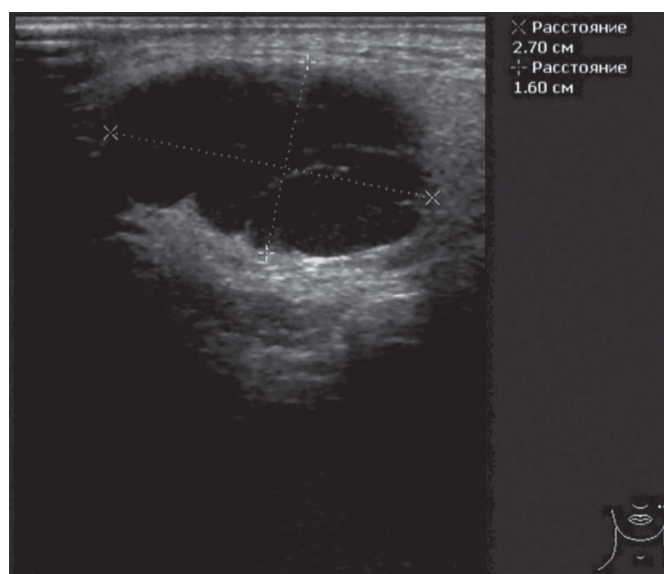


Fig. 6. Sonographic image of a hypoechoic oval-shaped pleomorphic adenoma.

The tumor vascularization was graded as mild, moderate, or enhanced. Mild vascularization of carcinoma was observed in 3 ($23.1 \pm 11.7\%$) cases, adenoma – in 28 ($57.1 \pm 7.1\%$) cases ($P < 0.05$), moderate vascularization – in 4 ($30.8 \pm 12.8\%$) and 16 ($32.7 \pm 6.7\%$) cases, increased vascularization – in 6 ($46.2 \pm 13.8\%$) and 5 ($10.2 \pm 4.3\%$) cases ($P < 0.05$), respectively. As can be seen from the table, among adenomas, mildly

expressed tumor vascularization was significantly ($P < 0.05$) more often recorded, and among carcinomas, increased vascularization of the tumor (Fig. 7-9).

As is known, salivary gland tumors account for 2% to 6.5% of all head and neck neoplasms. They are characterized by a wide variety of morphological variants, degree of malignancy, and clinical behavior [1]. Timely diagnosis of salivary gland tumors significantly improves

the results of surgical interventions and prognosis. A significant part (more than 80%) of all tumors is localized in three pairs of the major salivary glands, of which 70% originate from the parotid gland. The submandibular and sublingual glands account for about 11%. There is a direct correlation between the size and frequency of detection of salivary gland tumors. Echography is the main method for studying the major salivary glands in the diagnosis of various pathologies, in particular neoplasms [14]. Even in two-dimensional mode, the frequency of occurrence of such ultrasound parameters as the clarity of contours and the degree of heterogeneity of the echostructure allows a prelimi-

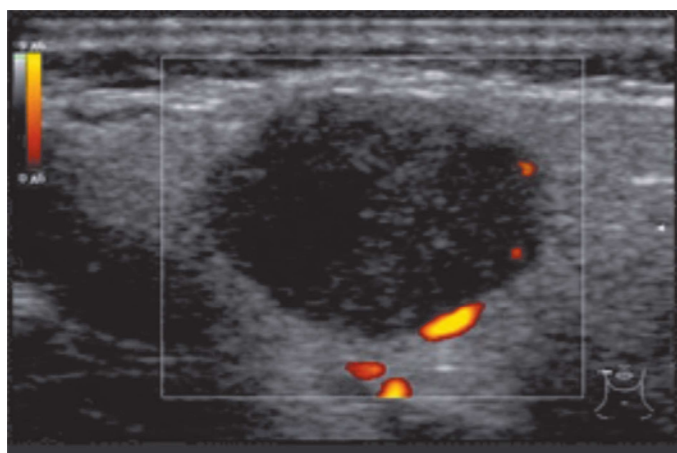


Fig. 7. *Mild vascularization of the parotid adenoma.*

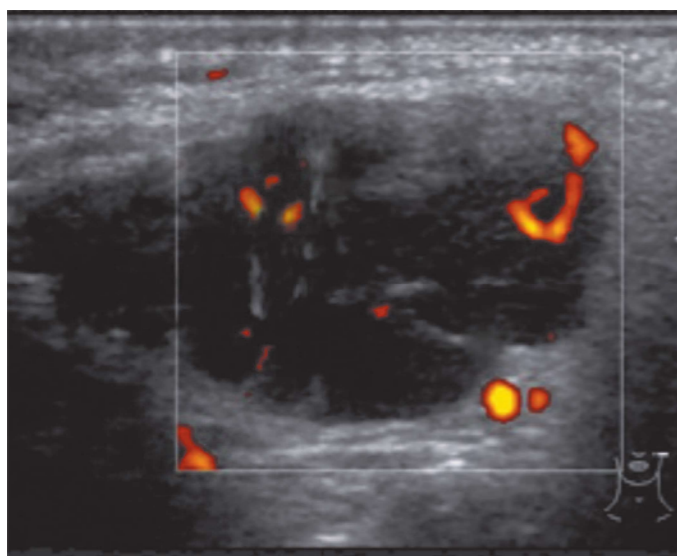


Fig. 8. *Adenolymphoma of the parotid gland. Moderate vascularization of the tumor – up to five vascular signals are visible with power Doppler ultrasound.*

nary assessment of the degree of malignancy of the process [15]. In the color Doppler mode, the predominance of central or peripheral vascularization also contributes to a narrowing of the range of differentiated tumor masses. However, the final method for verifying the diagnosis is the histopathological assessment of biopsy material, which can be taken under USG control [16].

Pleomorphic adenoma is most characterized by a round-oval shape, clear contours, homogeneous echostructure, and poor peripheral vascularization. The most characteristic features of Warthin tumors are: cystic echostructure and less pronounced central vascularization [17]. In our study, we analyzed the frequency of occurrence of echographic indicators in various types of salivary gland tumors that were diagnosed histologically. The most frequently detected benign tumor of the salivary glands was pleomorphic adenoma.

Conclusions

The most characteristic echographic parameters of benign salivary glands tumors are a round-oval shape, clear contours, homogeneous structure; for a malignant tumor – an irregular shape, fuzzy contours and increased vascularization.

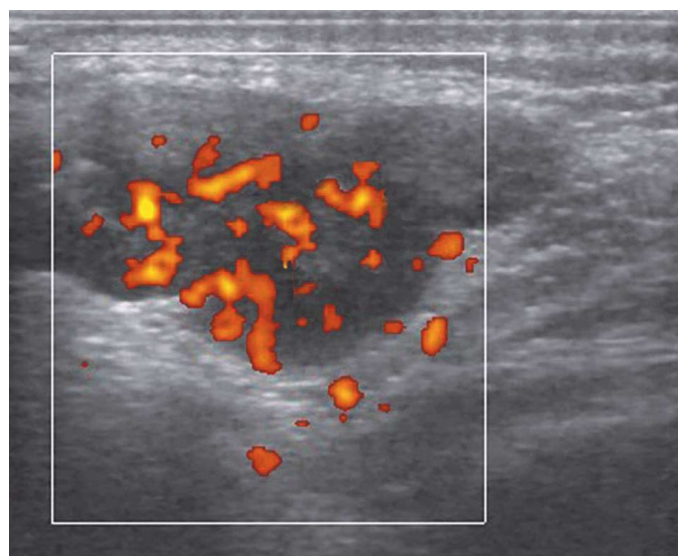


Fig. 9. *Increased vascularization of submandibular salivary gland carcinoma.*

Information on research funding sources: research funding was carried out at the expense of own funds.

Information on conflict of interest. The authors declare no conflict of interest related to the publication of this article.

References

- Peravali R.K., Bhat H.H.K., Upadya V.H., Agarwal A. and Naag S. Salivary Gland Tumors: A Diagnostic Dilemma. *J Maxillofac Oral Surg.* 2015 Mar; 14(Suppl 1): 438–442. doi: 10.1007/s12663-014-0665-1.
- da Silva LP, Serpa MS, Viveiros SK, Sena DAC, de Carvalho Pinho RF, de Abreu Guimarães LD, de Sousa Andrade ES, Dias Pereira JR, Silveira MMFD, Sobral APV, de Sousa SCOM, de Souza LB. Salivary gland tumors in a Brazilian population: A 20-year retrospective and multicentric study of 2292 cases. *J Craniomaxillofac Surg.* 2018 Dec;46(12):2227-2233. doi: 10.1016/j.jcms.2018.09.028.
- Lin HH, Limesand KH, Ann DK. Current state of knowledge on salivary gland cancers. *Crit Rev Oncog.* 2018; 23(3-4): 139–151. doi: 10.1615/CritRevOncog.2018027598.
- Valstar MH, de Ridder M, van den Broek EC. Salivary gland pleomorphic adenoma in The Netherlands: a nationwide observational study of primary tumor incidence, malignant transformation, recurrence, and risk factors for recurrence. *Oral Oncol* 2017; 66: 93-99. DOI: 10.1016/j.oraloncology.2017.01.004.
- Speight PM, Barrett AW. Salivary gland tumours: diagnostic challenges and an update on the latest WHO classification. *Diagnostic Histopathology.* 2020; 26(4):147-158. doi: 10.1034/j.1601-0825.2002.02870.x.
- Triantafyllou A, Thompson LD, Devaney KO, Bell D, Hunt JL, Rinaldo A, Vander Poorten V, Ferlito A. Functional Histology of Salivary Gland Pleomorphic Adenoma: An Appraisal. *Head Neck Pathol.* 2015;9(3):387-404. doi: 10.1007/s12105-014-0581-1.
- Wang XD, Meng LJ, Hou TT, Huang SH. Tumours of the salivary glands in northeastern China: a retrospective study of 2508 patients. *Br J Oral Maxillofac Surg.* 2015 Feb;53(2):132-7. doi: 10.1016/j.bjoms.2014.10.008.
- Khurram SA, Barrett AW, Speight PM. Diagnostic difficulties in lesions of the minor salivary glands. *Diagn Histopathology* 2017; 23: 250-9. <https://doi.org/10.1016/j.mpdhp.2017.04.008>.
- Del Signore AG, Megwalu UC. The rising incidence of major salivary gland cancer in the United States. *Ear Nose Throat J.* 2017 Mar;96(3):E13-E16. doi: 10.1177/014556131709600319. PMID: 28346649.
- Seethala RR, Stenman G. Update from the 4th Edition of the World Health Organization Classification of Head and Neck Tumours: Tumors of the Salivary Gland. *Head and Neck Pathol.* 2017; 11:55–67. doi: 10.1007/s12105-017-0795-0. PMID: 28247227. PMCID: PMC5340736.
- Khurram SA, Sultan-Khan J, Atkey N, Speight PM. Cytogenetic and immunohistochemical characterization of mammary analogue secretory carcinoma of salivary glands. *Oral Surg Oral Med Oral Pathol Oral Radiol.* 2016 Dec;122(6):731-742. doi: 10.1016/j.oooo.2016.07.008.
- Boliere C, Murphy J, Qaisi M, Manosca F, Fung H. Mammary Analogue Secretory Carcinoma of the Palate: Case Report and Review of the Literature. *Case Rep Dent.* 2019; 2019: 7416302. doi: 10.1155/2019/7416302.
- Meyer MT, Watermann C, Dreyer T, Ergün S, Karnati S. 2021 Update on Diagnostic Markers and Translocation in Salivary Gland Tumors. *Int J Mol Sci.* 2021 Jun 24;22(13):6771. doi: 10.3390/ijms22136771.
- Carotti M, Ciapetti A, Jousse-Joulin S, Salaffi F. Ultrasonography of the salivary glands: the role of grey-scale and colour/power Doppler. *Clin Exp Rheumatol.* 2014;32:S61–70. PMID: 24528823.
- El-Rasheedy, AEI, Abdalla AMAR, Hassanein SAh. The role of ultrasound in evaluating salivary glands swellings. *Egypt J Otolaryngol.* 2021; 37: 101. <https://doi.org/10.1186/s43163-021-00165-y>
- Kakoty S, Baruah TD, Babu CPG. FNAC and histopathological correlation of salivary gland lesions: An observational study.

Int Surg J. 2017; 4(7): 2148-52. DOI: <https://dx.doi.org/10.18535/jmscr/v6i7.21>.

17. Anto J Richie, Mellonie P. Sonological evaluation of major salivary gland lesions

with histopathological correlation. International Journal of Contemporary Medicine Surgery and Radiology. 2019; 4(2): B91-B94. DOI: <http://dx.doi.org/10.21276/ijcmsr.2019.4.2.21>.

ECHOGRAPHIC DIAGNOSIS OF SALIVARY GLAND TUMORS

*R.Y. Abdullaiev, P.O. Korol,
O.V. Shcherbina, R.R. Abdullaiev*

The purpose of the study is to determine echographic parameters of the diagnosis of salivary gland tumors.

Material and methods. The study is based on the analysis of the results of echography of the salivary gland in 62 patients with salivary gland tumors aged 26-78 years (on average 51 ± 7 years), among them 37 women and 25 men. Qualitative and quantitative echographic parameters were determined.

Results. Pleomorphic adenoma was diagnosed in 32 ($51.6 \pm 6.5\%$) cases, Wartin's tumor – in 17 (27.4 ± 5.7), mucocpidermoid carcinoma – in 6 ($9.7 \pm 3.7\%$), acinic cell carcinoma – in 5 ($8.1 \pm 3.5\%$) and myoepithelial carcinoma – in 2 ($3.2 \pm 2.2\%$) cases. The number of pleomorphic adenomas was significantly higher than Wartin's tumors ($P < 0.01$) and all types of salivary gland carcinomas ($P < 0.001$).

Benign tumors in 39 ($79.6 \pm 5.8\%$) cases had a round-oval shape, and in 10 ($20.4 \pm 5.8\%$) cases they had an irregular shape ($P < 0.001$). Malignant tumors in 4 ($30.8 \pm 12.8\%$) cases were round-oval, in 9 ($69.2 \pm 12.8\%$) cases they were irregular in shape ($P < 0.001$).

Mild vascularization of carcinoma was observed in 3 ($23.1 \pm 11.7\%$) cases, of adenoma in 28 ($57.1 \pm 7.1\%$) cases ($P < 0.05$), moderate vascularization – in 4 ($30.8 \pm 12.8\%$) and 16 ($32.7 \pm 6.7\%$) cases, increased vascularization – in 6 ($46.2 \pm 13.8\%$) and 5 ($10.2 \pm 4.3\%$) cases ($P < 0.05$), respectively.

Conclusions. The most characteristic echographic parameters of benign salivary glands tumors are a round-oval shape, clear contours, homogeneous structure; for a malignant tumor – an irregular shape, fuzzy contours and increased vascularization.

Keywords: echography, salivary gland tumors, pleomorphic adenoma, salivary gland carcinoma.

ЕХОГРАФІЧНА ДІАГНОСТИКА ПУХЛИН СЛИННИХ ЗАЛОЗ

*Р.Я. Абдуллаєв, П.О. Король,
О.В. Щербіна, Р.Р. Абдуллаєв*

Мета дослідження – визначення ехографічних критеріїв діагностики пухлин слинних залоз.

Матеріал і методи. Робота базується на аналізі результатів ехографії слинних залоз у 62 хворих з пухлинами слинних залоз віком 26-78 років (у середньому – 51 ± 7 років), серед них жінок 37, чоловіків 25. Визначено якісні та кількісні ехографічні параметри.

Результати. Плеоморфна аденома діагностувалася – у 32 ($51,6 \pm 6,5\%$) випадків, пухлина Вартіна – у 17 ($27,4 \pm 5,7$), мукоепідермоїдна карцинома – у 6 ($9,7 \pm 3,7\%$), ациноклітинна карцинома – 5 ($8,1 \pm 3,5\%$) та міоепітеліальна карцинома – у 2 ($3,2 \pm 2,2\%$) випадках. Кількість плеоморфних аденом було достовірно більше, ніж пухлин Вартіна ($P < 0,01$) та всіх видів карцином ($P < 0,001$) слинних залоз.

Доброякісні пухлини у 39 ($79,6 \pm 5,8\%$) випадків мали округло-овальну форму, у 10 ($20,4 \pm 5,8\%$) – неправильну ($P < 0,001$). Злоякісні пухлини у 4 ($30,8 \pm 12,8\%$) випадків були округло-овальної, у 9 ($69,2 \pm 12,8\%$) – неправильної форми ($P < 0,001$).

Слабовиражена васкуляризація карциноми відзначалася у 3 ($23,1 \pm 11,7\%$) випадках, аденоми у 28 ($57,1 \pm 7,1\%$) випадках ($P < 0,05$), помірна васкуляризація – у 4 ($30,8 \pm 12,8\%$) та 16 ($32,7 \pm 6,7\%$) випадків, посилена васкуляризація – у 6 ($46,2 \pm 13,8\%$) та у 5 ($10,2 \pm 4,3\%$) випадків ($P < 0,05$), відповідно.

Висновки. Найбільш характерними ехографічними ознаками доброякісних пухлин слинних залоз є округло-овальна форма, чіткі контури, однорідна структура; для злоякісної пухлини – неправильна форма, нечіткі контури та підвищена васкуляризація.

Ключові слова: ехографія, пухлини слинних залоз, плеоморфна аденома, карцинома слинної залози.