

## Clinical Case of Using Intravenous Forms of Anti-Tuberculosis Drugs to Improve the Treatment Efficiency of Tuberculosis in Patients with Malabsorption Syndrome

Kuzhko MM<sup>1</sup>, Butov DO<sup>2\*</sup>, Hulchuk NM<sup>1</sup>, Avramchuk OV<sup>1</sup>, Protsyk LM<sup>1</sup> and Kuzhko ZF<sup>3</sup>

<sup>1</sup>State Institution "F.G. Yanovsky National Institute of Phthisiology and Pulmonology of the National Academy of Medical Sciences of Ukraine", Kyiv, Ukraine

<sup>2</sup>Kharkiv National Medical University, Kharkiv, Ukraine

<sup>3</sup>Branch No.4 Non-profit municipal enterprise "Advisory and Diagnostic Center" of the Solomianskyi district, Kyiv, Ukraine

### Abstract

Clinical case of progression of pulmonary tuberculosis on a background of therapy with oral antimycobacterial drugs is presented for your information. Malabsorption of oral formulations was confirmed during treatment, allowing to change the treatment strategy and to cure the patient.

**Keywords:** Pulmonary tuberculosis; Treatment efficacy; Malabsorption syndrome; Anti-tuberculosis drugs intestinal malabsorption; Intravenous anti-tuberculosis drugs

### Background

The use of antimycobacterial therapy in its majority leads to positive dynamics of disease, sputum conversion and tuberculosis cure. The absence of the expected positive response to the used therapy we define in a limited number of drug-susceptible tuberculosis patients. One of the most common causes of the absence of a positive response in case of provided prescription of medicines under defined and controlled sensitivity of receiving chemotherapy may be malabsorption/maldigestion syndrome.

Under normal conditions, anti-tuberculosis drugs (ATD) are usually well absorbed when administered orally. Nevertheless, the determining factor for drug absorption is the absorptive capacity of the intestinal mucosa, which may be altered in several clinical situations [1-3].

### Case Presentation

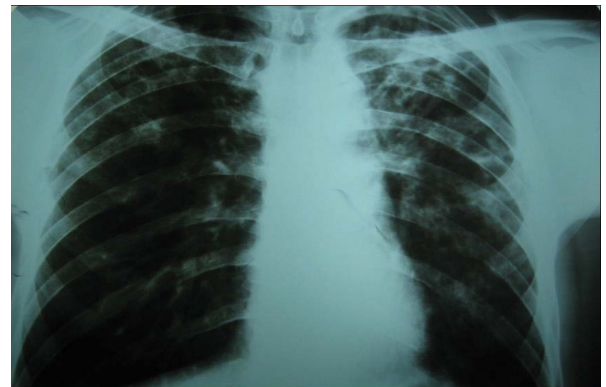
The patient is 47 years old. Pulmonary tuberculosis detected by X-ray examination (Figure 1) on complaints of cough with little amount of sputum, low-grade fever up to 37.1-37.3°C, weakness, sweating, weight loss of 12 kg within 1 year, defecation to 2-3 times a day (in big volume, foul-smelling, grey colour, with a shiny surface). Smoker (10-12 cigarettes per day). History of alcohol abuse over 8 years, though in the last 3 months before hospitalization the patient confirmed rejection of the use of alcohol, in this connection the special treatment for alcoholism has not been provided to the patient in hospital. Comorbidity was diagnosed with additional examination which revealed chronic pancreatitis with moderate external secretory failure. Other diseases, including HIV, kidney disease, endocrine and parasitic diseases have not been detected.

As for the newly diagnosed pulmonary tuberculosis, the patient was hospitalized to the district tuberculosis dispensary (DTD) in the place of residence.

### Findings upon admission to the DTD

According to the sputum examination (by molecular genetic method, microscopic, Bactec, and later in inoculation) *M. tuberculosis* were found in the patient. In molecular genetic testing, sensitivity to rifampicin was determined. In the drug susceptibility test, sensitivity to all drugs of first-line therapy was determined.

Ultrasound findings: pancreas slightly increased in size: head 27



**Figure 1:** X-ray of the chest upon admission to the DTD: bilaterally in the lungs, mainly in the upper lobes – focal-infiltrative changes, several cavitations of different sizes.

mm, body 25-26 mm, tail 22-23 mm. The width of the main duct 3-4 mm, increased echogenicity of the wall, the lumen is uneven. Contour is unclear, uneven due to local increases. Inhomogeneous structure of parenchyma, with areas of increased and decreased echogenicity.

Laboratory tests showed the presence of:

- I. blood  $\alpha$ -amylase: 180 g/l;
- II. urine  $\alpha$ -amylase: 250 g/l;
- III. blood lipase: 350 mmol/l;
- I<sub>5</sub>. elastase in stool: 120  $\mu$ g/g

Coprological examination: colour greyish; alkaline reaction; muscle

\*Corresponding author: Butov DO, Kharkiv National Medical University, Kharkiv, Ukraine, Tel: 380977723777; E-mail: [dddimid@yandex.ua](mailto:dddimid@yandex.ua)

Received April 13, 2015; Accepted July 02, 2015; Published July 07, 2015

**Citation:** Kuzhko MM, Butov DO, Hulchuk NM, Avramchuk OV, Protsyk LM, et al. (2015) Clinical Case of Using Intravenous Forms of Anti-Tuberculosis Drugs to Improve the Treatment Efficiency of Tuberculosis in Patients with Malabsorption Syndrome. J Pulm Respir Med 5: 269. doi:10.4172/2161-105X.1000269

**Copyright:** © 2015 Kuzhko MM, et al. This is an open-access article distributed under the terms of the Creative Commons Attribution License, which permits unrestricted use, distribution, and reproduction in any medium, provided the original author and source are credited.

fibres unchanged +; muscle fibres modified +++; fibrous connective tissue +; neutral fat +++++; fatty acids; soaps of fatty acids-; intracellular starch ++; cellulose digested +++; cellulose undigested ++; detritus ++; iodophilic flora +++; undigested food ingredients are detected: fat (steatorrhea) and proteins (creatorrhea).

### Prescribed therapy

- I. Standard antimycobacterial therapy per day: isoniazid (H) 0.3 g; rifampicin (R) 0.6 g; pyrazinamide (Z) 2.0 g; ethambutol (E) 1.6 g;
- II. Enzyme replacement therapy: pancreatin 10,000 IU 3 times a day, domperidone 10 mg 3 times a day, omeprazole 20 mg 2 times a day.

On the background of the prescribed treatment, which included standard antimycobacterial therapy and replacement therapy, in 2 months no clinical and laboratory improvement was noted in the patient: clinically accrued intoxication, progression of the process in the form of focal-infiltrative growth changes in the upper-middle section of the left lung (Figure 2) were confirmed.

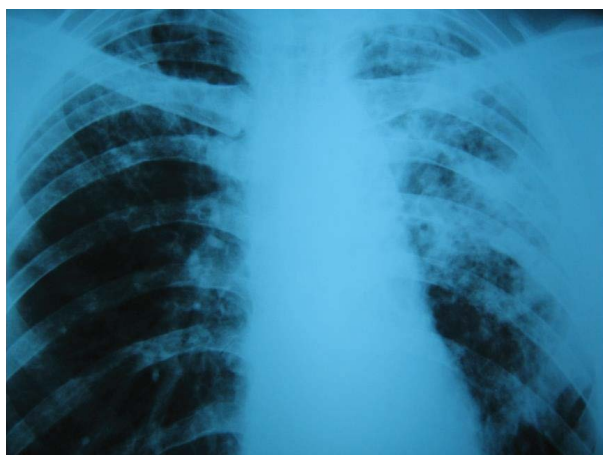Due to enzyme replacement therapy, compensation of externally secretory failure was defined:

- I. defecation – once a day, formed stool
- II. blood  $\alpha$ -amylase: 60 g/l;
- III. urine  $\alpha$ -amylase: 50 g/l;
- I<sub>c</sub>. blood lipase: 7.2 mmol/l;
- ç. elastase in stool: 180  $\mu$ g/g

Coprological examination: colornormal; reaction weakly alkaline; muscle fibres unchanged -; muscle fibres modified +; fibrous connective tissue +; neutral fat ++; fatty acids -: soaps of fatty acids -; intracellular starch +; cellulose digested +; cellulose undigested +; detritus +; iodophilic flora +; undigested food ingredients are detected: fat (steatorrhea) and proteins (creatorrhea).

The patient was sent to the State Institution “F.G. Yanovsky National Institute of Phthisiology and Pulmonology of the National Academy of Medical Sciences of Ukraine” (Institute) for examination and for further treatment.

Upon admission to the Institute, the general condition of the patient was satisfactory. Complaints of coughing with sputum, weakness, sweating.



**Figure 2:** X-ray of the chest after 2 months of treatment.

Due to a prolonged use of ATD, repeated molecular genetic testing was performed and showed preservation of sensitivity to R. We also repeated the inoculation of culture, followed by the formulation of the drug sensitivity test, which confirmed sensitivity to drugs of first-line therapy. However, given the duration of the results of research in the development of the treatment strategy we were more oriented by molecular genetic testing. Due to chemotherapy under direct supervision of medical personnel, it was decided to determine the concentration of some ATD. The blood samples collecting to evaluate the drugs concentrations was provided in different days: on the first day the patient received R and E orally in standard doses, the next day rifamycin sodium salt and E were administered iv in the same doses. The blood samples were drawn five times after oral and injected administration of the drugs: in 10 minutes, in 2 h, 3 h, 4 h and 5 h. All blood samples were centrifuged within 60 min and analyzed immediately in the State certified laboratory at the Institute. The data is presented in the Table 1. Extremely low concentrations of R and E were noted in all the blood samples after oral drugs administration. Such concentrations can be considered as sub-therapeutic [1-3]. After intravenous administration of the studied drugs the peak concentrations exceeded the minimum inhibitory concentrations required.

### Treatment

Given the low concentrations of rifampicin and ethambutol (E) after oral drugs administration, the patient was transferred to the combined administration of antimycobacterial drugs. Intravenous were used: isoniazid (H), rifamycin sodium salt (Riv), ethambutol; orally – pyrazinamide (Z). All drugs were used in pharmacopoeial permissible doses.

The intensive phase of treatment was continued for 60 more doses (total duration of the intensive phase was 60 doses of treatment received in the DTD, and a 60-dose combination therapy with predominant use of antimycobacterial drugs intravenously was prescribed at the Institute). Prolonged administration of intravenous ATD was performed using a permanent catheter.

### Results of the treatment course and follow-up

Within 1 week of treatment with the use of intravenous chemotherapy, the patient's condition was significantly improved: body temperature returned to normal, the patient had an appetite. During the 1st month of observation, a weight gain of 2 kg was determined. Given the pronounced positive clinical and radiological dynamics, absence of acid resistant bacillus in sputum in the examination in terms of control, after receiving 60 doses of combined chemotherapy with some intravenous anti-TB drugs, the patient was transferred to the supporting phase of chemotherapy in the DTD at the place of residence with continuation of intravenous administration of isoniazid and rifamycin sodium salt. Sputum conversion was confirmed on the 2nd month after the administration of drugs by v infusion according to the results of cultural examination. The data is presented in Table 2.

Tolerability of both the intensive and continuation phase of treatment was satisfactory, blood count and blood biochemical findings during observation did not go beyond control values. The data is presented in the Tables 3 and 4. Intravenous administration of some ATD (H, Riv and E) has led to positive dynamics of X-ray which are demonstrated in Figure 3.

The total duration of the treatment was 8 months. The effectiveness of the treatment according to the National standards was classified as “cured.”

	The medicinal product and method of administration			
	Rifampicin (0.6 g)	rifamycin sodium salt (0.6 g)	ethambutol hydrochloride (1.2 g)	
	Orally	i.v.	Orally	i.v.
10 minutes	0	26.54	0	8.36
1 hour	0	16.32	0	3.3
3 hours	0.34	9.31	0.43	1.1
4 hours	0.28	2.58	0.19	0.48
5 hours	0.1	0.93	0	0.3

Table 1: Study of drug concentrations in the blood.

	Month	Microscopy		Inoculation		Sensitivity				
		N	Result	N	Result	H	R	S	E	other
I*	0 TB	110	pos	5709	pos	sens	sens	sens	sens	-
I	2 mon.	258	pos	5844	pos					
II**	2 mon.	14	pos	5844	pos	sens	sens	sens	sens	-
II	3 mon.	11	neg	-	-					
II	4 mon.	5	neg	6175	neg					
I	6 mon.	161	neg		neg					
I	8 mon.	273	neg							

Table 2: Results of sputum examination. \*: Treatment in the DTD \*\*: treatment in National Institute of Phthiology and Pulmonology: 0 TB/Xpert MBT/RIF: DNA of mycobacteria was detected, RIF «-».II: 2 mon./Xpert MBT/RIF: DNA of mycobacteria was detected, RIF «-».

Indicator Month	WBC ×10 <sup>9</sup> /L	RBC ×10 <sup>12</sup> /L	HGB g/l	PLT ×10 <sup>9</sup> /L	LYM %	MON %	GRA %	ESR mm/hr
0 TB/I	11.4	5.14	127	294	17.1	8.0	74.9	6
2 mon./I	11.8	5.35	116	378	16.4	7.0	76.6	15
2 mon./II	12.4	5.38	118	360	16.4	6.4	77.2	11
4 mon./II	8.7	5.36	144	291	19.5	4.3	76.2	6
6 mon./I	9.3	5.26	168	287	16.4	7.0	76.6	3
8 mon./I	8.2	5.7	143	269	12.7	8.7	78.6	3

Table 3: Indicators of blood count.

Indicator Month	Bilirubin µmol/l	Direct bilirubin, µmol/l	ALT to 40 U/l	Urea 2.5-8.3 mmol/L	Creatinine 55-115 µmol/L	Uric acid 185-428 µmol/L	GGT 5-115 mmol/L	alkaline phosphatase U/L	protein g/l	blood glucose mmol/L
0 TB/I	17.5	10.4	11.8	3.76	82.7	-	29.8	-	76.3	6.5
2 mon./I	11.7	3.0	18.1	3.31	74.8	-	27.1	-	73.1	5.7
2 mon./II	11.1	3.2	19.1	3.28	68.4	280.1	27.8	235.7	79.1	5.8
4 mon./II	10.5	3.0	15.8	3.44	81.3	335.7	26.2	136.9	79.3	6.3
6 mon./I	14.5	3.2	22.3	4.9	84.4	-	31.2	-	78.2	6.2
8 mon./I	13.2	3.1	21.7	5.11	90.5	-	30.4	-	76.8	6.0

Table 4: Indicators of biochemical blood tests.

The duration of the follow-up after applying the full course of treatment was 6 months. During the specified time, the observed patient underwent clinical, laboratory and X-ray examinations. No signs of recurrence were found.

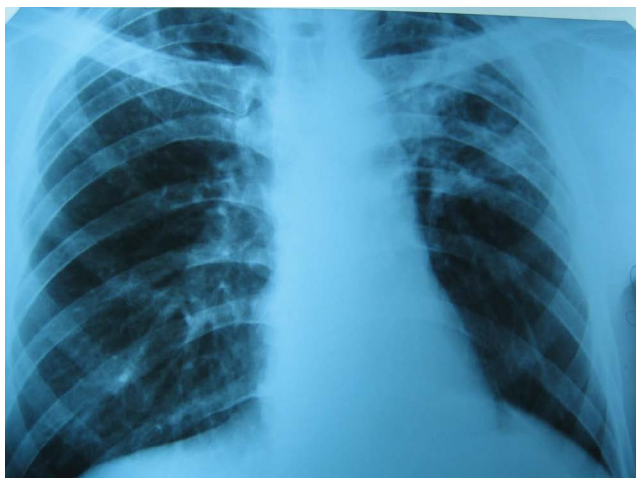### Review of the clinical case

Even with adequate chemotherapy (including drug susceptibility tests, using drugs in the required quantities and doses, accountability to treatment) the presence of comorbidities in the patient, inability to create in the blood and tissues optimal drug concentrations due to the violation of their absorption in the gastrointestinal tract or their rapid inactivation, lead to a decrease in the effectiveness of the treatment [4].

The use of controlled treatment and additional treatment regimens

(for the treatment of comorbidities), in its majority leads to positive dynamics of disease (as sputum conversion) and to a cure of this disease. Though there is a limited number of patients in which there is no expected positive response to the used therapy is noted. Possible lack of a positive response may be associated with the malabsorption syndrome [5,6]. A difference of obtained susceptibility to ATD in the patient's sputum and in the focal lesion ("hidden" drug resistance) should be considered as one of the causes of therapy inefficiency, diagnosing of which has great complexity and is possible only with the results of the culture examination of postoperative material [7].

Late detection of "hidden" resistance of M. tuberculosis to anti-TB drugs used in TB treatment leads to a steady propagation of resistant populations, and low concentrations of antimycobacterial drugs in the



**Figure 3:** X-ray of the chest after 8 months of treatment: in the background metastatic tuberculosis pneumofibrosis, mainly in the upper sections focal-infiltrative changes that continue to dissolve and thicken, cavitations decreased in size, the walls became thinner.

patient's blood. As a result, malabsorption leads to the formation of a large number of "mutant" strains, an increase in drug resistance and disease progression [8-10].

Thus, clinical signs or conditions that can lead to malabsorption syndrome should be determined in patients with the absence of a "positive response" to treatment, and their combination with low concentrations of anti-tuberculosis drugs in the blood can serve as a criterion for a change of treatment.

In some cases, the oral anti-TB therapy cannot be considered as the first choice due to a number of factors that reduce the bioavailability (vomiting, diarrhea, the effect of initial passage through the liver, morphological and functional state of the gastrointestinal tract, the effect of induction of intestinal enzymes, etc.), but intravenous administration of some drugs eliminates these factors resulting in 100 % bioavailability.

Clinical and experimental studies have established that the therapeutic effect of antimycobacterial drugs is directly dependent on the level of drug concentration in the blood, and hence in the focal lesion of specific inflammation [11,12]. It has been proven that including even one ATD to the antimycobacterial therapy regimen by parenteral administration in the intensive phase can increase the effectiveness of treatment [13-15].

Although the National treatment protocol of patients with pulmonary tuberculosis does not provide the definition of concentration levels created by ATD in the blood, the present clinical case shows the need for an individualized approach in choosing tactics for treating patients in the absence of a positive response.

Since identifying causal factors cannot lead to the elimination of malabsorption syndrome even if the reduction or complete disappearing of clinical signs of this disease on the background of replacement therapy, some anti-TB drugs in intravenous form may become an alternative choice. The present clinical case describes the possibility of a prolonged use of intravenous chemotherapy in patients with newly diagnosed pulmonary tuberculosis with malabsorption syndrome.

## Conclusions

The absence of a positive response in the application of appropriate antimycobacterial therapy may be associated with malabsorption syndrome.

Compensation of pancreatic function after replacement therapy does not always lead to increased bioavailability of drugs used orally.

Since malabsorption syndrome is connected with many diseases, the best way to achieve the therapeutic goal is to determine in patients with the absence of positive response to treatment, the most common malabsorption causes with simultaneous determination of the level of anti-TB drugs in the blood.

The use of some intravenous of ATD throughout the course of treatment with concomitant malabsorption is the treatment of choice.

## Acknowledgements

This work was supported by the State Institution "National Institute for Tuberculosis and Pulmonology named after F.G. Yanovsky of the National Academy of Medical Sciences of Ukraine".

## References

1. Hirsch S, Chaves G, Gotteland M, de la Maza P, Petermann M, et al. (1997) [Intestinal permeability in alcoholic patients without liver damage]. *Rev Med Chil* 125: 653-658.
2. Kimerling ME, Phillips P, Patterson P, Hall M, Robinson CA, et al. (1998) Low serum antimycobacterial drug levels in non-HIV-infected tuberculosis patients. *Chest* 113: 1178-1183.
3. Peloquin CA, MacPhee AA, Berning SE (1993) Malabsorption of antimycobacterial medications. *N Engl J Med* 329: 1122-1123.
4. Lienhardt C, Vernon A, Raviglione MC (2010) New drugs and new regimens for the treatment of tuberculosis: review of the drug development pipeline and implications for national programmes. *Curr Opin Pulm Med* 16: 186-193.
5. Owens SR, Greenson JK (2007) The pathology of malabsorption: current concepts. *Histopathology* 50: 64-82.
6. Othman M, Agüero R, Lin HC (2008) Alterations in intestinal microbial flora and human disease. *Curr Opin Gastroenterol* 24: 11-16.
7. Chukanov VI (2001) Scientific works of the 75th anniversary of the leading anti-TB institutions of Moscow 117-122.
8. Rattan A, Kalia A, Ahmad N (1998) Multidrug-resistant *Mycobacterium tuberculosis*: molecular perspectives. *Emerg Infect Dis* 4: 195-209.
9. Sterling TR, Lehmann HP, Frieden TR (2003) Impact of DOTS compared with DOTS-plus on multidrug resistant tuberculosis and tuberculosis deaths: decision analysis. *BMJ* 326: 574.
10. Musser JM (1995) Antimicrobial agent resistance in mycobacteria: molecular genetic insights. *Clin Microbiol Rev* 8: 496-514.
11. Nuermberger E, Grosset J (2004) Pharmacokinetic and pharmacodynamic issues in the treatment of mycobacterial infections. *Eur J Clin Microbiol Infect Dis* 23: 243-255.
12. Gumbo T, Louie A, Deziel MR, Liu W, Parsons LM, et al. (2007) Concentration-dependent *Mycobacterium tuberculosis* killing and prevention of resistance by rifampin. *Antimicrob Agents Chemother* 51: 3781-3788.
13. Karpin NL (2010) Efferent therapy in the treatment of patients with pulmonary tuberculosis drug resistant mycobacteria. *Tuberculosis and Lung Disease* 3: 28-33.
14. Mishin V, Yu (2011) The effectiveness of the treatment of patients with destructive pulmonary tuberculosis with parenteral and oral administration of anti-TB drugs. *Pulmonology* 1: 55-59.
15. Boff DF, Goldani LZ (2013) Initial combination of injectable and oral anti-tuberculosis agents for the treatment of severe disseminated tuberculosis. *Trop Doct* 43: 148-150.