




## REPORTS OF MORPHOLOGY

Official Journal of the Scientific Society of Anatomists,  
Histologists, Embryologists and Topographic Anatomists  
of Ukraine

journal homepage: <https://morphology-journal.com>



# Fractal dimension of skeletonized MR images as a measure of cerebral hemispheres spatial complexity

Maryenko N. I., Stepanenko O. Yu.

Kharkiv National Medical University, Kharkiv, Ukraine

### ARTICLE INFO

Received: 11 February 2022

Accepted: 17 March 2022

UDC: 611.813:57.086:517:530.191

### CORRESPONDING AUTHOR

e-mail: [maryenko.n@gmail.com](mailto:maryenko.n@gmail.com)

Maryenko N. I.

### CONFLICT OF INTEREST

The authors have no conflicts of interest to declare.

### FUNDING

Not applicable.

*In recent decades, fractal analysis has been increasingly used in various scientific fields, including neuroscience; this method of mathematical analysis allows you to quantify the space filling degree of the studied object and the degree of its spatial configuration complexity. The aim of the study was to determine the values of the fractal dimension of the cerebral hemispheres using fractal analysis of skeletonized magnetic resonance brain images. The present study used magnetic resonance brain images of 100 relatively healthy individuals (who had no structural changes in the brain) of both sexes (56 women, 44 men) aged 18-86 years (mean age 41.72±1.58 years). 5 tomographic sections of each brain were studied. The 1st coronal tomographic section was located at the level of the most anterior points of the temporal lobes, the 2nd - at the level of the mammillary bodies, the 3rd - at the level of the quadrigeminal plate, the 4th - at the level of the splenium of corpus callosum. The axial tomographic section was located at the level of the thalamus. Fractal analysis of skeletonized images was performed using box counting method. The obtained data were processed using generally accepted statistical methods. The average, minimum and maximum values of the fractal dimension of different tomographic sections were the following: 1st coronal section - 1.207±0.003 (1.147÷1.277), 2nd coronal section - 1.162±0.003 (1.077÷1.243), 3rd coronal section - 1.156±0.003 (1.094÷1.224), 4th coronal section - 1.158±0.003 (1.109÷1.218), axial section - 1.138±0.002 (1.079÷1.194). The average value of the fractal dimension of the five tomographic sections was 1.164±0.002 (1.126÷1.209), and the average value of the fractal dimension of the four coronal sections was 1.171±0.002 (1.122÷1.219). Fractal analysis of skeletonized images of the cerebral hemispheres allows to quantify the features of the topology and complexity of the spatial configuration of the cerebral hemispheres. The value of the fractal dimension can be influenced by the anatomical features of the studied areas of the brain, individual anatomical features, as well as atrophic and other pathological changes that lead to changes in the shape of the cerebral hemispheres. The values of the fractal dimension of skeletonized brain images tend to decrease with age. Coronal tomographic sections are the most representative for characterizing age-related atrophic changes. Fractal analysis of skeletonized images of the cerebral hemispheres can be used to diagnose diseases of the nervous system, and the results of the present study can be used as norm criteria.*

**Keywords:** fractal analysis, fractal dimension, brain, cerebral hemispheres, morphometry.

### Introduction

The brain is one of the most complex structures of the human body, and the study of its morphology is devoted to a huge number of scientific papers: from classical anatomical research to innovative research in modern neuroscience. In recent decades, diagnostic methods of neuroimaging, including magnetic resonance imaging, have become increasingly common. These methods allow us to study the

lifelong morphology of brain structures, which is important not only for classical morphological studies, but also for the diagnosis of many diseases of the nervous system.

Various morphometric methods are often used in neuromorphological research (including the use of neuroimaging methods) to objectify them and increase information. Most often, morphometry involves measuring

the linear size, area, volume of different structures and pathological foci and the calculation of various indices and indicators based on these parameters [19]. Most methods of morphometry are based on Euclidean geometry and are quite informative in the study of structures with geometrically simple shapes. However, the spatial configuration of brain hemispheres is not geometrically correct, so it is difficult to characterize using traditional methods of morphometry.

In recent decades, many natural sciences, including neuroscience, are increasingly using methods of fractal geometry, namely fractal analysis [2, 3, 14]. This method of mathematical analysis allows you to quantify the degree of filling of space by the object and the degree of complexity of its spatial configuration [10, 14]. Given this, the use of fractal analysis for morphometric study of the cerebral hemispheres is appropriate and informative, as quantitative characterization of the shape will assess both individual anatomical features that affect the configuration of the hemispheres and the presence of age or pathological changes in the brain [2].

To characterize the spatial configuration of different biological structures using fractal analysis, three types of images are most often used - silhouette (corresponding to the silhouette of the structure as a whole), outlined (to characterize the configuration of the contour, boundary or surface of the structure) and skeletonized [10]. The last type of images involves the procedure of skeletonization, which allows to obtain a digital skeleton of the studied structure by eroding the silhouette image [8, 10, 16, 17].

Skeletonization is most often used as a pre-treatment method for quantitative analysis (including fractal analysis) of dendritic tree neurons and other tree-like branched and reticulate structures [8, 10, 16, 17]. In these cases, skeletonization allows to level the thickness of the branches of branched structures and to characterize the degree of their branching. In our previous studies [15] and in the studies of other authors [13], fractal analysis of skeletal images of arbor vitae cerebelli was performed.

Other irregular structures that do not have a clear tree-like configuration can also be skeletonized. Such structures include brain hemispheres. In these cases, the skeletonization procedure detects the vertices of a certain figure (for example, the vertices of the convolutions of the cerebral hemispheres) and builds a network that connects all the detected vertices in the shortest segments and fills the space inside the silhouette. Despite the fact that brain hemispheres do not have the classical tree-like configuration, skeletalization of brain images has been useful for both fractal analysis and other methods of image analysis. Skeletonization is currently used as a pre-processing method to analyze magnetic resonance imaging of the cerebral hemispheres using the method of "Peak Width of Skeletonized Mean Diffusivity" [1], which in recent years has been used to detect diffuse pathological changes in vascular diseases of the brain, including diseases of small vessels [1, 7]. Skeletonization is also used for fractal

analysis of the structures of the cerebral hemispheres as a method of image pre-processing. The vast majority of such studies used the construction of a digital skeleton of white matter [4, 6, 20, 21, 24-26]. Skeletonization and fractal analysis can be used not only to study white matter, but also to study brain hemispheres as a whole. But studies of skeletal images of brain hemispheres in general have not yet been conducted (according to the available scientific literature). Given the lack of such studies and the great clinical significance of neuromorphological studies, we decided to choose the brain hemispheres as a whole as the object of study.

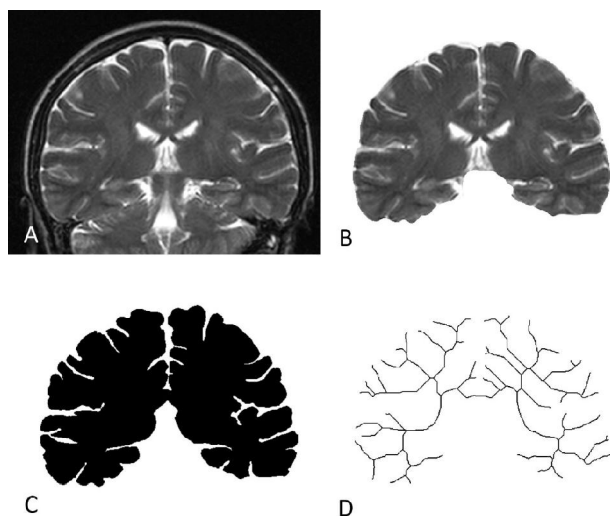
*The aim of the study* is to determine the value of the fractal dimension of the cerebral hemispheres using fractal analysis of skeletonized magnetic resonance imaging of the brain.

### Materials and methods

The study was conducted in compliance with the basic bioethical provisions of the Council of Europe Convention on Human Rights and Biomedicine (04.04.1997), the Helsinki Declaration of the World Medical Association on ethical principles of scientific medical research with human participation (1964-2008), and the Ministry of Health of Ukraine № 690 from 23.09.2009. The conclusion of the Commission on Ethics and Bioethics of Kharkiv National Medical University confirms that the study was conducted in compliance with human rights, in accordance with current legislation in Ukraine, meets international ethical requirements and does not violate ethical norms in science and standards of biomedical research (Minutes of the meeting of the Commission on Ethics and Bioethics of Kharkiv National Medical University № 10 dated November 7, 2018).

Magnetic resonance (MR) tomograms of 100 relatively healthy individuals brain (who did not have structural changes in the brain) of both sexes (women 56, men 44) aged 18-86 years (mean age  $41.72 \pm 1.58$  years) were used for the study. MR images were obtained using a Siemens Magnetom Symphony magnetic resonance imaging scanner with a magnetic induction value of 1.5 T. T2 and FLAIR modes with the following parameters were used: T2 mode - TE (echo time) 130 ms, TR (repetition time) 4440 ms, slice thickness - 5 mm; mode FLAIR - TE (echo time) 114 ms, TR (repetition time) 9000 ms, TI (inversion time) - 2500 ms; the thickness of the cut - 5 mm.

To examine each brain, 5 tomographic sections were selected, including four sections in coronal (frontal) projection and one section in axial (horizontal) projection. We chose tomographic sections that correspond to different parts of the cerebral hemispheres and are easily identifiable by anatomical landmarks, these sections correspond to areas of the brain where pathological lesions of the brain are most common in some neurodegenerative diseases, including Alzheimer's disease [11]. The 1st coronal tomographic section was located at the level of the anterior points of the



**Fig. 1.** Pre-processing of magnetic resonance imaging of the brain: A - original T-2 weighted MR image, B - removal of background structures, C - image segmentation with conversion to binary format, D - skeletonization of the image.

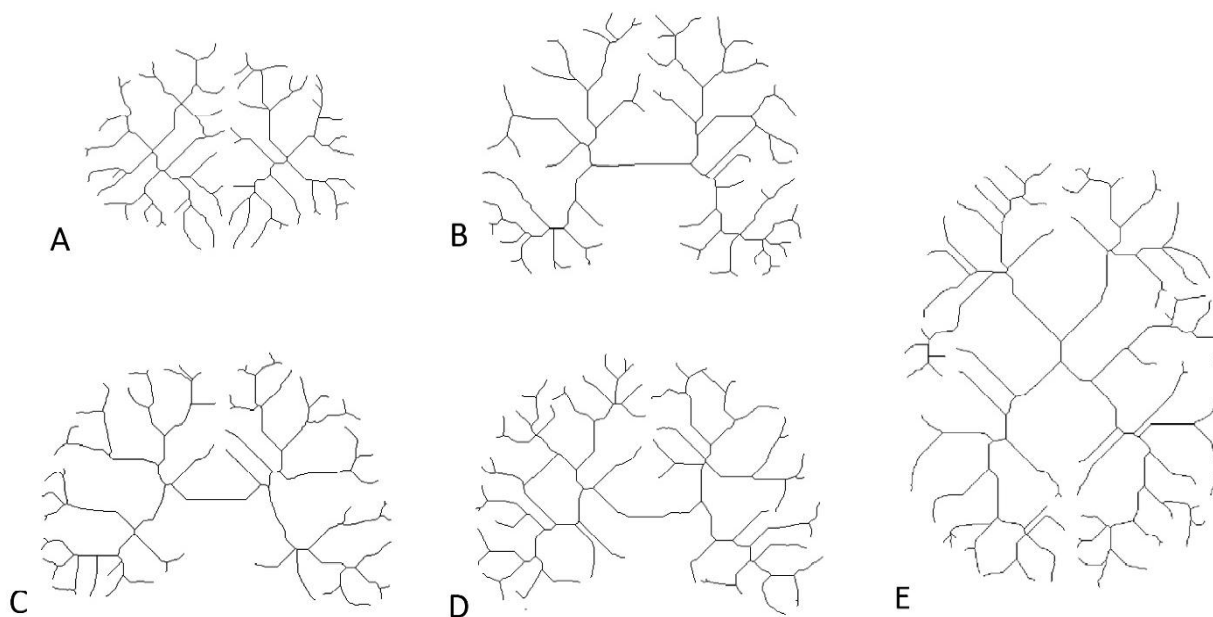
temporal lobes, the 2nd - at the level of corpus mamillare, the 3rd - at the level of lamina quadrigemina, the 4th - at the level of splenium corpori callosi. The axial tomographic section was located at the level of the thalamus.

After selecting the images, they were pre-processed (Fig. 1). The Adobe Photoshop CS5 graphics editor created images with a resolution of 128 pixels per inch and the following dimensions: 512x400 pixels for coronal sections and 512x800 pixels for axial sections. A fragment of the digital tomographic image corresponding to the study area was inserted into the previously created image, and this fragment was placed so that the tomographic section of the cerebral

hemispheres was completely placed in the created image and did not go beyond it (see Fig. 1A).

The next stage of preliminary preparation was the segmentation of images with their conversion into binary format. Initially, the background structures were removed from the image (see Figure 1B). For this purpose, pixels that do not correspond to the studied structure (tomographic section of the hemispheres) were colored white (for T2-weighted images) or black (for images obtained in FLAIR mode). Next, Adobe Photoshop CS5's "threshold" tool was used for preliminary ("rough") segmentation. Pixel brightness threshold processing was performed: all pixels with a brightness value less than the specified threshold value were colored black, the remaining pixels were colored white. For images obtained in T2 mode, a median threshold value of 128 was used, with the pixels corresponding to the brain tissue stained black and the rest white. For images obtained in FLAIR mode, an empirical brightness threshold of 65 was used, with the pixels corresponding to the brain tissue stained white and the rest black. After the previous "rough" segmentation with the help of manual correction, precise segmentation was performed to improve the anatomical accuracy of the obtained images, using the tools of the program "Adobe Photoshop CS5". Thus, as a result of MR image segmentation, we obtained binary silhouette images of the cerebral hemispheres (see Fig. 1C).

For further stages of image processing and analysis, the Image J program was used [23]. Binary silhouette images were skeletonized using the "skeletonize" tool (see Figure 1D). The line thickness of the digital skeleton formed with this tool was 1 pixel. This tool was used to process each of the five selected tomographic sections of the cerebral hemispheres (Fig. 2).



**Fig. 2.** Skeletonized images of the cerebral hemispheres: A - 1st coronal section, B - 2nd coronal section, C - 3rd coronal section, D - 4th coronal section, E - axial section.

**Table 1.** Statistical parameters of the distribution of fractal dimension (FD) values of cerebral hemispheres skeletonized images.

Tomographic section	M	m	s	CV, %	Min	Percentile 25	Me (percentile 50)	Percentile 75	Max
Coronal 1	1.207	0.003	0.027	2.27	1.147	1.186	1.210	1.227	1.277
Coronal 2	1.162	0.003	0.031	2.70	1.077	1.136	1.162	1.184	1.243
Coronal 3	1.156	0.003	0.029	2.47	1.094	1.137	1.152	1.177	1.224
Coronal 4	1.158	0.003	0.026	2.26	1.109	1.139	1.155	1.176	1.218
Axial	1.138	0.002	0.023	2.04	1.079	1.122	1.139	1.152	1.194
Average (all sections)	1.164	0.002	0.018	1.56	1.126	1.150	1.163	1.179	1.209
Average (1-4 coronal)	1.171	0.002	0.021	1.79	1.122	1.157	1.168	1.185	1.219

After skeletalization, fractal analysis of images was performed using the box counting method, using the "fractal box count" tool of the Image J. program. Fractal dimension (FD) values of skeletonized tomographic images of five different locations were determined in the MR tomogram of each brain (see Fig. 2). The mean FD values of all five sections and the average FD values of four coronal sections were also calculated for each brain.

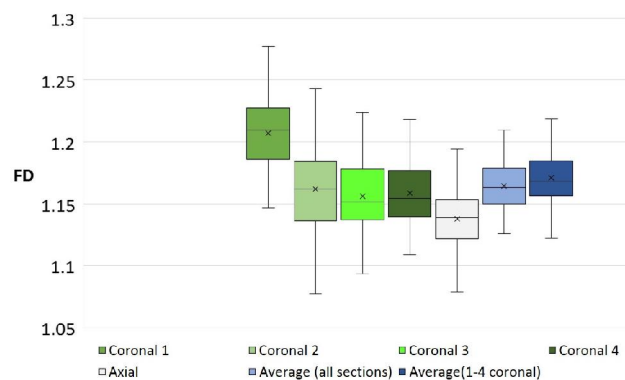
Statistical data processing was performed using Microsoft Excel 2016. Data were processed using variation statistics. The following statistical parameters were calculated for each variation series: arithmetic mean (M), its error (mM), standard deviation ( $\sigma$ ) and coefficient of variation (CV). To determine the peculiarities of the distribution of fractal dimension values, the median (Me), the values of the 25th and 75th percentiles, the minimum (min) and maximum (max) values were determined. The distribution of values for normality was checked using the Shapiro-Wilk W test. The significance of statistical differences between the fractal dimensions of tomographic sections of different localization was assessed using the Kruskal-Wallis KW test with Bonferroni correction and the post-hoc Dunn test for multiple comparisons. To determine the relationship between the values obtained, the Pearson correlation coefficient (r) was calculated, the significance of which was assessed using the Student's t test.

## Results

The distribution of fractal dimensional (FD) values of skeletal images of tomographic sections of five localizations, as well as average FD values of five tomographic sections and average FD values of four coronal sections are shown in Table 1 and Figure 3. When checking the distribution of FD values for normality it was found that the distributions of FD values of the 1st coronal section ( $p=0.674$ ), 2nd coronal section ( $p=0.331$ ), 3rd coronal section ( $p=0.166$ ) and axial section ( $p=0.823$ ) did not differ statistically significantly from the normal distribution. The difference in the distribution of FD values of the 4th coronal section from the normal distribution was questionable ( $p=0.084$ ). The distributions of the mean FD values of the five sections and the mean FD values of the four coronal sections also did not differ statistically significantly from the normal distribution ( $p=0.451$  and  $p=0.283$ , respectively).

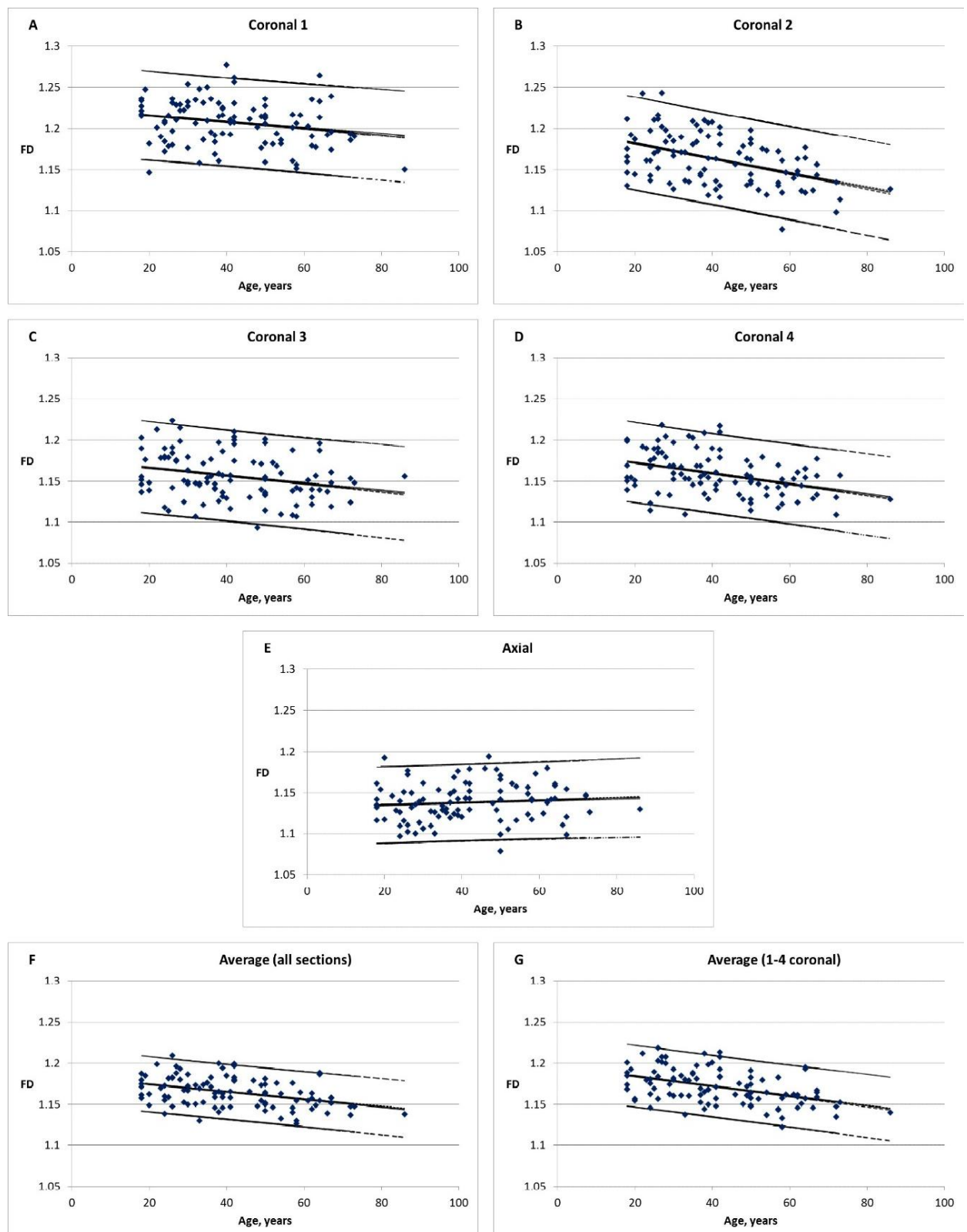
The nonparametric Kruskal-Wallis test was chosen to compare the FD values of five tomographic sections. The calculated value of p was less than the specified threshold level of significance  $\alpha$  ( $\alpha=0.050$ ,  $p>0$ ), therefore, the null hypothesis ( $H_0$  hypothesis) about the lack of differences between the studied samples can be refuted.

To find out which samples were statistically significantly different, we made pairwise comparisons using the Dunn post-hoc test. We chose the level of statistical significance  $\alpha=0.050$ , which with the Bonferroni correction for multiple comparisons was  $\alpha=0.005$ . It was found that the FD values of the 1st coronal section were statistically significantly different from the FD values of all other tomographic sections ( $p<0.001$ ), as well as the FD values of the axial section ( $p<0.001$ ). However, no statistically significant differences were found between the FD values of the following pairs of coronal sections: 2nd and 3rd ( $p=0.202$ ), 2nd and

**Fig. 3.** Distribution of fractal dimensional (FD) values of skeletonized images of the cerebral hemispheres.**Table 2.** Correlation relationships of fractal dimension values of skeletonized images of cerebral hemispheres.

	Coronal 1	Coronal 2	Coronal 3	Coronal 4	Axial
Coronal 1	-	0.40#	0.25*	0.29*	0.01
Coronal 2	0.40#	-	0.46#	0.43#	0.14
Coronal 3	0.25*	0.46#	-	0.51#	0.25*
Coronal 4	0.29*	0.43#	0.51#	-	0.10
Axial	0.01	0.14	0.25*	0.10	-

**Note:** the table shows the values of the Pearson correlation coefficients (r); \* -  $p<0.01$ ; # -  $p<0.001$ .



**Fig. 4.** Distribution of fractal dimensional (FD) values of different parts of the brain and confidence intervals of FD values; A - 1st coronal section, B - 2nd coronal section, C - 3rd coronal section, D - 4th coronal section, E - axial section, F - mean FD of all five sections, G - average value of 4 coronal sections FD; the level of significance selected for the calculation of confidence intervals of values - 95 %,  $p < 0.05$ .

4th ( $p=0.477$ ), 3rd and 4th ( $p=0.572$ ).

Correlation analysis of FD values of five tomographic sections was also performed (Table 2). It was found that the FD values of coronal sections were associated with a statistically significant positive correlation between medium and low strength. A stronger correlation was found between the FD values of adjacent coronal sections: 3rd and 4th, 2nd and 3rd, 1st and 2nd. Axial section FD values were not strongly correlated with coronal section FD values. A statistically significant positive correlation of axial section FD values was found only with FD values of the 3rd coronal section; with FD values of the rest of the coronal sections statistically significant correlation was not detected ( $p>0.05$ ).

Because the age range of the subjects was quite wide, ranging from 18 to 86 years, we investigated whether the values of the fractal dimension of skeletal images of the cerebral hemispheres change with age. As can be seen from the data in Figure 4, the FD values of different sections had a general tendency to decrease with age. The FD values of the coronal sections had a statistically significant negative correlation with age, while the FD values of the 1st and 3rd coronal sections had a weak correlation with age (respectively  $r=-0.22$ ,  $p<0.05$  and  $r=-0.26$ ,  $p<0.01$ ), and the 2nd and 4th sections - correlation of medium strength (respectively  $r=-0.45$ ,  $p<0.001$  and  $r=-0.39$ ,  $p<0.001$ ). In contrast to coronal sections, the FD values of the axial section did not have a statistically significant correlation with age ( $r=0.09$ ,  $p>0.05$ ). The mean FD values of all five tomographic sections and the mean FD values of the four coronal sections had a statistically significant negative correlation with age of medium strength (respectively  $r=-0.40$ ,  $p<0.001$  and  $r=-0.46$ ,  $p<0.001$ ).

## Discussion

Brain hemispheres are the subject of a number of different studies using fractal analysis due to the irregularity of their shape, as well as the clinical significance of quantitative characterization of the complexity of the spatial configuration of brain structures [2]. For fractal analysis of cerebral hemispheres structures, various techniques are used, which involve the analysis of different types of images (silhouette, outlined and skeletonized). Different authors studied different structures and parts of large hemispheres. In the vast majority of works to characterize atrophic changes of the brain fractal analysis of the cortex as a whole [5, 11, 22] and the surface of the brain [9, 12], including - analysis of the skeletal surface of hemispheres [12]. A number of studies have performed fractal analysis of the white matter of the cerebral hemispheres, including their silhouettes or tissue as a whole [6, 18, 26], contours or surfaces (linear boundary between the cortex and white matter) [6, 26] and skeletonized images [4, 6, 20, 21, 24-26]. Studies using fractal analysis of skeletal images of the white matter of the cerebral hemispheres are closest to our study. But the skeletonization of the white matter of the cerebral hemispheres used in these studies involves the use of complex image

segmentation algorithms, as it requires anatomically accurate separation of white matter and cortex. Therefore, the use of silhouette images of the cerebral hemispheres as a whole (including gray matter, white matter and cerebrospinal fluid inside the ventricles) with their subsequent skeletonization helps to simplify segmentation algorithms, and also allows to assess the spatial configuration of not only white matter but also the cerebral hemispheres in general.

Fractal analysis of skeletal images of both white matter and hemispheres of the brain as a whole provides a quantitative assessment of the topology of brain hemispheres. The digital skeleton repeats the configuration of the structure as a whole and has the same topology as the silhouette image. Therefore, the analysis of the digital skeleton makes it possible to assess how white matter and large hemispheres of the brain as a whole fill the space, eliminating the influence of the area of the silhouette image.

Fractal analysis of skeletal images also provides a quantitative characterization of the degree of spatial complexity and anatomical features of brain hemispheres. The number and density of convolutions visualized on tomographic sections may differ in different individuals and in different parts of the brain. The more vertices (convolutions) the silhouette image has, the more complex the configuration of its digital skeleton will be and the greater will be the value of its fractal dimension. The values of the fractal dimension determined by us as a result of this study may differ significantly in different individuals with close or the same age in the study of tomographic sections of the same localization (see Fig. 4). It can be assumed that the difference in FD values in these cases is significantly influenced by the peculiarities of individual anatomical variability. In addition, FD values may differ depending on the location and orientation of the tomographic section (including differences in FD values in the same person). This may indicate that the value of FD is also influenced by the anatomy of different parts of the brain (see Fig. 2). Thus, the FD values of skeletal images can reflect both individual and regional anatomical features of the cerebral hemispheres.

In addition to characterizing the anatomical features, fractal analysis of the digital skeleton of the white matter of brain hemispheres can detect changes in some diseases and pathological conditions. This method of research revealed changes after acute cerebrovascular disorders [24], after traumatic brain injury [20], multiple sclerosis [4] and amyotrophic lateral sclerosis [21]. This indicates the possibility of using this method of research to diagnose some diseases of the nervous system.

Age-related changes in the brain are of great importance for the development of normative criteria, which, in turn, can affect the value of the fractal dimension of skeletal images. Traditional morphometric methods based on Euclidean geometry have revealed a decrease in the gray and white matter of the brain; these features reflect the dynamics of



atrophic changes in the brain as a whole [19]. Using fractal methods, a statistically significant decrease in the values of the fractal dimension of the digital skeleton of white matter during normal aging was found [6, 25, 26], which is consistent with our data. Atrophic changes in the cortex and white matter of the cerebral hemispheres can change their spatial configuration, which in turn can affect the configuration of the digital skeleton - reducing the number and shortening of branches, reducing the number of connections, and so on. This simplification of the spatial configuration is reflected in the reduction of the fractal dimension of skeletal images.

According to our data, the FD values of coronal tomographic sections were more representative for characterizing age-related changes than the FD values of the axial section. In the work of King R. D. et al. [11] to study pathological atrophic changes in Alzheimer's disease, a fractal analysis of the cerebral cortex was performed; coronal sections of the same localization as in our study were studied; axial sections of three different localizations were also investigated. It was found that the difference between the FD values of the cerebral cortex of the control group and patients with Alzheimer's disease was greater in the study of coronal sections than in the study of axial sections. This data is consistent with the data we have received.

Given that the average FD value of the four coronal sections has a stronger correlation with age than the average FD value of all five tomographic sections, and given the lack of a statistically significant correlation between the FD values of the axial section and age, it is possible to consider that the most representative indicator for characterization of age changes is the average value of FD of four coronal sections. This value has the strength of the correlation with age, comparable to the greatest strength

of the correlation of a separate (2nd) tomographic section with age (respectively  $r=-0.46$  and  $r=-0.45$ ) and exceeds the strength of the correlation with age other coronal sections (1st, 3rd and 4th). Thus, averaging the values of coronal sections allows to obtain a supertotal effect, as it reduces the impact of errors, artifacts of tomography and processing of tomographic sections, as well as individual anatomical features. We calculated 95 % confidence intervals of FD values, which can then be used as age criteria (see Fig. 4).

A promising area of further research is the quantitative analysis of digital skeletons of the cerebral hemispheres and traditional morphometry to determine the factors influencing the value of the fractal dimension and, consequently, the complexity of the spatial configuration of the cerebral hemispheres.

## Conclusion

1. Fractal analysis of cerebral hemispheres skeletonized images allows to quantify the features of the topology and complexity of cerebral hemispheres spatial configuration.

2. The value of the fractal dimension can be influenced by the anatomical features of the studied areas of the brain, individual anatomical features, as well as atrophic and other pathological changes that lead to changes in the shape of the cerebral hemispheres. The values of the fractal dimension of skeletal images of the brain tend to decrease with age.

3. Coronal tomographic sections are the most representative for the characterization of age-related atrophic changes.

4. The obtained data can be used as normative criteria for the diagnosis of diseases of the nervous system using diagnostic methods of neuroimaging.

## References

- [1] Baykara, E., Gesierich, B., Adam, R., Tuladhar, A. M., Biesbroek, J. M., Koek, H. L., ... & Duering, M. (2016). A Novel Imaging Marker for Small Vessel Disease Based on Skeletonization of White Matter Tracts and Diffusion Histograms. *Annals of neurology*, 80(4), 581-592. doi: 10.1002/ana.24758
- [2] Di Ieva, A., Esteban, F. J., Grizzi, F., Klonowski, W., & Martin-Landrove, M. (2015). Fractals in the neurosciences, part II: clinical applications and future perspectives. *The Neuroscientist*, 21(1), 30-43. doi: 10.1177/1073858413513928
- [3] Di Ieva, A., Grizzi, F., Jelinek, H., Pellionisz, A. J., & Losa, G. A. (2014). Fractals in the neurosciences, part I: general principles and basic neurosciences. *The Neuroscientist*, 20(4), 403-417. doi: 10.1177/1073858413513927
- [4] Esteban, F. J., Sepulcre, J., de Mendizabal, N. V., Goñi, J., Navas, J., de Miras, J. R., ... & Villoslada, P. (2007). Fractal dimension and white matter changes in multiple sclerosis. *NeuroImage*, 36(3), 543-549. doi: 10.1016/j.neuroimage.2007.03.057
- [5] Esteban, F. J., Sepulcre, J., de Miras, J. R., Navas, J., de Mendizabal, N. V., Goñi, J., ... & Villoslada, P. (2009). Fractal dimension analysis of grey matter in multiple sclerosis. *Journal of the neurological sciences*, 282(1-2), 67-71. doi: 10.1016/j.jns.2008.12.023
- [6] Farahibozorg, S., Hashemi-Golpayegani, S. M., & Ashburner, J. (2015). Age- and sex-related variations in the brain white matter fractal dimension throughout adulthood: an MRI study. *Clinical neuroradiology*, 25(1), 19-32. doi: 10.1007/s00062-013-0273-3
- [7] Frey, B. M., Petersen, M., Schlemm, E., Mayer, C., Hanning, U., Engelke, K., ... & Cheng, B. (2021). White matter integrity and structural brain network topology in cerebral small vessel disease: The Hamburg city health study. *Human brain mapping*, 42(5), 1406-1415. doi: 10.1002/hbm.25301
- [8] Greenblum, A., Sznitman, R., Fua, P., Arratia, P. E., Oren, M., Podbilewicz, B., & Sznitman, J. (2014). Dendritic tree extraction from noisy maximum intensity projection images in *C. elegans*. *Biomedical engineering online*, 13, 74. doi: 10.1186/1475-925X-13-74
- [9] Ha, T. H., Yoon, U., Lee, K. J., Shin, Y. W., Lee, J. M., Kim, I. Y., ... & Kwon, J. S. (2005). Fractal dimension of cerebral cortical surface in schizophrenia and obsessive-compulsive disorder. *Neuroscience letters*, 384(1-2), 172-176. doi: 10.1016/j.neulet.2005.04.078
- [10] Jelinek, H. F., & Fernandez, E. (1998). Neurons and fractals: how reliable and useful are calculations of fractal dimensions?. *Journal of neuroscience methods*, 81(1-2), 9-

18. doi: 10.1016/s0165-0270(98)00021-1
- [11] King, R. D., George, A. T., Jeon, T., Hynan, L. S., Youn, T. S., Kennedy, D. N., ... & the Alzheimer's Disease Neuroimaging Initiative (2009). Characterization of Atrophic Changes in the Cerebral Cortex Using Fractal Dimensional Analysis. *Brain imaging and behavior*, 3(2), 154-166. doi: 10.1007/s11682-008-9057-9
- [12] Lee, J. M., Yoon, U., Kim, J. J., Kim, I. Y., Lee, D. S., Kwon, J. S., & Kim, S. I. (2004). Analysis of the hemispheric asymmetry using fractal dimension of a skeletonized cerebral surface. *IEEE transactions on bio-medical engineering*, 51(8), 1494-1498. doi: 10.1109/TBME.2004.831543
- [13] Liu, J. Z., Zhang, L. D., & Yue, G. H. (2003). Fractal dimension in human cerebellum measured by magnetic resonance imaging. *Biophysical journal*, 85(6), 4041-4046. doi: 10.1016/S0006-3495(03)74817-6
- [14] Mandelbrot, B. B. (1983). *The fractal geometry of nature*. N.Y.: W. H. Freeman&Co.
- [15] Maryenko, N., & Stepanenko, O. (2021). Characterization of white matter branching in human cerebella: quantitative morphological assessment and fractal analysis of skeletonized MR images. *Biomedical Research and Therapy*, 8(5), 4345-4357. doi: 10.15419/bmrat.v8i5.673
- [16] Milosević, N. T., & Ristanović, D. (2006). Fractality of dendritic arborization of spinal cord neurons. *Neurosci Lett*, 396(3), 172-176. doi: 10.1016/j.neulet.2005.11.031
- [17] Orłowski, D., & Bjarkam, C. R. (2012). A simple reproducible and time saving method of semi-automatic dendrite spine density estimation compared to manual spine counting. *J Neurosci Methods*, 208(2), 128-133. doi: 10.1016/j.jneumeth.2012.05.009
- [18] Pantoni, L., Marzi, C., Poggiesi, A., Giorgio, A., De Stefano, N., Mascalchi, M., ... & Diciotti, S. (2019). Fractal dimension of cerebral white matter: A consistent feature for prediction of the cognitive performance in patients with small vessel disease and mild cognitive impairment. *NeuroImage Clinical*, 24, 101990. doi: 10.1016/j.nicl.2019.101990
- [19] Podgórski, P., Bladowska, J., Sasiadek, M., & Zimny, A. (2021). Novel Volumetric and Surface-Based Magnetic Resonance Indices of the Aging Brain - Does Male and Female Brain Age in the Same Way?. *Frontiers in neurology*, 12, 645729. doi: 10.3389/fneur.2021.645729
- [20] Rajagopalan, V., Das, A., Zhang, L., Hillary, F., Wylie, G. R., & Yue, G. H. (2019). Fractal dimension brain morphometry: a novel approach to quantify white matter in traumatic brain injury. *Brain imaging and behavior*, 13(4), 914-924. doi: 10.1007/s11682-018-9892-2
- [21] Rajagopalan, V., Liu, Z., Alexandre, D., Zhang, L., Wang, X. F., Pioro, E. P., & Yue, G. H. (2013). Brain white matter shape changes in amyotrophic lateral sclerosis (ALS): a fractal dimension study. *PLoS one*, 8(9), e73614. doi: 10.1371/journal.pone.0073614
- [22] Roura, E., Maclair, G., Andorra, M., Juanals, F., Pulido-Valdeolivas, I., Saiz, A., ... & Villoslada, P. (2021). Cortical fractal dimension predicts disability worsening in Multiple Sclerosis patients. *NeuroImage. Clinical*, 30, 102653. doi: 10.1016/j.nicl.2021.102653
- [23] Schneider, C. A., Rasband, W. S., & Eliceiri, K. W. (2012). NIH Image to ImageJ: 25 years of image analysis. *Nature methods*, 9(7), 671-675. doi: 10.1038/nmeth.2089
- [24] Zhang, L., Butler, A. J., Sun, C. K., Sahgal, V., Wittenberg, G. F., & Yue, G. H. (2008). Fractal dimension assessment of brain white matter structural complexity post stroke in relation to upper-extremity motor function. *Brain research*, 1228, 229-240. doi: 10.1016/j.brainres.2008.06.008
- [25] Zhang, L., Dean, D., Liu, J. Z., Sahgal, V., Wang, X., & Yue, G. H. (2007). Quantifying degeneration of white matter in normal aging using fractal dimension. *Neurobiology of aging*, 28(10), 1543-1555. doi: 10.1016/j.neurobiolaging.2006.06.020
- [26] Zhang, L., Liu, J. Z., Dean, D., Sahgal, V., & Yue, G. H. (2006). A three-dimensional fractal analysis method for quantifying white matter structure in human brain. *Journal of neuroscience methods*, 150(2), 242-253. doi: 10.1016/j.jneumeth.2005.06.021

## ФРАКТАЛЬНА РОЗМІРНІСТЬ СКЕЛЕТОНОВАНИХ МАГНІТНО-РЕЗОНАНСНИХ ЗОБРАЖЕНЬ ЯК МІРА ПРОСТОРОВОЇ СКЛАДНОСТІ ВЕЛИКИХ ПІВКУЛЬ ГОЛОВНОГО МОЗКУ

Мар'єнко Н. І., Степаненко О. Ю.

Фрактальний аналіз в останні десятиліття дедалі ширше використовується у різних наукових сферах, у тому числі нейронауках. Цей спосіб математичного аналізу дозволяє кількісно визначити ступінь заповнення простору об'єктом та ступінь складності його просторової конфігурації. Мета дослідження - визначити значення фрактальної розмірності великих півкуль головного мозку за допомогою фрактального аналізу скелетонованих магнітно-резонансних зображень головного мозку. Для дослідження було використано магнітно-резонансні томограми головного мозку 100 умовно здорових осіб (які не мали структурних змін головного мозку) обох статей (жінок 56, чоловіків 44) віком 18-86 років (середній вік  $41,72 \pm 1,58$  років). У кожному мозку були досліджені 5 томографічних зрізів. 1-й корональний томографічний зріз був розташований на рівні найбільш передніх точок скроневих часток, 2-й - на рівні сосочкових тіл, 3-й - на рівні чотиригорбкової пластинки, 4-й - на рівні валка мозолистого тіла. Аксиальний томографічний зріз був розташований на рівні таламуса. Проводився фрактальний аналіз скелетонованих зображень за допомогою способу підрахунку квадратів. Отримані дані оброблялися за допомогою загальноприйнятих статистичних методів. Середні, мінімальне та максимальне значення фрактальної розмірності різних томографічних зрізів були наступними: 1-й корональний зріз -  $1,207 \pm 0,003$  ( $1,147 \div 1,277$ ), 2-й корональний зріз -  $1,162 \pm 0,003$  ( $1,077 \div 1,243$ ), 3-й корональний зріз -  $1,156 \pm 0,003$  ( $1,094 \div 1,224$ ), 4-й корональний зріз -  $1,158 \pm 0,003$  ( $1,109 \div 1,218$ ), аксиальний зріз -  $1,138 \pm 0,002$  ( $1,079 \div 1,194$ ). Середнє значення фрактальної розмірності п'яти зрізів складало  $1,164 \pm 0,002$  ( $1,126 \div 1,209$ ), середнє значення фрактальної розмірності чотирьох корональних зрізів складало  $1,171 \pm 0,002$  ( $1,122 \div 1,219$ ). Фрактальний аналіз скелетонованих зображень великих півкуль головного мозку дозволяє кількісно характеризувати особливості топології та складності просторової конфігурації великих півкуль головного мозку. На значення фрактальної розмірності можуть впливати анатомічні особливості досліджуваних ділянок головного мозку, індивідуальні анатомічні особливості, а також атрофічні та інші патологічні зміни, що призводять до змін форми великих півкуль головного мозку. Значення фрактальної розмірності скелетонованих зображень головного мозку мають тенденцію до зниження з віком. Найбільш репрезентативними для характеризування вікових атрофічних змін є корональні томографічні зрізи. Фрактальний аналіз скелетонованих зображень великих півкуль головного мозку може бути використаний для діагностики захворювань нервової системи, а результати даного дослідження можуть бути використані у якості критеріїв норми.

**Ключові слова:** фрактальний аналіз, фрактальна розмірність, головний мозок, великі півкулі головного мозку, морфометрія.