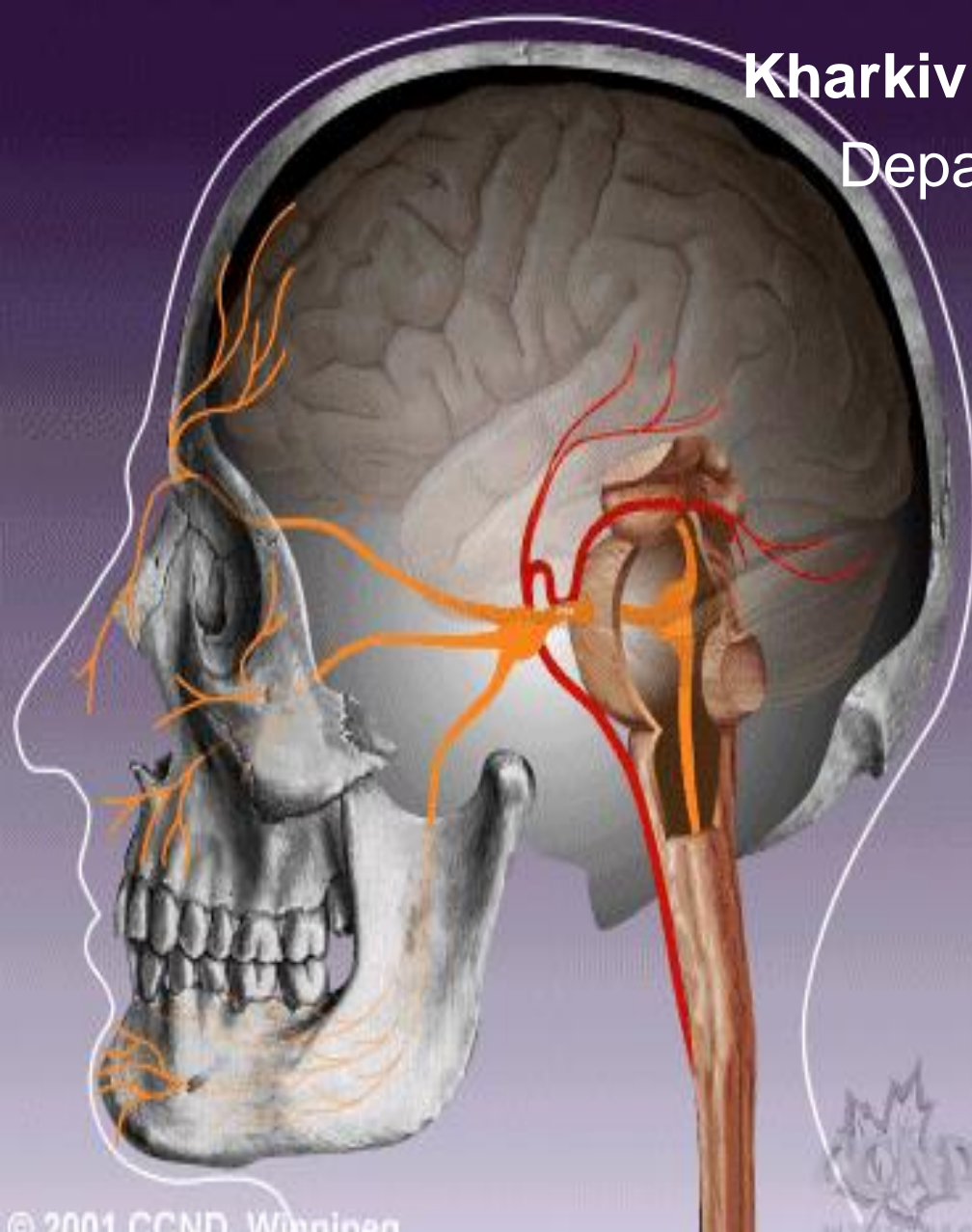


Kharkiv National Medical University,
Department of Human Anatomy

The Trigeminal (V) and Facial (VII) cranial NERVES

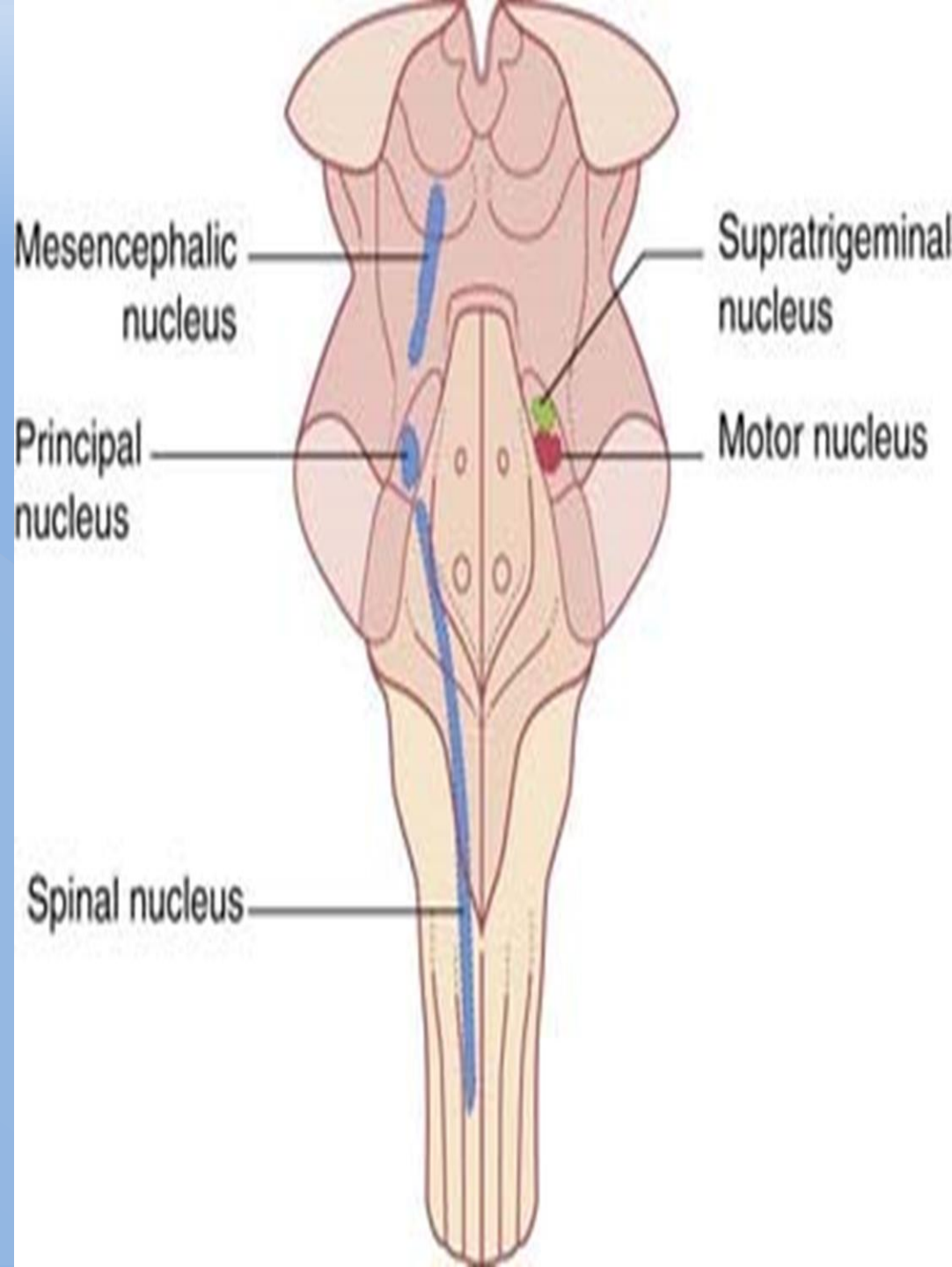


Associate professor, PhD, Hordiichuk Daria

The trigeminal nerve

- ⦿ The trigeminal **nerve is the largest** and most complex of the 12 cranial nerves (CNs).
- ⦿ It supplies sensations **to the face, mucous membranes, and other structures of the head**. It is the **motor** nerve for **the muscles of mastication** and contains **proprioceptive fibers**.
- ⦿ It leaves the brain by a large **sensory root** and a **smaller motor root** going out of the pons at its **junction with the middle cerebellar peduncle**. It passes laterally to join the **Gasserian (semilunar) ganglion in the Meckel's cave**.

- ◉ The **trigeminal nerve** originates from three **sensory nuclei** (mesencephalic, principal sensory, spinal nuclei of trigeminal nerve)
- ◉ and one **motor nucleus** (motor nucleus of the trigeminal nerve)



Trigeminal Nerve

It is the **largest** cranial nerve and
contains both **sensory & motor** fibers

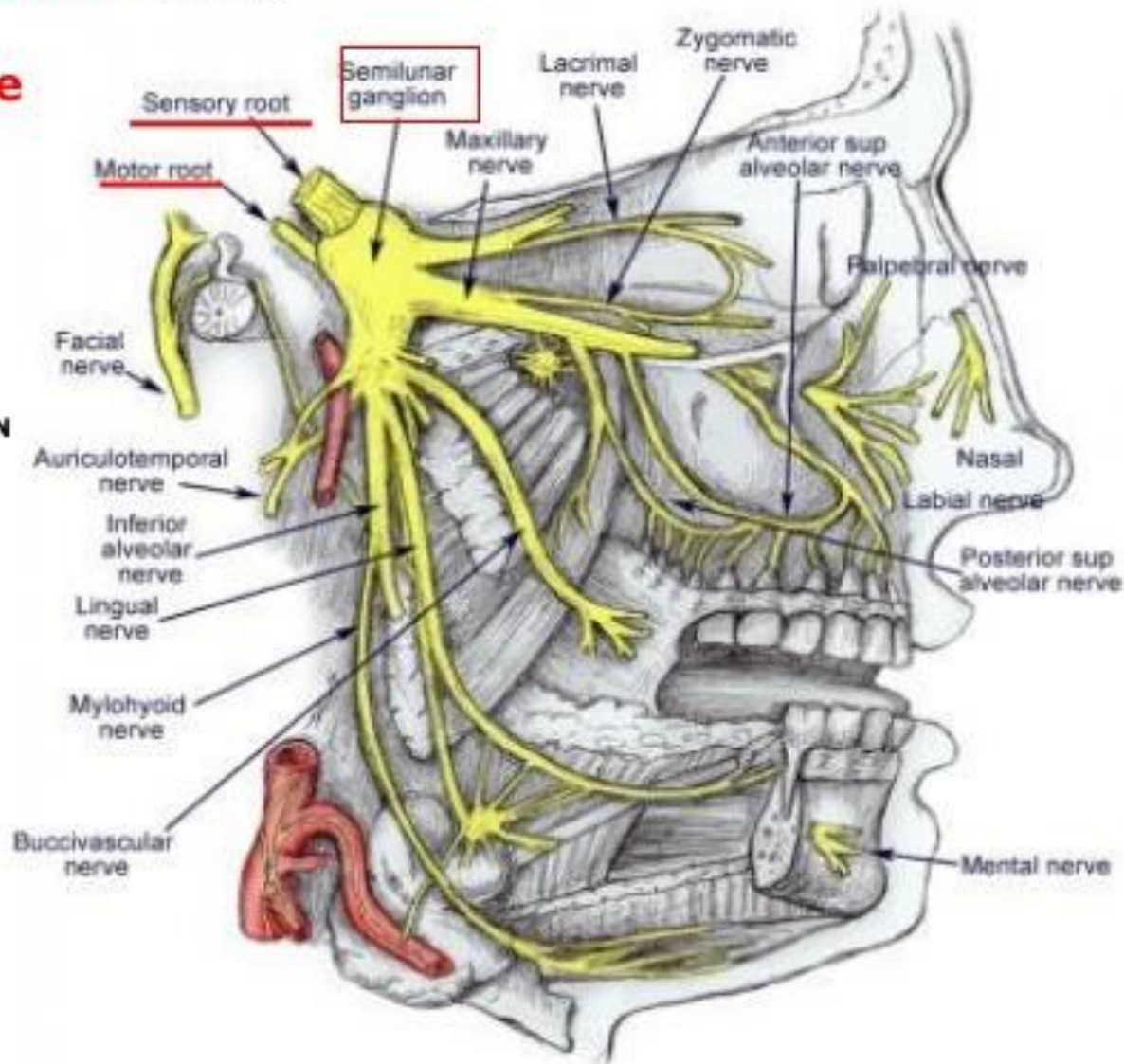
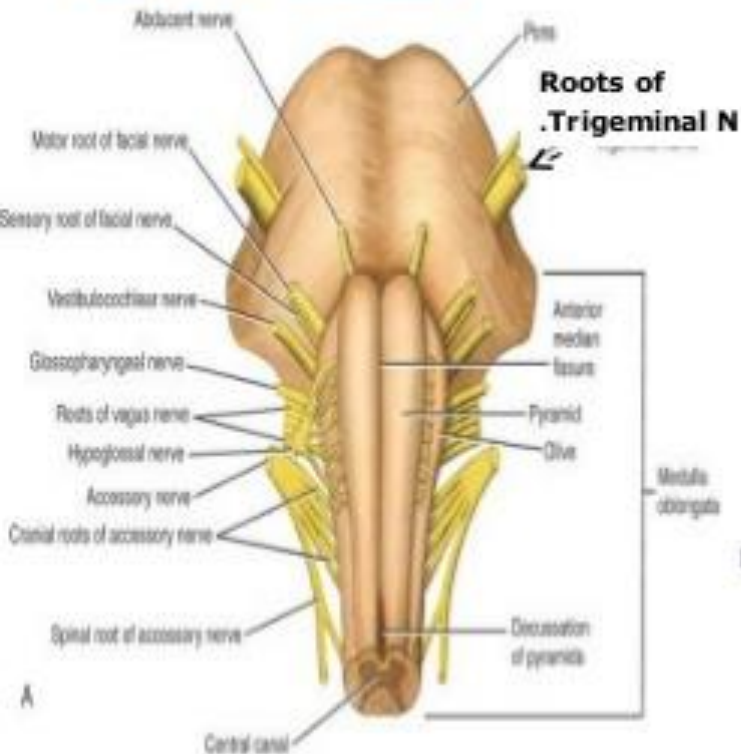
:Origin

It leaves **anterior surface**

: of **pons** by 2 roots

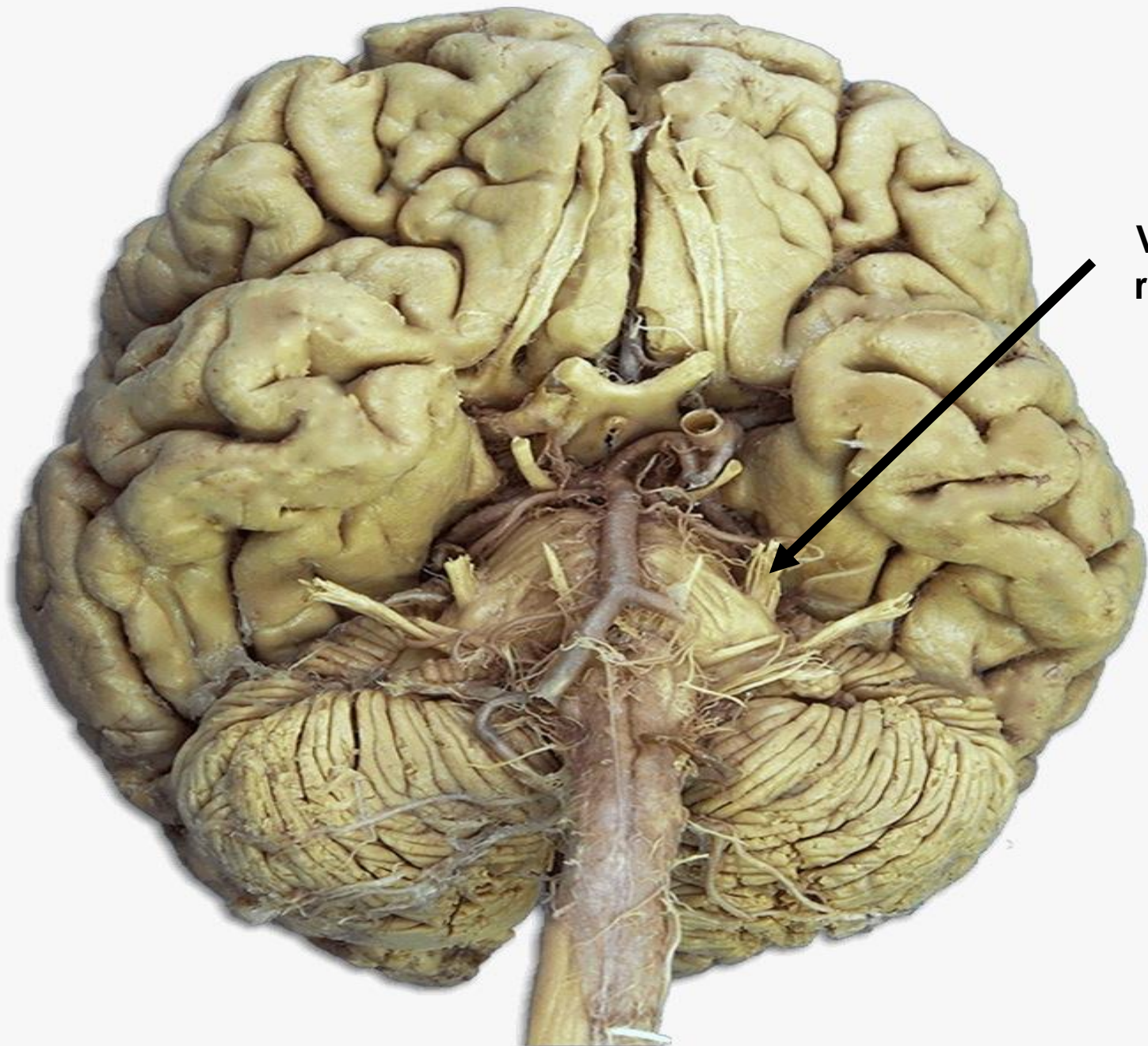
A small motor root. 1

A large sensory root. 2



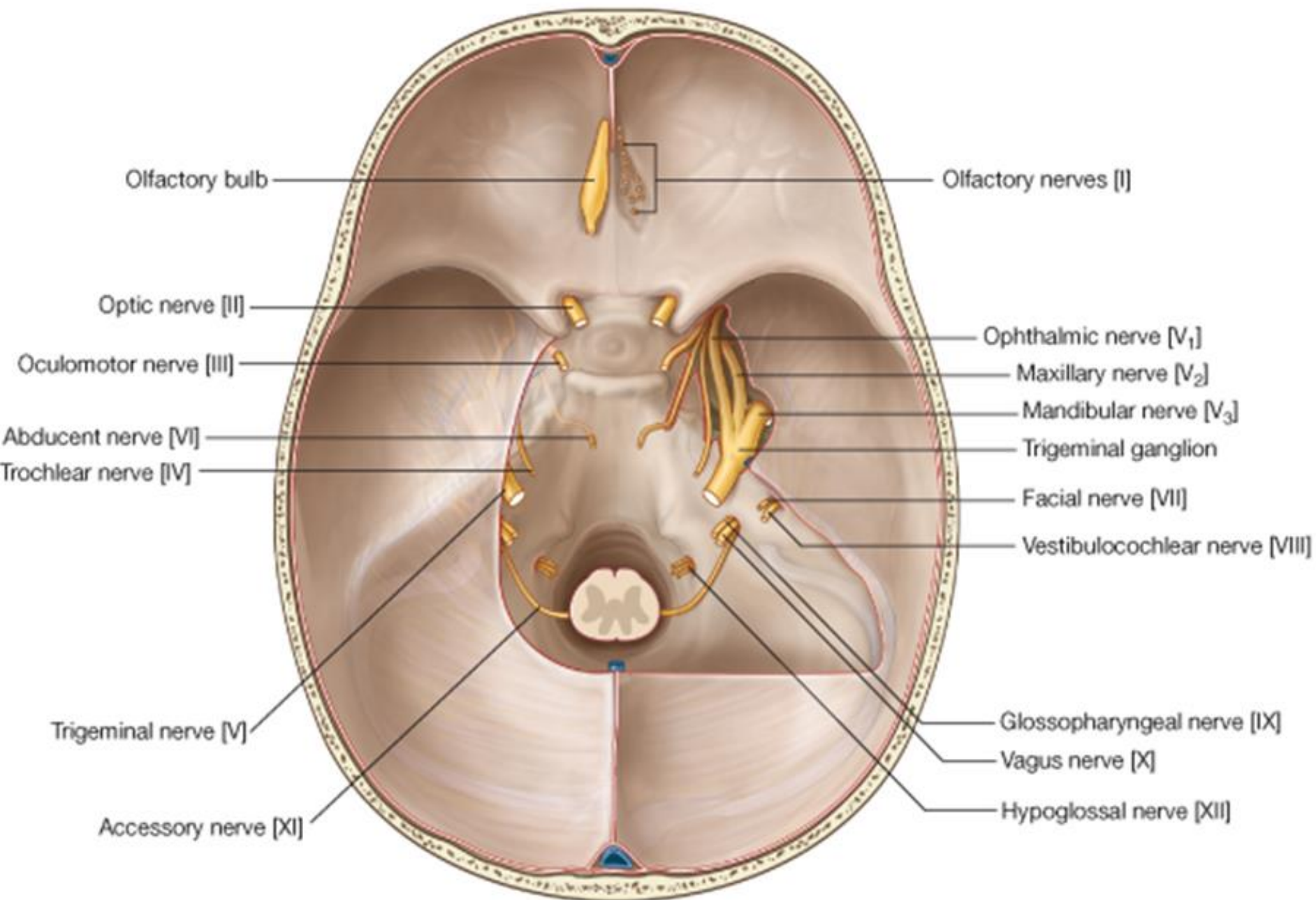
- ◎ **Sensory:** The three terminal branches of **CN V** innervate the **skin, mucous membranes and sinuses of the face**. Their distribution pattern is similar to the dermatome supply of spinal nerves (except there is little overlap in the supply of the divisions).
- ◎ **Motor:** Only the **mandibular branch** of **CN V** has motor fibres. It **innervates** the **muscles of mastication: medial pterygoid, lateral pterygoid, masseter and temporalis**. The mandibular nerve also supplies other 1st pharyngeal arch derivatives: **anterior belly of digastric mm., m. tensor velli palatini and m.tensor tympani**.
- ◎ **Parasympathetic Supply:** The **post-ganglionic** neurones of **parasympathetic ganglia** travel with branches of the trigeminal nerve.

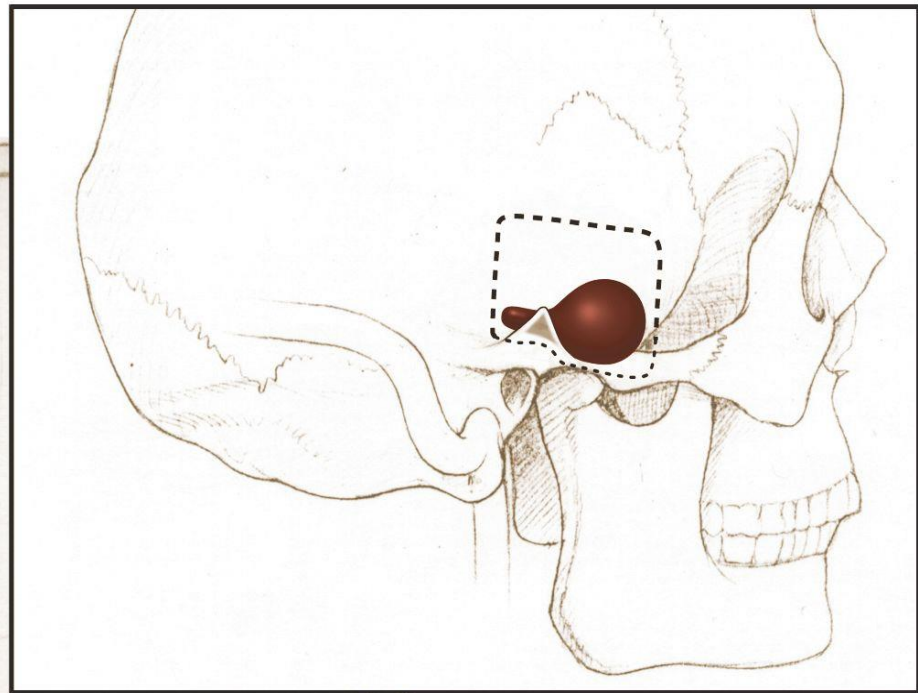
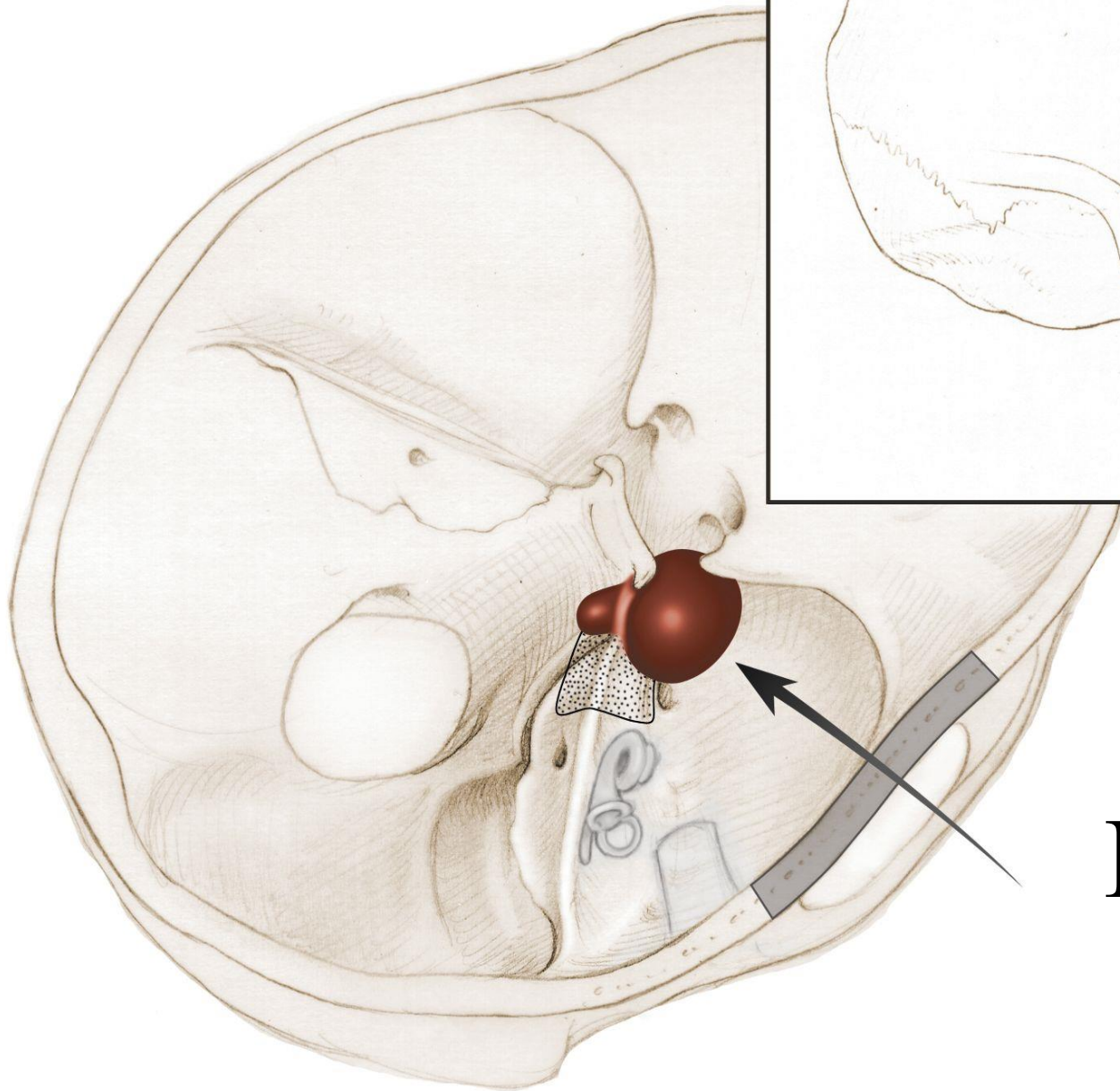
NB!!! (CN V IS NOT A PART OF THE CRANIAL PSS).



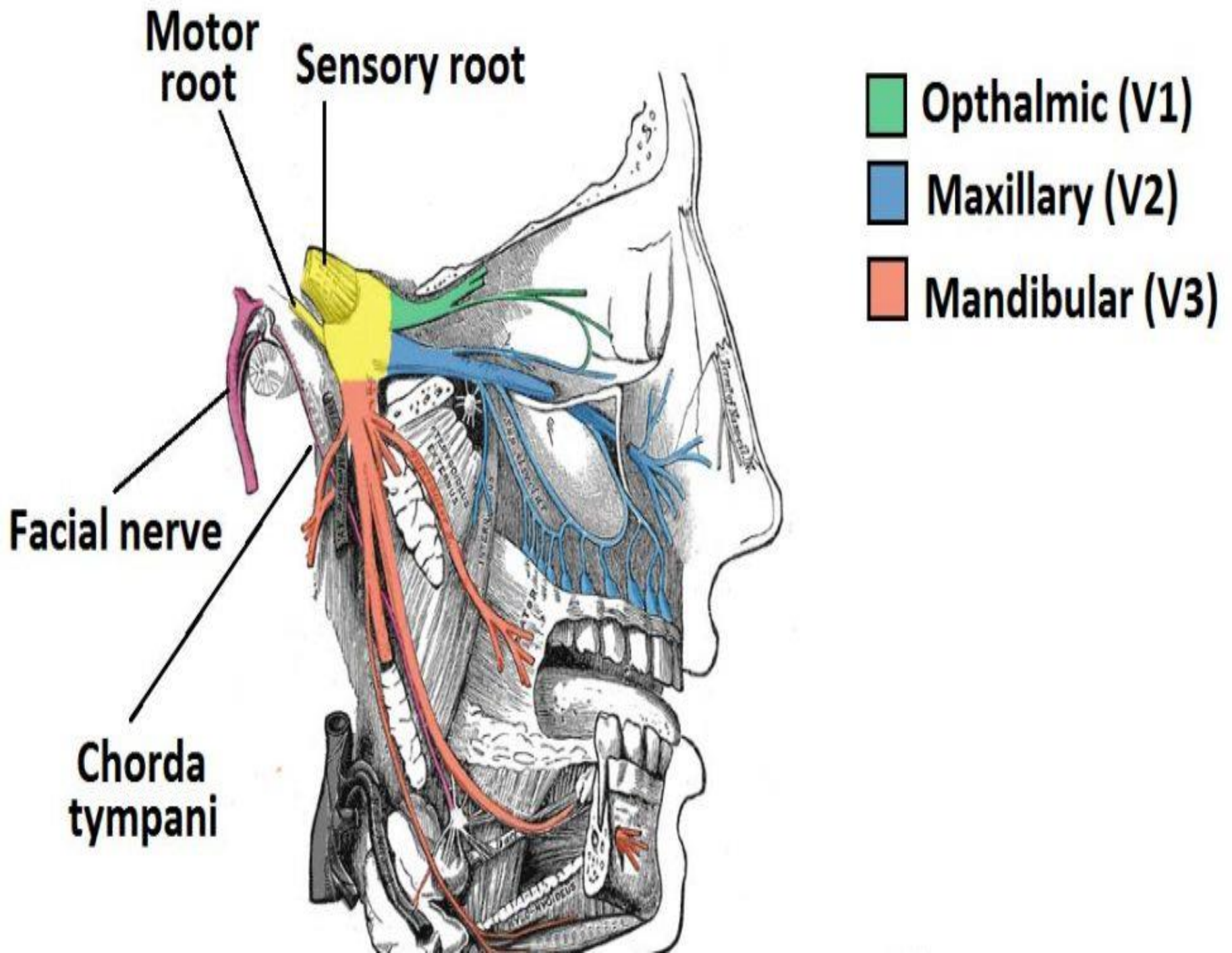
Vcn -
roots

- In **middle cranial fossa**, the sensory root expands **into the trigeminal ganglion**. A ganglion (pl. ganglia) refers to a collection of the neuron cell bodies outside the central nervous system.
- The trigeminal ganglion is located lateral to the cavernous sinus, in a depression of the temporal bone. This depression is known as the **trigeminal cave**.
- The peripheral aspect of the trigeminal ganglion gives rise to 3 divisions: **ophthalmic (V1)**, **maxillary (V2)** and **mandibular (V3)**.





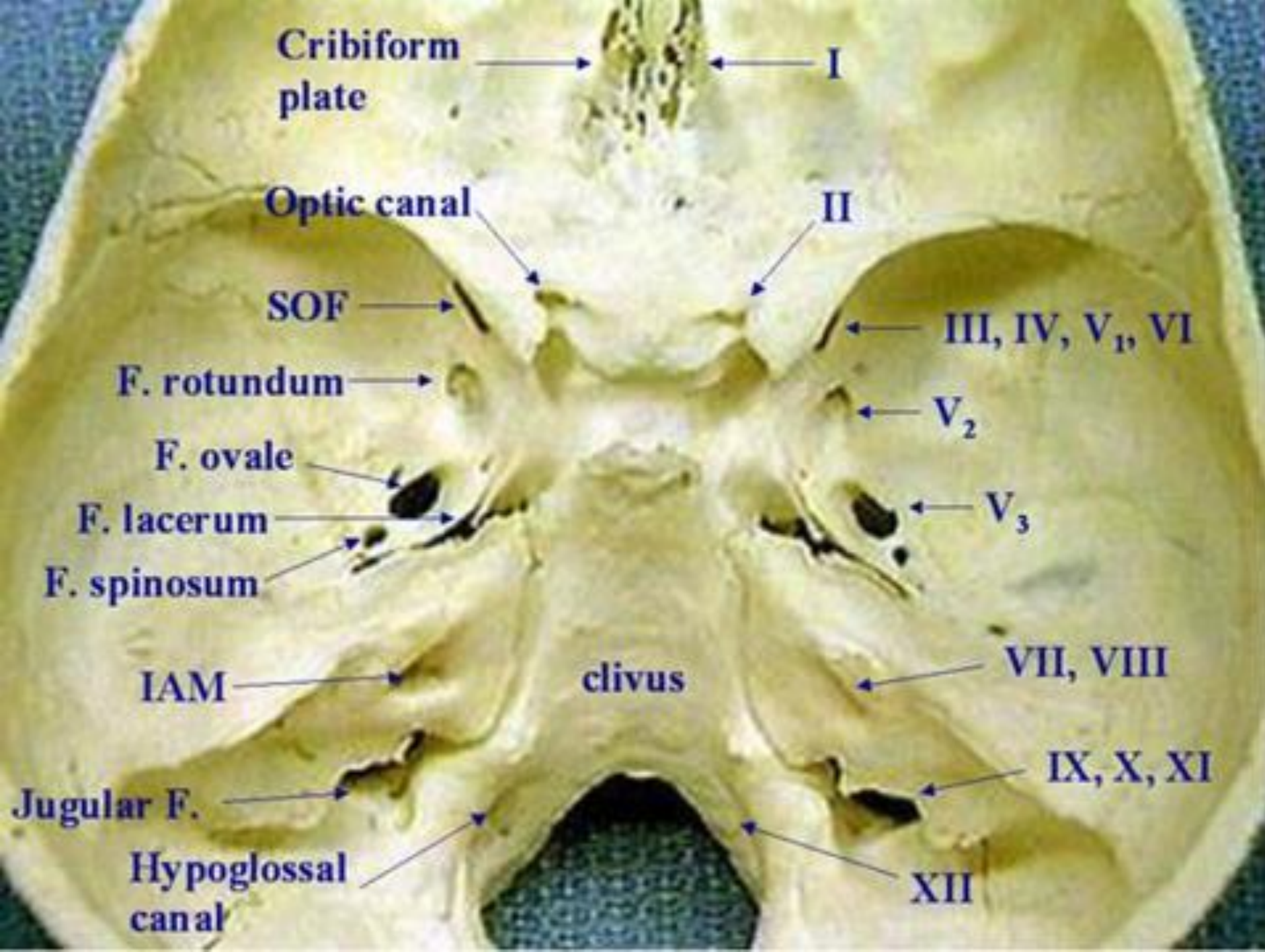
Meckel's
cave

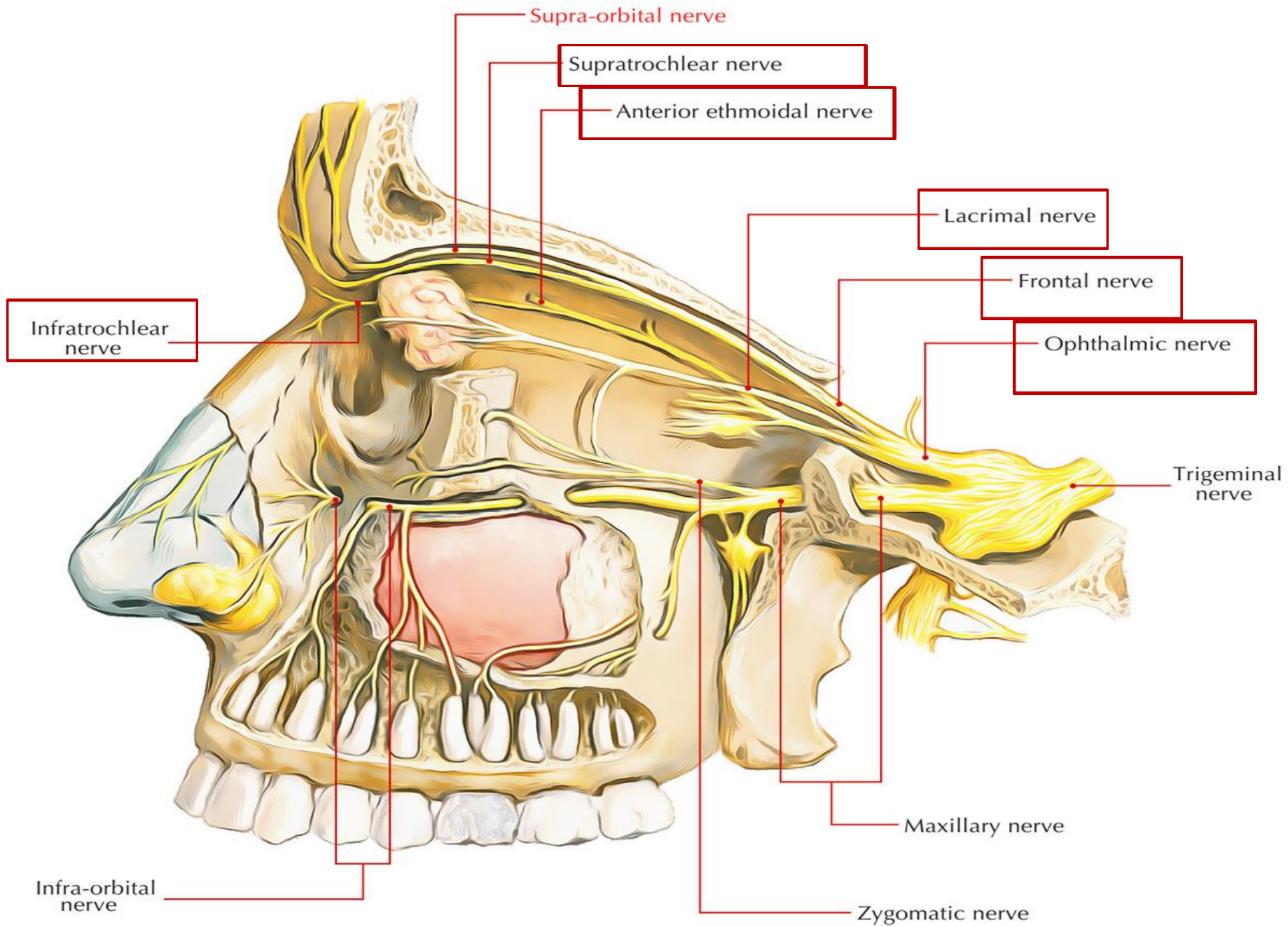


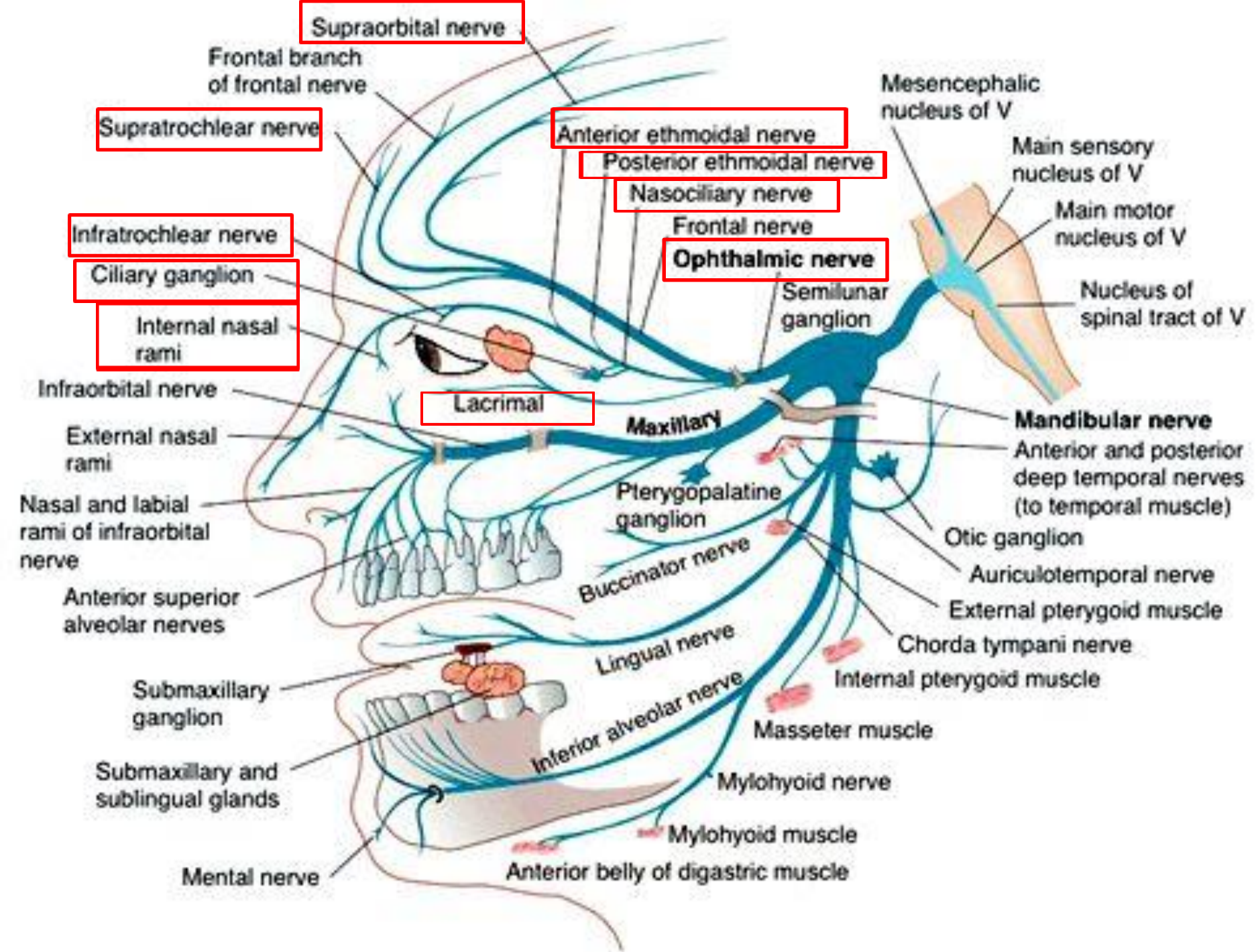
- ④ The **motor root** passes inferiorly to the sensory root, along the floor of the **trigeminal cave**. Its fibres are only distributed to the **mandibular division**, which leave the skull through foramen **ovale**
- ④ The **ophthalmic nerve** and **maxillary nerve** moves laterally to the cavernous sinus exiting the cranium via the **superior orbital fissure** and **foramen rotundum** respectively. The mandibular nerve exits via the foramen ovale entering the infra-temporal fossa. (Note – be aware that while we talk about the nerves exiting the cranial cavity, the sensory components can also be said to be entering the cranial cavity, since they are afferent fibres).

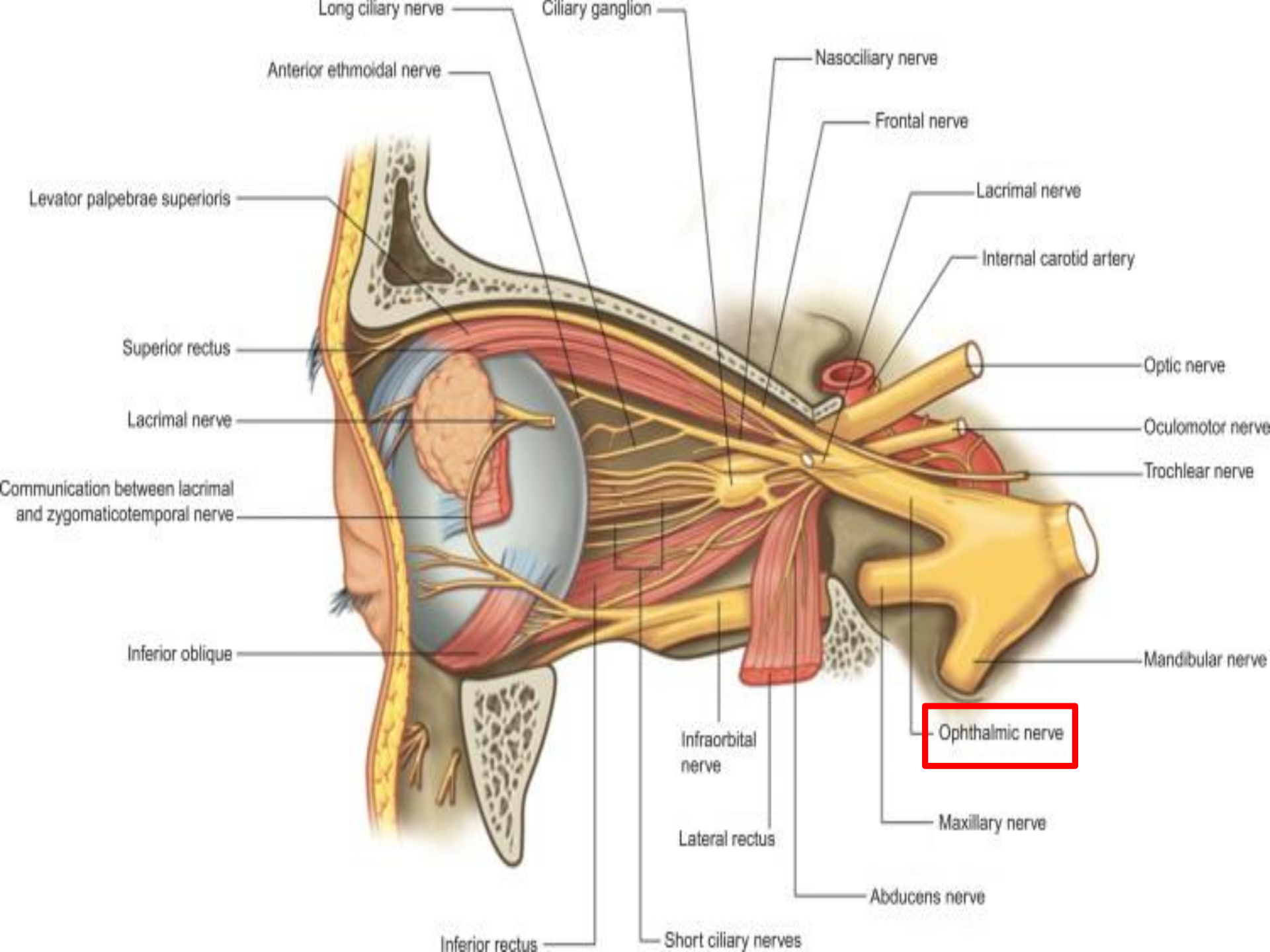
Ophthalmic Nerve

- Ophthalmic nerve gives rise to 3 terminal branches:
- **frontal,**
- **Lacrimal,**
- **nasociliary**, which innervate the skin and mucous membrane of derivatives of the frontonasal prominence derivatives:
- *Forehead and scalp*
- *Frontal and ethmoidal sinus and air cells*
- *Upper eyelid and its conjunctiva*
- *Cornea*
- *Dorsum of the nose*

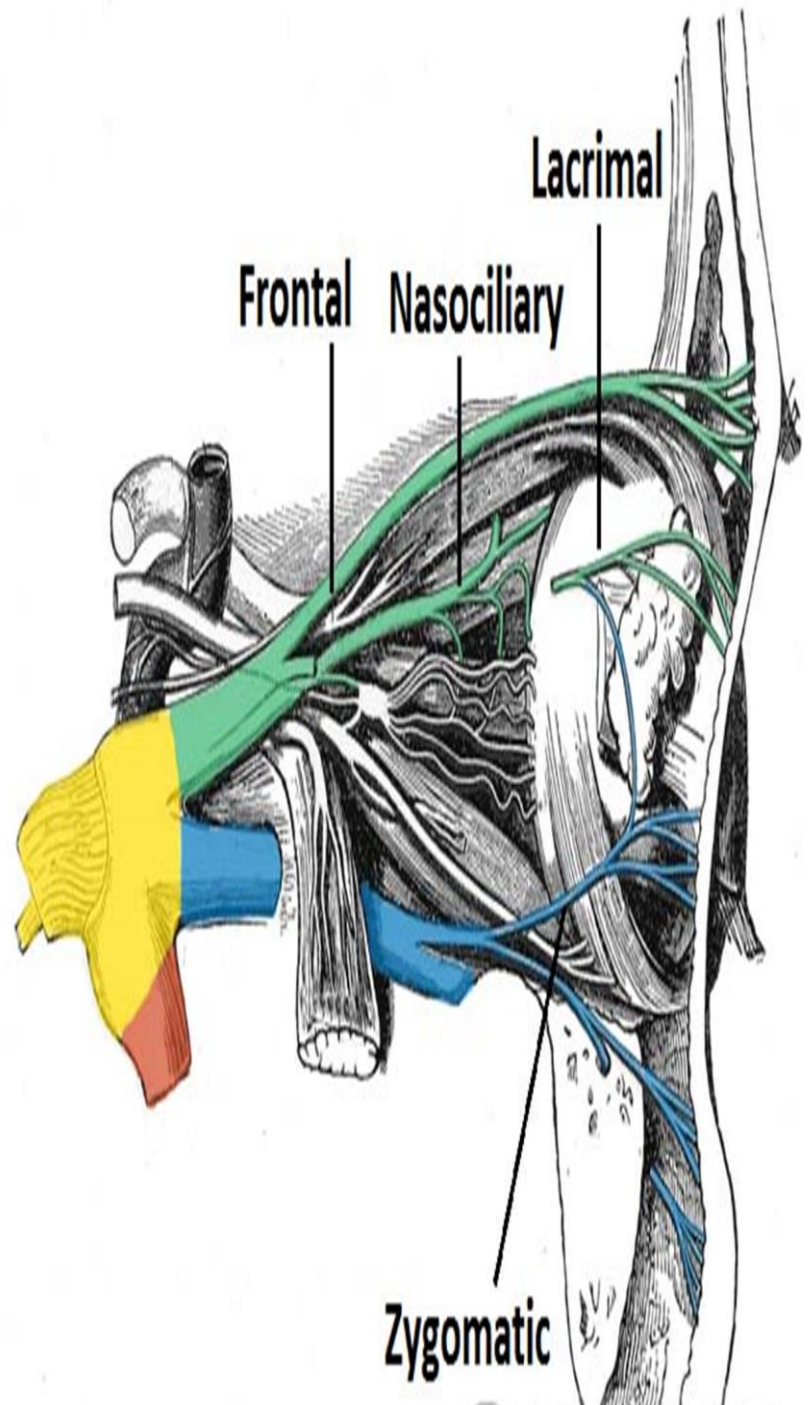








- ◎ **Parasympathetic Supply:**
- ◎ **Lacrimal gland:** Post ganglionic fibres from the **pterygopalatine ganglion** (derived from the facial nerve), travel with the **zygomatic branch of V2** and then join the **lacrimal branch of V1**. ***The fibers supply parasympathetic innervation to the lacrimal gland.***



Va TRIGEMINAL: OPHTHALMIC

SENSORY

- Scalp
- Upper face
- Eye
- Sinuses

DELIVERS

10 short ciliary n's

PARASYMPATHETIC VIA CILIARY GANGLION

- Ciliary muscle (accommodation)
- Sphincter pupillae
- Lacrimal gland (via pterygopalatine ganglion)

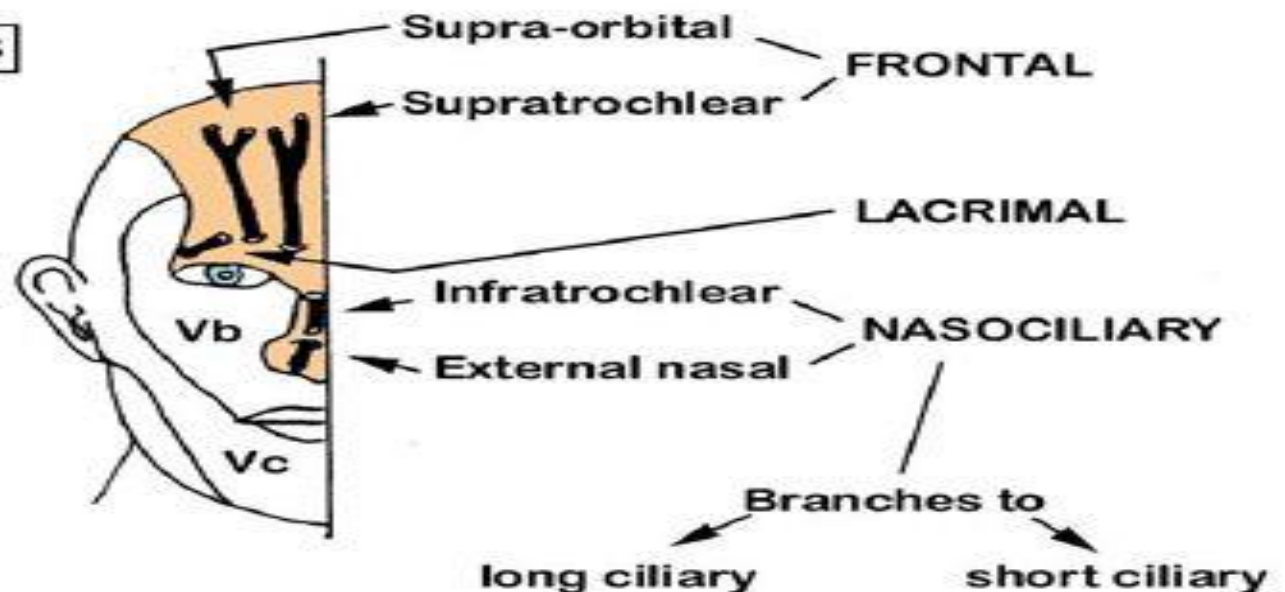
2-3 long ciliary n's

SYMPATHETIC VIA CAVERNOUS SINUS

- Dilator pupillae

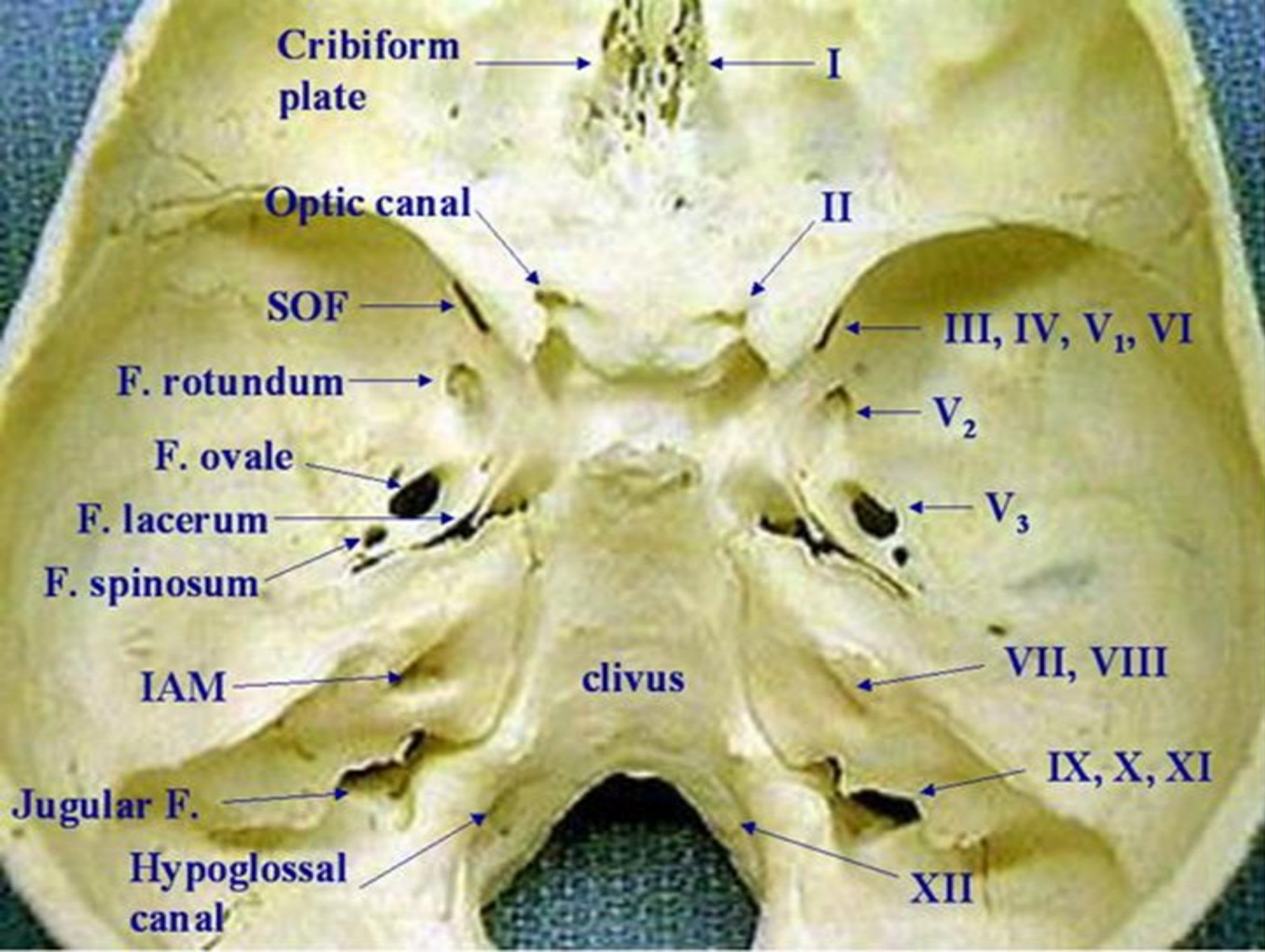
KEY BRANCHES

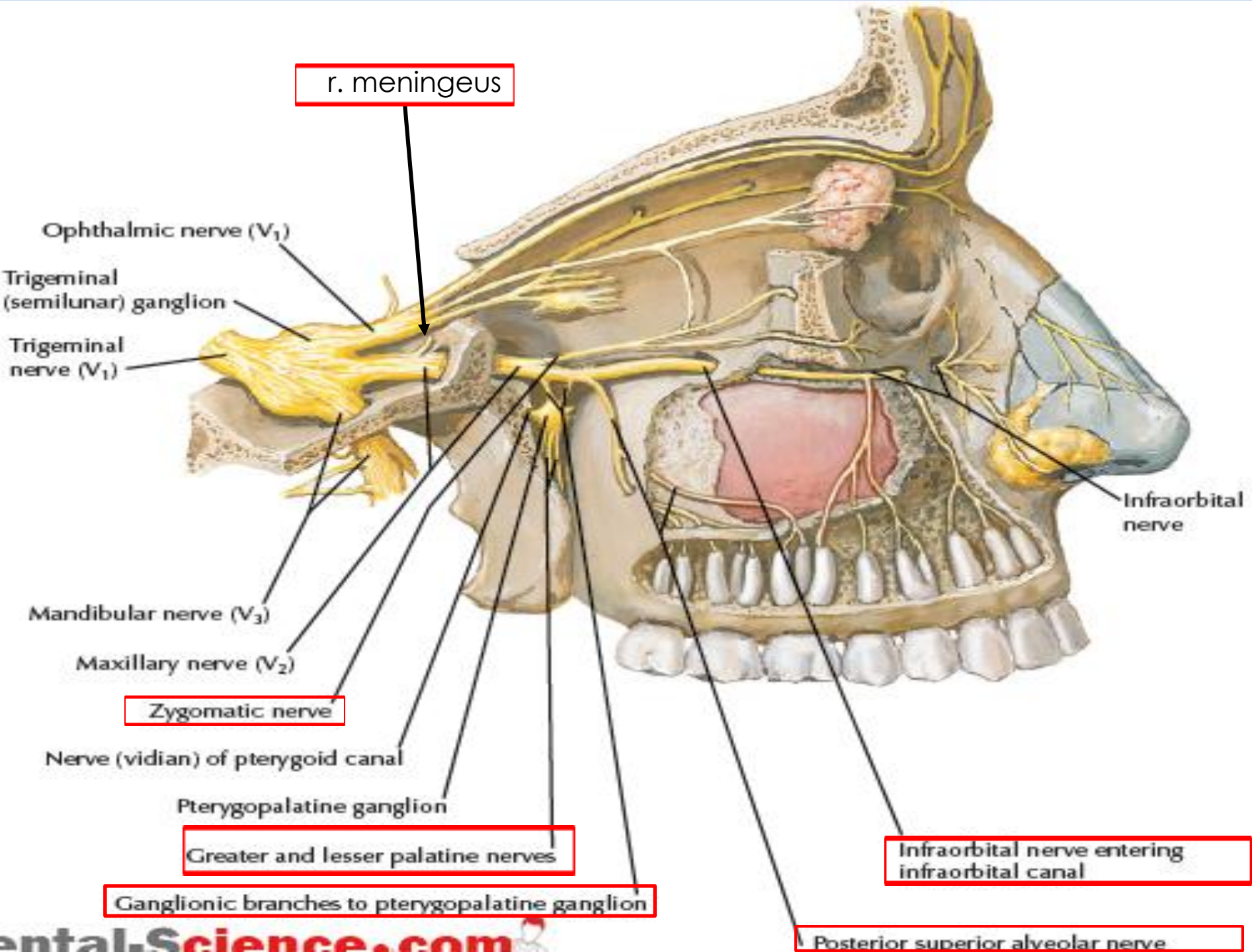
5 SENSORY
TO FACE

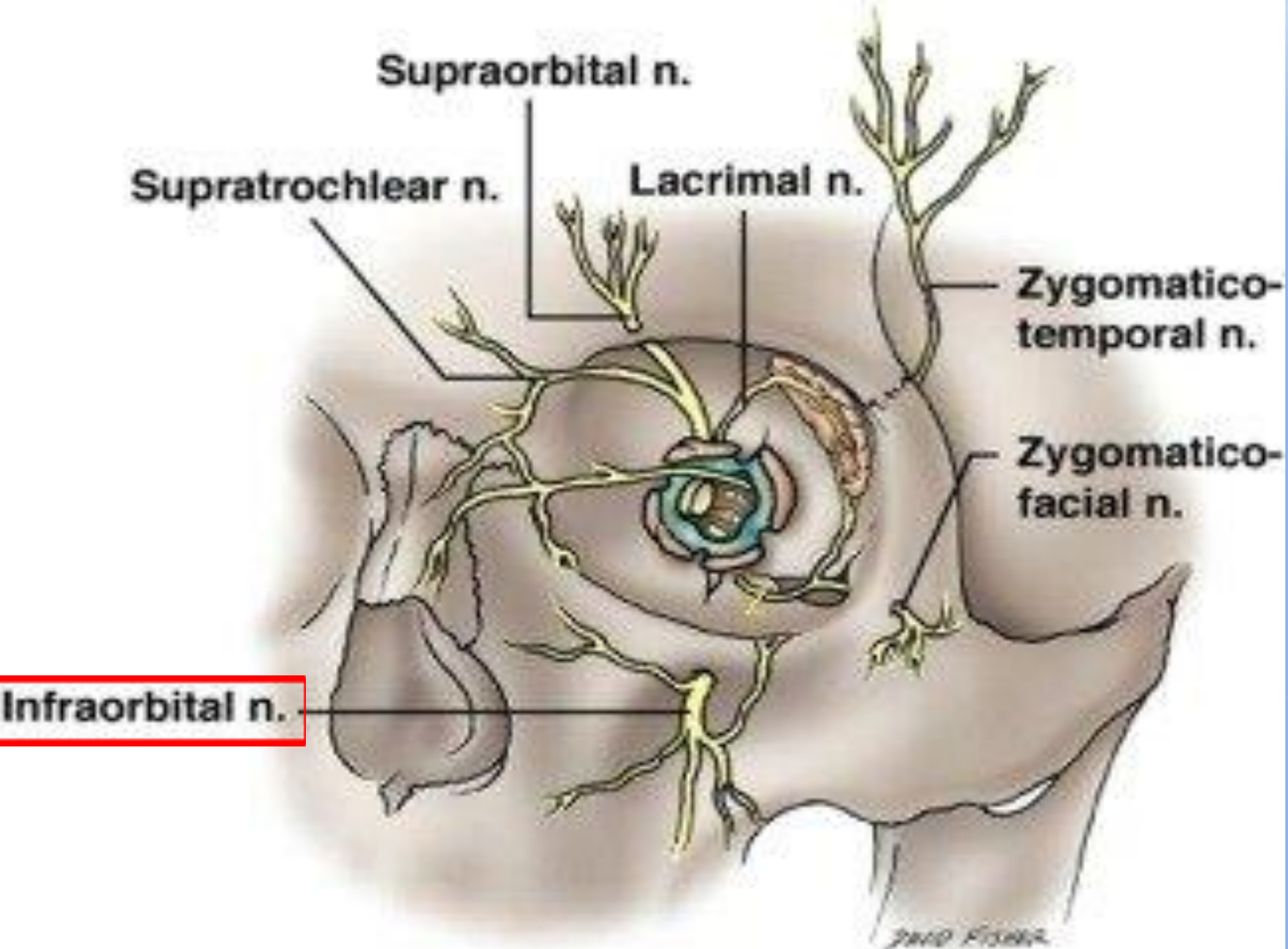


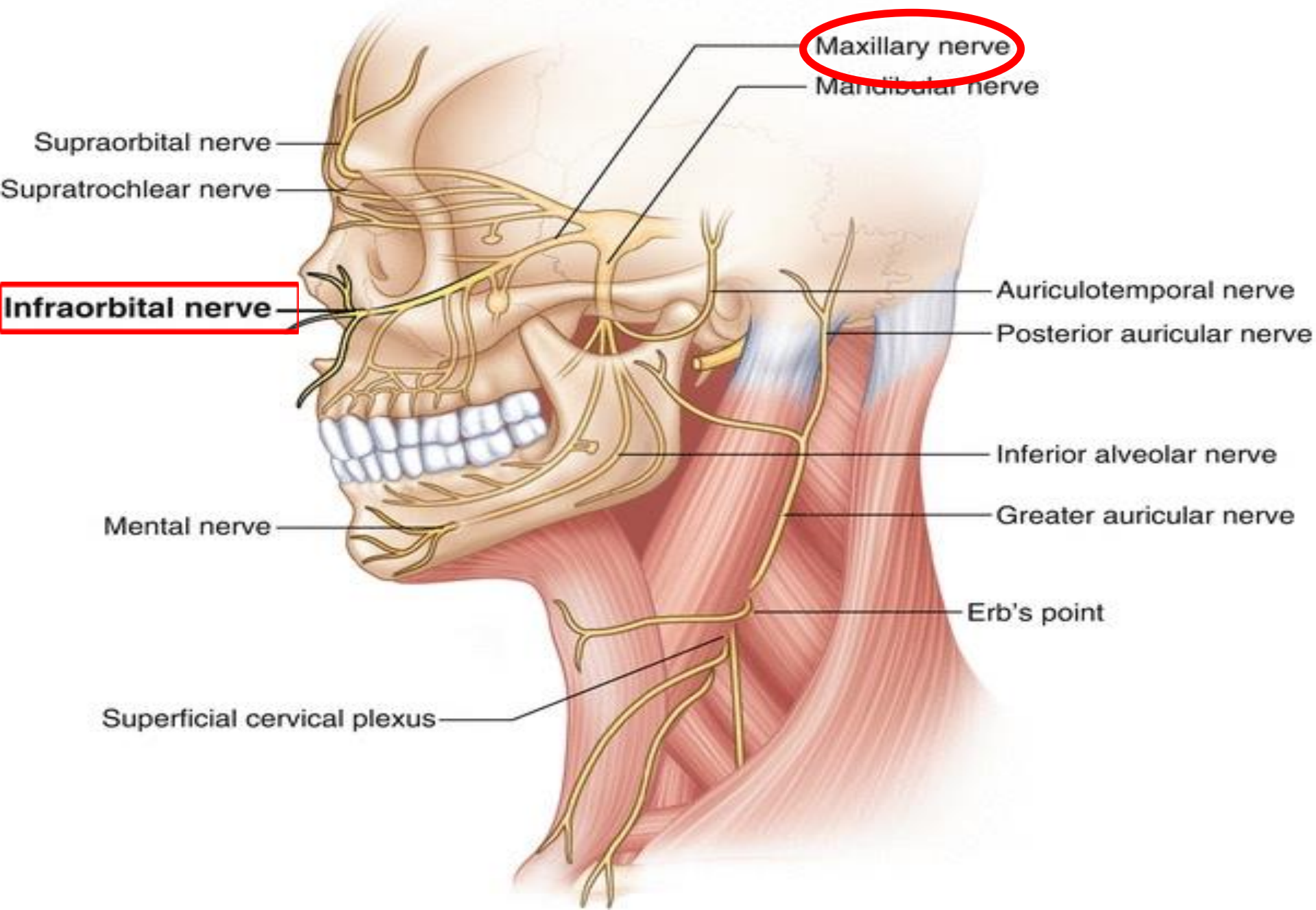
◎ Maxillary Nerve

- ◎ **Maxillary nerve** gives rise to 14 terminal branches, which innervate **the skin, mucous membranes and sinuses of derivatives of the maxillary prominence of the 1st pharyngeal arch:**
 - ◎ Lower eyelid and its conjunctiva
 - ◎ Cheeks and maxillary sinus
 - ◎ Nasal cavity and lateral nose
 - ◎ Upper lip
 - ◎ Upper molar, incisor and canine teeth and the associated gingiva
 - ◎ Superior palate







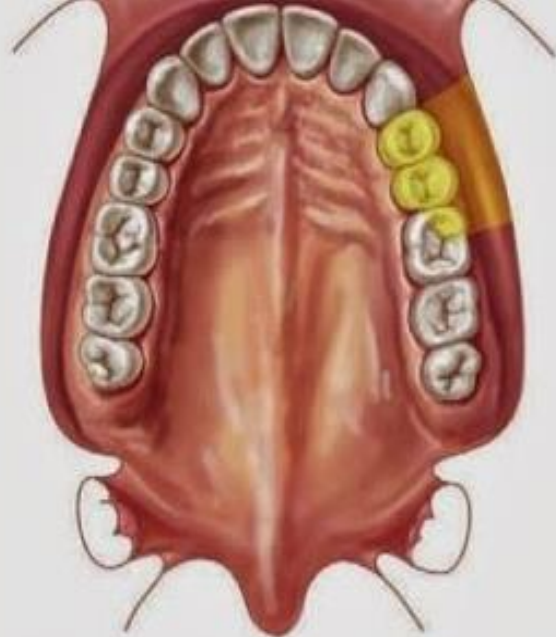

NB!!!“Small goose paw” – it is 3 terminal branches of infraorbital nerve!
(r.palpebralis inf., rr. nasales externi, rr. labiales supp.)

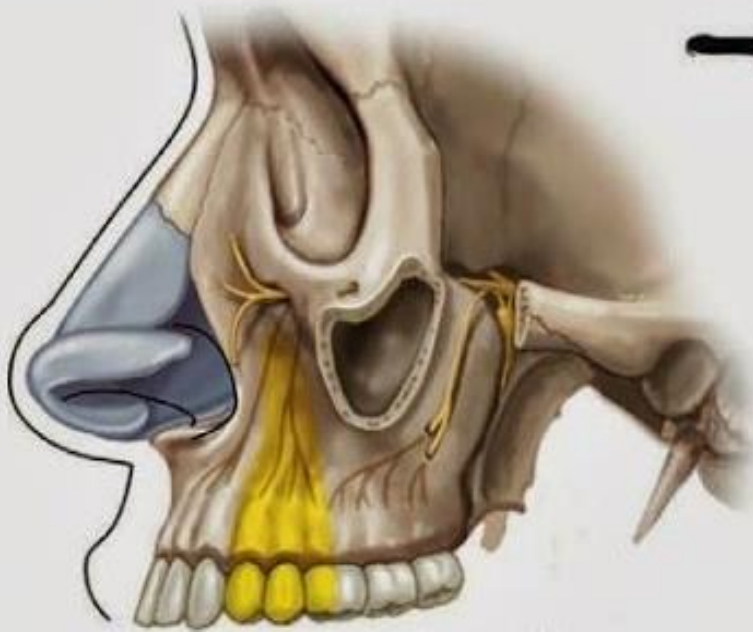
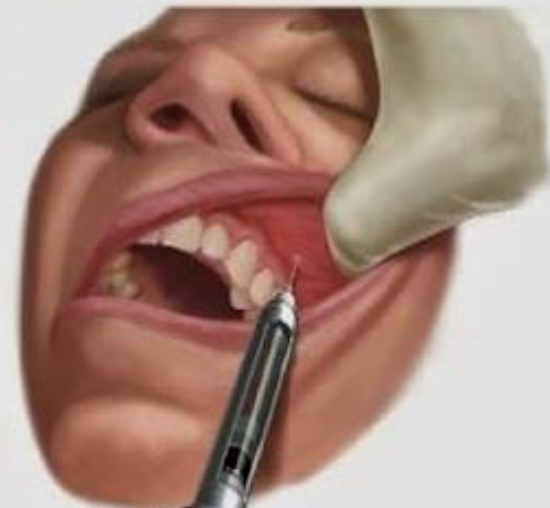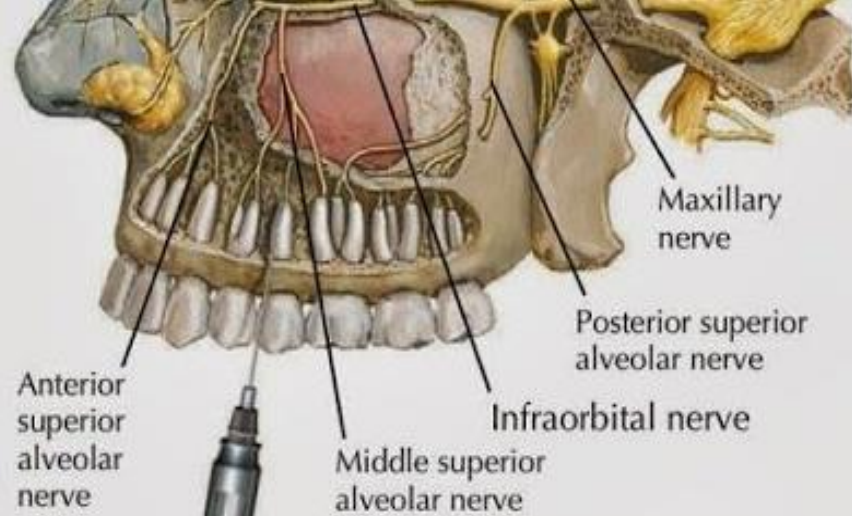


Parasympathetic Supply:

- ① **Lacrimal gland:** Post ganglionic fibers from the **pterygopalatine ganglion** (derived from the **V2 nerve**), travel **with** the **zygomatic branch of V2** and then join the lacrimal branch of **V1**. The fibers supply parasympathetic innervation to the lacrimal gland.
- ② **Nasal glands:** Parasympathetic fibers are also carried to the mucous glands of the nasal mucosa. **Post-ganglionic fibers travel with the nasopalatine and greater palatine nerves** (branches of **V2**)



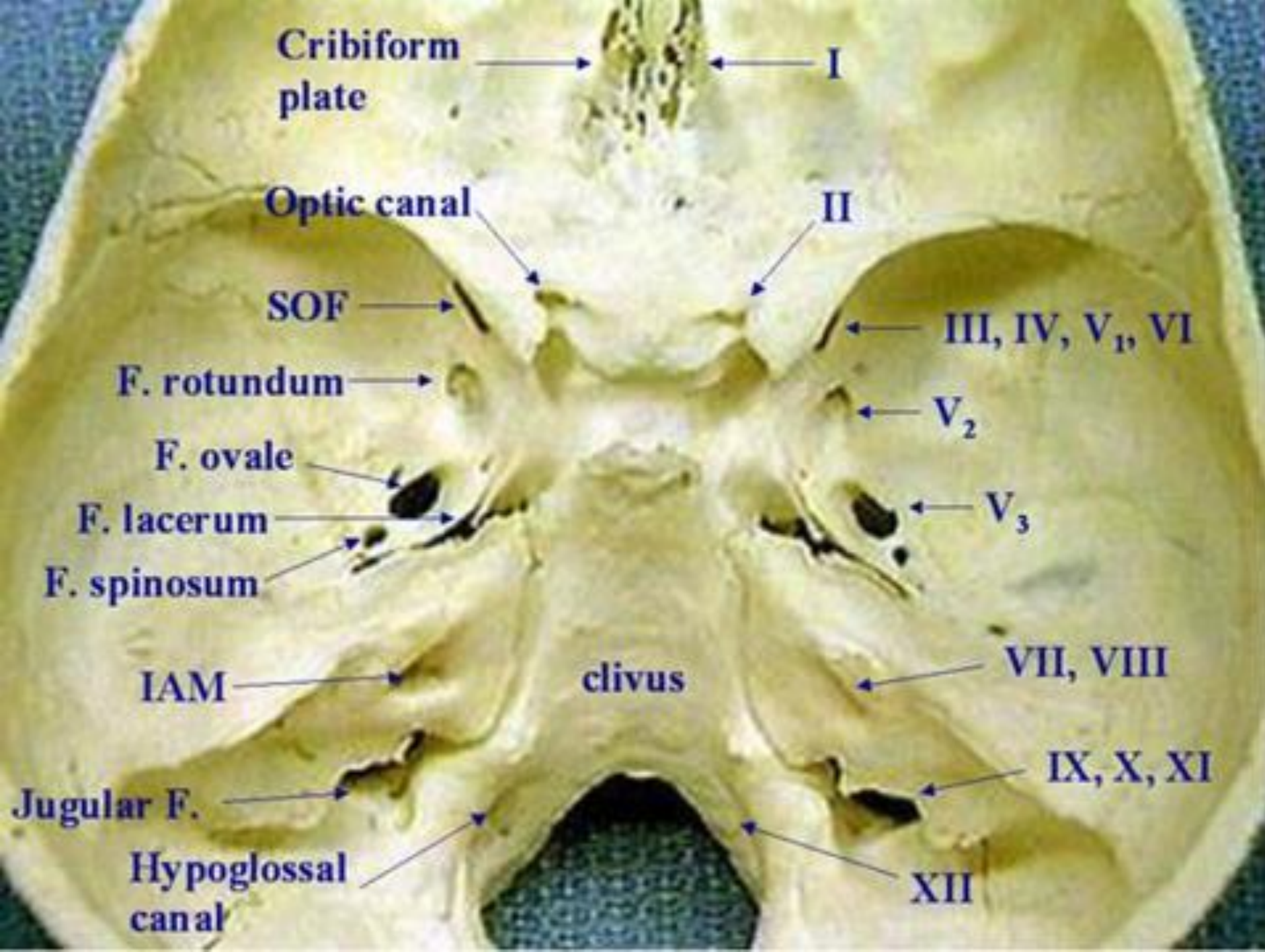
Area anesthetized by a middle superior alveolar injection



F. Netter M.D.

◎ **MANDIBULAR NERVE**

- ◎ **Mandibular nerve** gives rise to 7 main branches **in the infra-temporal fossa**:
- ◎ **n. spinosus**,
- ◎ **muscular branches**,
- ◎ **buccal nerve**,
- ◎ **inferior alveolar nerve**,
- ◎ **auriculotemporal nerve**,
- ◎ **lingual nerve**,
- ◎ **Sensory branch to otic ganglion**
- ◎ These branches **innervate the skin, mucous membrane and striated muscle derivatives of the mandibular prominence of the 1st pharyngeal arch.**

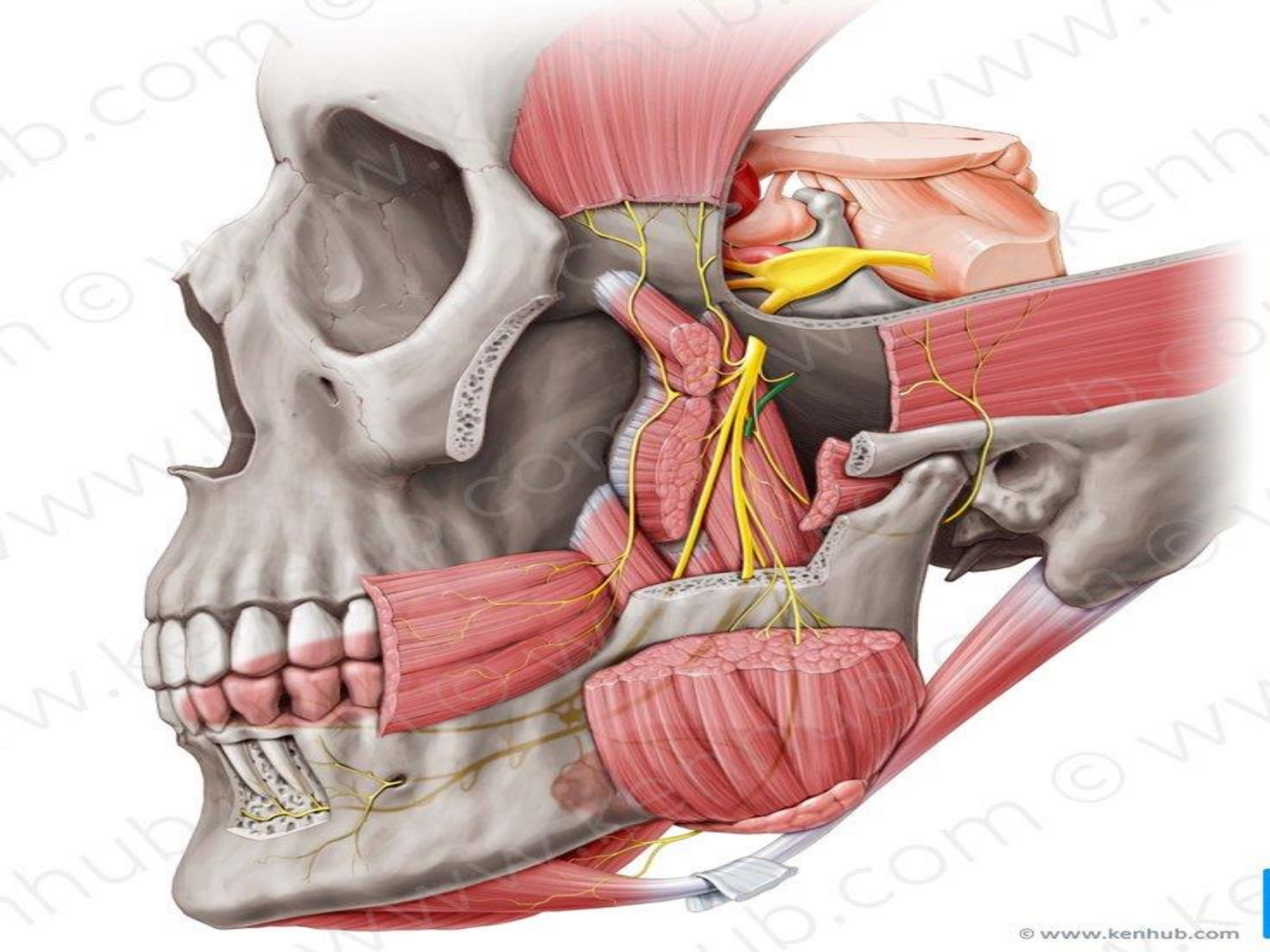


⦿ **Motor Supply:**

- ⦿ **Muscles of mastication;** medial pterygoid, lateral pterygoid, masseter, temporalis
- ⦿ Anterior belly of the digastric muscle and the mylohyoid muscle (these are suprahyoid muscles)
- ⦿ Tensor veli palatine m.
- ⦿ Tensor tympani mm.

⦿ **Parasympathetic Supply:**

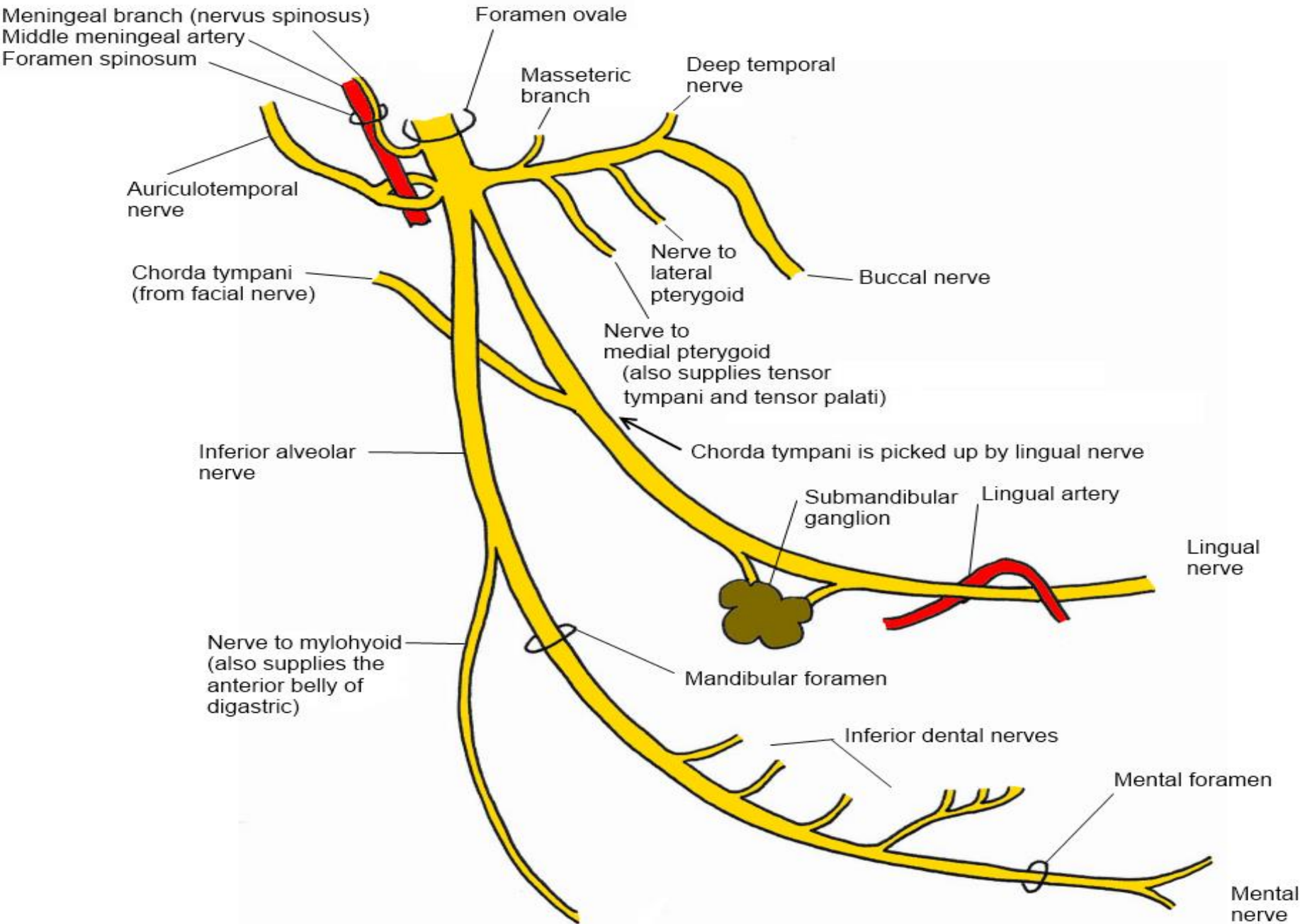
- ⦿ **Submandibular and Sublingual glands:** Post-ganglionic fibres from the **submandibular ganglion** (derived from the facial nerve), travel with the **lingual nerve** to innervate these glands.
- ⦿ **Parotid gland:** Postganglionic fibres from **the otic ganglion** (derived from the CN IX), travel with the **auriculotemporal branch** of the V3 to innervate the parotid gland.

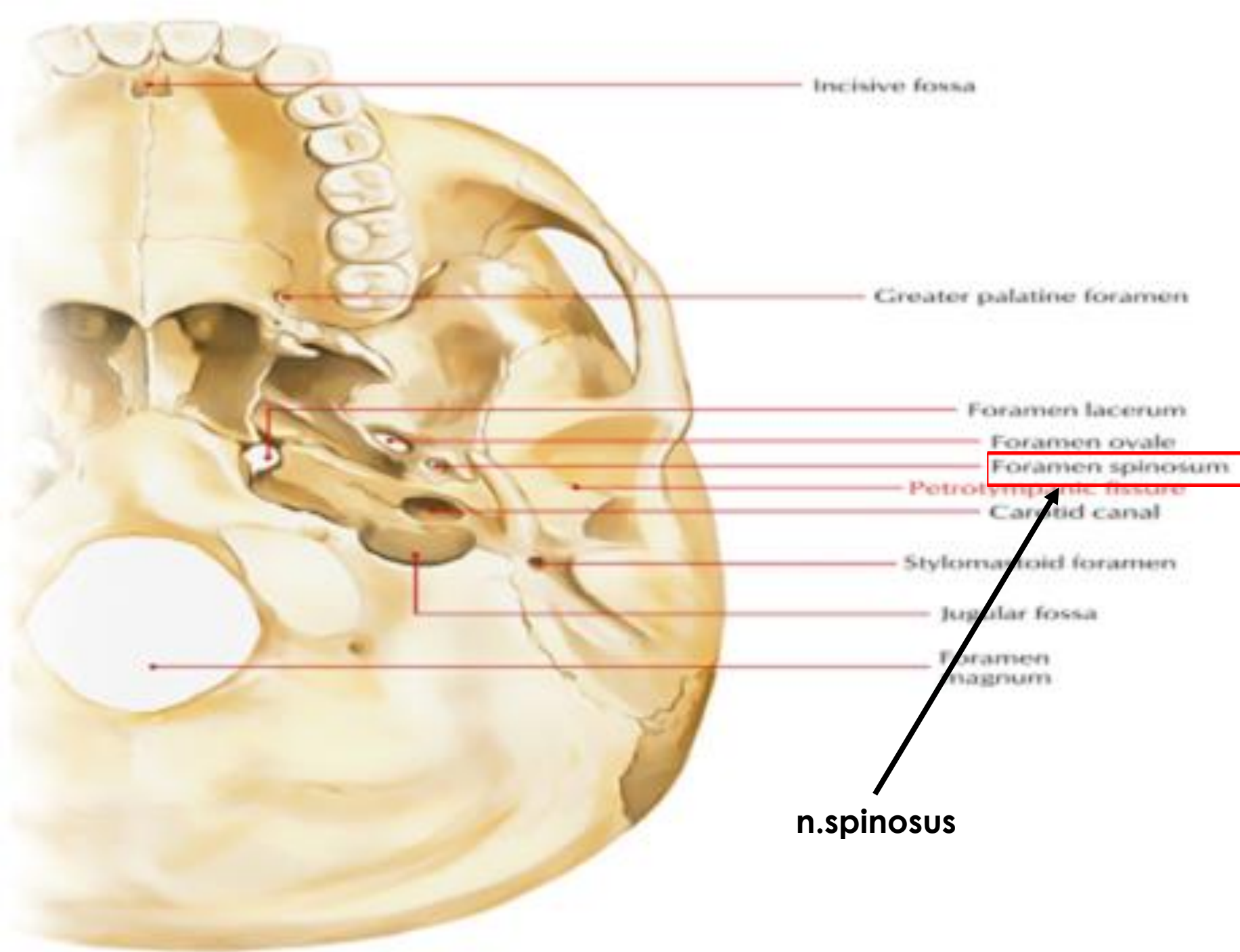


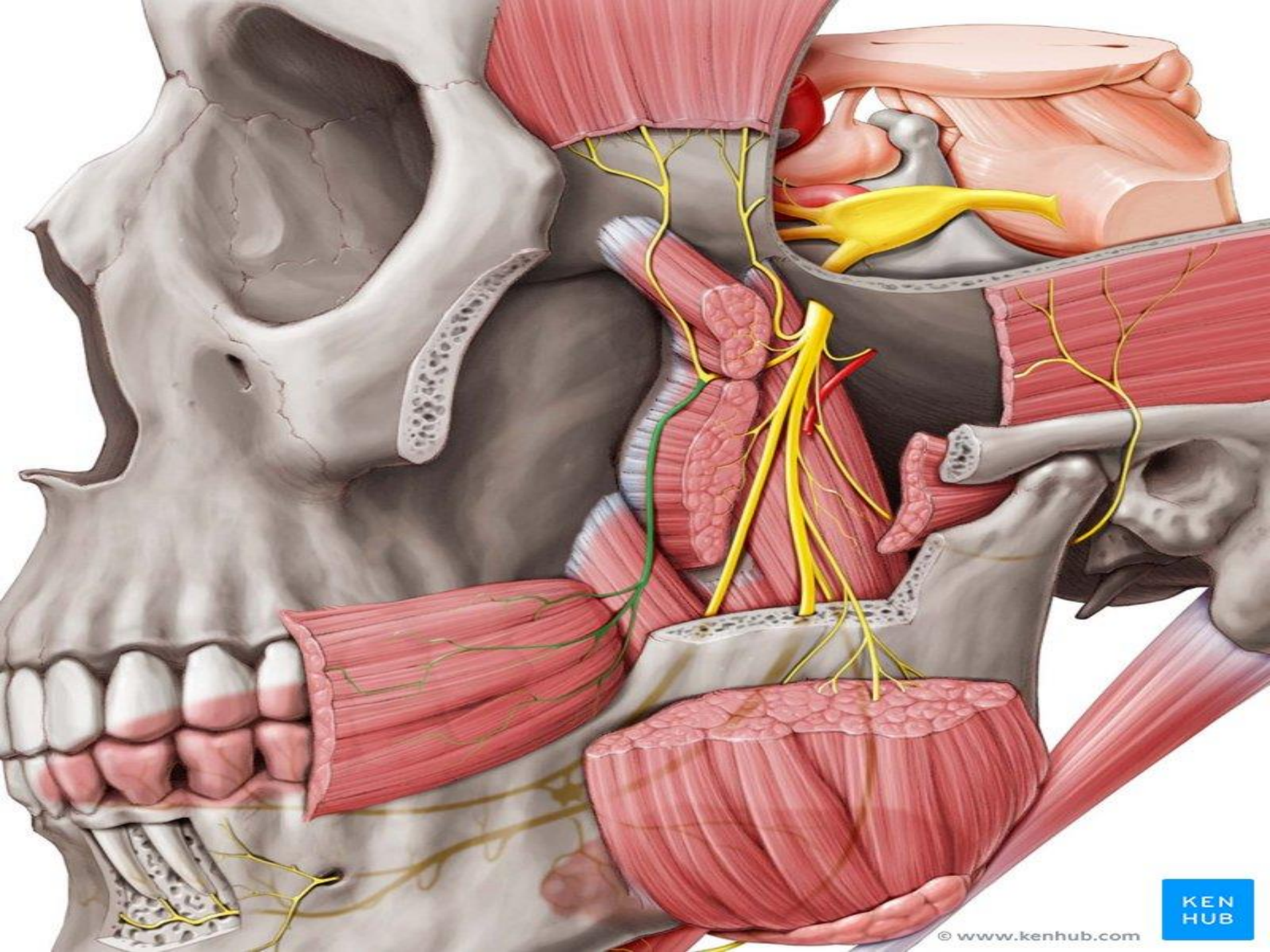
SENSORY SUPPLY OF MANDIBULAR NERVE:

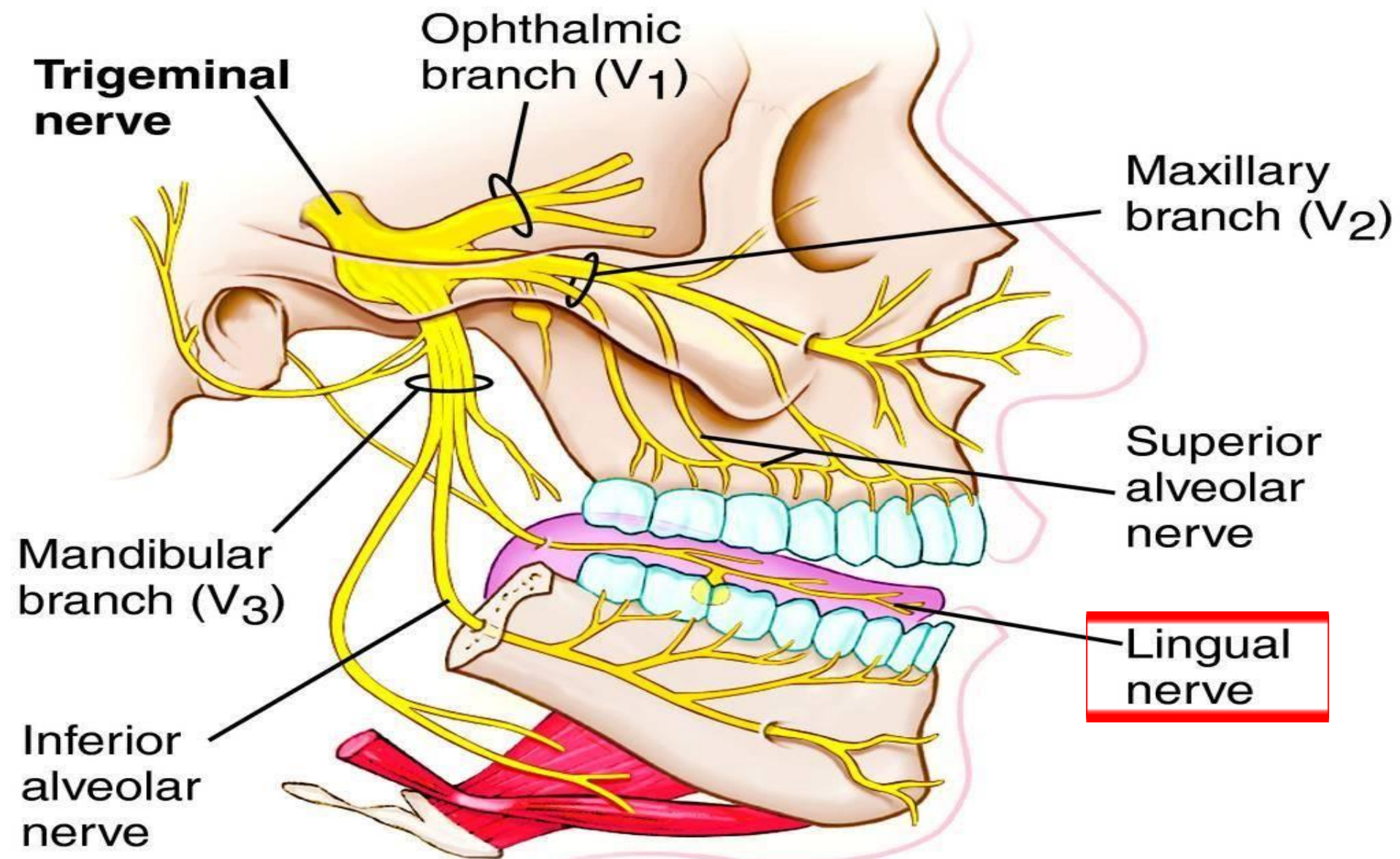
- Mucous membranes and floor of the oral cavity
- External ear
- Lower lip
- Chin
- Anterior 2/3 of the tongue (**only general sensation**; special taste sensation supplied by the chorda tympani, a branch of the facial nerve VII)
- Lower molars, premolars, canine and incisors teeth and their gingiva

MANDIBULAR NERVE

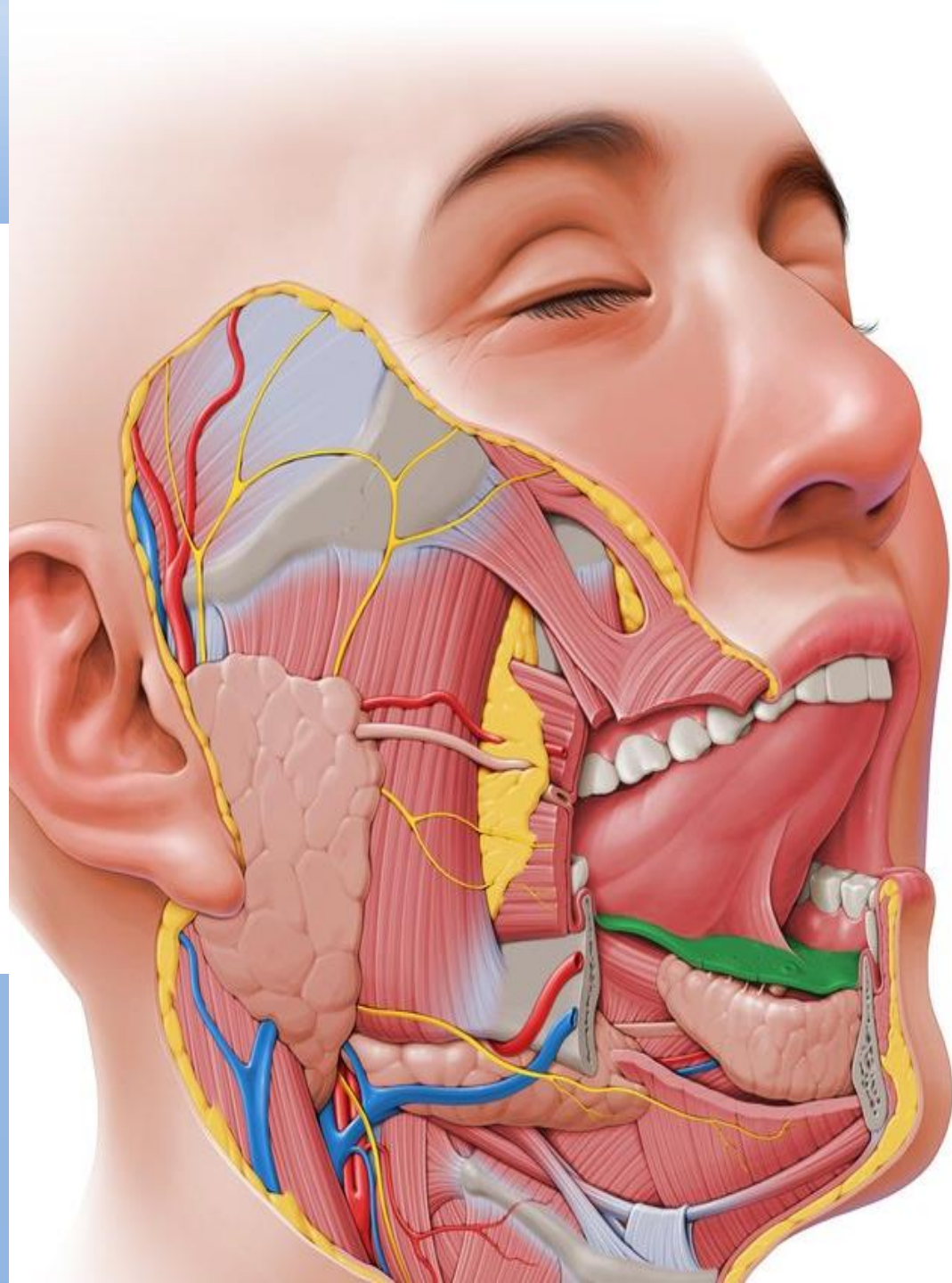
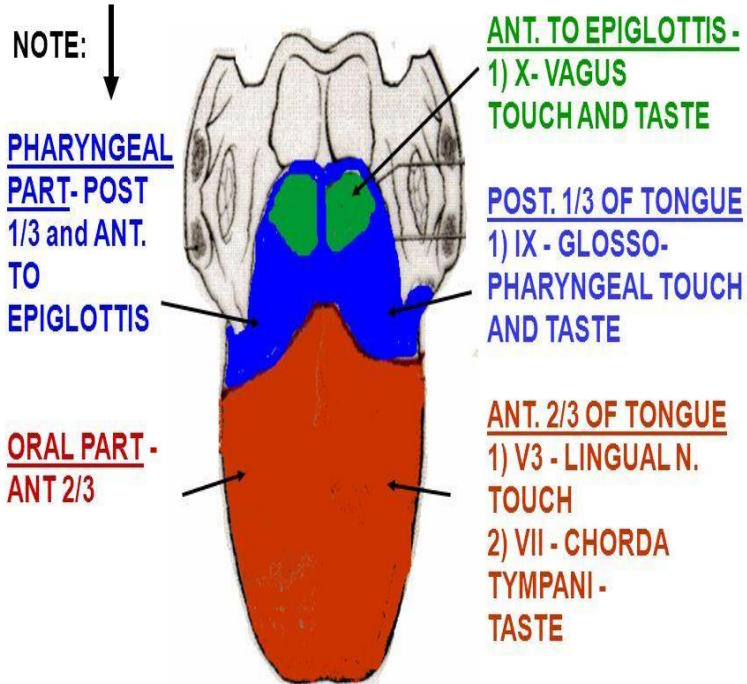


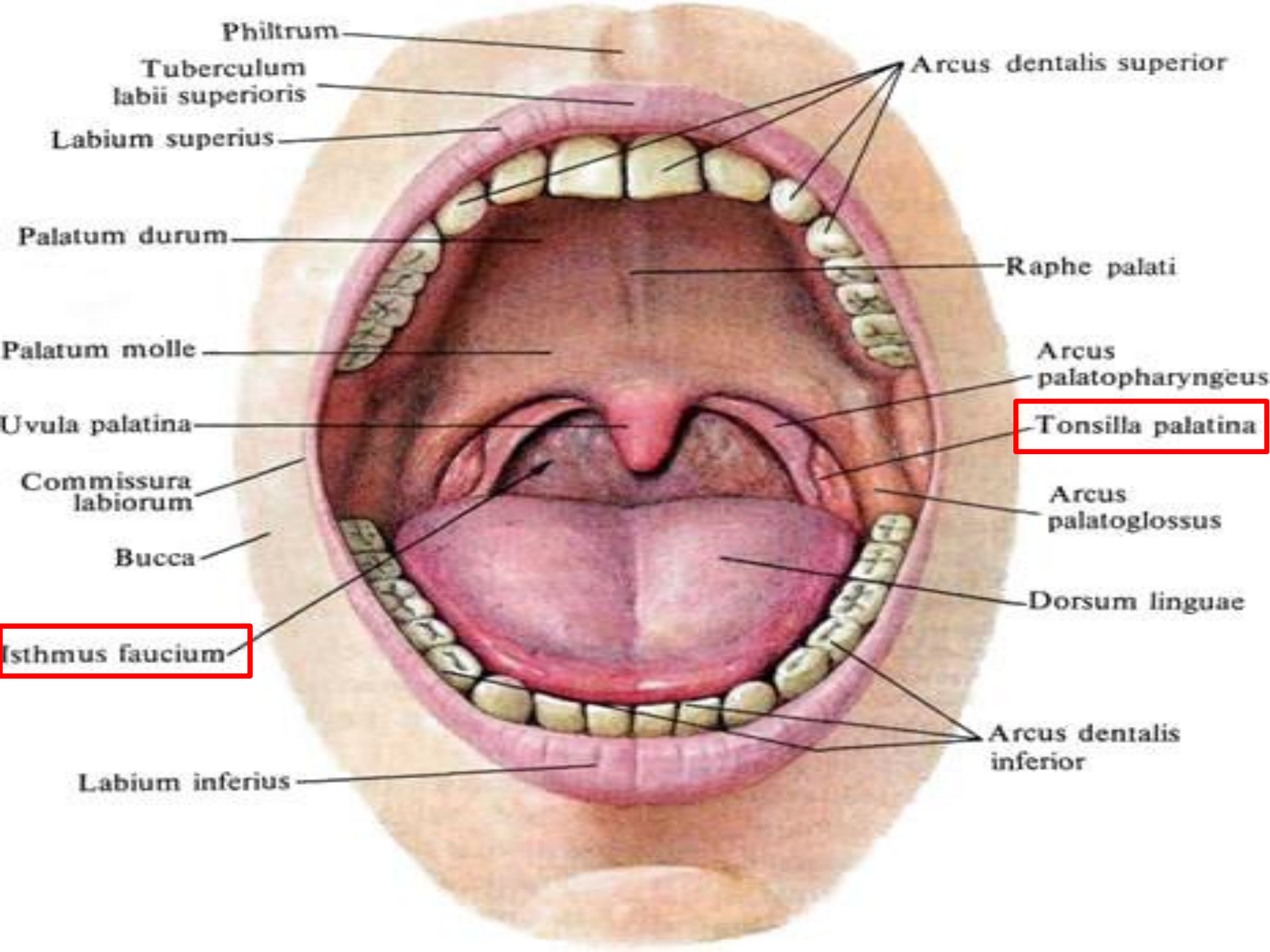




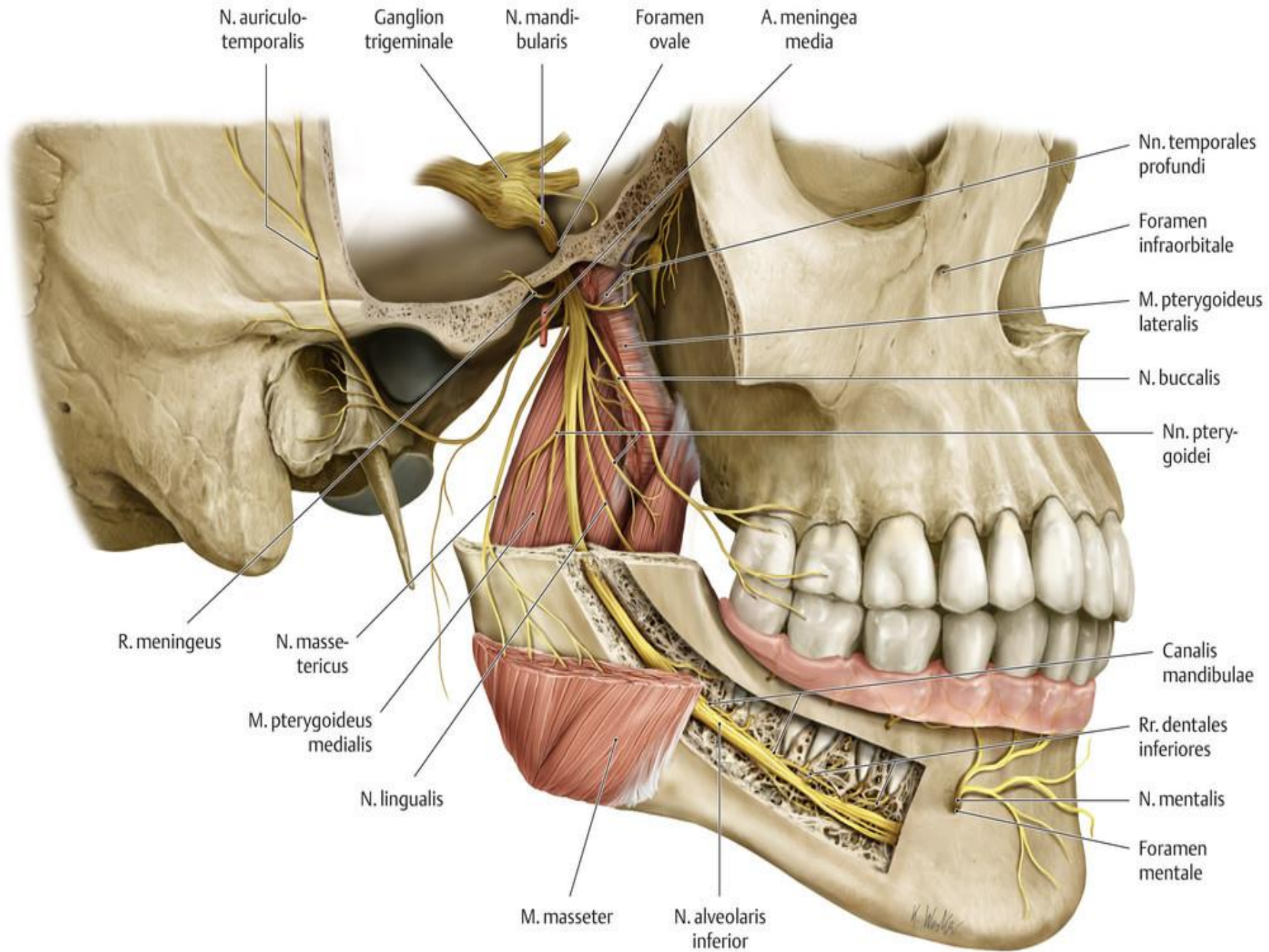


SENSORY INNERVATION OF TONGUE

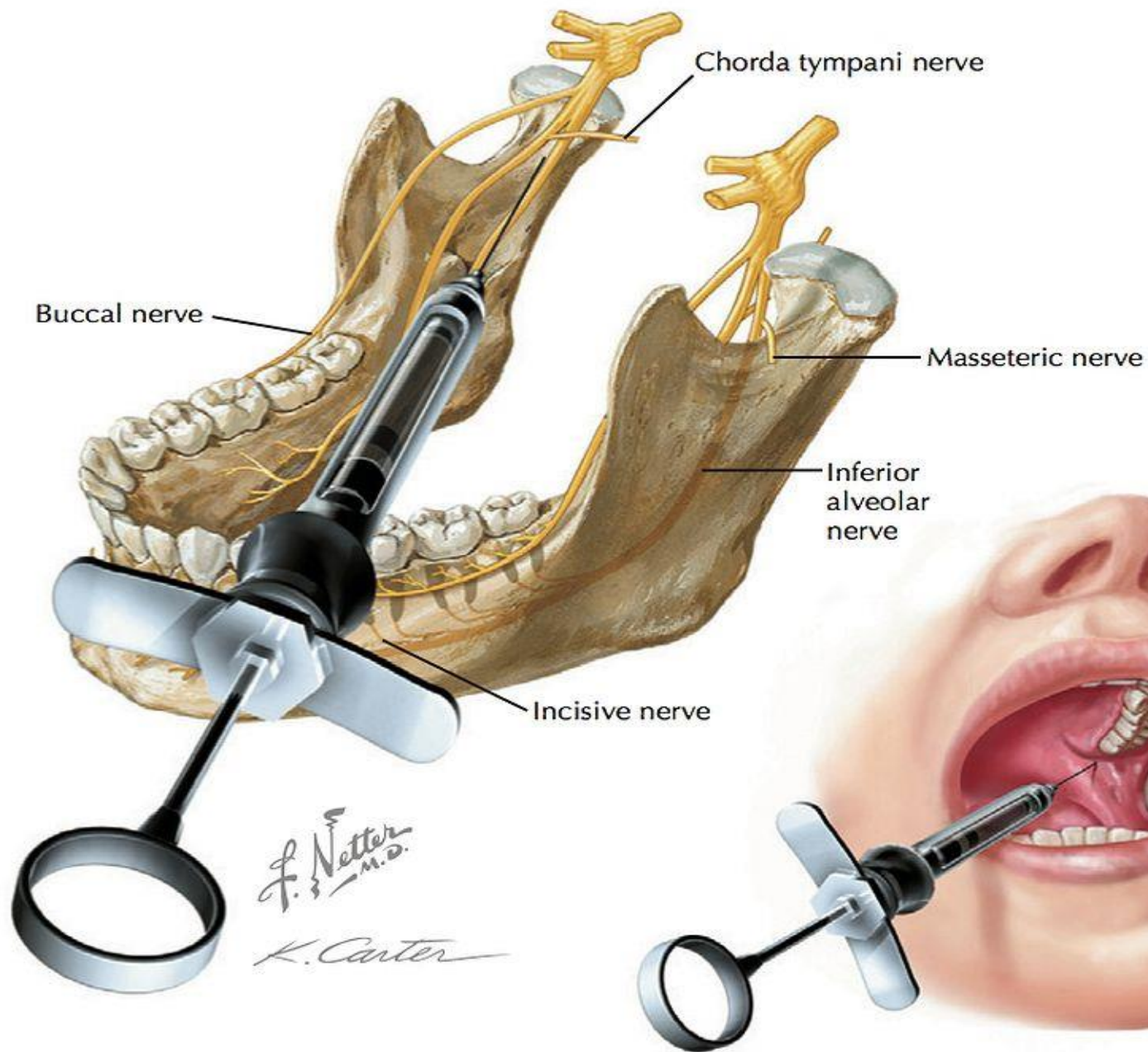


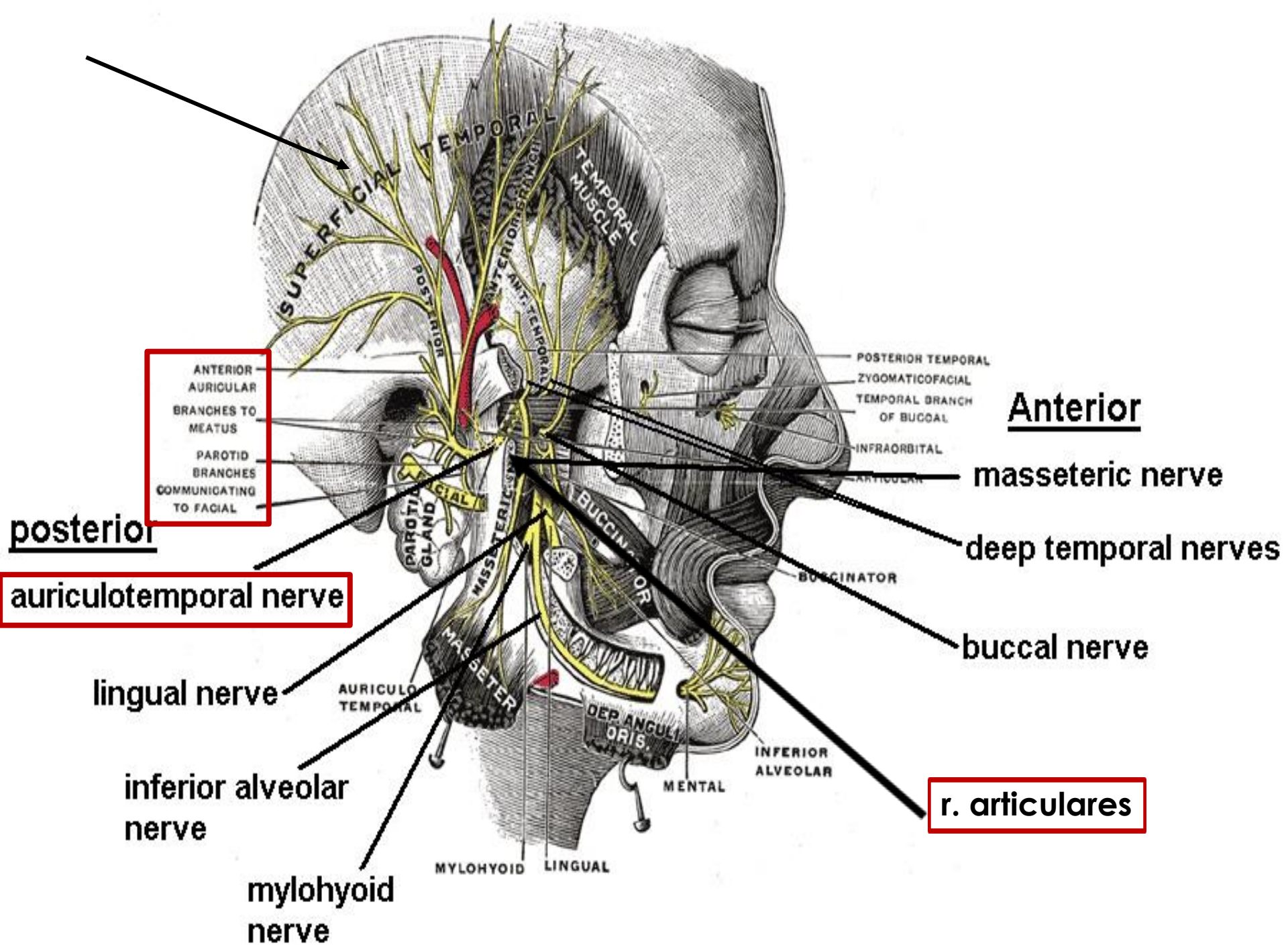


- ◎ The **inferior alveolar nerve** - a branch of V3, travels through the **mandibular foramen** and **mandibular canal**. Within the mandibular canal, the inferior alveolar nerve forms the inferior dental plexus, which innervates the lower teeth. A major branch of this plexus, the **mental nerve**, supplies the skin and mucous membranes of the lower lip, skin of the chin, and the gingiva of the lower teeth.



- ◉ In some dental procedures which require a **local anaesthesia**, the inferior alveolar nerve is blocked before it gives rise to the plexus.
- ◉ The anaesthetic solution is administered at the **mandibular foramen**, causing numbness of area supplied by the inferior alveolar nerve. The anaesthetic fluid also spreads to the **lingual nerve** which originates near the inferior alveolar nerve, causing numbness of the anterior 2/3 of the tongue.





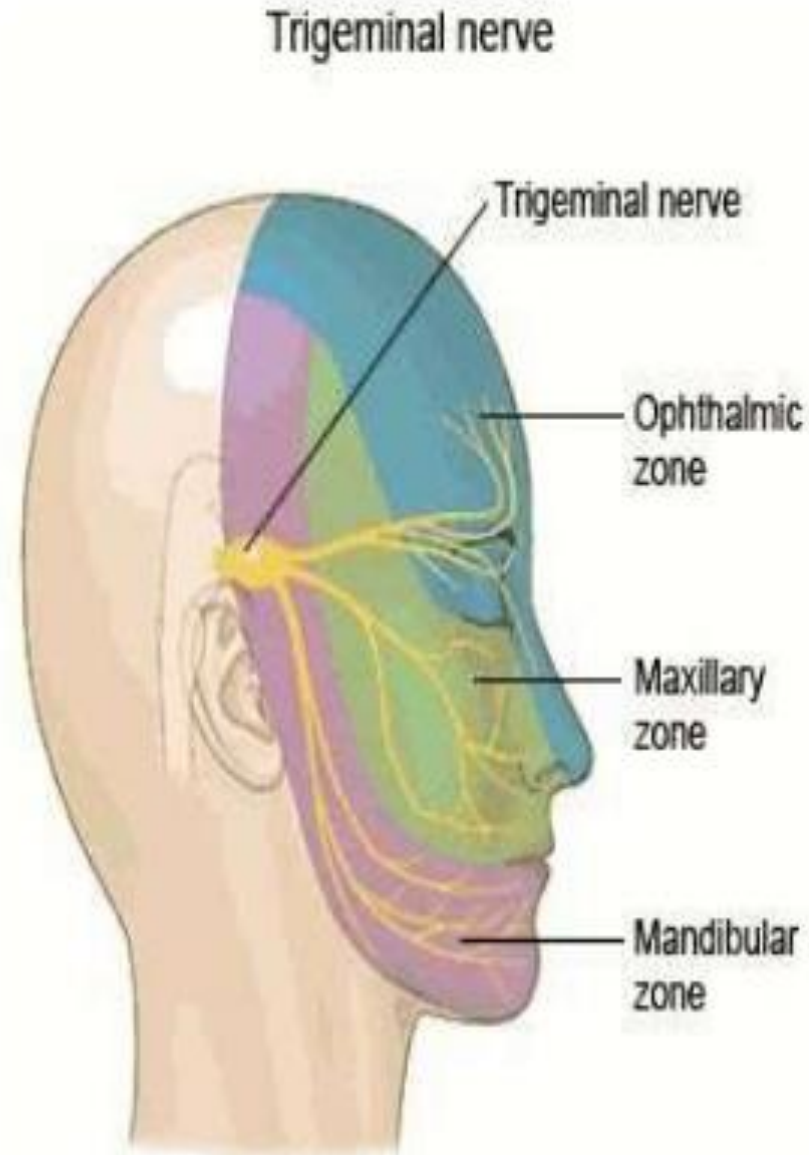
Sensory supply

Cutaneous innervation of the face is by

Trigeminal nerve

Areas supplied :

- **Ophthalmic zone** includes tip and side of the nose, upper eye lid and forehead
- **Maxillary zone** upper lip, part of the side of nose, lower eye lid, cheeks and small part of temple
- **Mandibular zone** include lower chin, skin overlying mandible, part of pinna, external acoustic meatus and temple

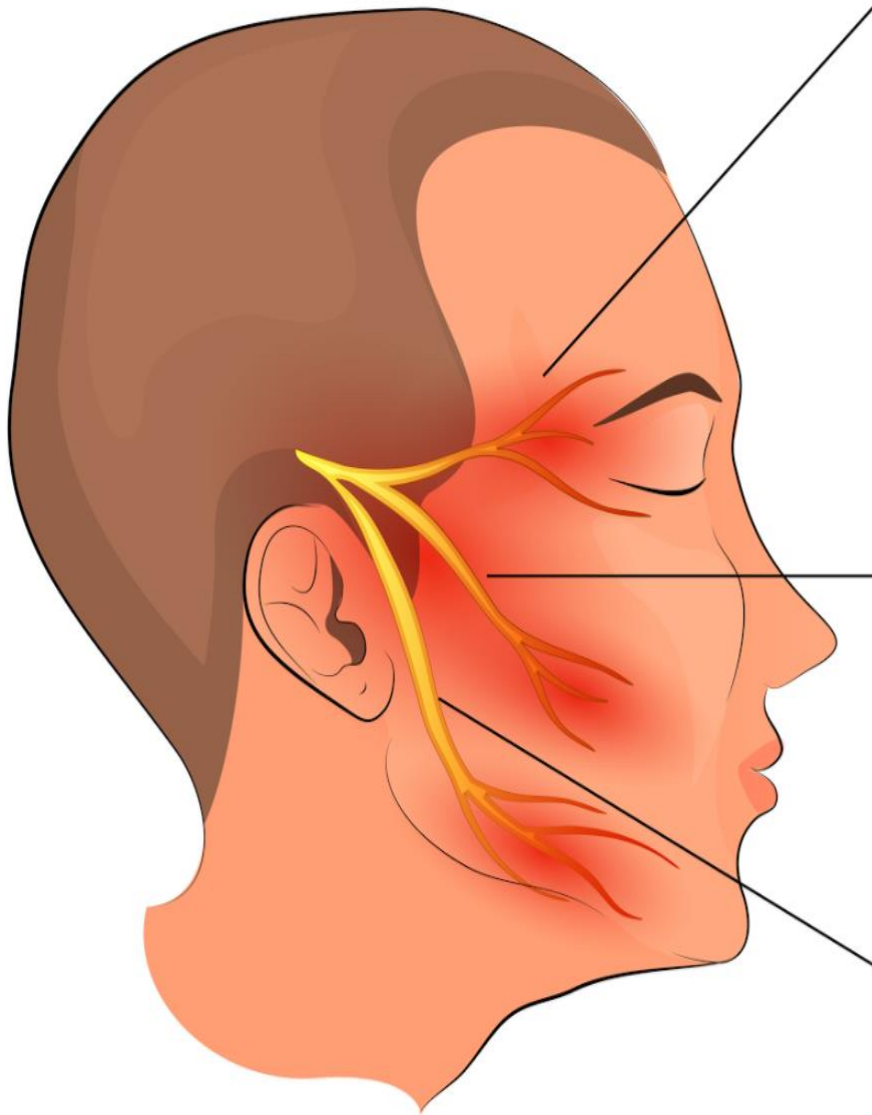


Opthalmic: eye, brow,
forehead & front scalp


TRIGEMINAL NEURALGIA

Maxillary: Upper lip, teeth
& gum; lower eyelid &
side of nose

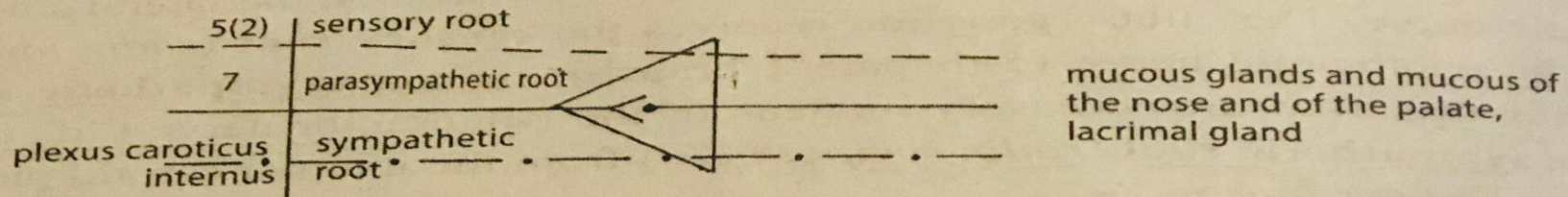
Mandibular: Lower lip,
teeth & gum; lower jaw to
side of head




The Ciliary ganglion




The Pterygopalatine ganglion




The Otic ganglion



The Submandibular ganglion

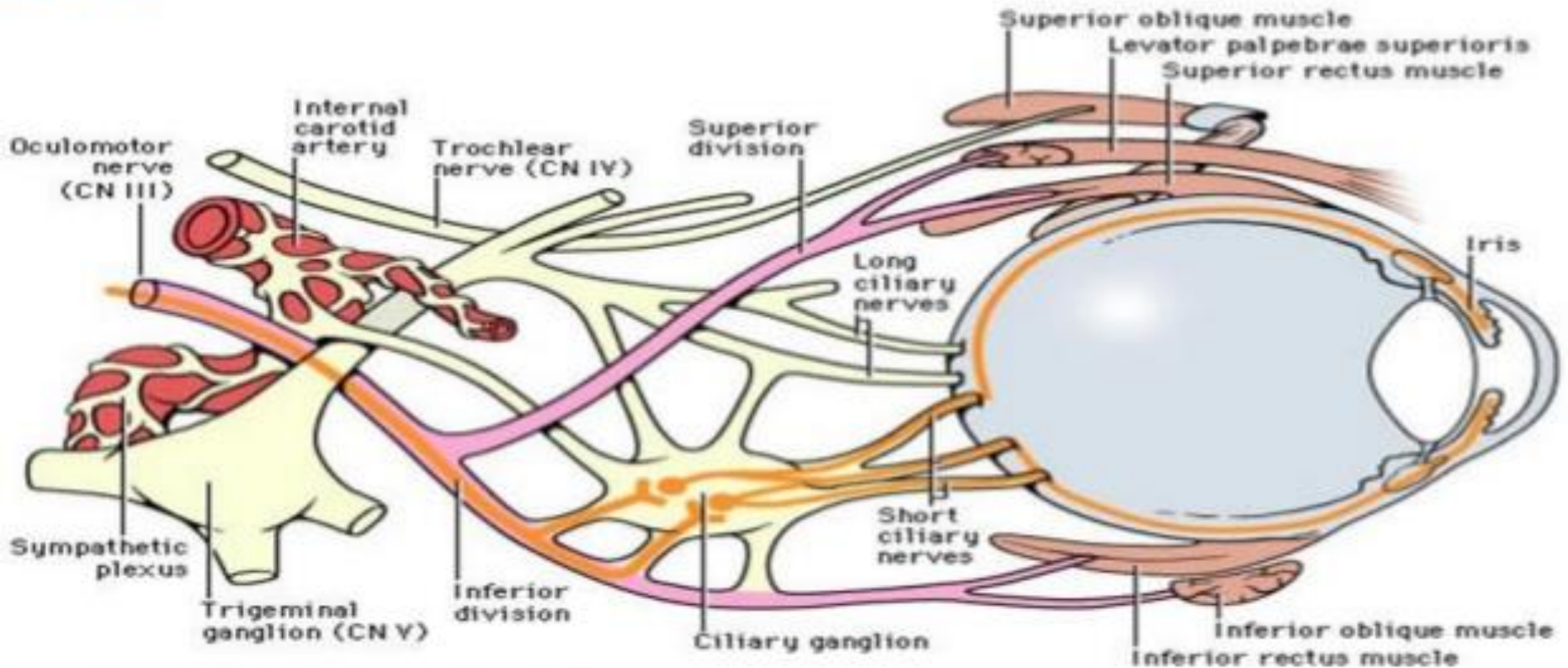


The Sublingual ganglion



Parasympathetic innervation (Ciliary ganglion)

1. **The preganglionic fibers** originate from **Edinger Westphal nucleus** in the midbrain & run with the oculomotor nerve to relay in the **ciliary ganglion**.
2. From the ciliary ganglion, **postganglionic fibers** are carried by the **short ciliary nerves** to innervate the sphincter pupillae and ciliary muscles”.



Sympathetic innervation : (enter the ciliary ganglion & leave it without relay)

1. **Preganglionic** sympathetic fibres relay in Superior cervical ganglion
2. **Postganglionic fibres** are carried by **long ciliary nerves** from sympathetic plexus around the internal carotid artery to supply dilator pupillae muscle

SPHENOPALATINE (PTERYGOPALATINE) GANGLION

Site: in the **pterygopalatine fossa**, below maxillary nerve, connected to it by 2 ganglionic branches .

ROOTS :

Sensory root : maxillary nerve

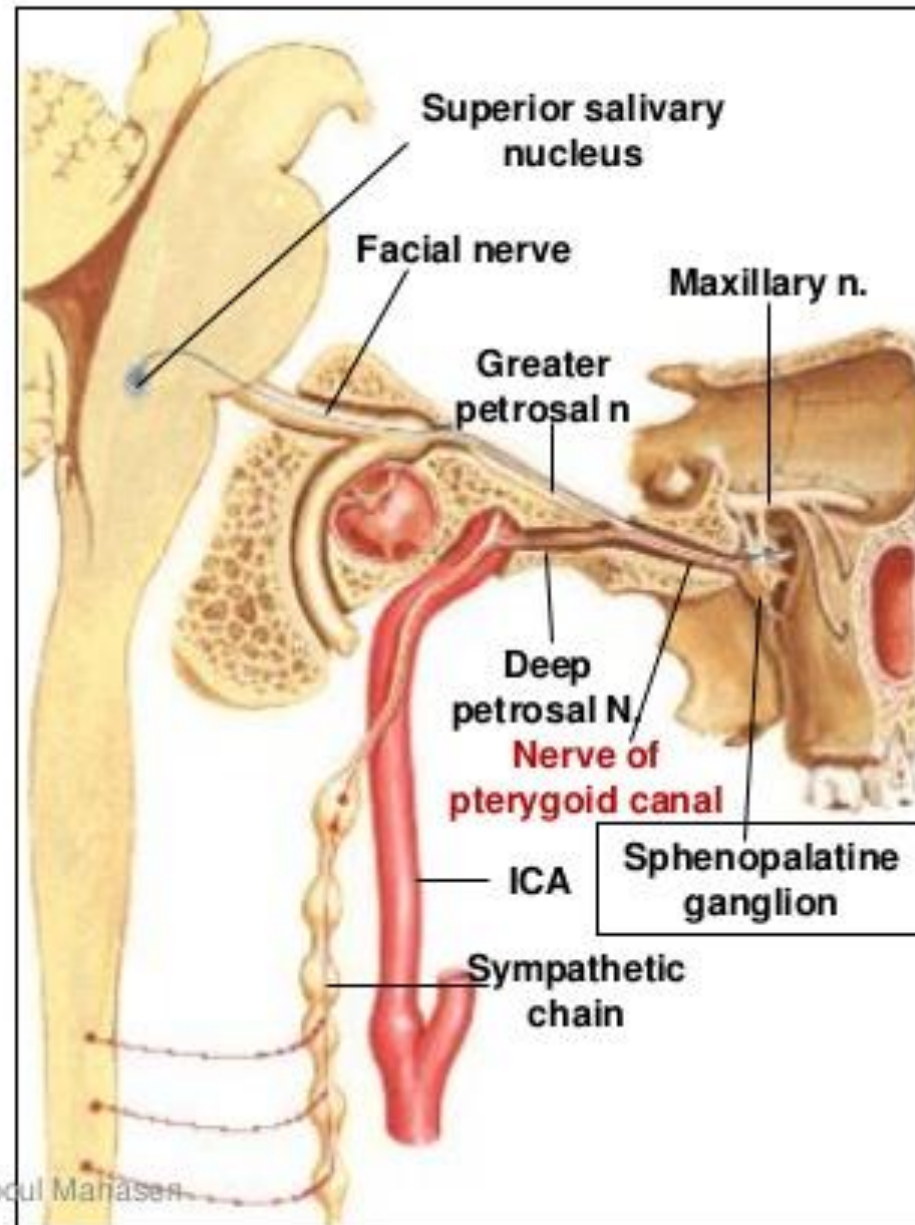
Parasympathetic root : greater petrosal nerve from facial nerve .

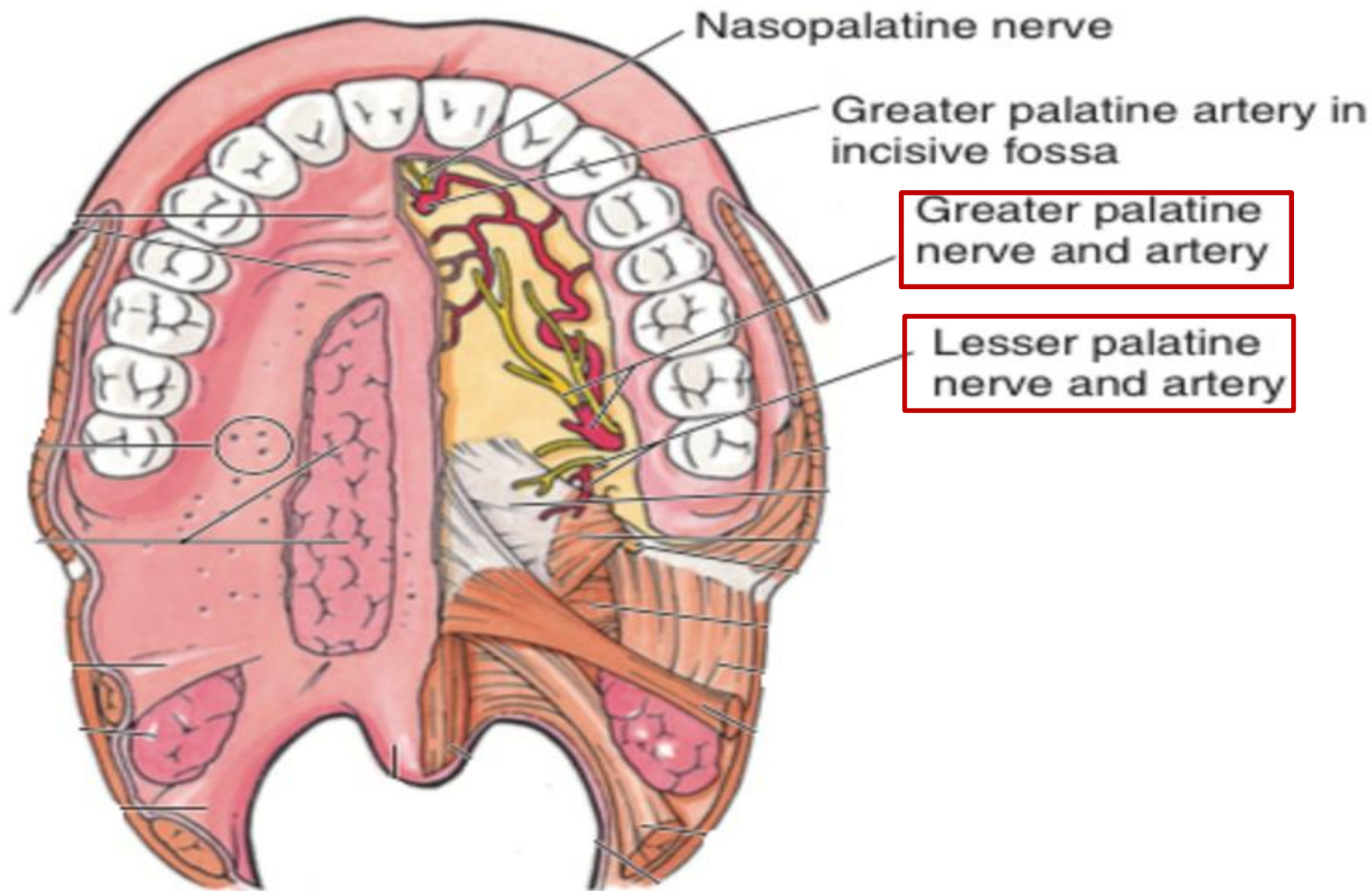
Sympathetic root : deep petrosal nerve , fibers originate from the plexus around internal carotid artery

Parasympathetic root

Nucleus : lacrimal nucleus (pons)

Preganglionic fibres : pass along **greater superficial petrosal nerve** → joins **deep petrosal** in the foramen lacerum to form → **nerve to pterygoid canal (Vidian N.)** → pass through pterygoid canal → **ganglion**





OTIC GANGLION

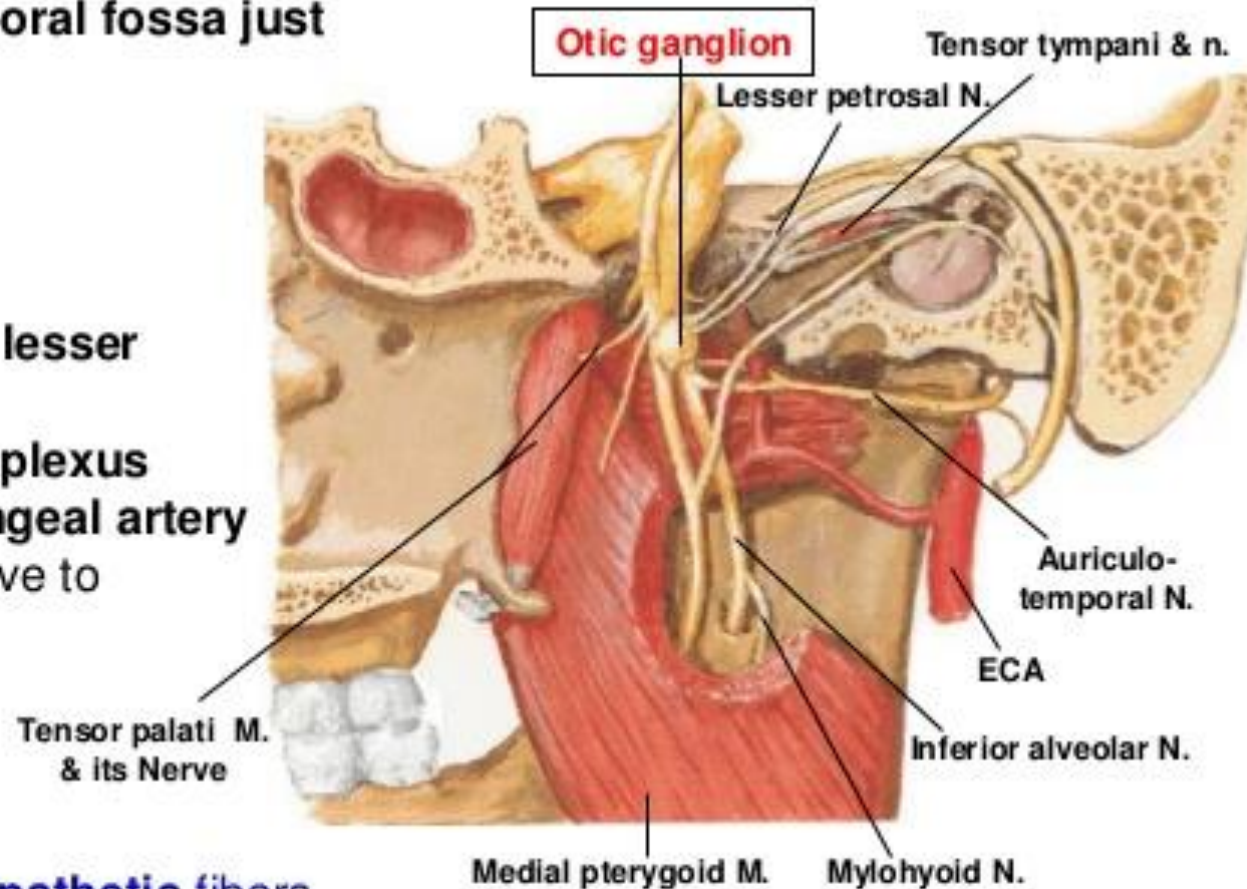
Site : lies in the infratemporal fossa just below the foramen ovale

Roots:

1. **Parasympathetic root** : lesser petrosal nerve
2. **Sympathetic root** : from plexus around the middle meningeal artery
3. **Motor root** : from the nerve to medial pterygoid muscle

Branches:

1. **Postganglionic parasympathetic fibers** carried by the auriculotemporal nerve to the **parotid gland**
2. **Sympathetic fibers** to the parotid vessels
3. **Motor fibres**: to tensor palati and tensor tympani muscles .

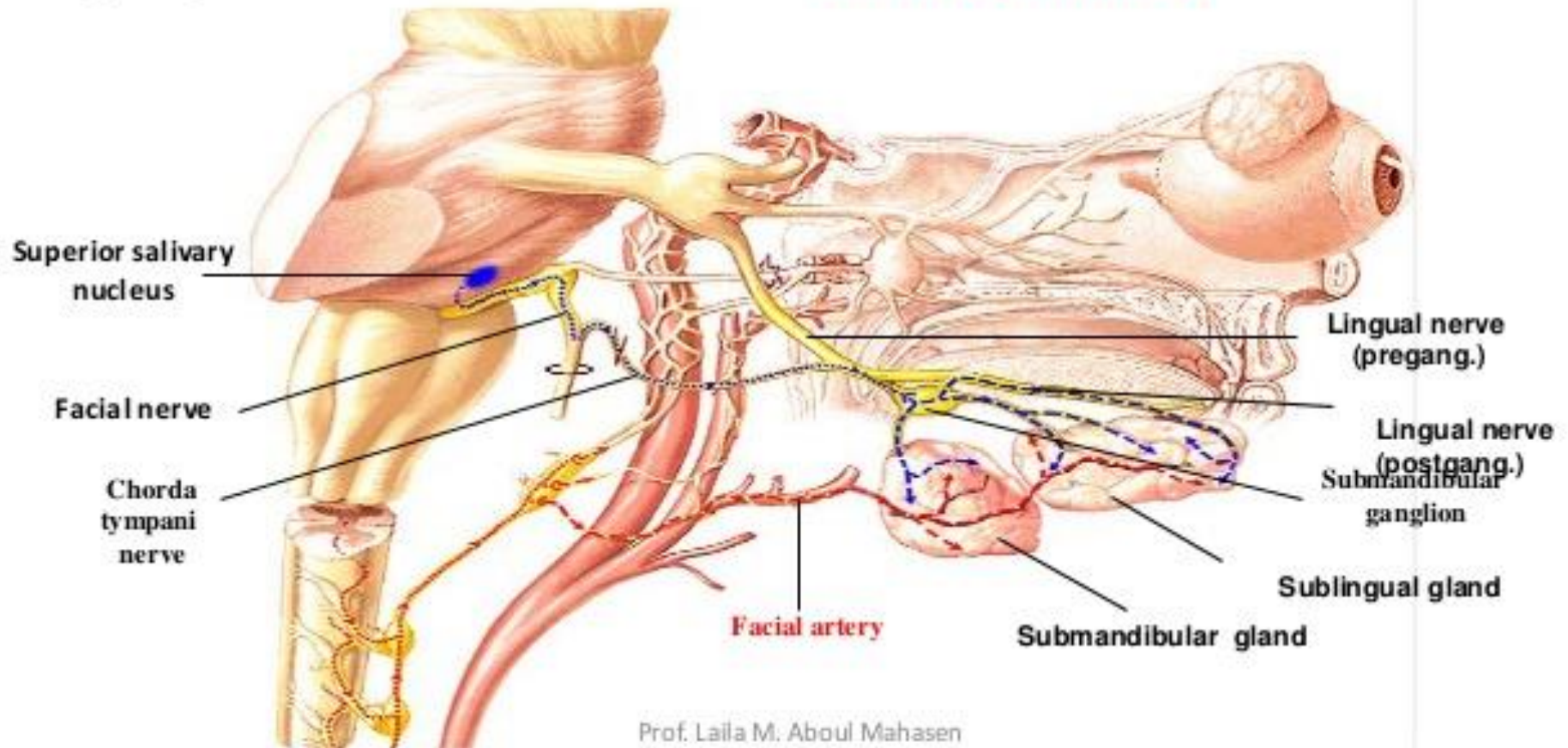


Submandibular Ganglion

Sensory : lingual N..

Sympathetic : plexus around **facial A.**

Parasympathetic: preganglionic parasympathetic fibers from the **chorda tympani** (from **facial N.**) relay in **submandibular ganglion** & postganglionic fibres **carried by the lingual nerve**



Submandibular Ganglion

A small parasympathetic ganglion suspended from the lingual nerve on the upper part of lateral surface of hyoglossus muscle

Roots:

Sensory: lingual N. .

Sympathetic: plexus around facial & lingual arteries

***Sensory & sympathetic fibres transverse the ganglion without relay .**

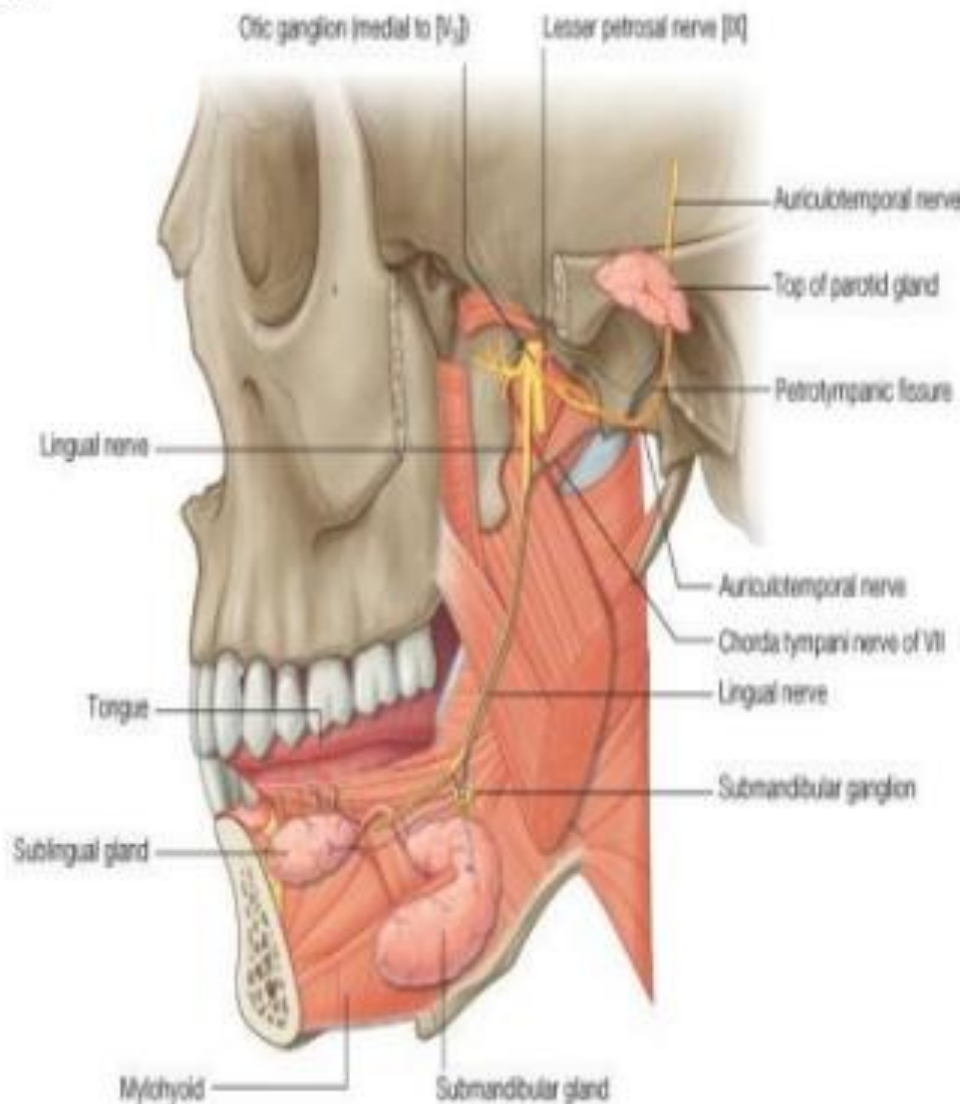
Parasympathetic: preganglionic fibers from chorda tympani (from facial N.) relay in the ganglion & postganglionic fibres are carried by lingual nerve

Branches:

1.Parasympathetic secretomotor to both submandibular and sublingual glands

2.Sensory: carry sensations from the submandibular and sublingual glands

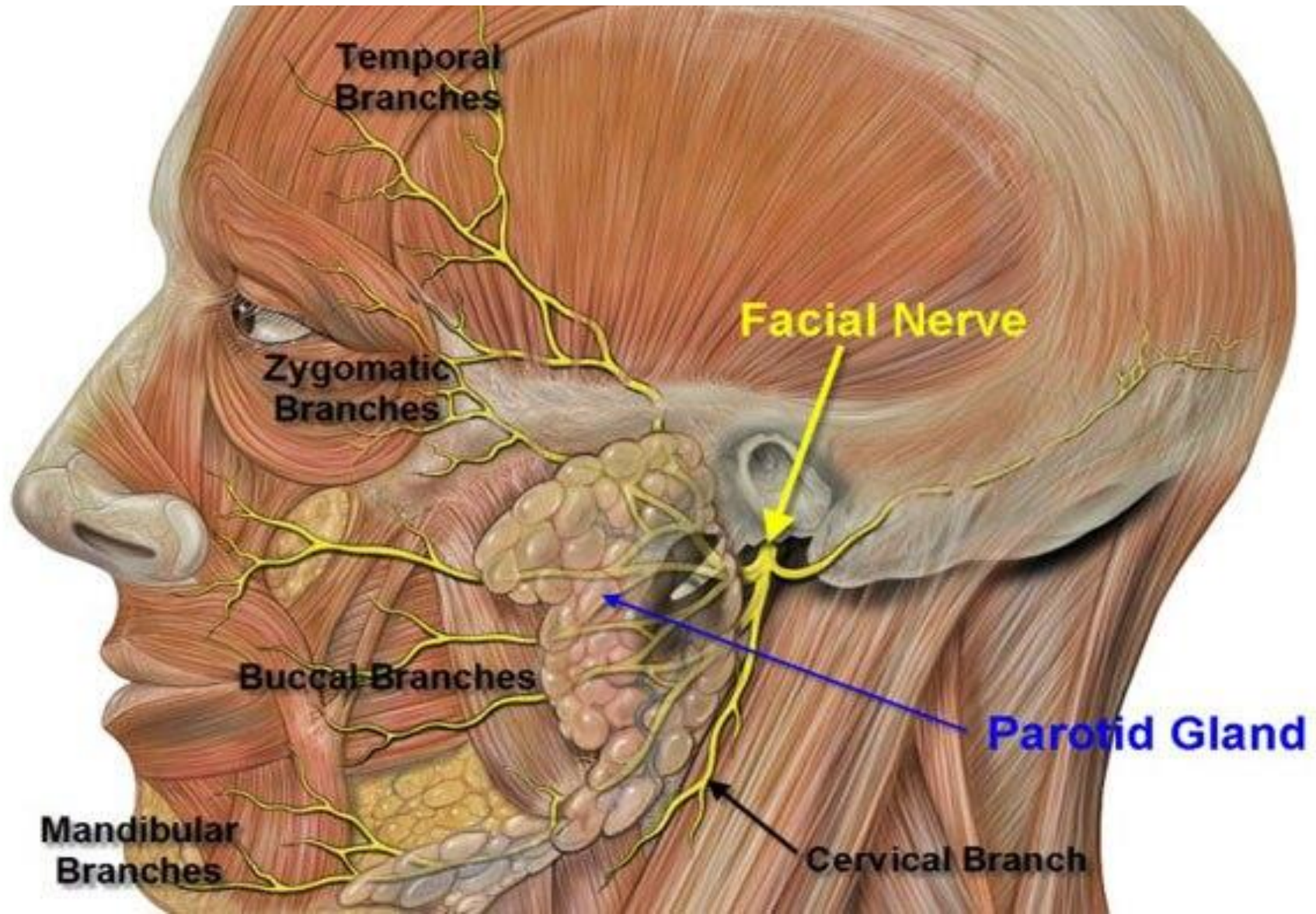
3.Sympathetic: to the vessels of the submandibular and sublingual glands



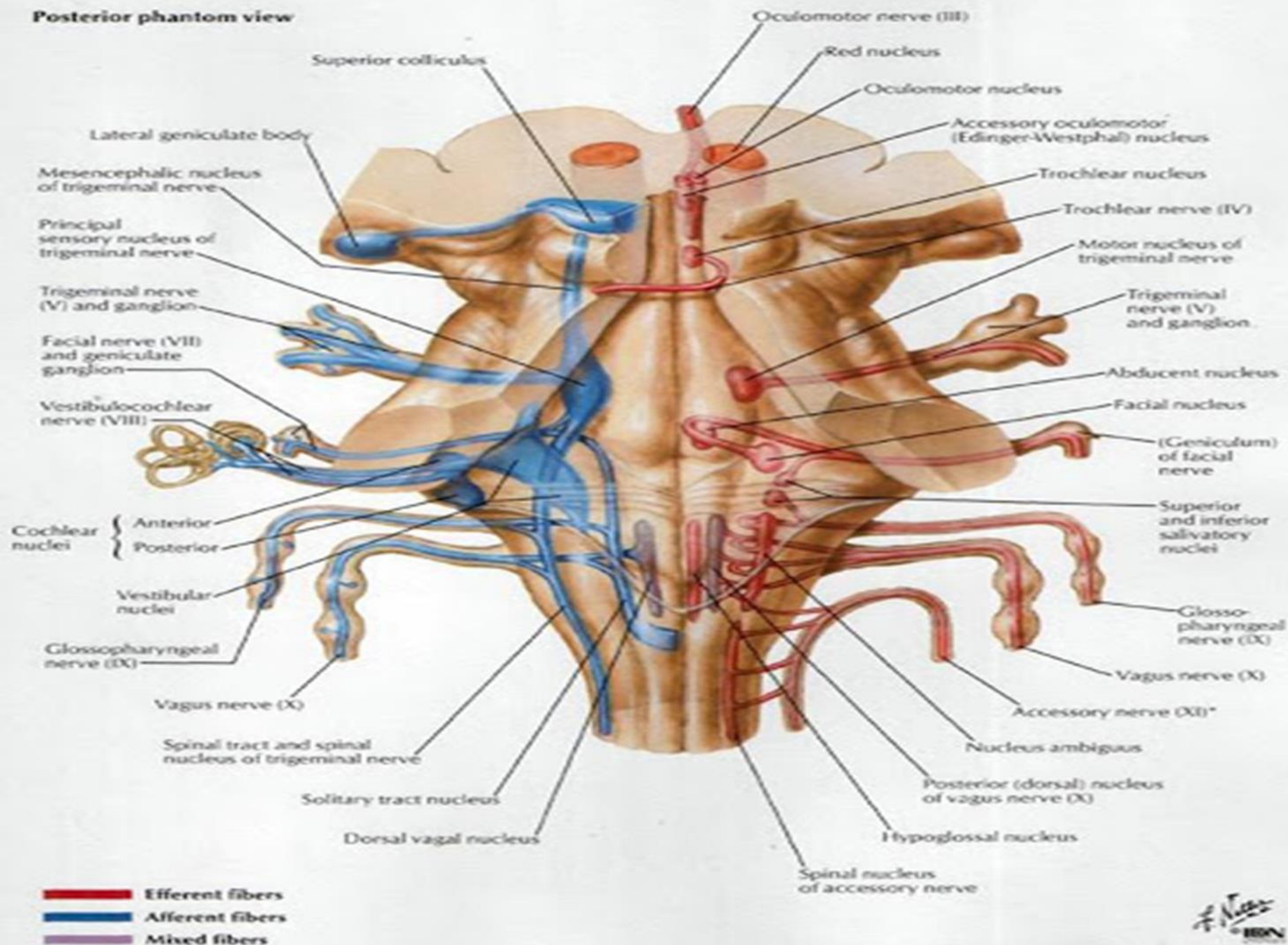
THX FOR YOUR ATTENTION



The Facial nerve

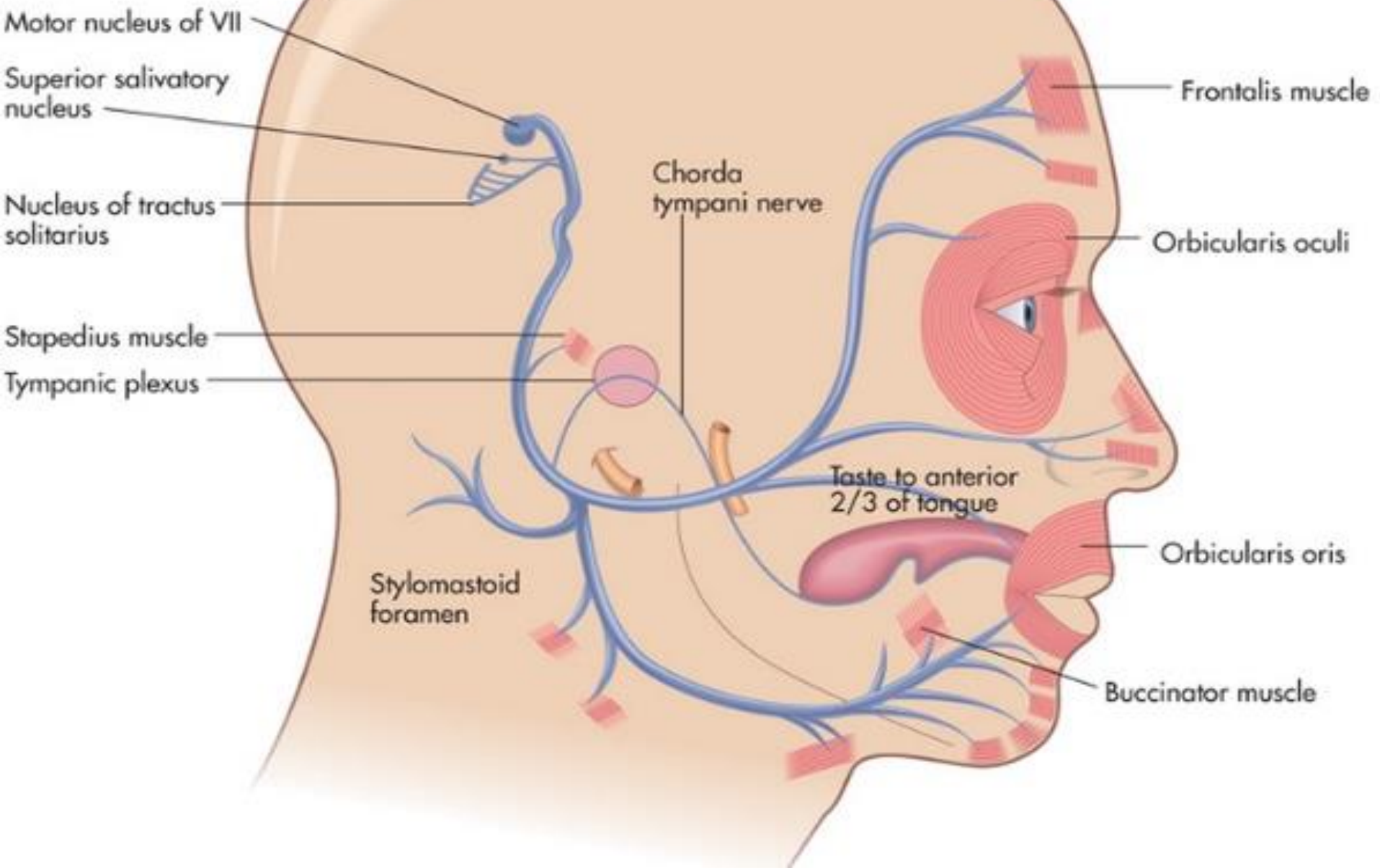


Posterior phantom view

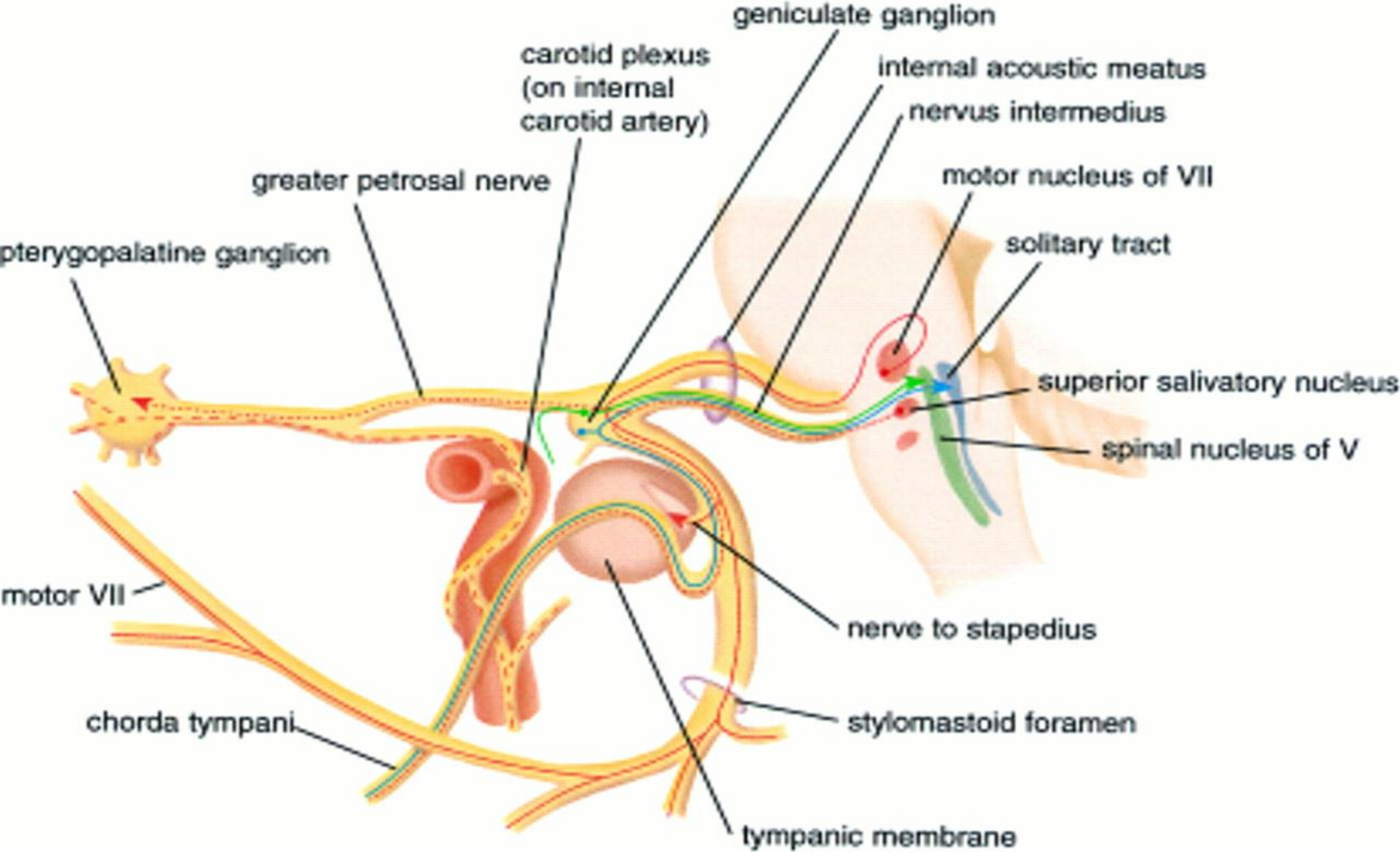


The Facial nerve

- The facial nerve is associated with the derivatives of the second pharyngeal arch.
- **Motor**: Innervates the muscles of *facial expression, the posterior belly of the digastric, the stylohyoid and the stapedius muscles.*
- **Sensory**: A small area **around the concha of the auricle.**
- **Special Sensory**: Provides **special taste sensation to the anterior 2/3 of the tongue.**
- **Parasympathetic**: Supplies *many of the glands of the head and neck, including:*
 - > *Submandibular and sublingual salivary glands.*
 - > *Nasal, palatine and pharyngeal mucous glands.*
 - > *Lacrimal glands.*



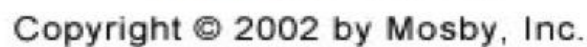
- The facial **motor nucleus** is the main nucleus of the facial nerve, but it must be noted that the nerve also contains **secretomotor fibers** (from the **superior salivatory nucleus**), **taste fibers** (connected to the solitary complex), and a small group of **cutaneous sensory fibers** that supply the ear (connected to the trigeminal complex). The facial **motor nucleus** lies laterally of the 6th CN nucleus.

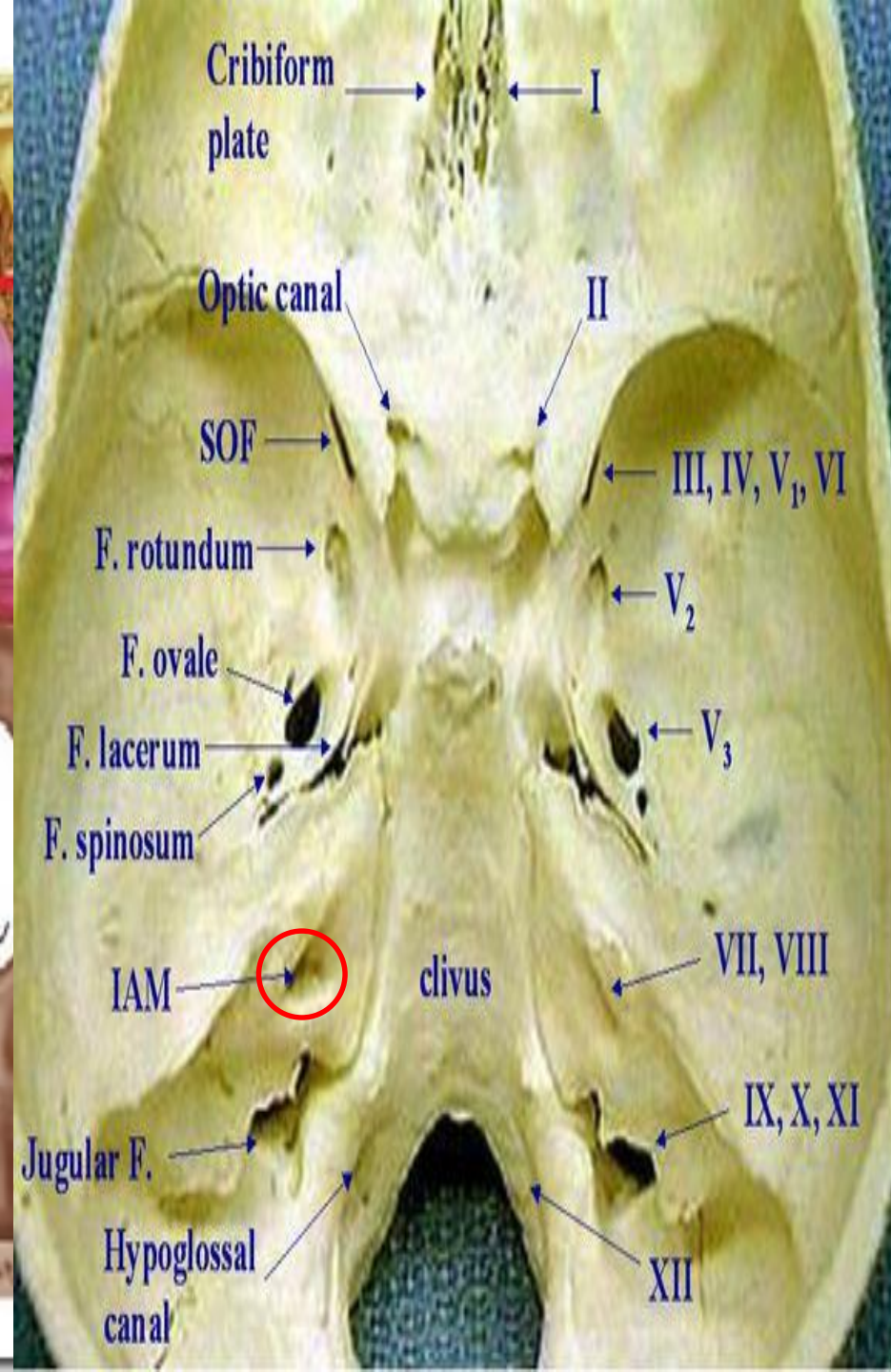
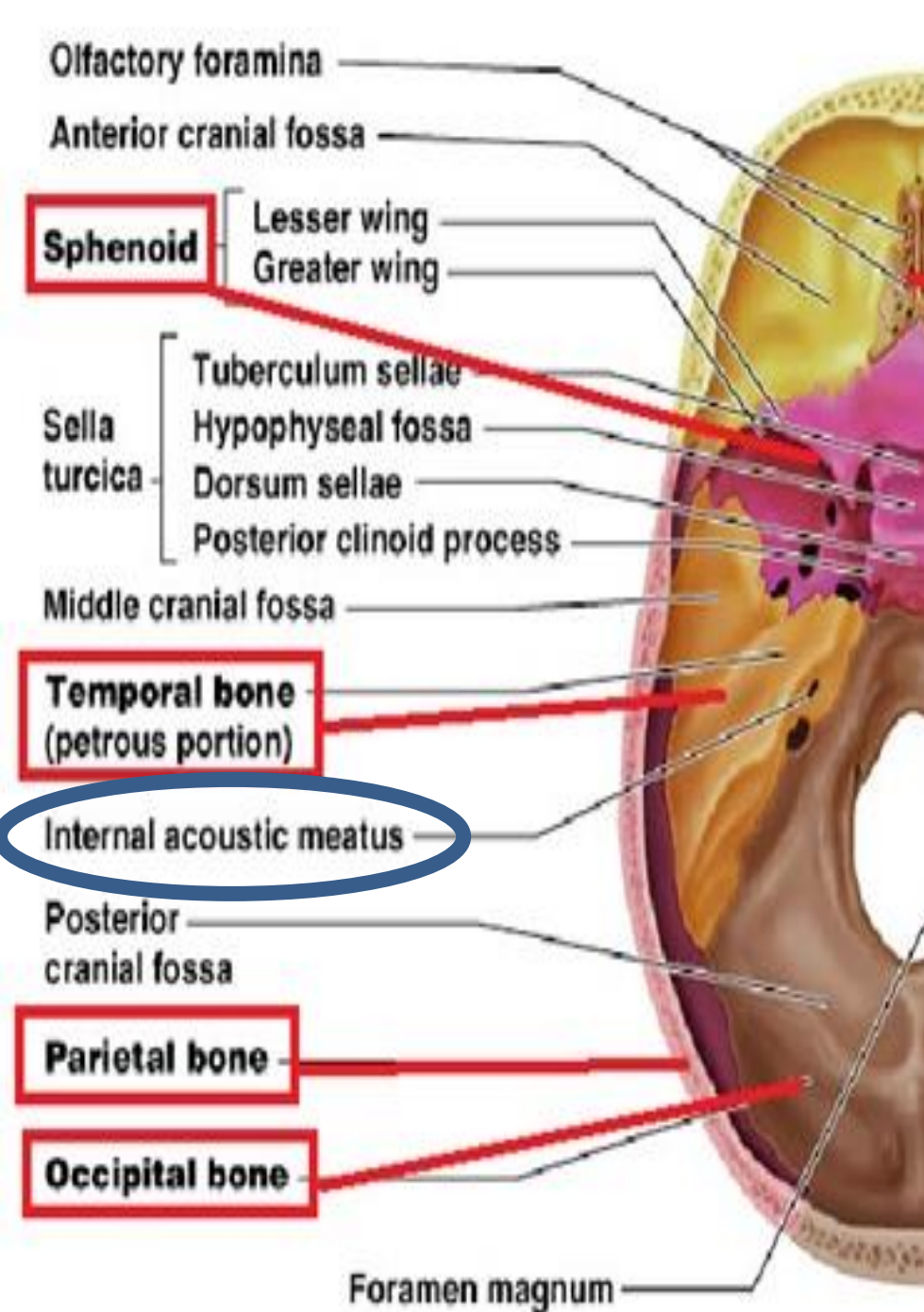


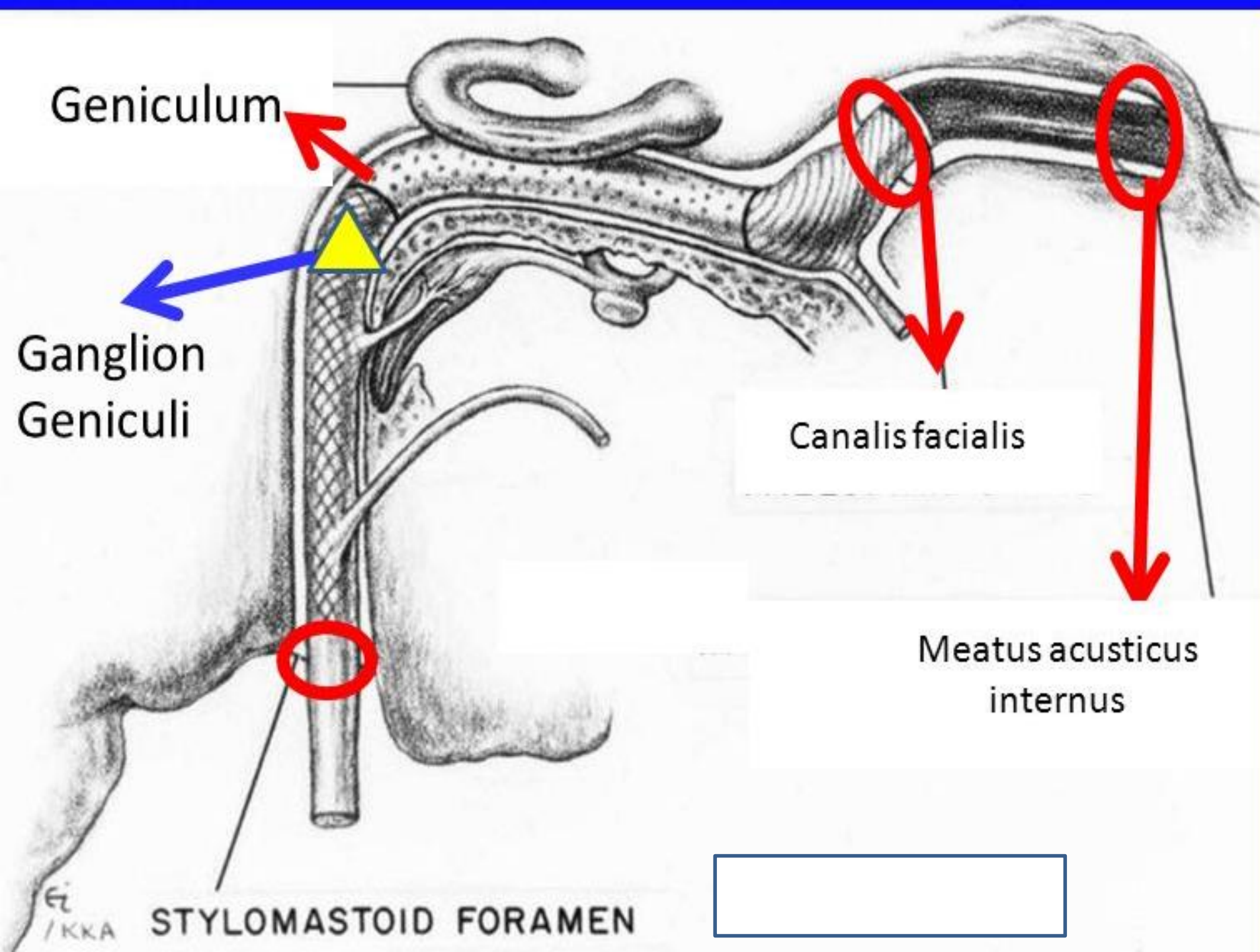
- special visceral efferent
 - special visceral afferent
 - - - sympathetic
 - - - parasympathetic
 - general somatic afferent
- special visceral efferent

- The **facial motor nucleus** is the main nucleus of the facial nerve; it supplies the superficial muscles of the face. In addition to the supply of the facial muscles, the facial nerve carries secretomotor fibres (from the superior salivatory nucleus), taste fibers (connected to the solitary complex), and a small group of cutaneous sensory fibers that supply the external ear (connected to the trigeminal complex).
- **The secretomotor and taste fibers form a separate root of the nerve, called the nervus intermedius.**

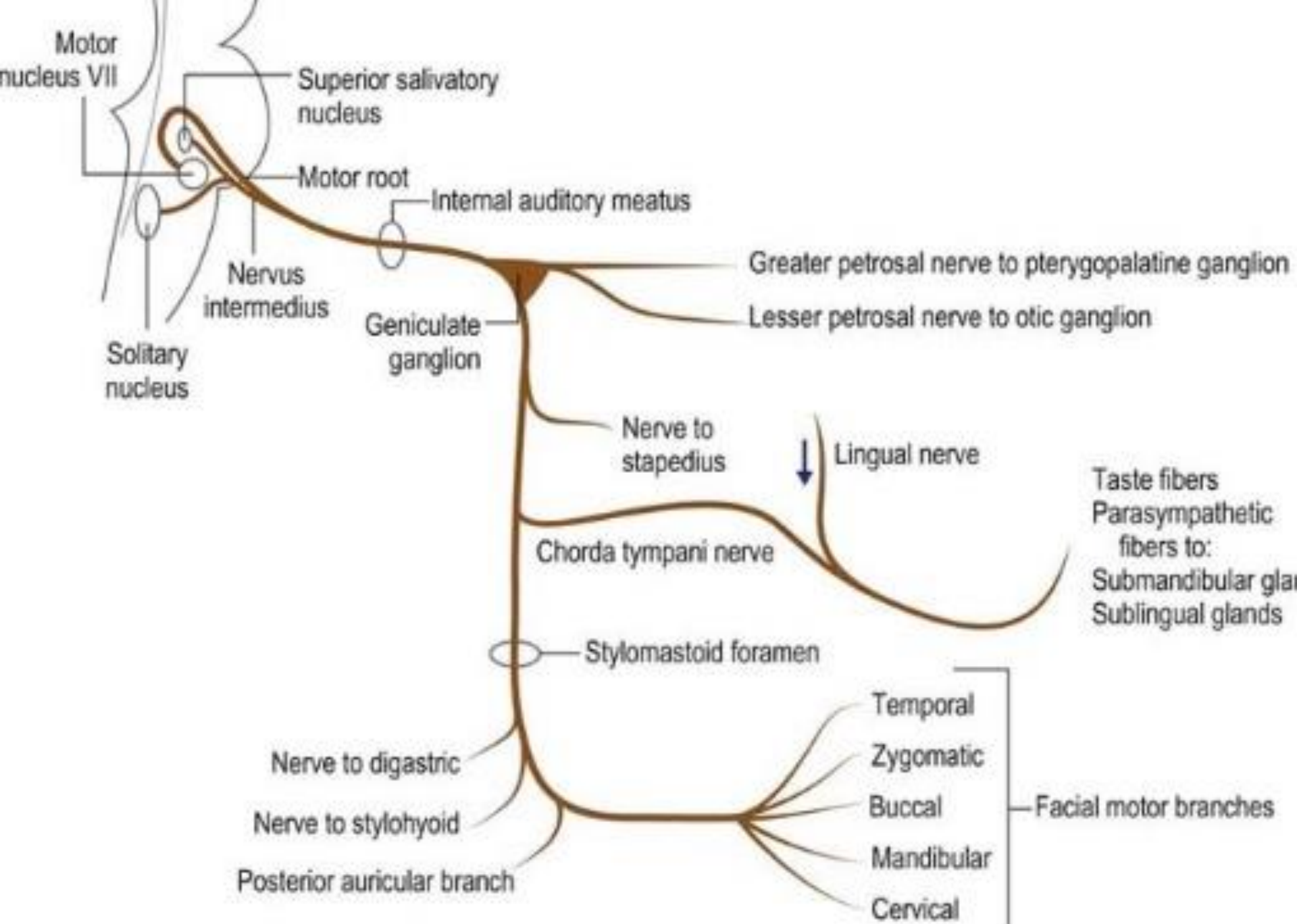
- ⑦ The nerve arises in the **pons**, an area of the brainstem.
- ⑦ It begins as two roots; a large **motor root**, and a small **sensory root** (the part of the facial nerve that arises from the sensory root is sometimes known as the **intermediate nerve**).
- ⑦ The two roots moves through the **internal acoustic meatus**, a 1cm long opening in the petrous part of the temporal bone. **Here, they are in very close proximity to the inner ear.**
- ⑦ Still within the temporal bone, the roots leave the internal acoustic meatus, and enter into the **facial canal**. The canal is a 'Z' shaped structure. Within the facial canal, three important structures occur:
- ⑦ Firstly the *two roots* **fuse** to form the facial nerve.
- ⑦ Second, the nerve forms the **geniculate ganglion** (a ganglion is a collection of nerve cell bodies).

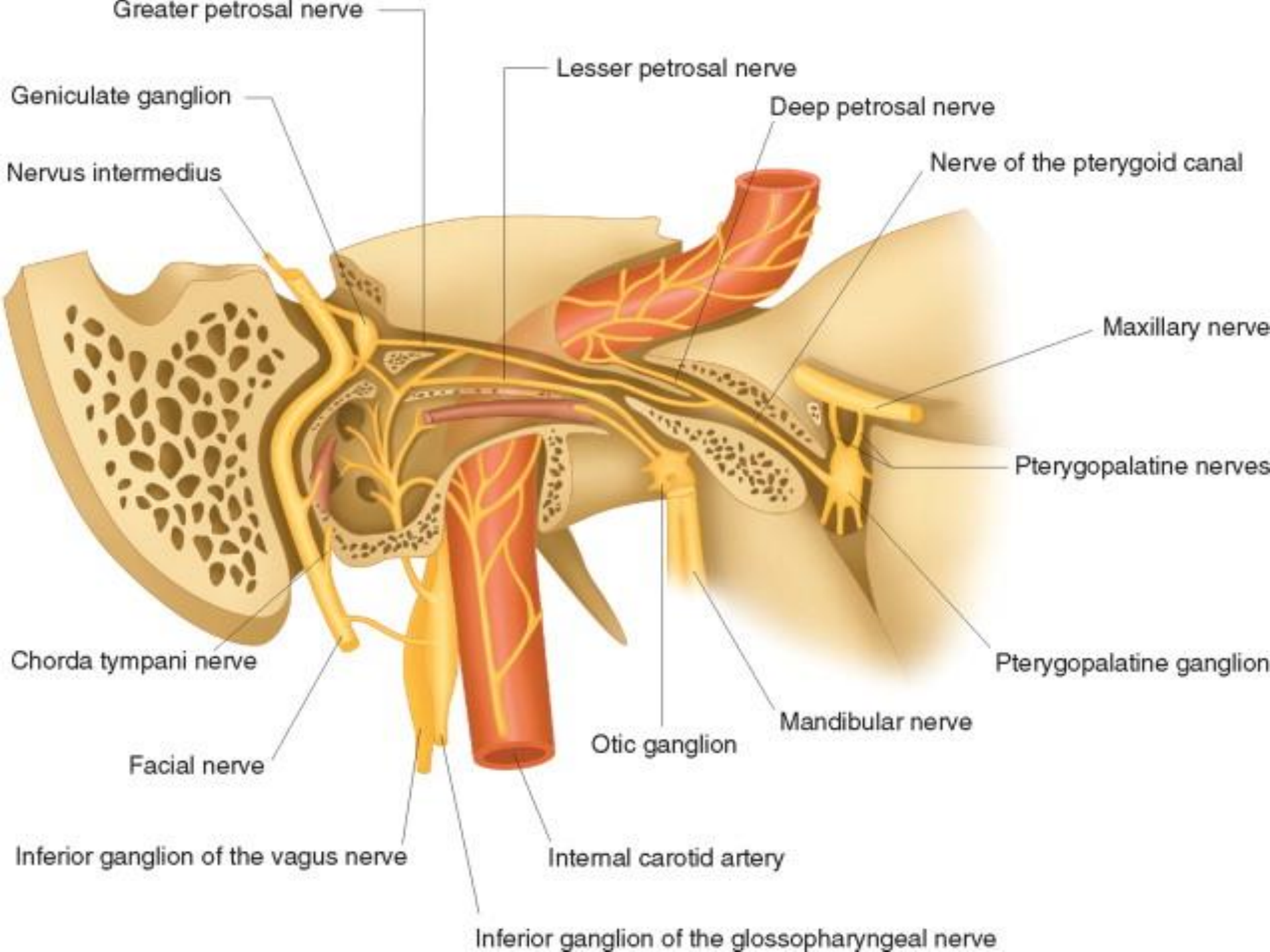


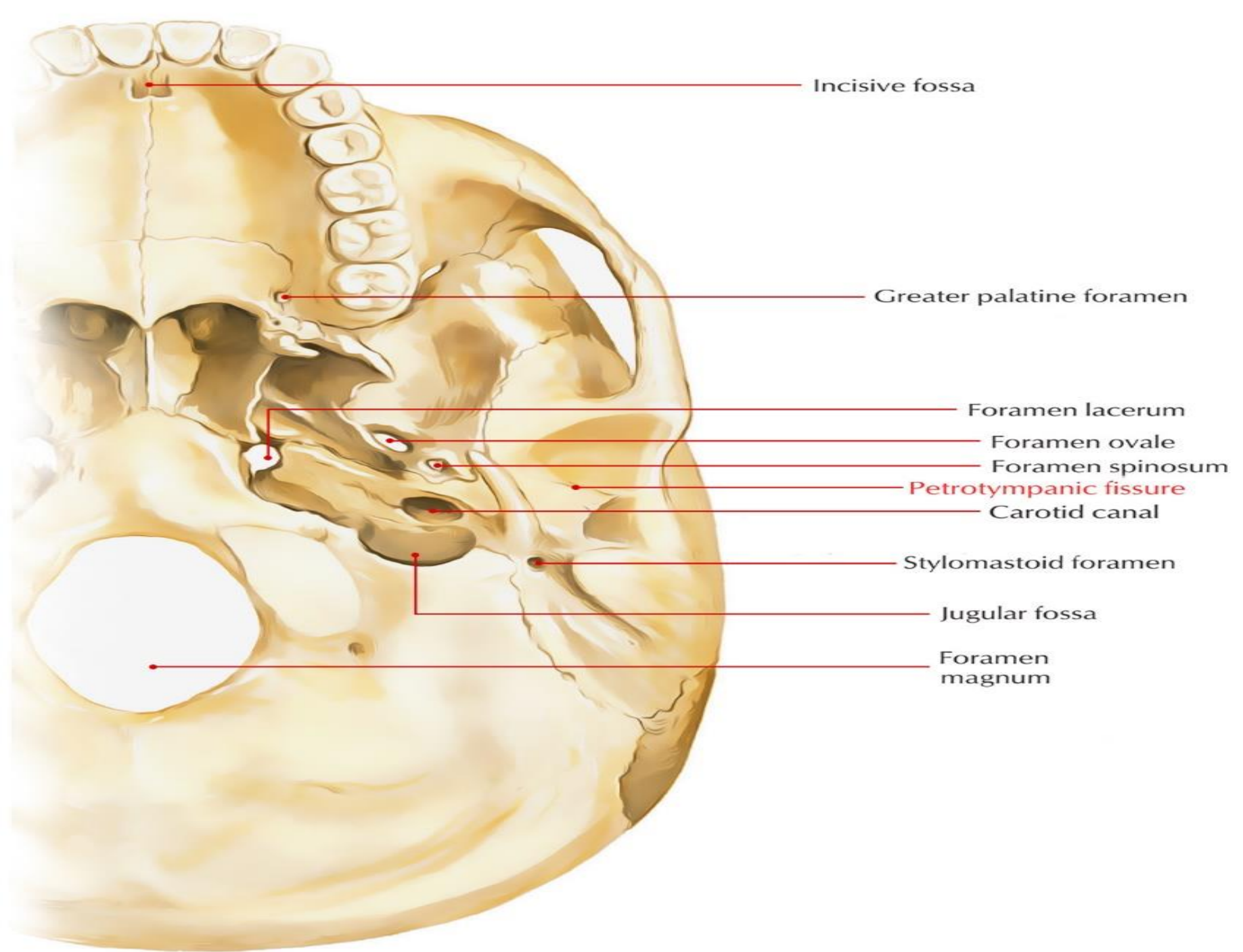




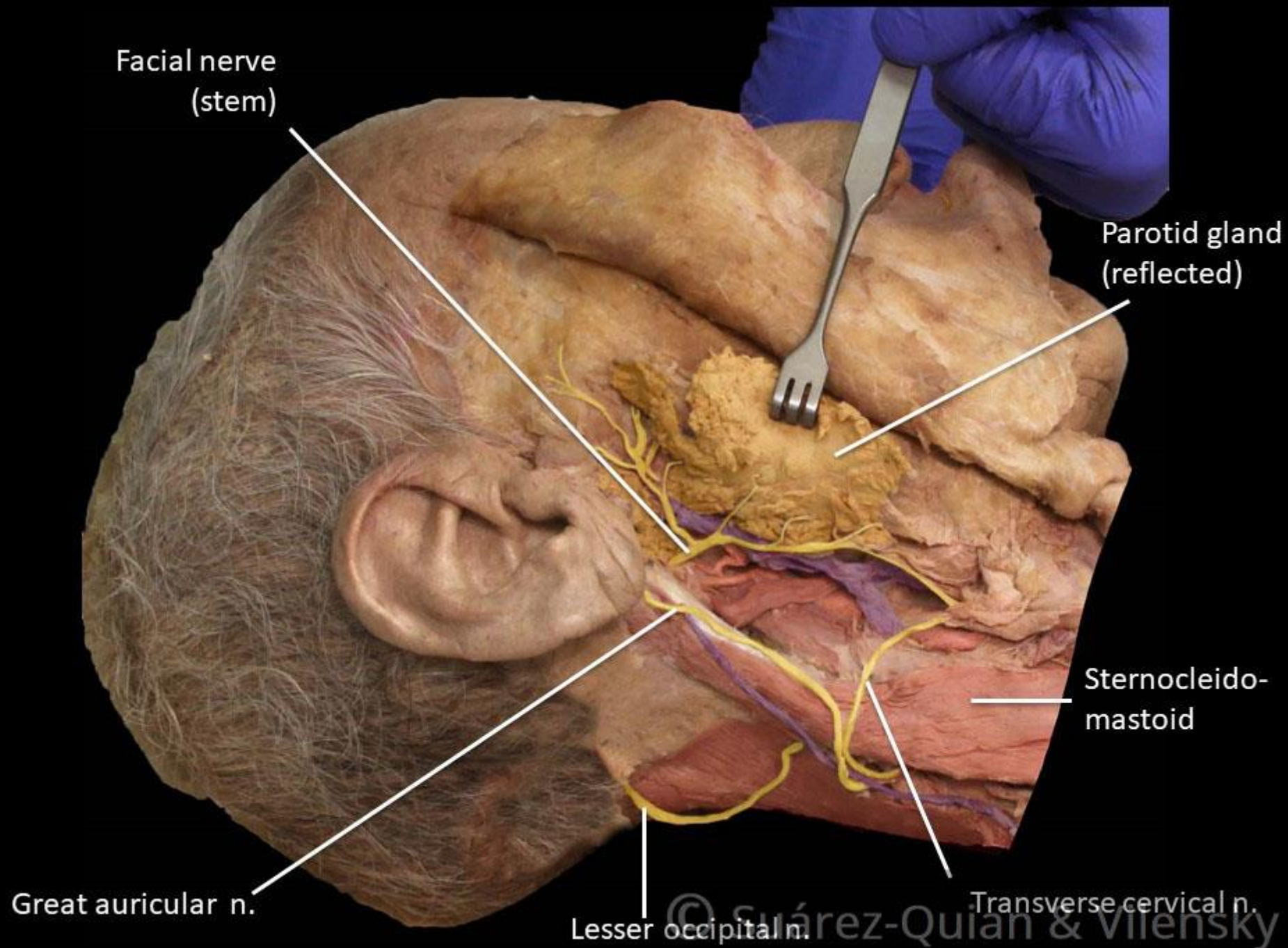
- ◉ Lastly, the nerve gives rise to:
 - > **Greater petrosal nerve** – parasympathetic fibres to mucous glands and lacrimal gland.
 - > **Nerve to stapedius** – motor fibres to stapedius muscle of the middle ear.
 - > **Chorda tympani** – special sensory fibres to the anterior 2/3 tongue and parasympathetic fibres to the submandibular and sublingual glands.
- ◉ The facial nerve then exits the facial canal (and the cranium) via the **stylomastoid foramen**. This is an exit located just posterior to the styloid process of the temporal bone.
- ◉ **Further it gives off Extracranial branches**







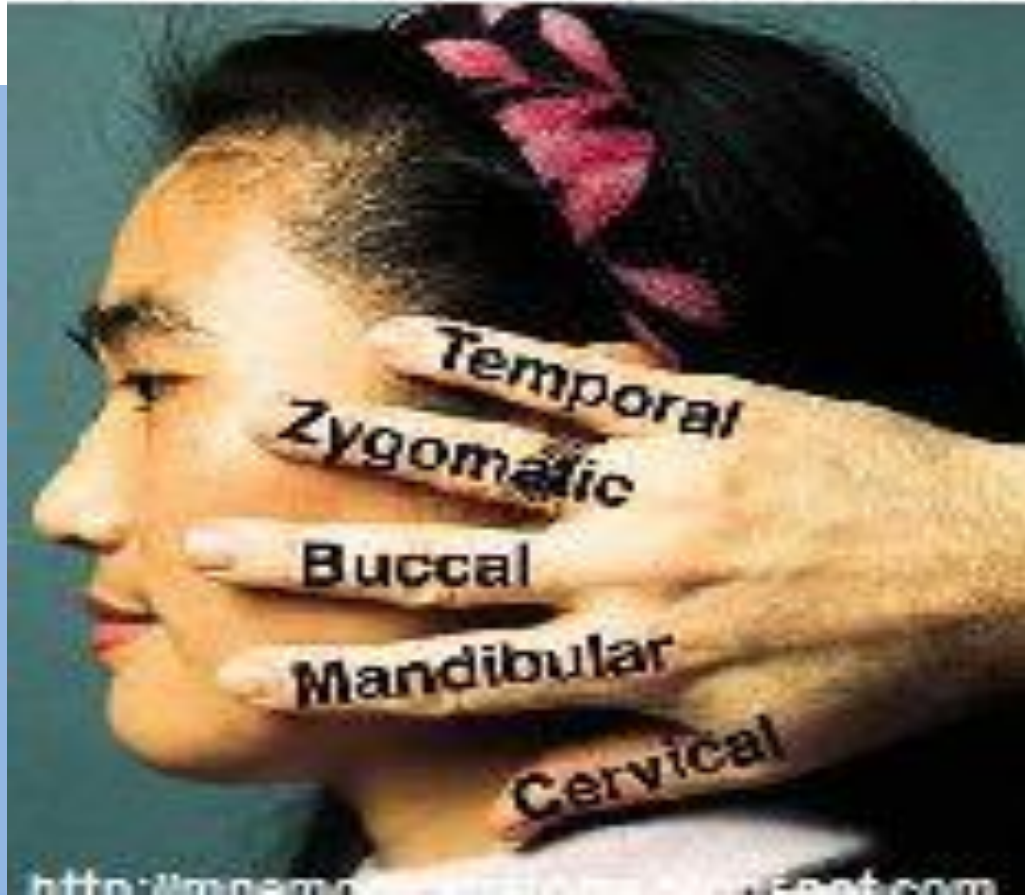- After leaving the skull, the facial nerve turns superiorly to run just anterior to the external ear.
- **The first extracranial branch** - is the **posterior auricular nerve**. It provides **motor innervation** to the some of the muscles around the ear.
Immediately distally to this, motor branches are sent to the posterior belly of the digastric muscle and to the stylohyoid muscle.
- The main trunk of the nerve, now termed the **motor root** of the facial nerve, continues anteriorly and inferiorly into the parotid gland.
- **NB!!!(note** – *the facial nerve does not contribute towards the innervation of the parotid gland, which is innervated by the glossopharyngeal nerve***).**

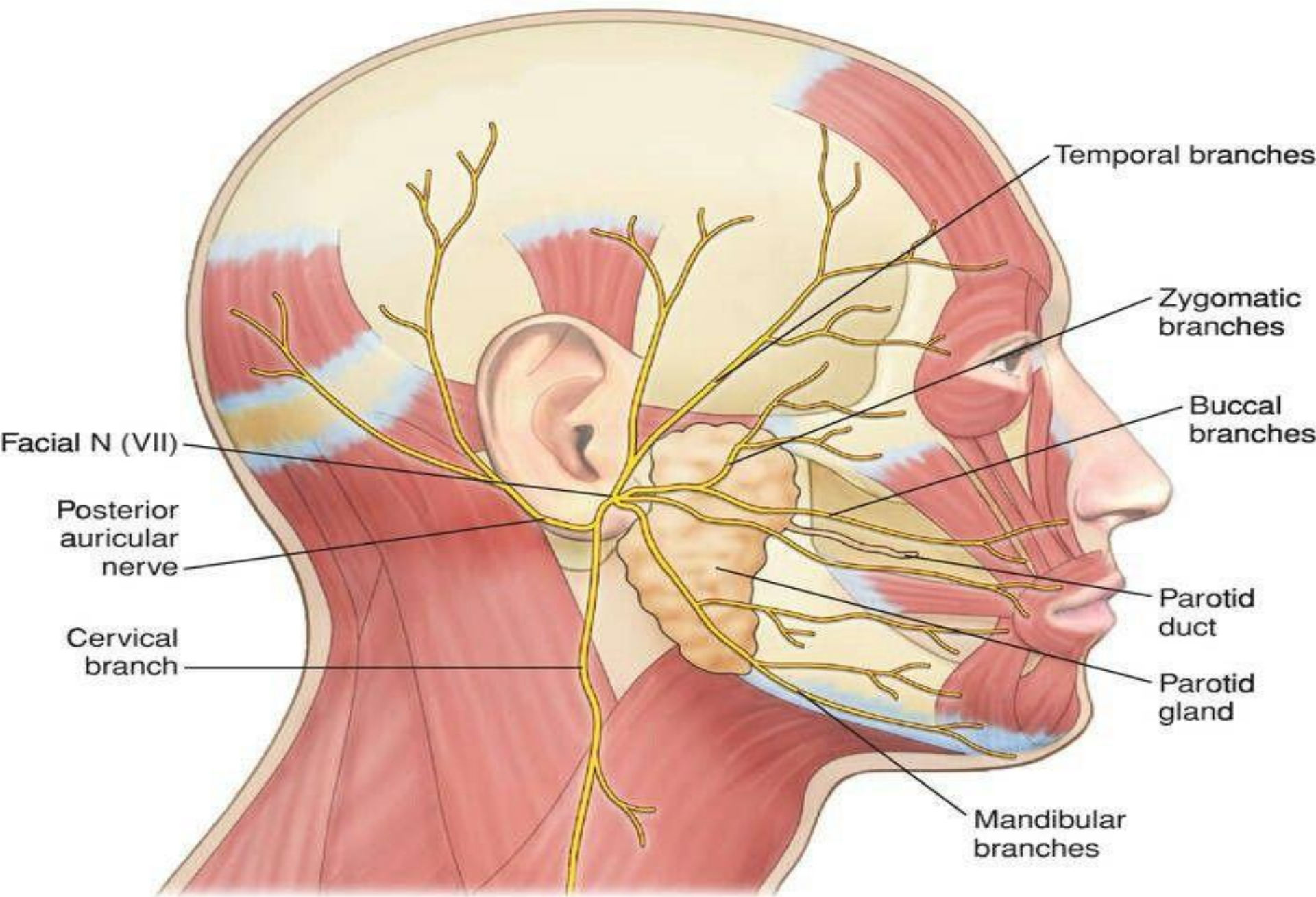


- ◉ Within the parotid gland, the facial nerve terminates by bifurcating into five motor branches. These innervate the muscles of facial expression:
- ◉ **Temporal branch** – Innervates the frontalis, orbicularis oculi and corrugator supercilii
- ◉ **Zygomatic branch** – Innervates the orbicularis oculi.
- ◉ **Buccal branch** – Innervates the orbicularis oris, buccinator and zygomaticus muscles.
- ◉ **Marginal Mandibular branch** – Innervates the mentalis muscle.
- ◉ **Cervical branch** – Innervates the platysma.

Zanzibar By Motor Car"

Branches of the Facial Nerve



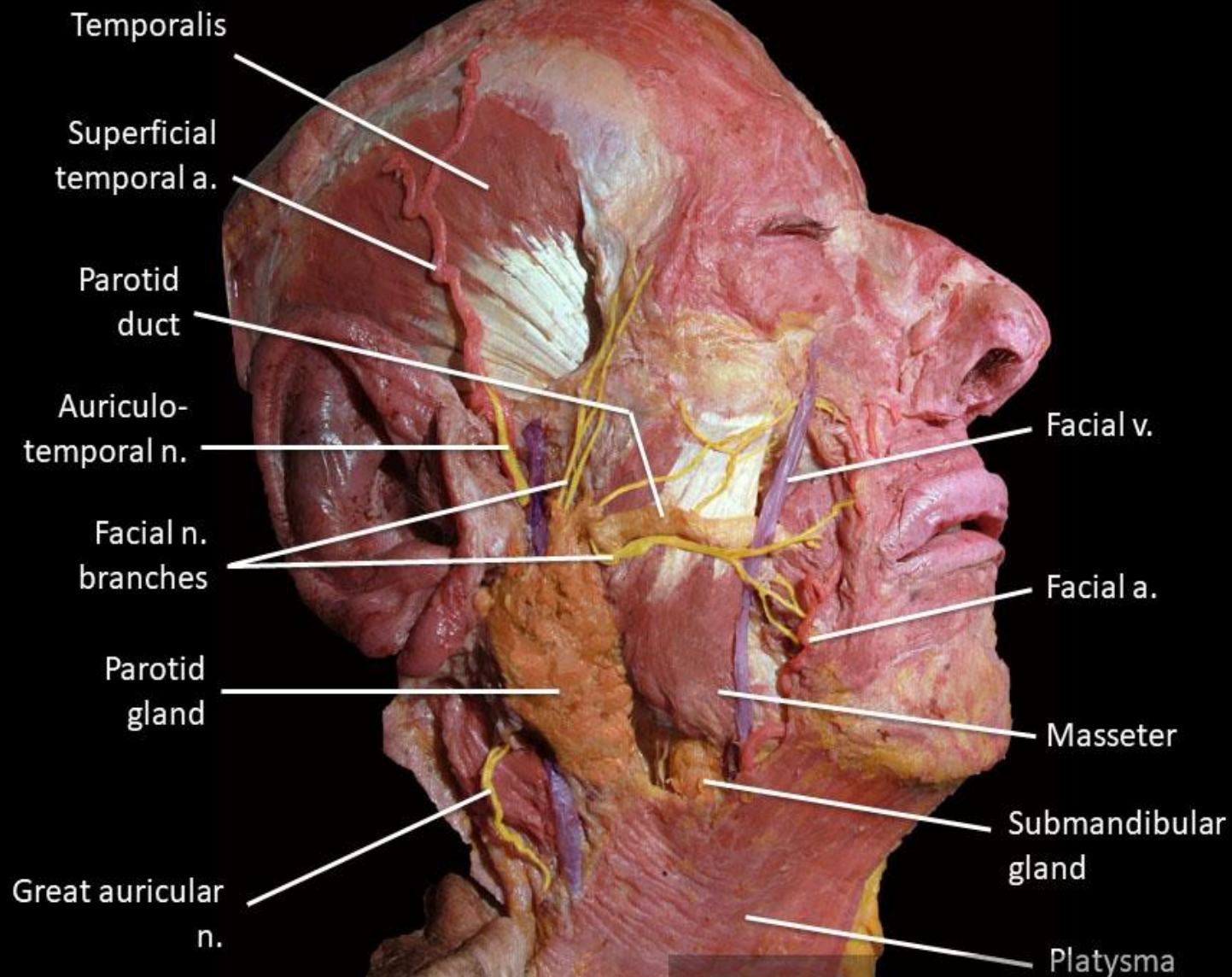


Motor Functions

- Branches of the facial nerve are responsible for innervating many of the muscles of the head and neck. All these muscles are derivatives of the **second pharyngeal arch**.
- THE FIRST MOTOR BRANCH arises within the facial canal; the **nerve to stapedius**. The nerve passes through the pyramidal eminence to supply the stapedius muscle in the middle ear.
- BETWEEN THE STYLOMASTOID FORAMEN, AND THE PAROTID GLAND, THREE MORE MOTOR BRANCHES ARE GIVEN OFF:**
- Posterior auricular nerve** – Ascends in front of the mastoid process, and innervates the intrinsic and extrinsic muscles of the outer ear. It also supplies the occipital part of the occipitofrontalis muscle.
- Nerve to the posterior belly of the digastric muscle** – Innervates the posterior belly of the digastric muscle (a suprahyoid muscle of the neck). It is responsible for raising the hyoid bone.
- Nerve to the stylohyoid muscle** – Innervates the stylohyoid muscle (a suprahyoid muscle of the neck). It is responsible for raising the hyoid bone.

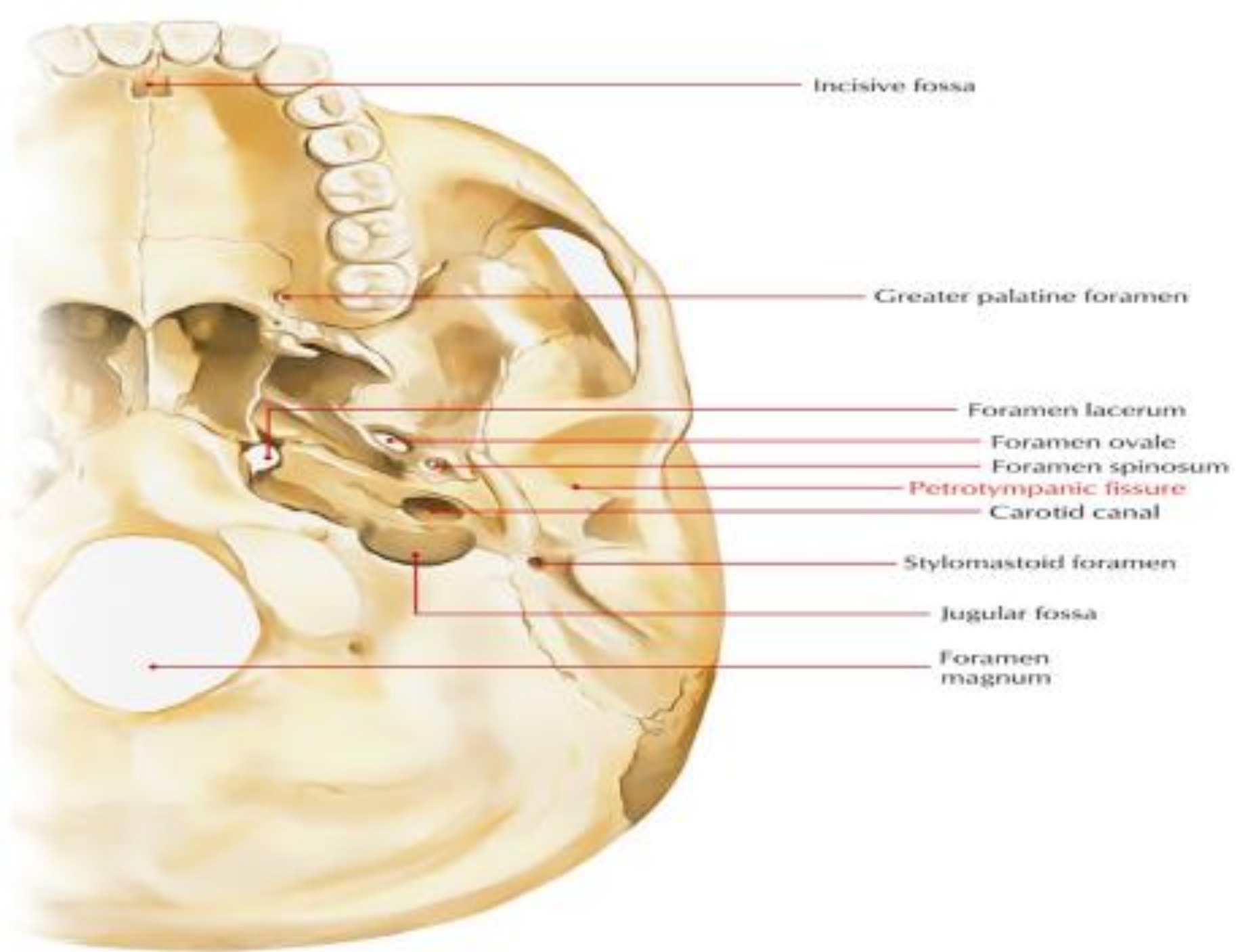
- ◎ The largest component of CN VII provides efferent motor innervation to the following muscles:
 - > Muscles of “facial expression”
 - > Stylohyoid m. (raises hyoid bone)
 - > Posterior belly of digastric m. (raises hyoid bone)
 - > Stapedius m. (dampens vibrations of the stapes on the oval window)
 - > Occipitofrontalis m. (intrinsic muscle of the scalp)
- ◎ The muscles innervated by CN VII are known as “branchial muscles” as they are derived from embryonic structures of the 2nd pharyngeal arch (hyoid arch).





◎ **Special Sensory Functions**

- ◎ The **chorda tympani** branch of the facial nerve is responsible for innervating the anterior 2/3 of the tongue with the special sense of taste.
- ◎ The nerve arises in the facial canal, and travels across the bones of the middle ear, exiting via the petrotympanic fissure, and entering the infratemporal fossa. Here, the chorda tympani communicate with the **lingual nerve (V3 CNV)**.
- ◎ The *parasympathetic fibres of the chorda tympani stay with the lingual nerve, but the main body of the nerve leaves to innervate the anterior 2/3 of the tongue.*

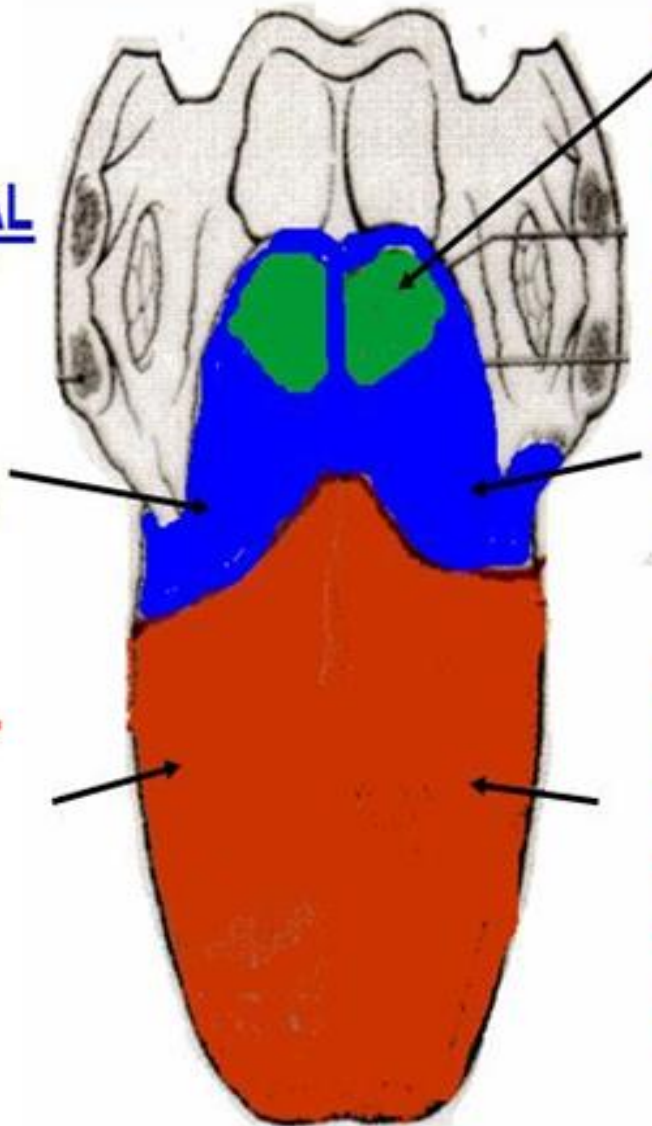


SENSORY INNERVATION OF TONGUE

NOTE: ↓

PHARYNGEAL
PART- POST
1/3 and ANT.
TO
EPIGLOTTIS

ORAL PART -
ANT 2/3



ANT. TO EPIGLOTTIS -
1) X- VAGUS
TOUCH AND TASTE

POST. 1/3 OF TONGUE
1) IX - GLOSSO-
PHARYNGEAL TOUCH
AND TASTE

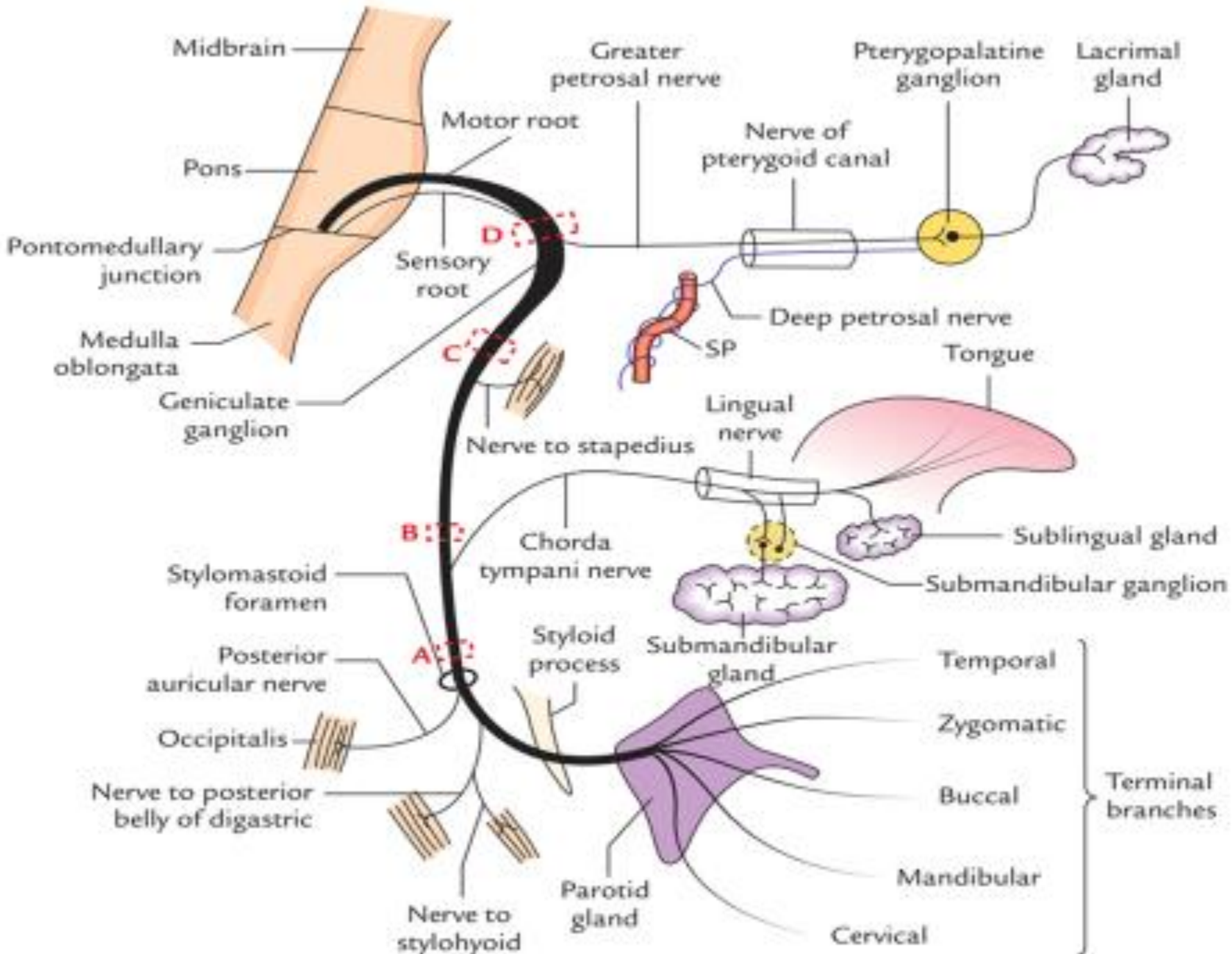
ANT. 2/3 OF TONGUE
1) V3 - LINGUAL N.
TOUCH
2) VII - CHORDA
TYMPANI -
TASTE

● **Parasympathetic Functions**

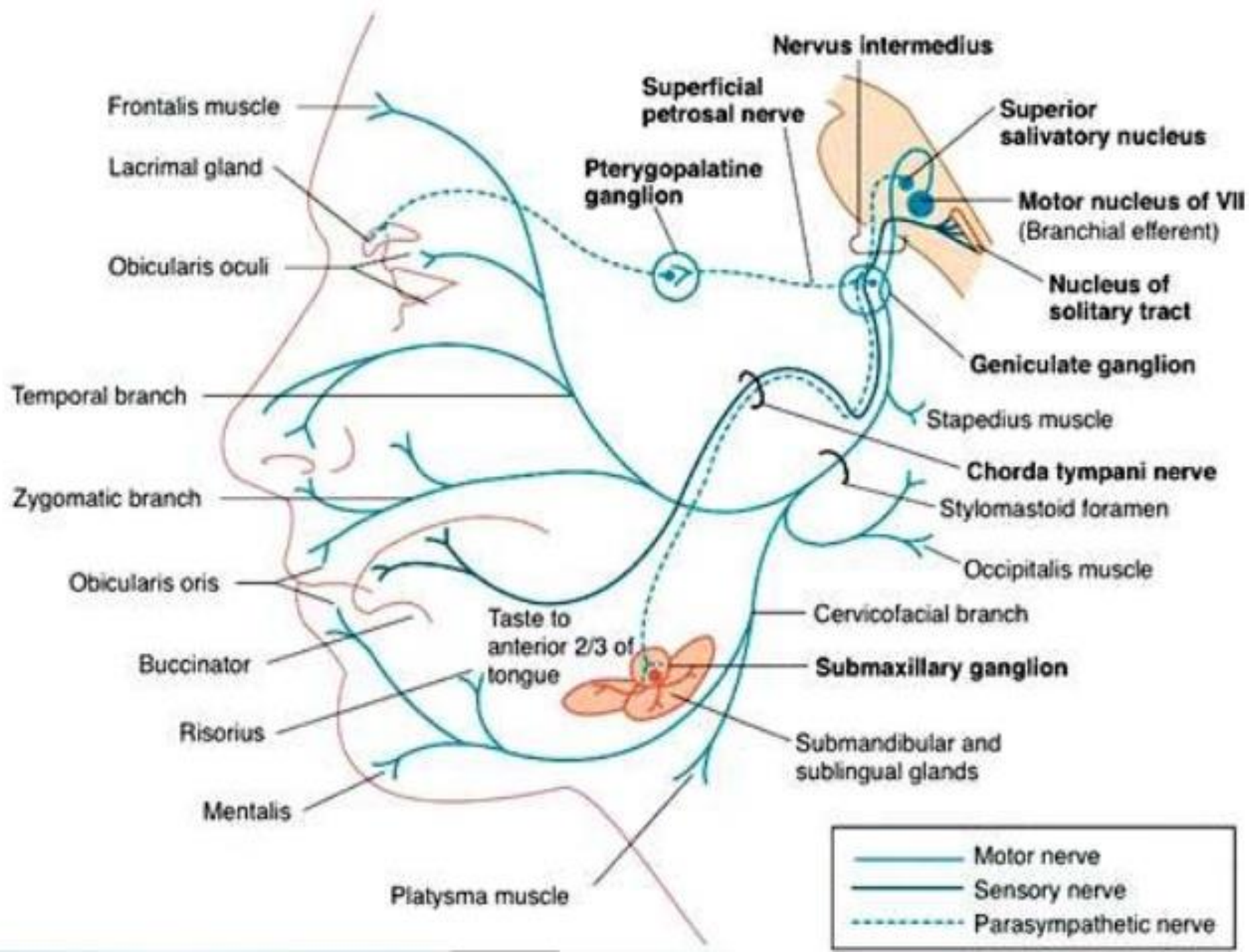
- The parasympathetic fibres of the facial nerve are carried by the **greater petrosal** and **chorda tympani** branches.

● **Greater Petrosal Nerve**

- The greater petrosal nerve arises immediately distal to the **geniculate ganglion** within the facial canal. It then moves in anteromedial direction, exiting the temporal bone into the **middle cranial fossa**. From here, it travels through the foramen lacerum, combining with the deep petrosal nerve to form the **nerve of the pterygoid canal**.
- The **nerve of pterygoid canal** then passes through the **pterygoid canal (Vidian canal)** to enter the **PTERYGOPALATINE FOSSA**, and synapses with the **pterygopalatine ganglion**. Branches from this ganglion then go on to provide parasympathetic innervation to the **mucous glands** of the **oral cavity**, **nose** and **pharynx**, and the **lacrimal gland**.



- ④ The **fibers from the superior salivary nucleus** and the **NTS** converge as they leave the cerebellopontine angle and enter the internal acoustic meatus (IAC). They then travel through the facial canal where only the taste fibers synapse in the **geniculate ganglion**. At this point, the newly arisen postsynaptic afferent taste fibers and the presynaptic parasympathetic fibers travel with the facial nerve through the facial canal.
- ④ Before the facial nerve exits the cranium via the stylomastoid foramen, it gives off the chorda tympani. The chorda tympani travels superiolaterally and **enters the middle ear**, arches across pars flaccida medial to the superior portion of the handle of malleus, and traverses above the insertion of tensor tympani. The chorda tympani exits the cranium via the **petrotympanic fissure** and enters the infratemporal fossa.



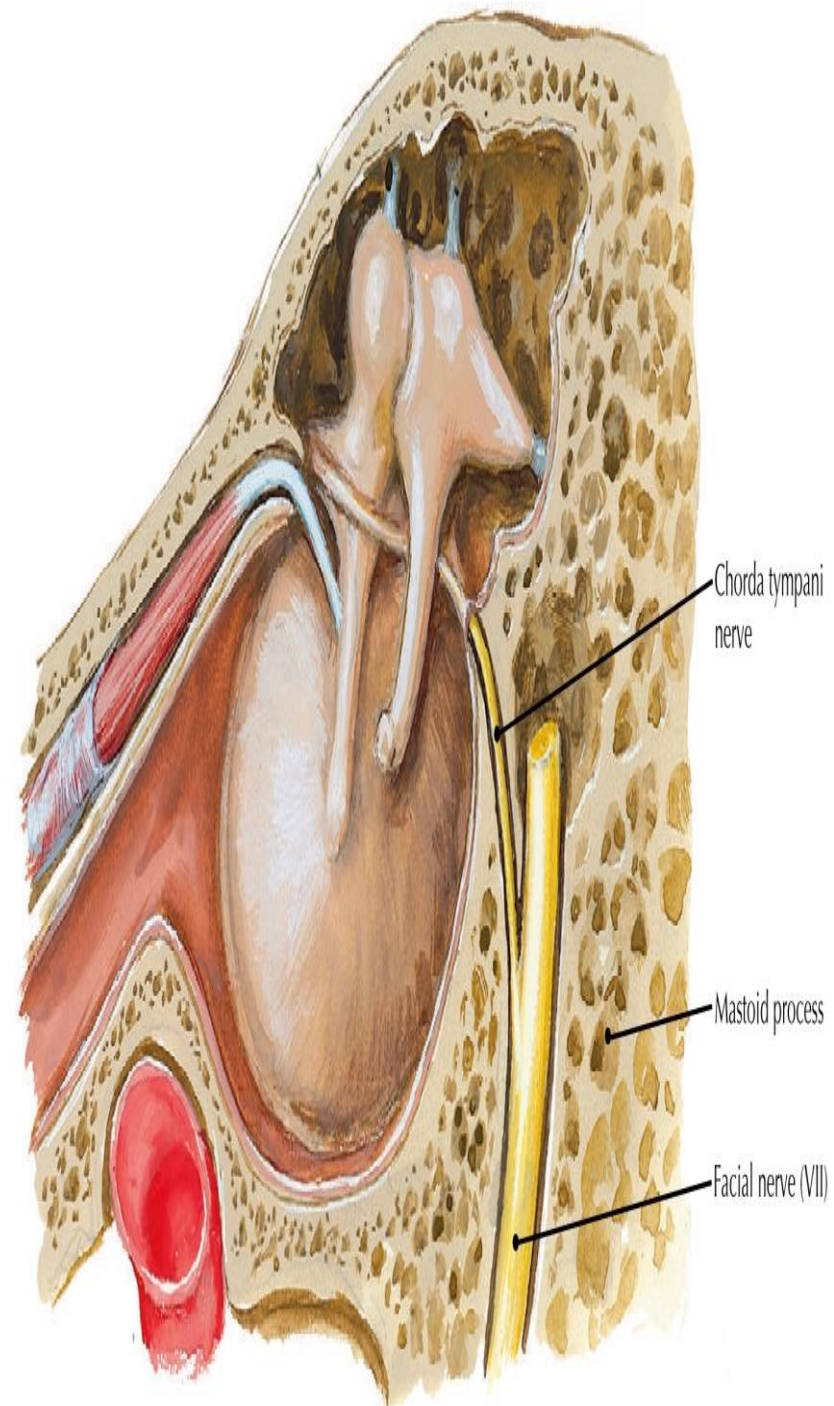
- ◎ CN VII provides preganglionic parasympathetic innervation to:
 - > Submandibular glands
 - > Sublingual glands
 - > Lacrimal glands
 - > Mucous membranes of the nose, palate, and pharynx
- ◎ It is important to note that all of the **postganglionic parasympathetic nerve fibers from CN VII** are actually carried to their ultimate targets via divisions of **CN V**.
- ◎ Parasympathetic innervation in the head and neck promotes the production of mucous, tears, and saliva and is counter regulated by sympathetic innervation.

⦿ **Anatomic Pathway of Parasympathetics:**

- ⦿ The parasympathetic fibers of CN VII originate in the **superior salivary nucleus** of the pons and leaves the cerebellopontine angle as the **nervus intermedius** (of Wrisberg).
- ⦿ The nervus intermedius enters the internal acoustic meatus .
- ⦿ The parasympathetic fibers then pass through the **geniculate ganglion** (without synapsing) and join one of two divisions of **CN VII**:
 - Greater petrosal nerve (parasympathetics only)
 - Chorda tympani (taste to anterior 2/3 tongue as well as parasympathetics)

◉ Chorda Tympani

- ◉ The **chorda tympani** also carries some parasympathetic fibres. These combine with the **lingual nerve** (a branch of the trigeminal nerve) in the **infratemporal fossa** and form the **submandibular ganglion**. Branches from this ganglion travel to the submandibular and sublingual **salivary glands**.



BELL'S palsy :

“Facial nerve paralysis”

It is the commonest type of facial palsy.

It is the major cause of the acute facial nerve paralysis.

It affects totally half side of the face due to the LMN Lesion.

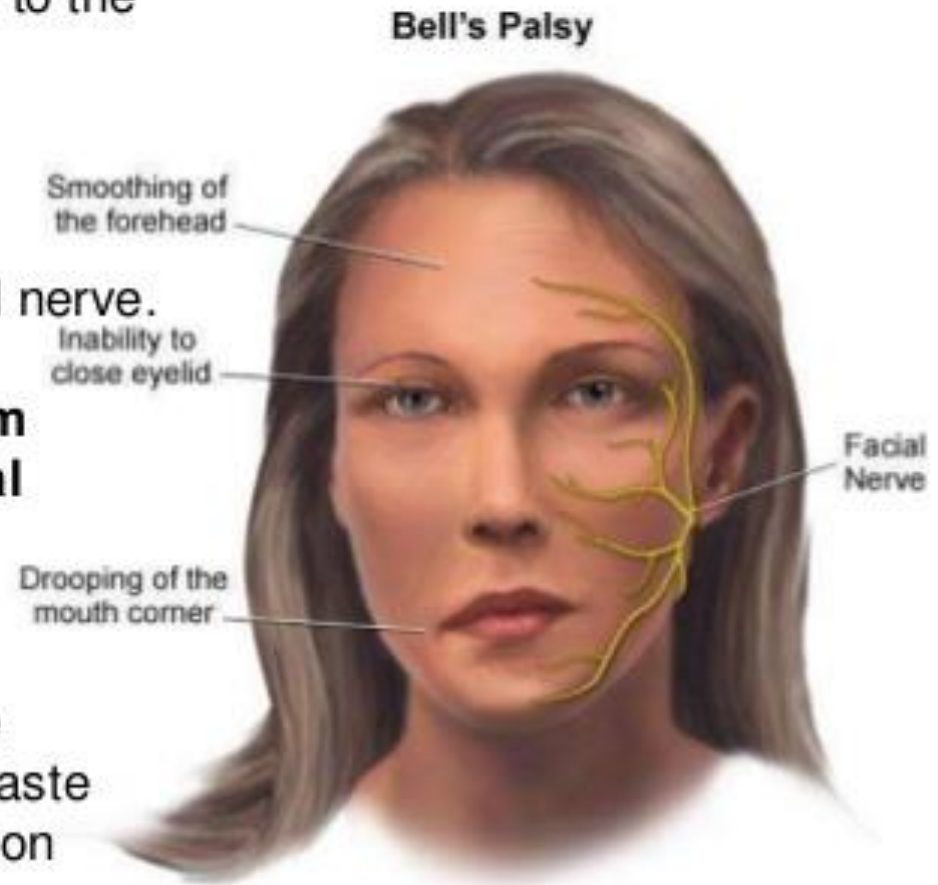
Its **idiopathic**

Its due to the **inflammation** of the facial nerve.

The inflammation prevents nerve from sending correct signals to brain & facial muscles.

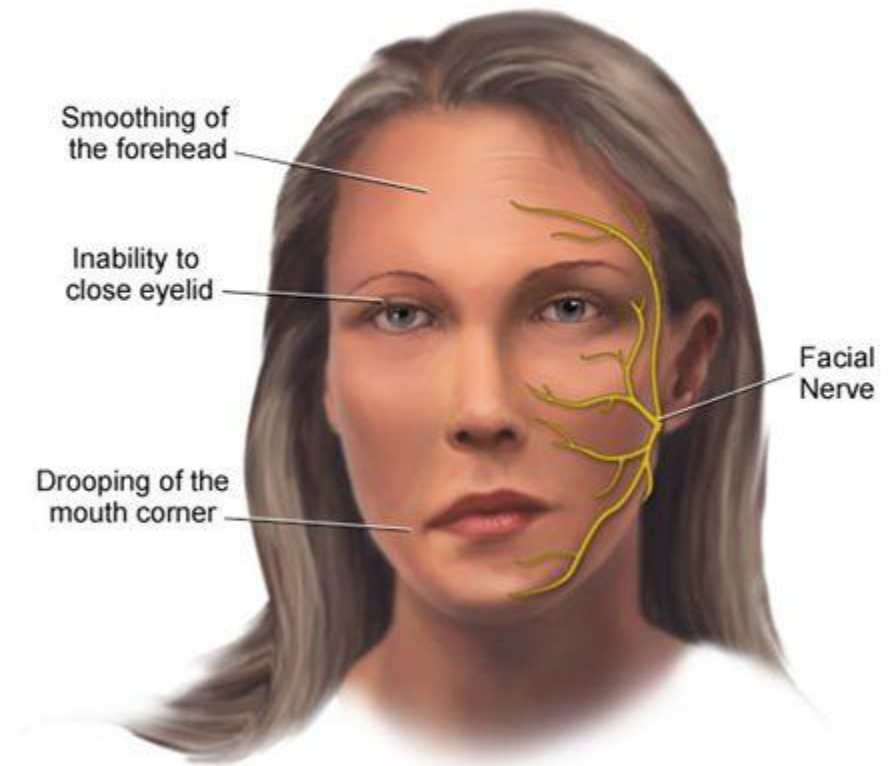
Sign & symptoms :

droopy eyelid, drooping corner of the mouth, unilateral facial weakness loss of taste decreased salivation and tear secretion



Signs of Facial Nerve Paralysis

- Facial asymmetry
- Eyebrow droop
- Inability to wrinkle forehead
- Drooping of corner of mouth
- Inability to close eye and uncontrolled tearing
- Unable to put hold lips tightly together



THANK YOU FOR ATTENTION.

