



# Wiadomości Lekarskie

Czasopismo Polskiego Towarzystwa Lekarskiego



Pamięci  
dra Władysława  
Biegańskiego

TOM LXXII, 2019, Nr 7, lipiec

Rok założenia 1928

---



# Wiadomości Lekarskie

**Editor in-Chief:**

Prof. Władysław Pierzchała

**Deputy Editor in-Chief:**

Prof. Aleksander Sieroń

**Statistical Editor:**

Dr Lesia Rudenko

**Polskie Towarzystwo Lekarskie:**

Prof. Waldemar Kostewicz – President PTL

Prof. Jerzy Woy-Wojciechowski – Honorary President PTL

Prof. Tadeusz Petelenz

---

**International Editorial Board – in-Chief:**

Marek Rudnicki

Chicago, USA

**International Editorial Board – Members:**

Kris Bankiewicz	San Francisco, USA	George Krol	New York, USA
Christopher Bara	Hannover, Germany	Krzysztof Łabuzek	Katowice, Poland
Krzysztof Bielecki	Warsaw, Poland	Henryk Majchrzak	Katowice, Poland
Zana Bumbuliene	Vilnius, Lithuania	Ewa Małecka-Tendera	Katowice, Poland
Ryszarda Chazan	Warsaw, Poland	Stella Nowicki	Memphis, USA
Stanislav Czudek	Ostrava, Czech Republic	Alfred Patyk	Gottingen, Germany
Jacek Dubiel	Cracow, Poland	Palmira Petrova	Yakutsk, Russia
Zbigniew Gasior	Katowice, Poland	Krystyna Pierzchała	Katowice, Poland
Andrzej Gładysz	Wroclaw, Poland	Tadeusz Płusa	Warsaw, Poland
Nataliya Gutorova	Kharkiv, Ukraine	Waldemar Priebe	Houston, USA
Marek Hartleb	Katowice, Poland	Maria Siemionow	Chicago, USA
Roman Jaeschke	Hamilton, Canada	Vladyslav Smiiianov	Sumy, Ukraine
Andrzej Jakubowiak	Chicago, USA	Tomasz Szczepański	Katowice, Poland
Oleksandr Katrushov	Poltava, Ukraine	Andrzej Witek	Katowice, Poland
Peter Konturek	Saalfeld, Germany	Zbigniew Wszolek	Jacksonville, USA
Jerzy Korewicki	Warsaw, Poland	Vyacheslav Zhdan	Poltava, Ukraine
Jan Kotarski	Lublin, Poland	Jan Zejda	Katowice, Poland

---

**Managing Editor:**

Agnieszka Rosa

amarosa@wp.pl

**Graphic design / production:**

Grzegorz Sztank

www.red-studio.eu

**International Editor:**

Lesia Rudenko

l.rudenko@wydawnictwo-aluna.pl

**Publisher:**

ALUNA Publishing

ul. Przesmyckiego 29, 05-510 Konstancin – Jeziorna

www.aluna.waw.pl www.wiadomoscilekarskie.pl

www.medlist.org

**Distribution and Subscriptions:**

Bartosz Guterman prenumerata@wydawnictwo-aluna.pl

## CONTENS / SPIS TREŚCI

### EDITORIAL ARTICLE / ARTYKUŁ REDAKCYJNY

- Ewa Kucharska, Aleksandra Kucharska, Aleksander Sieroń, Mariusz Nowakowski, Karolina Sieroń  
MODERN METHODS OF TREATMENT IN PALLIATIVE CARE 1229

### ORIGINAL ARTICLES / PRACE ORYGINALNE

- Svitlana V. Vozianova, Olena O. Dyadyk, Inna I. Horda, Yaroslav S. Radkevich  
MORPHOLOGICAL AND IMMUNOHISTOCHEMICAL FEATURES OF TISSUE HOMEOSTASIS IN PATIENTS WITH ALOPECIA AREATA  
IN THE CHRONIC STAGE ASSOCIATED WITH METABOLIC SYNDROME AND THE NON-BURDENED COURSE OF THE DISEASE 1236
- Dariusz Jagielski, Dorota Zysko, Klaudiusz Nadolny, Joanna Wizowska, Bartosz Biel, Waldemar Banasiak, Piotr Ponikowski  
PREDICTORS OF INAPPROPRIATE SHOCKS FROM IMPLANTABLE CARDIOVERTER-DEFIBRILLATORS 1243
- Oleg Y. Kanikovskiy, Yaroslav V. Karyi, Yura V. Babiichuk, Yevhen V. Shaprynskiy  
COMPARATIVE ASSESSMENT OF BILE DUCT DECOMPRESSION METHODS IN PATIENTS WITH OBSTRUCTIVE JAUNDICE OF NON-TUMOR GENESIS 1247
- Iliia G. Fomenko, Viktoriia Yu. Harbuzova, Olha A. Obukhova, Vladislav V. Pohmura, Inna A. Plakhtienko, Svitlana N. Piven  
THE ASSOCIATION OF APA1-POLYMORPHISM OF VITAMIN D RECEPTOR GENE (VDR) WITH DEVELOPMENT OF GENERALIZED PARODONTITIS IN UKRAINIAN POPULATION 1253
- Iryna I. Sokolova, Svitlana I. German, Tetiana V. Tomilina, Yuliia O. Slynko, Anatoliy M. Potapchuk, Karyna V. Skydan, Nataliia M. Udovychenko  
POSSIBILITIES OF MODERN X-RAY EXAMINATION METHODS FOR DIAGNOSTICS OF HIDDEN DENTAL CARIES OF APPROXIMAL LOCALIZATION 1258
- Valeriy A. Kapustnik, Olga V. Istomina  
THE RELATIONSHIP OF VIP LEVEL WITH CARDIOPULMONARY PARAMETERS IN PATIENTS WITH CHRONIC OBSTRUCTIVE PULMONARY DISEASE IN COMBINATION WITH HYPERTENSION 1265
- Ivan I. Topchii, Alexander N. Kirienko, Denis A. Kirienko, Iryna I. Yakovtsova, Alla A. Gavriluk, Svitlana V. Danyliuk, Igor V. Ivakhno, Vira D. Tovazhnianska  
FEATURES OF ENDOTHELIUM MORPHOLOGICAL STRUCTURE IN KIDNEY VESSELS, CORONARY ARTERIES AND AORTA DURING CHRONIC KIDNEY DISEASE 1269
- Serhii O. Soloviov, Hennadiy A. Mokhort, Olena P. Trokhimenko, Hleb V. Zahoriy, Viktor V. Trokhymchuk, Iryna P. Kolesnikova, Iryna V. Dziublyk  
PHARMACOECONOMIC AND EPIDEMIOLOGICAL BASES OF OPTIMAL ROTAVIRUS VACCINE SUPPLY FOR UKRAINIAN POPULATION 1274
- Veronika Dudnyk, Olha Zborovska, Yuliia Vyzhga, Kateryna Khromykh, Ganna Zvenigorodska, Vladymyr Popov, Valentyn Bakhnivskiy  
INSTRUMENTAL ASSESSMENT OF MYOCARDIAL FUNCTION BY DOPPLER TISSUE IMAGING IN CHILDREN WITH CONGENITAL HEART DEFECTS AFTER SURGICAL CORRECTION  
AND ITS CORRELATION WITH GALECTIN-3 AMOUNT AS BIOLOGICAL MARKER OF CARDIAC FIBROSIS 1281
- Jolanta Piskorz, Gustaw Wójcik, Włodzimierz Bulikowski, Dorota Kozak-Putowska  
ASSESSMENT OF CHANGES OF SKIN MOISTURE IN PATIENTS SUBJECT TO GENERAL ANESTHESIA WITH NEUROLOGICAL DISEASES IN AN INTERVIEW 1288
- Oleg A. Bychkov, Vitalii E. Kondratiuk, Nina G. Bychkova, Zemfira V. Morozova, Svetlana A. Bychkova, Alina P. Tarasiuk  
ROLE OF IMMUNE SYSTEM IN DEVELOPMENT AND PROGRESS OF COMBINED ARTERIAL HYPERTENSION AND GOUT 1295
- Svetlana Chuhray, Viktoriia Lavrynenko, Rostyslav Kaminsky, Olena Ustyimenko, Iryna Dzevulska, Ruzhena Matkivska, Oleksandr Kovalchuk, Olena Holubchenko, Liudmyla Sokurenko  
THE INFLUENCE OF DRUG TREATMENT ON CARDIO-VASCULAR SYSTEM OF THE RATS WITH CONGENITAL HYPOTHYROIDISM 1300
- Uljana Fedorova, Orysya Syzon, Igor Gajduchok, Kostyantyn Ischejkin, Marianna Dashko  
CLINICAL AND METABOLIC ANALYSIS OF DISORDERS IN PSORIATIC PATIENTS 1304
- Iryna V. Balaniuk, Elena V. Myronyk, Yuriy O. Randiuk, Andriy V. Andruschak  
GENERAL IMMUNOLOGICAL REACTIVITY OF PATIENT'S ORGANISM WITH CHRONIC HEPATITIS C 1310
- Viktor V. Kovalenko, Iryna M. Tkachenko, Zoryana Y. Nazarenko, Natalia M. Braillko, Julia G. Romanova, Olga V. Sheshukova, Yaroslav V. Vodorig  
THE STUDY OF ORAL FLUID DYNAMIC PARAMETERS ON THE BACKGROUND OF PATHOLOGICAL AND PHYSIOLOGICAL DENTAL ABRASION 1315
- Oleksandr I. Smiyan, Kateryna O. Smiian-Horbunova, Tetiana P. Bynda, Andriy M. Loboda, Sergij V. Popov, Ihor Yu. Vysotsky, Oleksandr P. Moshchych, Olena G. Vasylieva,  
Yuliia A. Manko, Olena L. Ovsianko, Mariia V. Kolesnikova, Natalia O. Dolgova, Tatiana O. Aleksakhina, Bara' Al-Rawashdeh  
OPTIMIZATION OF THE TREATMENT OF ROTAVIRUS INFECTION IN CHILDREN BY USING *BACILLUS CLAUSII* 1320

PRACA ORYGINALNA  
ORIGINAL ARTICLE

## POSSIBILITIES OF MODERN X-RAY EXAMINATION METHODS FOR DIAGNOSTICS OF HIDDEN DENTAL CARIES OF APPROXIMAL LOCALIZATION

Iryna I. Sokolova<sup>1</sup>, Svitlana I. German<sup>1</sup>, Tetiana V. Tomilina<sup>1</sup>, Yuliia O. Slynko<sup>1</sup>, Anatoliy M. Potapchuk<sup>2</sup>, Karyna V. Skydan<sup>1</sup>, Nataliia M. Udovychenko<sup>1</sup>

<sup>1</sup> KHARKIV NATIONAL MEDICAL UNIVERSITY, KHARKIV, UKRAINE

<sup>2</sup> UZHGOROD NATIONAL UNIVERSITY, UZHGOROD, UKRAINE

### ABSTRACT

**Introduction:** In case of hidden carious cavities development on the approximal teeth surfaces, the clinical diagnostics of this process is difficult. Then, the diagnostics of carious lesion is not possible without carrying out X-ray examination.

**The aim** of the study was a comparative analysis of the effectiveness of clinical and X-ray diagnostics for hidden caries of approximal teeth surfaces.

**Materials and methods:** Condition of 2 963 teeth of 115 people aged from 19 to 55 was analysed. Additionally, a digital panoramic 2D diagnostics (Planmeca ProSensor, Finland) and Cone Beam Computed Tomography 3D Diagnostics (Morita, Japan) were used for clinical examination of patients.

**Results:** In both variants of diagnostics, the number of caries defects in the upper jaw was higher than in the lower one, and the frequency of caries lesion of various teeth groups had the following sequence in descending order: molar teeth, premolar teeth, incisor teeth and canine teeth. Hidden carious cavities of average depth and deep were detected with almost the same frequency in both variants of the study, which by 1.9 - 2.0 times respectively exceeded the frequency of superficial carious cavities detection ( $p = 0.0001$ ). According to the results of clinical studies, hidden superficial carious cavities occurred in single cases and X-ray examination improved their diagnostics by 9.6 times ( $p = 0.0000$ ).

**Conclusions:** X-ray examination allows increasing the effectiveness of diagnostics of hidden carious cavities of approximal localization by 1.2 times on the whole ( $p < 0,05$ ). In such cases orthopantomography (OPG) has reasonably sufficient diagnostic capabilities. Definitely, 3D Cone Beam Computed Tomography (CBCT) has much more diagnostic capabilities, but its use can not be justified for the diagnostics of caries only.

**KEY WORDS:** dental caries, hidden cavities, approximal localization, OPG, CBCT

Wiad Lek 2019, 72, 7, 1258-1264

### INTRODUCTION

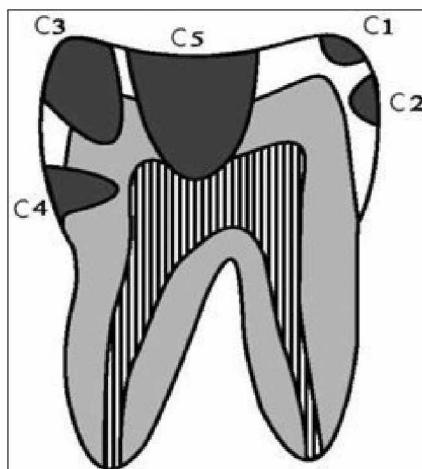
Nowadays dental caries remains the most widespread dental disease in the world, and dentists devote most of their time to its treatment. In many cases, cariosity diagnostics does not cause difficulties – caries lesion is easily recognized clinically, and, as a rule, there is no need for X-ray examination. But with caries localization on approximal surfaces, especially with teeth overcrowding, root cement caries in the subgingival area, in deep figures with a narrow inlet, in cases of suspicion of secondary caries under dental fillings or crowns, X-ray examination is crucial for diagnostics and generation of treatment planning [1, 2].

Previously, X-ray method of examination was considered additional in dentistry, in particular, in treatment of uncomplicated caries it was almost not used. But over time, due to visualization technologies progress, X-ray method of examination gradually gained a proper place among the basic diagnostic methods [3, 4, 5]. Firstly, the final diagnosis is made in view of X-ray data in the great

majority of cases; secondly, no dental intervention can be considered relevant without detailed X-ray monitoring; thirdly, follow-up visits and dispensary observation of the patient should be based on regular X-ray control [5, 6, 7, 8, 9, 10].

The most up-to-date method for unbiased findings acquisition until 2007 was orthopantomography (OPG). This type of X-ray examination is widely used in dentistry today as well, but with the advent of 3D technology in radiology (Cone Beam Computed Tomography, CBCT) OPG is predominantly prescribed for the primary diagnostics [11, 12, 13].

It is known that a certain projection distortion of the object by magnitude or configuration occurs in the process of carrying out two-dimensional X-ray examination, which includes OPG [5]. It is believed that only CBCT carrying out offers the opportunity to accurately measure the distance in a straight line or a curve from one point to another, to determine the measure of the angle between the lines or areas. The object is scanned without projection



**Fig. 1.** X-ray classification of carious defect depth according to J. Espelid, B. Tveit (1986): C<sub>1</sub> – dental cavity located only within half the width of enamel; C<sub>2</sub> – caries that damages more than half the thickness of enamel but does not reach amelodentinal junction; C<sub>3</sub> – caries of enamel and dentine, in which defect takes at least half the layer of hard tooth tissues to the tooth cavity; C<sub>4</sub> – defect that takes more than half the thickness of dentine but is not connected to the tooth cavity; C<sub>5</sub> – carious defect that can reach tooth cavity.

distortion and without loss of data, practically «one to one» [2, 6, 14, 15].

Spin-Neto and co-writers (2013) [16] were interested in the problem of artifacts when the patient moved, which lead to images blurring and, consequently, to their unsuitability for diagnostic purposes. The movements of patients include breathing, heartbeats, muscle contraction and tremor. When this happens, the image becomes blurred, which is manifested in striped or annular artifacts as well as double contours. The movement of the patient leads to geometrical errors in the reconstruction process, which in turn causes poor image quality in the final format.

The authors also emphasized that the effective radiation dose for intraoral images varies from 1 to 8 microsieverts ( $\mu\text{Sv}$ ), while the effective dose when using CBCT will be higher.

Young and co-writers (2009) [17] carried out similar studies in vitro, also using 3D Accuitomo<sup>®</sup> (Morita, Japan) and compared it with solid-state sensor from Gendex<sup>®</sup> (US) in relation to caries detection. Researchers found interproximal lesions in dentine particularly with the help of CBCT images. As for interproximal enamel lesions, both CBCT and solid-state sensor showed the worst diagnostic results. But CBCT, according to the authors, more often leads to false-positive conclusions in case of caries on occlusal surfaces of teeth. It was also noted that the probability of false-positive results increased since the dentine zones display was occasionally less radiopaque. It is obvious that this false radiolucency can be caused by the geometry of irradiation, since the attenuation degree of X-rays in the dentine under the enamel tubercles is less than in the dentine of any other part of coronal part of teeth.

This effect could be avoided if it were not for separate teeth examination. An effective radiation dose of 20  $\mu\text{Sv}$ , which patients undergo when passing 40x40 mm CBCT scanning with Accuitomo<sup>®</sup> (Morita, Japan) is significantly different in comparison with four X-ray images of dental occlusion with a rectangular collimator (5  $\mu\text{Sv}$ ).

Computer tomographic scanners are not the same, there are many modifications and not each type of a device can be effectively, and most importantly - justifiably and safely used in dentistry. Thus, in a study of a skull the patient receives 1000-1500  $\mu\text{Sv}$  (microsieverts) on a sequential conventional tomographic scanner, at least 400  $\mu\text{Sv}$  – on a spiral one and only 45-60  $\mu\text{Sv}$  with CBCT. We consider this advantage to be extremely important, as during X-ray studies a patient should not receive radiation exposure exceeding 1 Sv per year [7, 18].

Despite high quality of the image, the use of CBCT in dentistry has some disadvantages. Metal fillings, dental prostheses, that are often in mouths of patients, cause scattered artifacts that interfere with anatomical structures identification. However, they are leveled off in the process of information processing with the artifact elimination program [3].

Tissue section on a fifth-generation dental computer tomographic scanner Vereviewepocs 3D R100 (Morita, Japan), that is used to carry out CBCT of maxillofacial area at one of the clinical bases of the Department of Dentistry of Kharkiv National Medical University, is 0.125 mm for the study of a small segment (4x4 cm) and 0.160 mm for jaws in general, which allows to diagnose minor defects.

Thus, the data accumulation regarding comparison of possible diagnostic consideration of various modern methods of X-ray diagnostics of cariosity, especially hidden caries, remains relevant today.

## THE AIM

The aim of the study was carrying out a comparative analysis of clinical and X-ray diagnostics with hidden dental caries of approximal surfaces.

## MATERIALS AND METHODS

115 people (68 females and 47 males at the age from 19 to 55) were involved in the study. Dental health of 2963 teeth was analyzed. The diagnostics of caries of hard tooth tissues was based on the clinical classification according to lesion depth (caries in the stain stage, superficial, medium and deep caries) and on X-Ray classification according to J. Espelid, B. Tveit (1986) (Fig. 1). Periodontal probe Explorer was used for an in-depth clinical examination, and the following equipment was used for X-ray examination: an innovative fifth-generation dental computer tomographic scanner Vereviewepocs 3D R100 (Morita, Japan) - for digital panoramic 2D diagnostics (OPG) and Cone Beam Computed Tomography (CBCT) in 3D mode; an intraoral sensor of a new standard Planmeca ProSensor (Finland) -

**Table I.** The number of clinically detected hidden carious cavities, depending on teeth group, localization and lesion depth, (abs., %)

Localization of carious defects, teeth group, lesion depth	The number of carious defects	
	n	%
<b>Approximal surfaces of molar teeth</b>	<b>188</b>	<b>50.81</b>
<u>upper jaw:</u>	<u>102</u>	<u>54.25</u>
of these superficial	2	
medium	45	
deep	55	
<u>lower jaw:</u>	<u>86</u>	<u>45.75</u>
of these superficial	-	
medium	47	
deep	39	
<b>Approximal surfaces of premolar teeth</b>	<b>119</b>	<b>32.16</b>
<u>upper jaw:</u>	<u>61</u>	<u>51.26</u>
of these superficial	-	
medium	24	
deep	37	
<u>lower jaw:</u>	<u>58</u>	<u>48.74</u>
of these superficial	-	
medium	21	
deep	37	
<b>Approximal surfaces of canine teeth</b>	<b>11</b>	<b>2.97</b>
<u>upper jaw:</u>	<u>10</u>	<u>90.9</u>
of these superficial	-	
medium	2	
deep	8	
<u>lower jaw:</u>	<u>1</u>	<u>9.09</u>
of these superficial	-	
medium	-	
deep	1	
<b>Approximal surfaces of incisor teeth</b>	<b>52</b>	<b>14.05</b>
<u>upper jaw:</u>	<u>44</u>	<u>84.62</u>
of these superficial	7	
medium	25	
deep	12	
<u>lower jaw:</u>	<u>8</u>	<u>15.38</u>
of these superficial	-	
medium	5	
deep	3	
Total	370	12.48

for local 2D diagnostics of several teeth in radiovisiography mode.

Caries diagnostics was carried out under the conditions of clinical encounter of patients based at University Dental Center of Kharkiv National Medical University. Certification for X-ray study carrying out normally occurred after dental examination. However, in some cases CBCT images made for other purposes such as in-depth diagnostics of endodontal pathology, periodontal diseases, sinus pathology, when planning dental implantation, etc. were evaluated first, and then clinical evaluation of teeth condition of these patients was performed.

The study conducted in accordance with the 7th revision of the principles of the Declaration of Helsinki (2013), the European Convention on Human Rights and Biomedicine.

Statistical processing of the actual material was carried

out using a statistical package Statistica 13.2 with Fisher's z test and chi-square test.

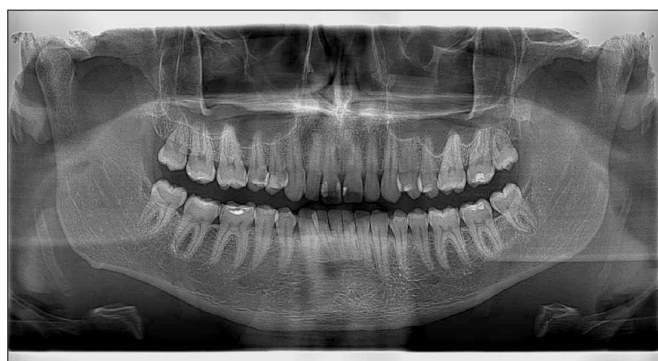## RESULTS AND DISCUSSION

According to the results of the analysis of hard tissues condition of 2963 teeth, we clinically diagnosed 370 hidden carious lesions of approximal teeth surfaces, which was  $12.48 \pm 1.2\%$  of cases (Table I). Carrying out X-ray examination allowed us to additionally detect 78 more hidden carious cavities of the specified localization ( $2.63 \pm 0.2\%$ ) (Table II) and increase the effectiveness of their diagnostics by 1.2 times ( $p < 0.05$ ).

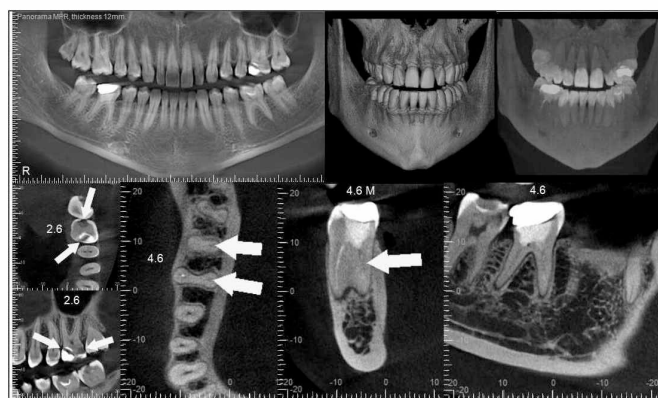
That is, the combination of both diagnostic methods allowed us to diagnose only 448 hidden caries cavities, which was  $15.11 \pm 1.7\%$  of total teeth number, the condition of which was analyzed (Table II).

**Table II.** The number of X-ray detected hidden carious cavities depending on teeth group, localization and lesion depth, (abs., %)

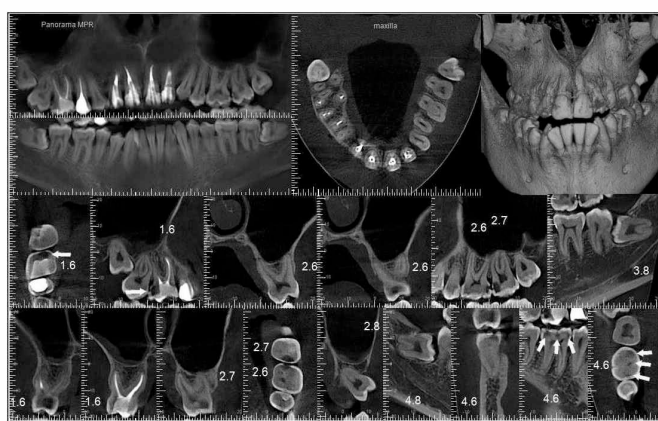
Localization of carious defects, teeth group, lesion depth	The number of carious defects		The level of significance in comparison with clinically detected carious defects
	n	%	
<b>Approximal surfaces of molar teeth</b>	<b>243</b>	<b>54.25</b>	<b>0.5362</b>
<u>upper jaw:</u>	<u>131</u>	<u>53.91</u>	<u>0.9515</u>
of these C1	7		
C2	25		
C3	54		
C4	42		
C5	3		
<u>lower jaw:</u>	<u>112</u>	<u>46.09</u>	<u>0.9620</u>
of these C1	6		
C2	16		
C3	49		
C4	36		
C5	5		
<b>Approximal surfaces of premolar teeth</b>	<b>136</b>	<b>30.36</b>	<b>0.7569</b>
<u>upper jaw:</u>	<u>73</u>	<u>53.68</u>	<u>0.7800</u>
of these C1	5		
C2	8		
C3	23		
C4	36		
C5	1		
<u>lower jaw:</u>	<u>63</u>	<u>46.32</u>	<u>0.7900</u>
of these C1	1		
C2	4		
C3	21		
C4	37		
C5	-		
<b>Approximal surfaces of canine teeth</b>	<b>11</b>	<b>2.45</b>	<b>0.7838</b>
<u>upper jaw:</u>	<u>10</u>	<u>90.91</u>	<u>0.9994</u>
of these C1			
C2	1		
C3	2		
C4	7		
C5	-		
<u>lower jaw:</u>	<u>1</u>	<u>9.09</u>	-
of these C1	-		
C2	-		
C3	-		
C4	1		
C5	-		
<b>Approximal surfaces of incisor teeth</b>	<b>58</b>	<b>12.95</b>	<b>0.8660</b>
<u>upper jaw:</u>	<u>48</u>	<u>82.76</u>	<u>0.8096</u>
of these C1	3		
C2	8		
C3	25		
C4	12		
C5	-		
<u>lower jaw:</u>	<u>10</u>	<u>17.24</u>	<u>0.9157</u>
of these C1	-		
C2	2		
C3	5		
C4	3		
C5	-		
Total	448	15.11	0.2777



**Fig. 2.** Orthopantomography (OPG) of a patient D. Hidden carious cavities in teeth 1.5 (K3), 3.8 (K1), 3.7 (K1, K2), 3.6 (K2), 4.6 (K2)



**Fig. 3.** OPG and CBCT screenshots of a patient P. Hidden carious cavities in teeth 2.6 (K4), 4.7 (K5)



**Fig. 4.** OPG and CBCT screenshots of a patient H. Hidden carious cavities in teeth 2.6 (K3), 2.7 (K4), 4.6 (K2, K3), 4.8 (K1)

The data in the tables show that the frequency of hidden carious cavities detection was different depending on teeth group. It should also be noted that this dependence persisted both in clinical diagnostics and X-ray study. Thus, the number of hidden carious cavities was the highest in molar teeth (50.81% in the clinical study and 54.25% - in X-ray study,  $p = 0.5362$ ). Among premolar teeth the number of hidden cavities was somewhat lower – 32.16% and 30.36% respectively,  $p = 0.7569$ . In the frontal group of teeth hidden cavities were recorded in even smaller

number: among incisor teeth in 14.05% and 12.95% of cases respectively ( $p = 0.8660$ ) and among canine teeth – in 2.97% and 2.45% of cases respectively ( $p = 0.7838$ ). That is, the frequency of caries lesion of different teeth groups had the following sequence in descending order: molar teeth, premolar teeth, incisor teeth and canine teeth, which coincides with the data of Mykhalchenko A.V. and co-writers [19].

Regarding the detection of hidden carious cavities depending on the jaws, the number of caries defects in the upper jaw was higher than in the lower jaw in both variants of the study. With that, the difference in the number of hidden cavities in upper and lower jaws was statistically significant only in frontal teeth group: in clinical study –  $p = 0.0001$  among canine teeth and  $p = 0.0000$  among incisor teeth; in X-ray study –  $p = 0.0000$  among canine teeth and incisor teeth.

The characteristics of hidden carious defects according to the lesion depth was the following. Signs of carious process on approximal surfaces only within the enamel were detected clinically in 9 teeth ( $0.30 \pm 0.1\%$ ), and using X-ray according to the criteria C1 and C2 - in 86 teeth ( $2.90 \pm 0.1\%$ ), that is 9.6 times more ( $p = 0.0000$ ). The occurrence of carious cavities of medium depth was diagnosed in 169 teeth ( $5.70 \pm 0.2\%$ ) using the clinical method and - in 179 teeth ( $6.04 \pm 0.2\%$ ) using X-ray (according to the criterion C3). Deep carious cavities were detected clinically in 192 teeth ( $6.47 \pm 0.3\%$ ) and using X-ray (according to the criteria C4 and C5) - in 183 teeth ( $6.17 \pm 0.1\%$ ). That is, hidden carious cavities of medium depth as well as deep cavities were detected with almost the same frequency in both variants of the study, which by 1.9 - 2.0 times respectively exceeded the frequency of superficial carious cavities detection ( $p = 0.0001$ ). Taking into account the results of clinical studies presented in Table I, superficial carious cavities are detected in single cases or are not detected at all. X-ray examination helps to improve the diagnostics of caries at early stages of its development (C1 and C2), which is confirmed by the data in Table II.

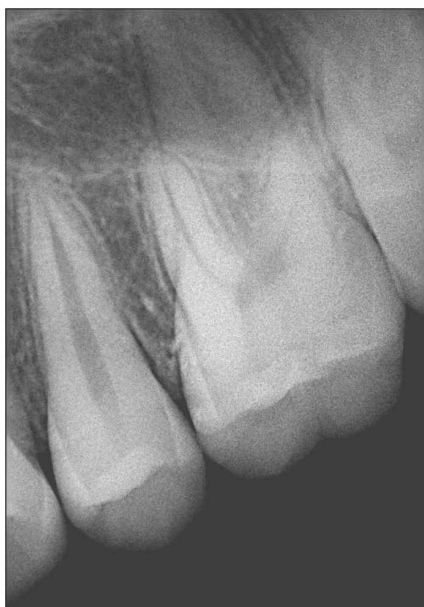Some errors were made during the analysis of the obtained data of X-ray examination (OPG), the total number of which was 24 cases. Given that, the bulk of errors (22 observations,  $91.7 \pm 5.6\%$ ) was accounted for overdiagnosis. False picture of carious lesions in 22 teeth was due to dental fillings of X-ray transparent materials that do not have a geometrically correct shape and are placed without cavity liners. Overdiagnosis in remaining observations (2 cases,  $8.3 \pm 0.6\%$ ) is associated with the location of carious cavities below the contour height. The crucial part in clarifying the truth was to carry out in-depth X-ray examination - CBCT.

Examples of detecting hidden carious defects on OPG and in CBCT screenshots are presented in Fig. 2 - 4.

It should be noted that, in our opinion, X-ray examination was virtually irrelevant for effective diagnostics on the condition of high-quality images.

However, comparison of X-ray data with the results of clinical examination showed that distortion of carious defects sizes occurred quite often. The degree of distortions was the smallest on CBCT and OPG. The risk of false in-





**Fig. 5.** Local 2D diagnostics of teeth 2.5, 2.6 in radiovisiography mode. Hidden carious cavity in a tooth 2.6 (K1)

formation was higher when carrying out OPG compared with CBCT. The reason for this in the area of incisor teeth was overlapping of the shadow from the tongue and in the area of canine teeth and premolar teeth - overlapping of approximal surfaces of adjacent teeth. The best diagnostic capabilities were in incisor teeth and molar teeth.

While carrying out CBCT, especially on the latest-generation devices, the risk of improper visualization of hidden cariosity was virtually absent and possible only in the presence of anomalies in dentition.

According to the results of the study, X-ray diagnostics of hidden caries defects among all the teeth groups was the most complicated in upper premolar teeth due to the peculiarities of the shape of these teeth and the degree of their shadows overlapping.

In case of suspicion of hidden carious cavity after carried out clinical examination, it is generally enough to refer the patient to a local 2D diagnostic procedure of several teeth in radiovisiography mode (Fig. 5).

In our opinion, it is necessary to extend the readings to X-ray examination for dental caries. The preference is to be given to orthopantomography, taking into account reasonably sufficient diagnostic capabilities of this method. Orthopantomography should be carried out strictly in the position of central occlusion in order to avoid dental tissues overlapping. In complicated cases it is rational to carry out 3D X-ray diagnostics, which allows obtaining more accurate image not only in sagittal (like orthopantomography), but also in transversal and axial projections. But the use of CBCT can not be justified for the diagnostics of caries only, which coincides with the opinion of Young and others (2009), Wenzel and others (2013). The latter may, however, be an occasional finding during CBCT on condition of necessity for diagnostics of endodontal pathology, periodontal diseases in order to plan a dental implantation etc.

## CONCLUSIONS

Methods of 2D diagnostics – OPG and radiovisiography have reasonably sufficient diagnostic capabilities. 3D diagnostics should never be used for caries diagnostics only. But, undoubtedly, only CBCT provides an optimal diagnostic capability to evaluate not only the topography of hidden carious cavities, but their sizes as well. Therefore, carrying out 3D diagnostics may be recommended for in-depth study of a specific clinical situation.

It would be appropriate to consider the study of frequency of secondary caries occurrence with the use of modern X-ray methods as perspectives of further researches.

## REFERENCES

1. Vasil'yev A.Y. *Lučevaya diagnostika v stomatologii: natsional'noye rukovodstvo*. M.: GEOTAR-Media, 2010; 288.
2. Ritter I., Reiz S., Rothamel D. et al. Registration accuracy of three-dimensional surface and cone beam computed tomography data for virtual implant planning. *Clin. Oral Implant. Res.* 2012;XXIII,4:447-452.
3. Arkhipov A.V., Arkhipov V.D., Vyrmaskin S.I. [i dr.] *Effektivnost' sovremennykh metodov rentgenologicheskogo obsledovaniya v usloviyakh stomatologicheskoy polikliniki*. *Izvestiya Samarskogo nauchnogo sentra Rossiyskoy akademii nauk*. 2014;XVI,5(4):1364-1367.
4. Borisenko A.V. A.V. Borisenko, Pechkovskiy K.Ye., Nesin A.F. [i dr.] *Rentgenologicheskaya diagnostika pul'pita*. *Sovremennaya stomatologiya*. 2013;3:19-21.
5. Kulakov A.A. *Ekspertiza kachestva okazaniya stomatologicheskoy pomoshchi (klinicheskiye aspekty)*. M., 2012:398.
6. Chibisova M.A., Zubareva A.A., Dudarev A.L., Shavgulidze M.A. *Primeneniye konusno-luchevoy komp'yuternoy tomografii v khirurgicheskoy stomatologii, chelyustno-litsevoy khirurgii i otorinolaringologii dlya differentsial'noy diagnostiki stomatologicheskikh zabolevaniy*. *Stomatolog-praktik*. 2012;4:20-25.
7. Fanakin V.A., Butyugin I.A., Batanova Ye.V. *Konusno-luchevaya komp'yuternaya tomografiya v detskoj stomatologii: Problemy stomatologii*. *Actual problems of stomatology*. 2014;4.
8. Aggarwal V., Logani A., Shah N.: The evaluation of computed tomography scans and ultrasounds in the differential diagnosis of periapical lesions. *J Endod.* 2008; XXXIV, 11: 1312-1315. doi:10.1016/j.joen.2008.08.005.
9. Chan H.I. Mbch I.C. Wang H.L. *Dental imaging in implant treatment planning*. *Implant Dent.* 2010; 19: 288-298. doi: 10.1097/ID.0b013e3181e59ebd.
10. Henriques J.C., Castilho J.C., Jacobs R., Amorim J.B., Rosa R.J.L., Matai G.V., - Correlation between hand/wrist and panoramic radiographs in severe secondary hyperparathyroidism. *Clin. Oral Invcstig.* 2012; 16. doi: 10.1007/s00784-013-1025-0. Epub 2013 Jul 12.
11. Adams G.I., Gansky S.A., Miller A.I., Harrell W.E., Hatcher D.C. Comparison between traditional 2-dimensional cephalometry and 3-dimensional approach on human dry skulls. *Am. J. Orthod. and Dentofacial Orthop.* 2004; LXXIV, 4: 397-409. doi:10.1016/S0889540604003439.
12. Cartes G., Garey I., Deana N., Navarro P., Alves N. *Mandibular Canal Course and the Position of the Mental Foramen by Panoramic X-Ray in Chilean Individuals*. *Biomed Res Int.* 2018. Jun. 7; doi: 10.1155/2018/2709401.
13. Jacobson A., Jacobson R.J.: *Radiographic cephalometry. From basics to 3-D imaging*. Quintessence Books. 2006. ISBN 10: 0867154616 ISBN 13: 9780867154610.
14. Rogatskin D.V. *Radiodiagnostika chelyustno-litsevoy oblasti. Konusno-luchevaya komp'yuternaya tomografiya. Osnovy vizualizatsii*. – L'vov: GalDent, 2010. – 148 s.

15. Ruzhilo-Kalinovskaya I., Ruzhilo T.K. Trekhmernaya tomografiya v stomatologicheskoy praktike. Per. s pol'sk. L'vov, 2012: 584.
16. Spin-Neto R., Mudrak J., Matzen L.H. et al. Cone beam CT image artefacts related to head motion simulated by a robot skull: visual characteristics and impact on image quality. Dentomaxillofac Radiol. 2013; Feb. XXXII (2): 1-8. doi: 10.1259/dmfr/32310645.
17. Young S.M., Lee J.T., Hodges R.J. et al. A comparative study of high-resolution cone beam computed tomography and chargedcoupled device sensors for detecting caries. Dentomaxillofac Rad. 2009; 38: 445-51.
18. Batista W.O.C., Nawarro MYT., Maia A.F.: Effective doses in panoramic image from conventional and CBCT equipment. Radial Prot Dosimetry. 2012; CLI (1): 67-75. doi:10.1148/radiol.2481071451.
19. Mikhal'chenko A.V., Mikhal'chenko D.V., Zakhvatoshina M.A., FilyukYe.A. Kharakternyye lokalizatsii defektov tverdykh tkaney zubov u vzroslykh. Fundamental'nyye issledovaniya. 2014; 4:114-117.

*The article is prepared within the framework of the initiative research work implementation of the Department of Dentistry of Kharkiv National Medical University «Development of new methods of diagnostics, treatment and prevention of dental pathology in children and adults», the implementation period is 2015-2017, the registration code is 0115U000230 (the head is Professor I.I.Sokolova) and research work of the Department of Dentistry of post-graduate education with the course of therapeutic and orthopedic dentistry of Uzhhorod National University «Study of a problem of biological effects of iodine-fluorine deficiency in the environment on the intensity of clinical course of maxillofacial area pathology. Modern diagnostic methods and characteristics of comprehensive treatment», the implementation period is 2016-2018, the registration code is 0114U001382 (the head is Professor A.M. Potapchuk).*

**Authors' contributions:**

*According to the order of the Authorship.*

**Conflict of interest:**

*The Authors declare no conflict of interest.*

---

**CORRESPONDING AUTHOR**

**Iryna I. Sokolova**

Kharkiv National Medical University

Kharkiv, Ukraine

tel: +380503433988

e-mail: sokdentirina@gmail.com

**Received:** 11.02.2019

**Accepted:** 04.06.2019