

***Kharkiv National Medical University
Department of Prosthetic Dentistry***

***Skills algorithms
for a practically-oriented state exam in
the specialty "Prosthetic dentistry"***

Kharkiv-2019

External reviewers: Head of Department of Propaedeutics of Prosthetic Dentistry of the Medical dentistry Academy, Habilitated degree in Medicine, Professor Dmitriy M. Korol, Head of the Department №1 of Prosthetic Dentistry of the Kharkov Medical Academy of Postgraduate Education the Ministry of health Ukraine, Habilitated degree in Medicine, Professor Vasiliy I. Grizodub.

The authors of Study Guide:

Skill algorithms for a practice-oriented state exam by specialty "Orthopedic Dentistry": study guide for the students and interns of the Faculty of Dentistry / Ihor Yanishen, Hennadii Hryshanin, Viacheslav Tomilin, Iryna Diudina, Iryna Pereshivailova. – KhNMU, 2019. – 95 p.

Study Guide is composed in accordance with the program of the course of orthopedic dentistry. In the Study Guide, there was an increased focus on the basic schemes of action algorithms, which is necessary to perform manual skills in accordance with the Protocol for the orthopedic treatment of patients during outpatient admission at the clinic of orthopedic dentistry.

The Study Guide is recommended for students, interns and teachers of the Faculty of Dentistry.

Approved by the Scientific Council of the KNMU Protocol № __ __/__/20__.

Additional information on the following links:

<http://www.liveinternet.ru/users/gengrish/>

<http://gengrish.livejournal.com/>

Content

1.	The scheme of examination of the patient in the clinic of orthopedic dentistry.	4
2.	Diagnosis Making	9
3.	Treatment planning	17
4.	Selective grinding of teeth, alignment of the occlusal surface, occlusiogram	21
5.	Ligature binding of teeth	24
6.	Preparation of tooth hard tissues under the full stamped metal crown. .	27
6.1.	Sequence of using diamond abrasives of various grit, designation, properties, abbreviation	28
6.2.	Recommended speeds of rotation of abrasive heads in revolutions per minute	28
7.	Preparation of tooth hard tissues under a plastic crown	30
8.	Impression Taking Procedures.	31
8.1.	The plan of treatment of edentulous patients by complete removable laminar dentures	36
9.	Gypsum Model Production.	38
10.	Central Jaw Relationship Determination in Edentulous Patient	38
11.	Crowns fitting	42
12.	The Single Swaged Crowns Inspection	46
13.	Checking of the Framework of Cast-Metal Crowns	47
14.	The frameworks of fixed solid cast bridges checking with supporting elements in the form of full crowns on the phantom	49
15.	Crown's fixation.	50
16.	Dental Bridges Cementation.	53
17.	Crown removal.	54
18.	Dental Bridge removal.	56
19.	Try-in for acrylic partial and complete removable laminar dentures. .	59
20.	Partial and Complete Removable Dentures Bases Correction	60

The initial stage of professionally-oriented exam in the specialty «*Orthopedic dentistry*» is the examination patient.

Initial definition: examination – is a complex of studies of patient that are carried out in a certain traditionally established sequence to establish the individual characteristics of clinical manifestations and the course of the disease – the diagnosis.

1. Scheme of examination patient in clinic of orthopedic dentistry.

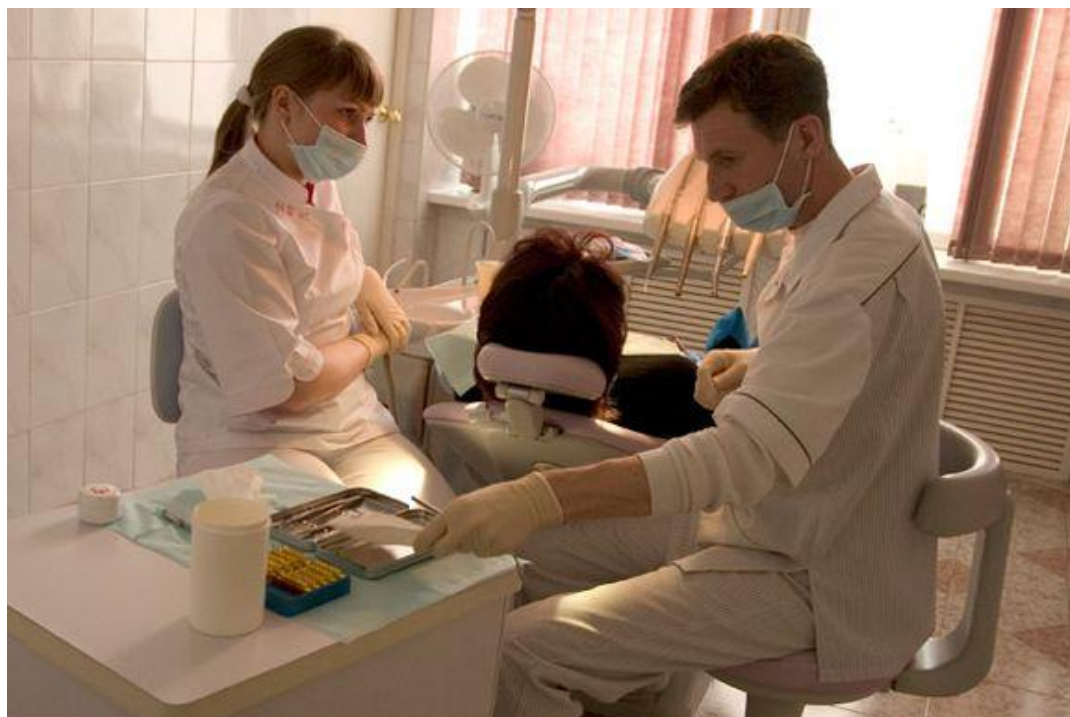Purpose of task: mastering and consolidating the skills necessary for examination patient in clinic of orthopedic dentistry, for to work with an outpatient card of a dental patient.

Material security:

- patient;
- dental unit;
- big kidney-shaped tray with tool for inspection: dental mirror, throat spatula.

Medical requirements:

- it is necessary to conveniently place the patient in the dental chair: head at the level of the doctor's elbow;
- wear a latex gloves and a mask;
- the doctor is located in front of the patient, when examining the area of the upper or lower jaw, the doctor in the right hand holds the probe, in the left - the dental mirror.



SEQUENCE OF METHODS EXAMINATION

Subjective Examination

The method of examination- is questioning.

Sequence: complains, anamnesis morbi, anamnesis vitae.



The patient's examination, as a rule, begins with the clarification of complaints. At the same time, complaints are not recorded in a random sequence, but they find out and then clarify the main, the **most relevant and further less relevant motives** of the patient's treatment for help to the dentist - the orthopedist.

Considering the purposeful behavior of the patient when referring to the clinic of orthopedic dentistry from the position of functional systems, P.K. Anokhin, it should be remembered that **the careful establishment of incentives for the patient** to go to the clinic is crucial for patient satisfaction with the results of orthopedic treatment.

The motive of the patient's treatment in the clinic of orthopedic dentistry is based on the previously created **model of positive emotion associated with the results of orthopedic treatment**; namely: restoration of the anatomical integrity of the crown parts of teeth, dentition and, in addition, rehabilitation of the functions of biting, chewing, aesthetic norms of a smile, face and diction. The model of emotion is created by the patient on the basis of the previous experience of treatment and the level of intellectual and cultural development.

When clarifying and refinement the **relevance of complaint motives**, they find out, clarify and correct the **positive emotion model of orthopedic treatment**, planning a treatment, one of the stages of which is the choice of the prosthesis design, and the obligatory coordination of the treatment plan with the patient.

Orthopedist-dentist is obliged to determine the individual functional orientation of the patient's complaints, their causal relationship with anatomical disorders: defects, discoloration, the shape of the crown parts of the teeth, and defects of the dentition.

For example, difficulty or disorder of the function of biting, chewing, swallowing, aesthetic smiles and facial aids, due to defects of the crown parts of the teeth, dentition defects or edentulous jaws.

Motivation for the patient's treatment can be: color change and violation of the anatomical shape of the crown parts of the teeth, spattering of saliva during communication, violation of diction, aesthetic norms of a smile and face.

Anamnesis morbi (remembering the disease).

During the examination, the patient is questioned in detail, and then the information on how much time passed after to arise the first signs of the disease is recorded in the column "Development of a present disease". Further specify, due to complications of the course of caries diseases, paradontium, paradontosis or trauma, operations of tooth extraction were carried out. Find out how long the tooth extraction was performed. How many time has passed after the last operation. In this case, the questions asked by the patient should be focused on the manifestation of clinical symptoms, the course of the disease or the circumstances of the injury. Be sure to find out whether previously orthopedic dental care was provided, and if it turned out - establish what prosthetic designs and for what period of time the patient used and / or uses.

Anamnesis vitae (remembering the life).

Using the method of questioning, they receive information both from the patient's words and from documents obtained from other specialists, analyze the information received and put it in the column "Past and accompanying diseases."

A special note is made about the source of information: "From the words of the patient ...", "Based on the extract from the medical history ..." "Based on the reference ...". In this case, the doctor must find out whether the patient is on or before the dispensary, whether the treatment was conducted and for how long.

They are questioning, treatment has been carried out for the diseases of hepatitis, tuberculosis and other infections that present the epidemiological danger of infectious contamination of others.

A separate line indicates whether the patient is currently suffering from cardiovascular, neuropsychiatric diseases that present a threat of exacerbation or a crisis course during treatment.

Carefully find out the presence of concomitant diseases in order to take measures to prevent and treat possible complications syncope, collapse, hyper- and hypotonic

crises, attack of stenocardia, hypo- and hyperglycemic coma, epileptic attack). Pay attention to the presence in the patient of diseases of the gastrointestinal tract, endocrine disorders.

A separate line indicates the presence and / or absence in the patient's history of allergic manifestations and reactions, indicates the patient's well-being at the present time.

Objective Examination

Method examination: inspection (visual research).

Conducted in good light, better natural, with the help of a set of dental instruments: a mirror, a probe, a throat spatula, eye tweezers. Before starting the examination, the doctor wears gloves and a mask. When examined make used gauze wipes.

Sequence of examination:

Head, face: presence and / or expression - asymmetry, nasolabial folds, submental folds, and depth.

The angles of the mouth: location, the presence of pathological changes. **Red lip rim:** color, the presence of pathological changes.

Areas of temporomandibular joints: skin color, volume of movements, and freedom of opening the mouth.

The mucous membrane of the vestibule of the oral cavity, the exit points of the ducts of the salivary glands, the mucous membrane of the gums, the lips - color, the presence of pathological changes, wetness.

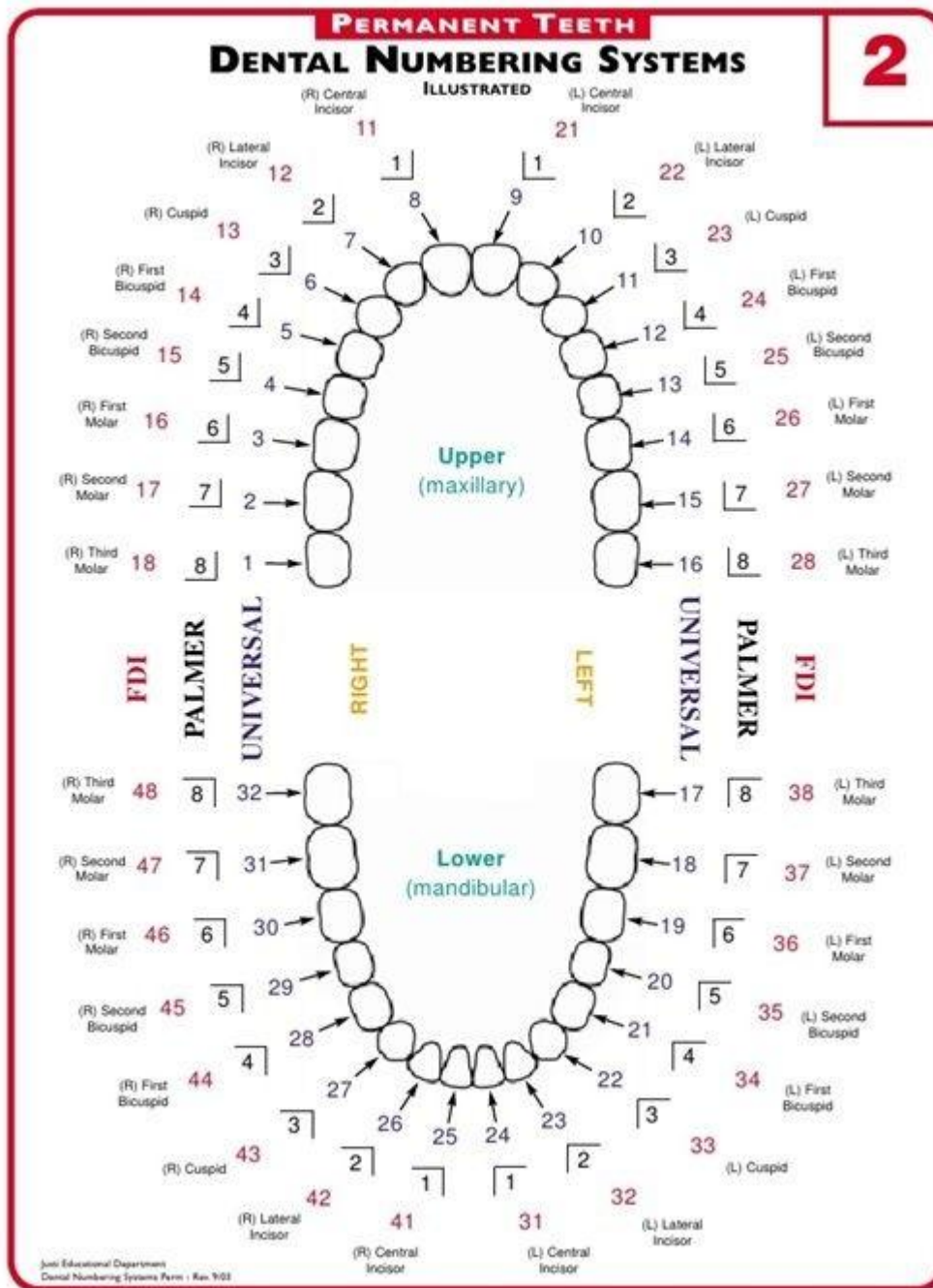
Dental rows: shape, bite, the type of dentition in the central occlusion, the presence of teeth dystopia. **Presence of defects in the crown parts of the teeth**, carious cavities, hyperemia and edema of the gum margin, presence of supra- and subgingival deposits, dentogingival pockets, bare teeth. **The presence and location of defects in the dentition**, the location of the defect in the sides and / or the front portions of the dentition and with relatively to the remaining teeth.

Status localis note in the clinical formula of the dentition: above and below the numbers denoting the quadrant of the maxillofacial region and each tooth.

In the first row, the symbols that correspond to the status at the time of filling in the document are put.

In the second row, the degree of pathological mobility of the tooth according to Entin is noted. If the teeth are stable, without pathologic mobility, then in the second row, and if noted - in the third row, with the help of conventional designations, the non-removable designs planned for orthopedic treatment of the patient are noted.

Cd – crown, ar – pin tooth, X – cast tooth, pontic of bridges.



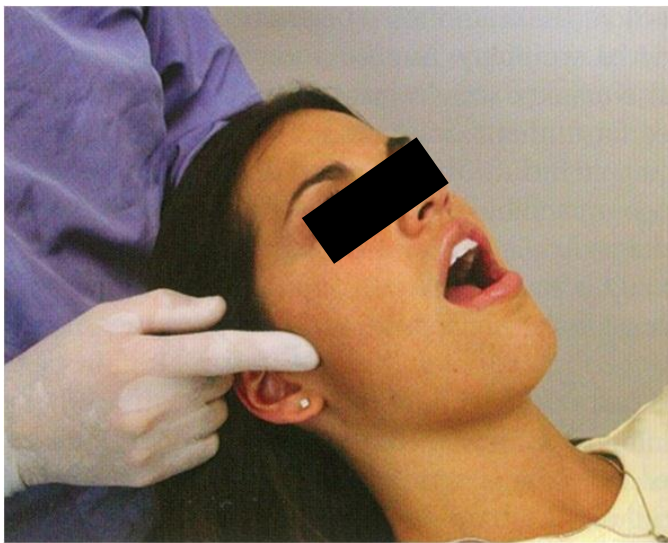
Dental numbering system of the International Dental Organization FDI-ISO (1970).

In this case, the supporting elements of the non-removable bridges denture are interconnected by arched lines. Dashes show interconnected support elements of non-removable structures of dentures. Similarly, the planned design of non-removable splint and splint-prostheses.

Determine the type of occlusion, that is, the "type of location" of teeth and dentition with relatively to antagonists in the central occlusion.

Alveolar processes, degrees of atrophy, distance from the location of the muco-gingival fold, attachment of the frenulum of the tongue, lips and strings to the crests of the alveolar processes. The height of the palate, the location and expression of the line "A". Tongue - color, the presence of pathological changes.

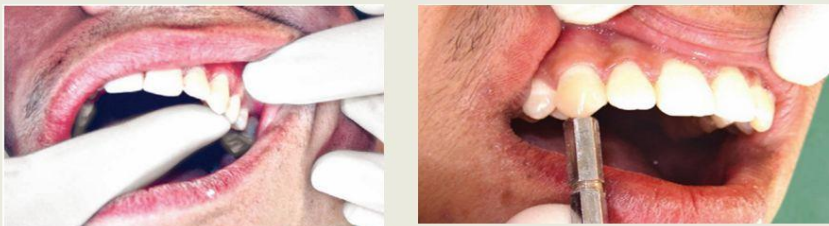
The method of examination - is palpation. Sequence: regional, submental, parotid lymph nodes: enlargement, painfulness. The area of the TMJ. Oral cavity: muco-gingival folds, abnormal mobility of teeth. Depth of carious cavities, dentogingival pockets, location of muco-gingival folds, attachment of frenulum, mucous membranes of cheeks, lips, tongue. Exostoses: presence, size, location.



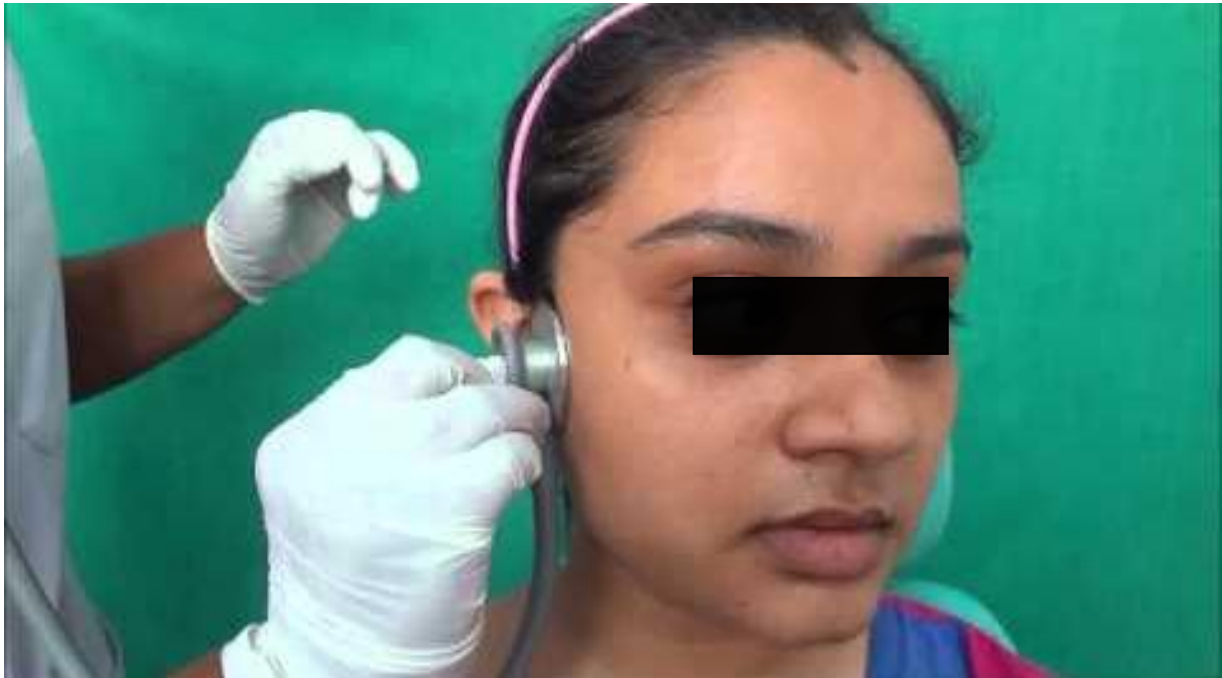The method of examination - is percussion. Sequence: each of the "problematic" teeth separately.

HOW CAN WE DO PERCUSSION?

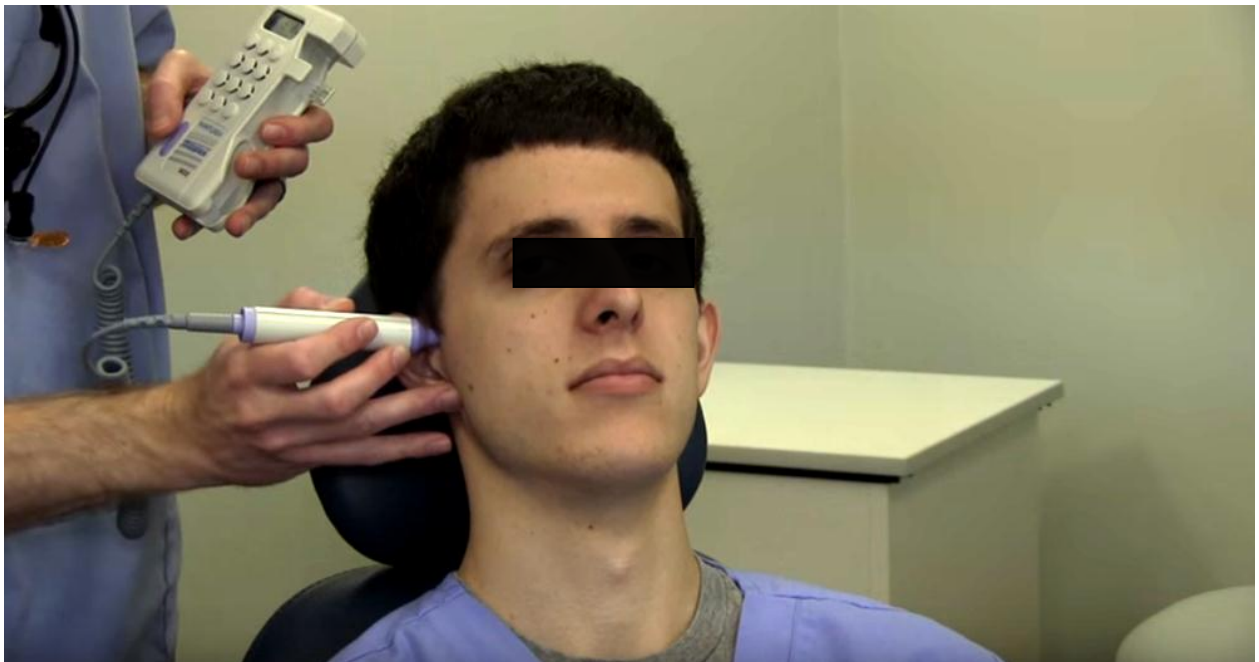- Percussion can be carried out by :
- gentle tapping with gloved finger
- Blunt handle of mouth mirror
- Each tooth should be percussed on all the surfaces of tooth until the patient is able to localize the tooth with pain. Degree of response to percussion is directly proportional to degree of inflammation



The method of examination - is auscultation. Sequence: area of the TMJ. The presence of sounds during the movement of the lower jaw, opening and closing the mouth, with functional occlusions. Vertical and horizontal percussion of "problem" teeth.



DOPPLER AUSCULTATION

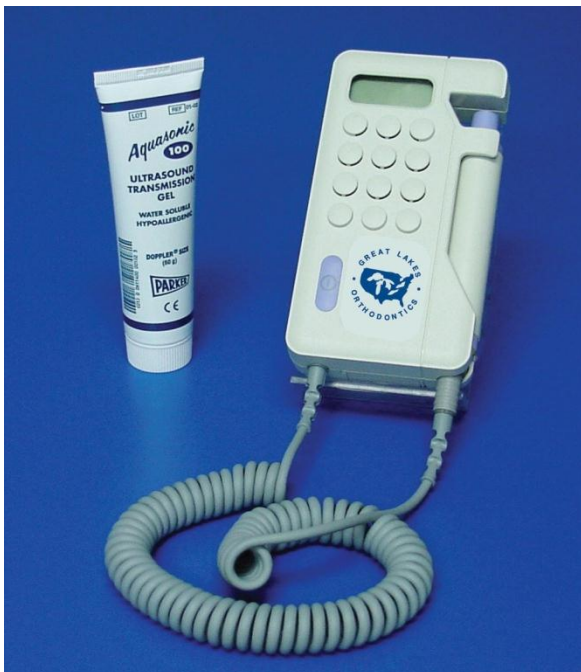

DOPPLER AUSCULTATION

A rapid, accurate auscultation instrument utilized for the detection, analysis, and evaluation of Temporomandibular Joint Dysfunction*.

FEATURES:

1. Simple to learn
2. Non-invasive
3. Easy to perform
4. Comfortable
5. Immediate feedback



DOPPLER AUSCULTATION

ADVANTAGES:

1. The 4 MHz transducer is the optimum frequency
2. for TMJ Screening.
3. This hand-held doppler is ideal for listening to
4. joint sounds (crepitus or clicking) in evaluating
5. TMJ dysfunction.
6. Allows accurate evaluation of properly aligned
7. disc assembly from a lateral pull or medial pull
8. disc displacement.

Additional Accessories:

1. Doppler Kit
2. Includes: 4 MHz transducer, gel, earphones, carrying case, & manual.
3. Doppler Gel (ea.)
4. Doppler Gel (12/pkg)

Additional methods of examination - radiography (sighting, panoramic), electrodontometry, blood tests, urine and others needed to establish a diagnosis.

RADIOVISIOGRAPHY

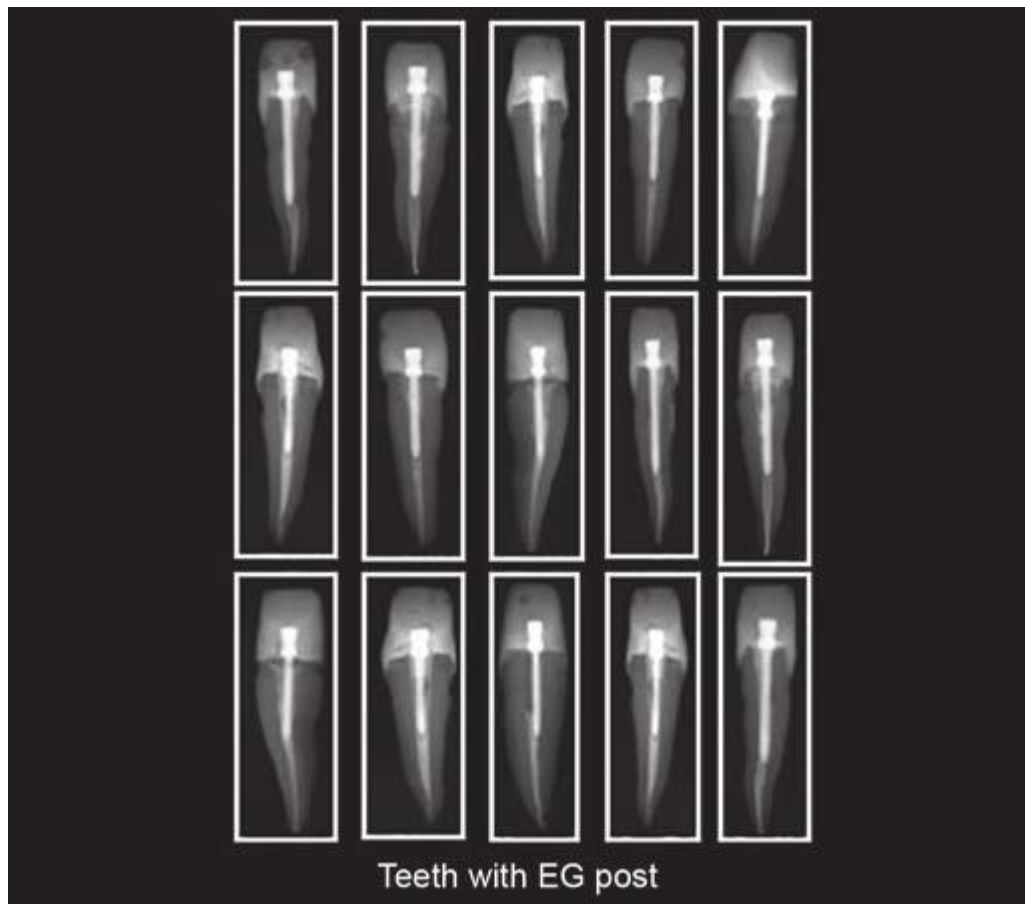
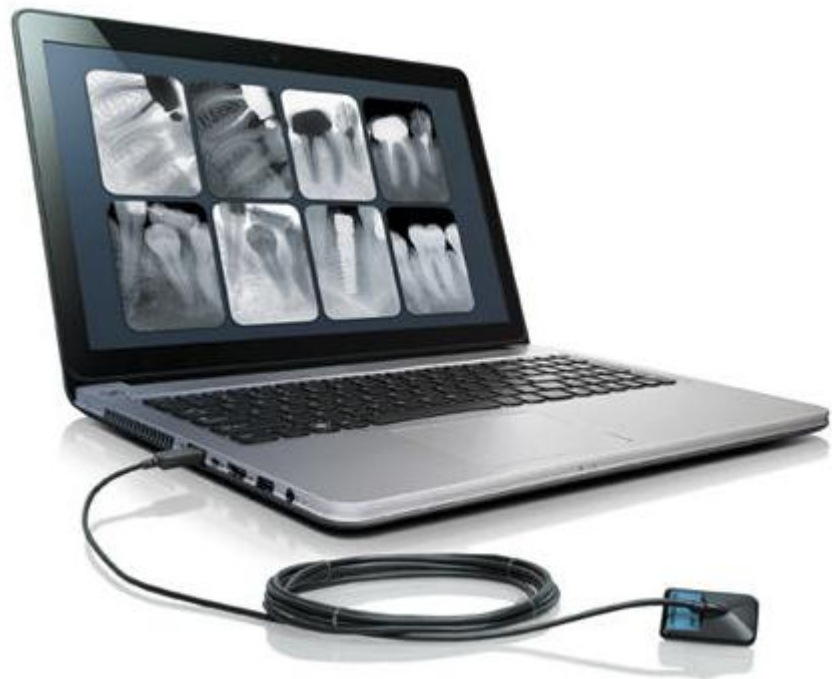- ✓ All the procedures can be visualized almost immediately
- ✓ Any area of the picture can be enlarged
- ✓ Provides necessary magnification

- ✓ Good resolution
- ✓ Conventional developing is not necessary
- ✓ Bone pattern, its height and depth during implant placement can be visualized

RADIO VISIO GRAPHY-

3 Components

- Radio- a conventional X-ray machine with a timer capable of very short exposure time.
- Visio- converts output signal from the CCD to a digital format and displays the image on a monitor.
- Graphy- a data storage unit connected to a video printer.

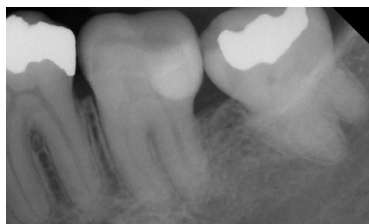

Teeth with EG post

Radiovisiography

Local films

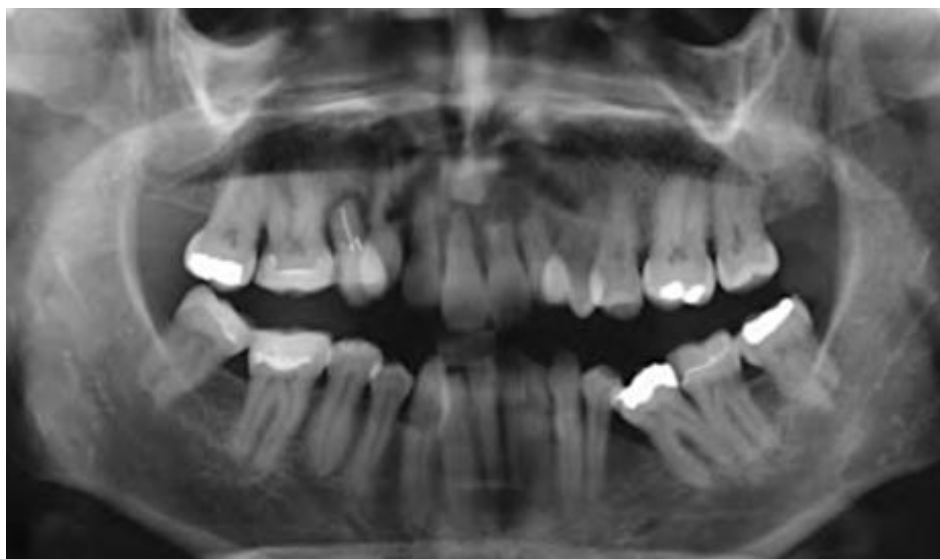(Intra-oral views) provide a sufficiently detailed view for assessing bone support, root morphology, caries, or periapical pathology.



Local film

Panoramic films

(Extra-oral views) provide useful information about the presence or absence of teeth, helpful in assessing third molars and impactions, evaluating the bone before implant placement, and screening edentulous arches for buried root tips.



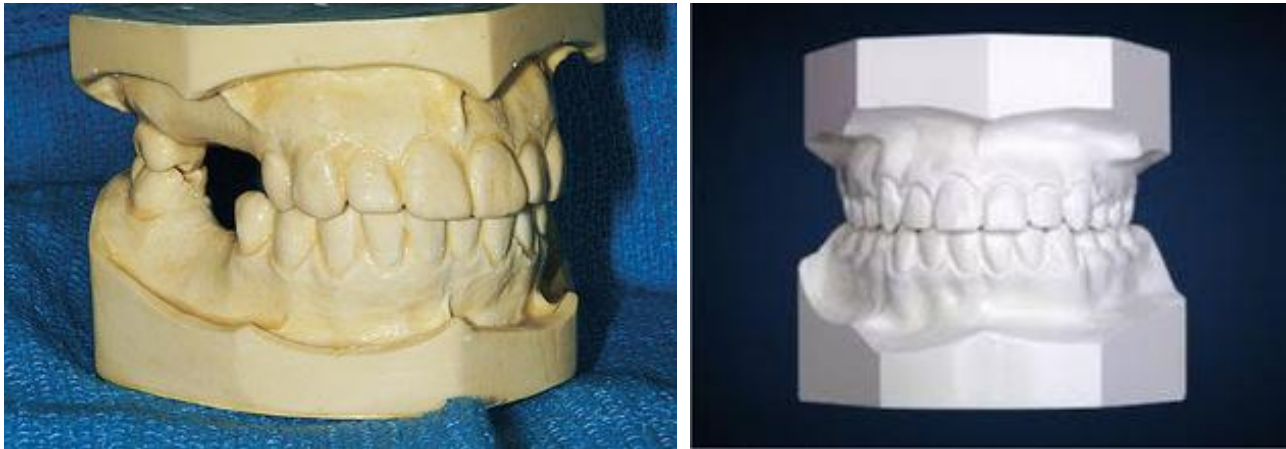
Panoramic film

Electroodontodiagnostics (electric pulp tester) – method of measuring the response to electrical stimulation the pulp (sensitivity registration to current intensity). In the norm (in case of intact teeth) pulp reacts to the 2 – 6 mA current intensity. In carious teeth pulp reacts to (20 – 40) mA current intensity; in pulpitis – 50 – 60 mA; in periodontitis – over 100 mA.

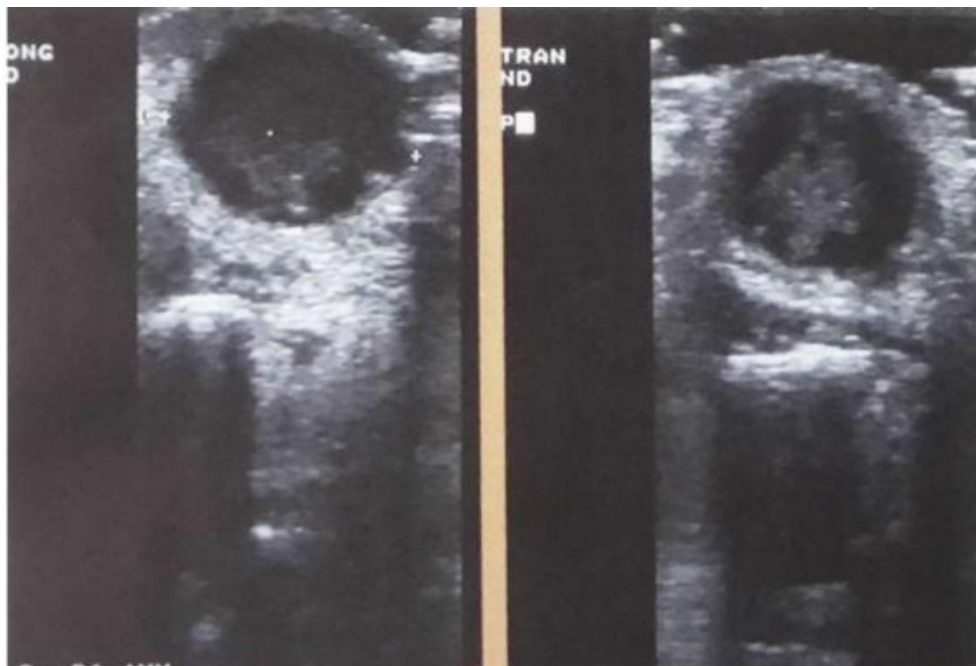

Electroodontometry (EOD)

Diagnostic models - the positive projection of the dentition and jaw, tissues of prosthetic seat area and mucosa reproduced in a gypsum or plastic (picture: Shows reduced vertical dimension, direct bite, and abnormal position of teeth).



Ultrasound (US) Ultra-high frequency sound waves are transmitted through the body using a piezoelectric material. Good probe/skin contact is required (through gel medium) as waves can be absorbed, reflected, or refracted. High-frequency (short wavelength) waves are absorbed more quickly whereas low-frequency waves penetrate further. US has been used to image the major salivary glands and the soft tissues.

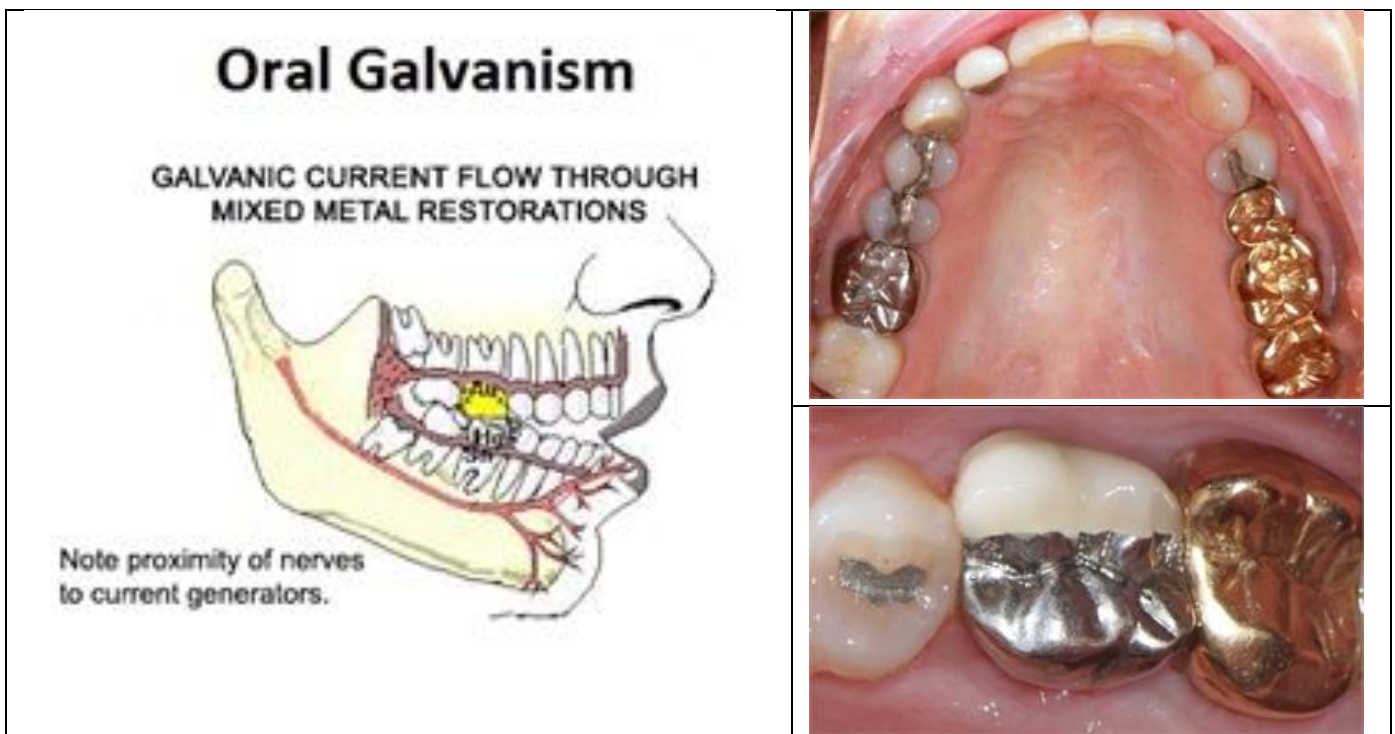


Longitudinal and transverse US sections of a submandibular gland demonstrating a sharply defined, hypoechoic round lesion. This appearance is consistent with an abscess formation in the gland, supported a diagnosis of acute sialadenitis.

Galvanometry. Pure metals are almost never used in dentistry, because the physical characteristics are inappropriate. Instead, metal fillings, crowns, and implants are made up of alloys (metal blends), and they can contain any combination of “classic” gold crown, for example, is likely made up of things like gold, platinum, palladium, silver, copper, and tin.

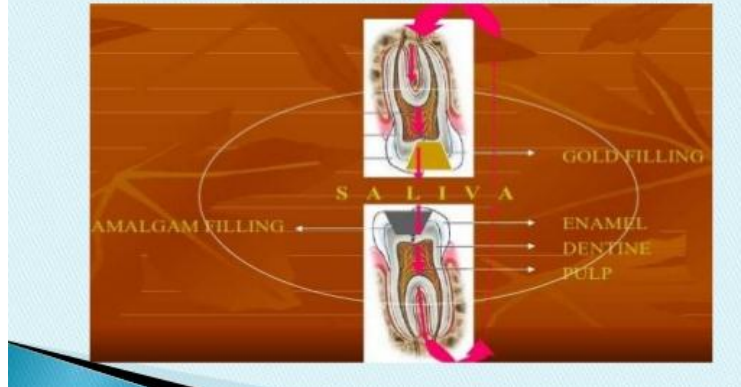An electric current, called a “galvanic” current, is generated by the transportation of metal ions from the dental metals into saliva. This phenomenon is called “oral galvanism”. First, the electric currents increase the rate of corrosion (or dissolution) of metal-based dental restorations and replacements. These ions react with other components of the body, leading to sensitivity, inflammation, and, ultimately, autoimmune disease. Second, some individuals are very sensitive to these internal electrical currents. Oral galvanism can result in local lesions, nerve shocks, a metallic or salty taste, burning tongue, unexplained pain, and discoloration.

Finally, there is the concern that oral galvanism directs electrical currents into brain tissue and can disrupt the natural electrical current in the brain.



Galvanic Shock

A pain sensation caused by electric current generated by a contact between two dissimilar metal forming a galvanic cell in oral environment.



Gnathodynamometry Method of masticatory pressure determination using different kinds of special device – gnathodynamometer. Masticatory pressure – developed by masticatory muscles and applied to masticatory surface.




FIG. 1.—Haber's gnathodynamometer in box, together with "biting plate" for estimating the pressure of single teeth.


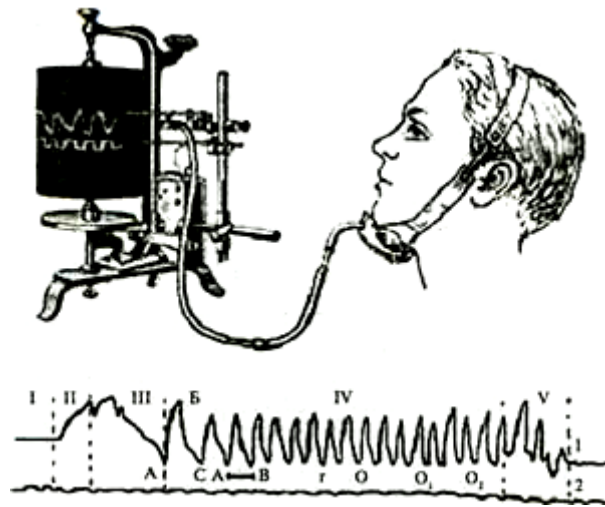
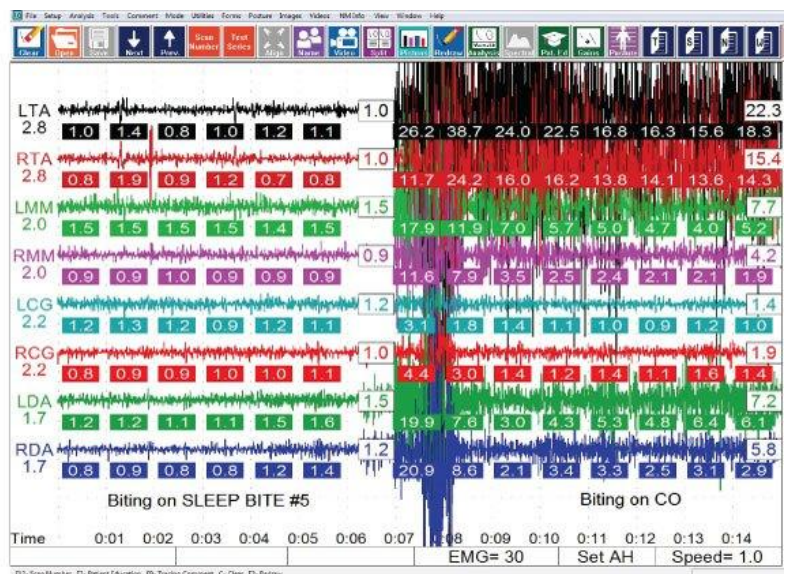


FIG. 2.—Haber's gnathodynamometer in use on the right-hand side of the mouth.

Masticatiography Method of mandible movements' registration in all chewing phases: physiological equilibrium; opening the mouth; biting the chop of food with incisors; grinding with lateral teeth; swallowing in central occlusion.



Electromyography (EMG). Electromyography, or EMG, involves testing the electrical activity of muscles. Often, EMG testing is performed with another test that measures the conducting function of nerves. This is called a nerve conduction study. During EMG, small pins or needles are inserted into muscles to measure electrical activity. Patient is asked to contract your muscles by moving a small amount during the testing. With nerve conduction studies, small electrodes are taped to patient's skin or placed around his fingers.



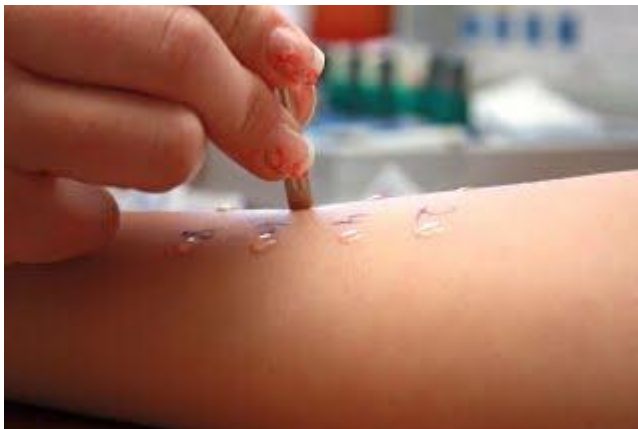Myotonometry. Method of muscular tonus determination with myotonometer. It is possible to estimate contractile muscular tonus and rest muscular tonus.

Rheography. Method of vessels pulse volume determination by means of graphic registration of electrical tissue resistance alteration.

Allergy Tests. Involves having a skin or blood test to find out what substance, or allergen, may trigger an allergic response in a person. Skin tests are usually done because they are rapid, reliable, and generally less expensive than blood tests, but either type of test may be used.

There are three types of skin tests:

1. Skin prick test.
2. Intradermal test.
3. Skin patch test.



Blood test Allergy blood tests look for substances in the blood called antibodies. Blood tests are not as sensitive as skin tests but are often used for people who are not able to have skin tests.

Laboratory tests

Blood Tests (Hematology)

Red Blood Count (RBC) - the number of red blood cells to evaluate anemia

White Blood Count (WBC) - the number of white blood cells to evaluate infection

Differential Count - the proportions of the different types of white blood cells varies in infection, allergies, etc.

Platelet Count - the count of the number of these cells which participate in blood clotting

Coagulation (clotting) studies - bleeding time, prothrombin time and other tests determine the clotting process in the blood

Hemoglobin - a measure of the oxygen-carrying capacity of the blood

Chemistry tests

- Sugar (glucose) - the amount of sugar in the blood is a measurement for diabetes mellitus
- Electrolytes (sodium, potassium, chloride and carbon dioxide) - these substances maintain fluid and blood pressure balance and are essential for the function of most body systems
- Enzymes (CK, LD, AST, ALT) - help to diagnose heart and liver diseases
- Cholesterol - high amounts are associated with heart and blood vessel diseases
- Urea Nitrogen - test for kidney function
- Uric Acid - may indicate gout

Microbiology

- Culture - growth of bacteria for the purpose of identification
- Smear/Stain - preliminary evaluation of infection
- Sensitivity test - testing bacteria with antibiotics to determine which drug is most effective

Urinalysis Many individual tests make up the urinalysis, such as glucose, blood, bacteria. The physician gains information about the kidneys, liver and other body processes from these tests.

Cytology

- Pap smear - microscopic examination of cells to determine abnormal conditions or malignancy
- Sputum - microscopic evaluation for malignancy or other disorders such as asbestosis

Histology Biopsy - the removal of a small section of tissue to be studied. The type of cells and their chemical reactions are evaluated.

Immunology AIDS test - positive when a person has the AIDS virus

Immunoematology (Blood Bank) Blood type and Rh - to identify a person's blood type which can be O, A, B or AB and Rh which can be either positive or negative.

Saliva pH assessment Saliva sampling is performed fasting or in 3 – 4 hours after the last meal. The patient rinses his oral cavity with distilled water and gather all the content into the test tube. After that the pH instrument is placed into the tube and assessments are taken.

Determination of masticatory efficiency

A diagnosis must be based on adequate information and must account for the findings from the history and examination. Where findings cannot be accounted for, further investigation may be incorporated into the treatment plan, provided such action would not be injurious to the patient.

Teeth coefficients of masticatory efficiency by N.I. Agapov

		50																
		25								25								
Agapov	25	0	5	6	4	4	3	1	2	2	1	3	4	4	6	5	0	25
Dental formula	50	18	17	16	15	14	13	12	11	21	22	23	24	25	26	27	28	50
		48	47	46	45	44	43	42	41	31	32	33	34	35	36	37	38	
Agapov	25	0	5	6	4	4	3	1	2	2	1	3	4	4	6	5	0	25
		25								25								
		50																
Total		100																

Teeth coefficients of masticatory efficiency by I.M. Oxman

		50																
		25								25								
Oxman	25	3	5	6	3	3	2	1	2	2	1	2	3	3	6	5	3	25
Dental formula	50	18	17	16	15	14	13	12	11	21	22	23	24	25	26	27	28	50
		48	47	46	45	44	43	42	41	31	32	33	34	35	36	37	38	
Oxman	25	4	5	6	3	3	2	1	1	1	1	2	3	3	6	5	4	25
		25								25								
		50																
Total		100																

Functional methods of masticatory efficiency determination Efficiency of mastication depends on the following factors:

- number of articulating pairs,
- presence of teeth with caries and its complications,
- state of parodontium and masticatory muscles,

- type of bite,
- dentomaxilla anomalies,
- general state of the organism,
- neuroreflector connections,
- saliva discharge and composition of saliva,
- size and consistency of food lump.

Masticatory tests

The method of masticatory apparatus function evaluation was worked out by Christiansen in 1923. For this purpose it was given three identical cylinders of a coconut to a patient. After 50 masticatory motions the oral cavity fluid with the chewed nuts was spited out in a tray, washed, dry out at the temperature 1000 C during 1 hour and sift through the special sieve. They judge about efficiency of mastication through the amount of unsifted particles of the food which remained in the sieve.

The goal of masticatory tests:

1. To determine the functional status of masticatory system
2. To define the indications to the restorations of masticatory system
3. To evaluate the effectiveness of orthopedic treatment.

Physiological masticatory according by I.S. Rubinov

It was determined that in pathological processes of maxilla-facial region (lost of teeth or other abnormalities) the chewing time to the swallowing moment is prolonged.

It was also determined the duration of chewing process is equal to 14 c. in case of orthogenetic bite (the rest in the sieve is 0). The patient is given 0,8 g. of hazelnut and he chews the nut to the swallowing reflex.

Investigator obtains two measures:

1. Percentage of pulverized food.
2. Chewing time.

Physiological masticatory according by Helman

Masticatory efficiency is determined by chewing duration analysis. The patient is given of 5 g of almonds and he chews it during 50 sec. Then he spit bolus into the bowl, rinses the

oral cavity with boiled water and also spit the content of his oral cavity. For disinfection purpose 5 – 10 drops of the 5 % sublimate solution is added. All the mass is filtered with gauze. The remainder is dried using the water bath, then it is sieved. Received mass is weighted. The result converse into percentage. Ex.: The rest on the sieve is 2,82 g. Then the percentage of masticatory efficiency is composed: 5 g. – 100 %; 2,82 – X; X= (2.82 x 100) / 5 = 56,4 %.

V.Y.Kurliadskyi offered the more detailed chart of masticatory efficiency evaluation – **Odontoparadontogram**. Taking into account functional efficiency of masticatory apparatus for determining the diagnosis a doctor must use amendments depending on the state of parodontium. In case of the first degree of parodontium illnesses and teeth mobility the functional value of teeth decreases to 25%; in the second degree of mobility - to 50%, in the third degree - to 100%.

Odontoparadontogram is a table, which collecting the information about every tooth and its supporting apparatus. Information is given as the conditional denotations, got as a result of clinical examination, information of radiographs investigation and gnathodynamometria. N - Without the pathological changes; 0 - a tooth is absent; ¼ (one fourth) - atrophy of the first degree; ½ (a half (one second)) - it is atrophy of the second degree; ¾ (three fourth) - atrophy of the third degree. Atrophy above ¾ belongs to the fourth degree for which a tooth is held by soft tissues and is subject to the extraction.

above	0	0	0	0	0	0	0	0	0	0	0	0	0	0	0	0	0
¾	0,5	0,75	0,75	0,45	0,45	0,4	0,25	0,3	0,3	0,25	0,4	0,45	0,45	0,75	0,75	0,5	
½	1,0	1,5	1,5	0,9	0,9	0,75	0,5	0,6	0,6	0,5	0,75	0,9	0,9	1,5	1,5	1,0	
¼	1,5	2,25	2,25	1,3	1,3	1,1	0,75	0,9	0,9	0,75	1,1	1,3	1,3	2,25	2,25	1,5	
N	2,0	3,0	3,0	1,75	1,75	1,5	1,0	1,2	1,2	1,0	1,5	1,75	1,75	3,0	3,0	2,0	
	1.8	1.7	1.6	1.5	1.4	1.3	1.2	1.1	2.1	2.2	2.3	2.4	2.5	2.6	2.7	2.8	
	4.8	4.7	4.6	4.5	4.4	4.3	4.2	4.1	3.1	3.2	3.3	3.4	3.5	3.6	3.7	3.8	
N	2,0	3,0	3,0	1,75	1,75	1,5	1,0	1,0	1,0	1,0	1,5	1,75	1,75	3,0	3,0	2,0	
¼	1,5	2,25	2,25	1,3	1,3	1,1	0,75	0,75	0,75	0,75	1,1	1,3	1,3	2,25	2,25	1,5	
½	1,0	1,5	1,5	0,9	0,9	0,75	0,5	0,5	0,5	0,5	0,75	0,9	0,9	1,5	1,5	1,0	
¾	0,5	0,75	0,75	0,45	0,45	0,4	0,25	0,25	0,25	0,25	0,4	0,45	0,45	0,75	0,75	0,5	
above	0	0	0	0	0	0	0	0	0	0	0	0	0	0	0	0	

2. Diagnosis Making (Establishing diagnosis)

Initial Definitions:

A diagnosis - is a medical conclusion about the pathological state of the maxillofacial system, written in terms of the classifications and nomenclature of diseases.

Example: Upper jaw dentition defect class 3, subclass 3 by Kennedy, Lower jaw dentition defect class 1 by Kennedy or Toothless upper jaw the 1 type by Schroeder, Toothless lower jaw the 1 type by Keller. The mucous membrane of the denture foundation area class 1 by Supple.

The diagnosis consists of two parts, in which are sequentially indicated:

1. The main disease and its complications.
2. Concomitant diseases and their complications.

The diagnosis of the main disease contains the following components in their sequence:

- **The morphological component** informs about the essence and localization of the main pathoanatomical disorders.

Example: defect of the dentition of the upper jaw 3 class 3 subclasses, defect of the dentition of lower jaw of the 1 class by Kennedy or the edentulous upper jaw of type 1 by Schroeder, the edentulous lower jaw of type 1 by Keller. Mucous membrane of the basal seat area class 1 by Supple.

- **The functional component of the diagnosis** informs about the violation of the basic functions of the dento-alveolar system, as a rule, in quantitative terms. For example, a loss of masticatory efficiency of 60% by Agapov.

- * **The aesthetic component** informs about aesthetic disturbances. For example, a violation of diction, a violation of the aesthetic norms of a smile, a violation of aesthetic standards of the face.

- * **The pathogenetic component** links the previous components of the diagnosis to a medical report, informs about their causes and pathogenesis. For example, due to complications of the carious process that developed over 10 years; as a result of generalized periodontitis, which developed over 5 years.

* - note when writing an extended medical history

The purpose of the task: development and consolidation of research skills necessary for diagnosing patients of the orthopedic dentistry clinic, working with an outpatient card of a dental patient.

Material security:

- phantom of the patient's head, patient;
- models of prosthetic seat area with intact or filling teeth;
- dental unit;
- a large kidney-shaped tray with instruments for examination: a dental mirror, a throat spatula.

Requirements for the doctor:

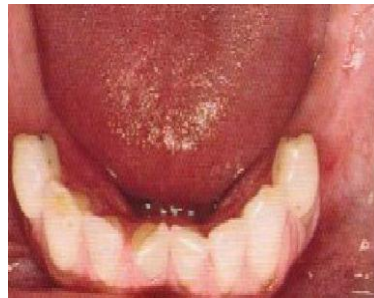
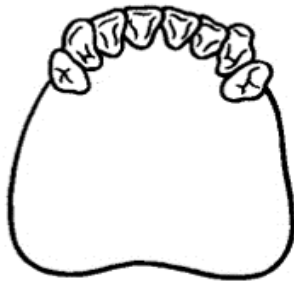- it is necessary to comfortably sit the patient in the dental chair: head at the level of the doctor's elbow;
- wear latex gloves and a mask;
- The doctor is located in front of the patient. When examining the area of the upper or lower jaw, the doctor in the right hand holds the probe, in the left - the dental mirror.

Method of conducting:

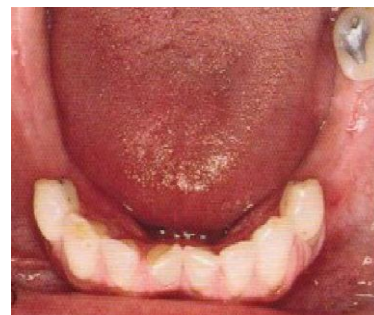
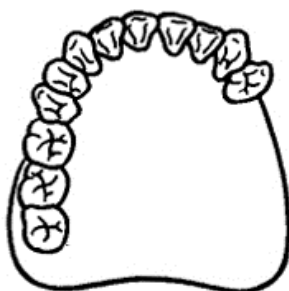For the diagnosis use **the classification of defects of the dentition by Kennedy (1951), with additions by Appligate (1953).**

Need to remember the following:

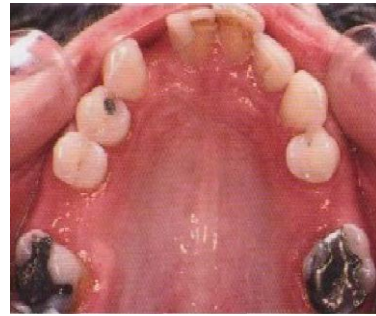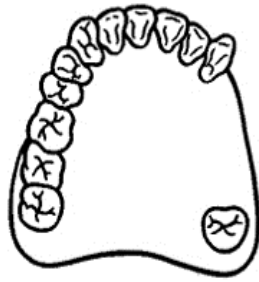- **the first class** includes clinical cases, when defects located in the lateral areas on both sides are limited only medially and are not distal;



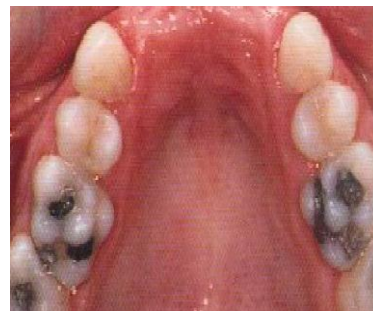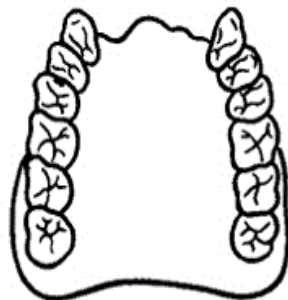- **to the second class** - defects located in the lateral areas from one side are limited only medially and not limited distally;



- **to the third class** - defects located in the lateral areas are limited both medially and distally;



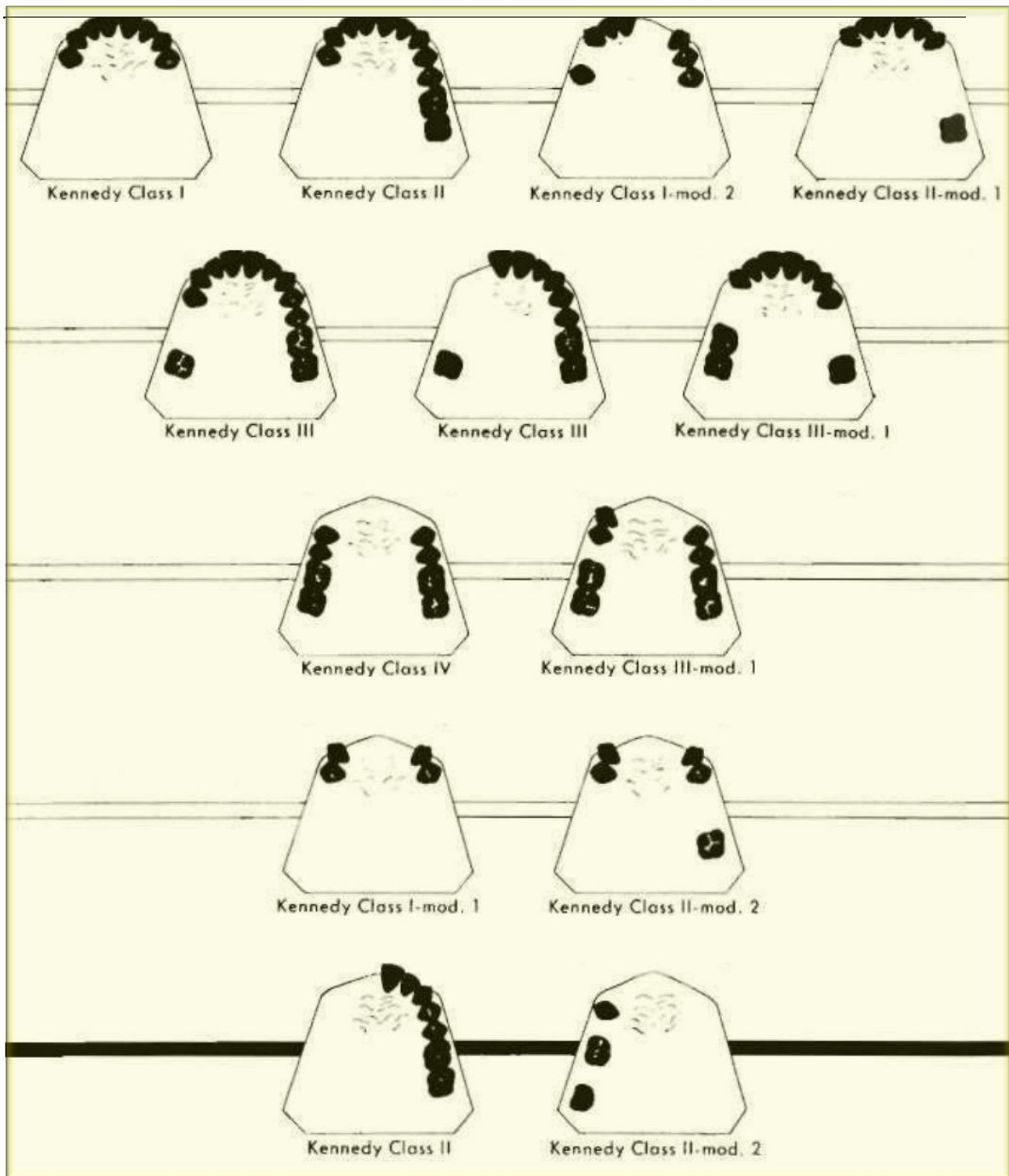
- **to the fourth class** - defects located in the front sections and crossing an imaginary line passing between the central incisors.



Additions by Applegate (1953) have the following meanings:

1. **Defining a defect class** should not outstrip the extraction of teeth, as this can change the established defect class.
2. **If the defect located in the region of the third molar** is not replaced, its presence is not taken into account in the classification.
3. **If the third molar** is used as a supporting tooth, then it is taken into account in the classification.
4. **If the defect is located in the region of the 2nd molar** and is not "replaced", it is not considered in the classification.
5. **The defect class determines** the most distally located.
6. **Additional defects are considered** as subclasses and are determined by their number.
7. **The size of additional defects is not considered**; only their number is considered, which determines the number of the subclass.
8. **There are no subclasses in the fourth grade.** Defects that are located distal to the defect located in the anterior portion of the dentition determine its class.

Prosthodontics



Representative examples of partially edentulous arches classified by the *Kennedy*.

APPLEGATE'S RULES FOR APPLYING THE KENNEDY CLASSIFICATION

(Rules Governing the Application of the Kennedy Method)

Rule 1

Classification should follow rather than precede any extractions of teeth that might alter the original classification.

Rule 2

If a third molar is missing and not to be replaced, it is not considered in the classification.

Rule 3

If a third molar is present and is to be used as an abutment, it is considered in the classification.

Rule 4

If a second molar is missing and is not to be replaced, it is not considered in the classification (e.g. if the opposing second molar is likewise missing and is not to be replaced).

Rule 5

The most posterior edentulous area (or areas) always determines the classification.

Rule 6

Edentulous areas other than those determining the classification are referred to as *modification* and are designed by their number.

Rule 7

The extent of the modification is not considered, only the number of additional edentulous areas.

Rule 8

There can be no modification areas in Class IV arches.

Scheme of diagnosis for defects of dentition

Upper jaw dentition defect _____ class _____ subclass, Lower jaw dentition defect _____ class _____ subclass by Kennedy. Loss of masticatory efficiency _____% by Agapov.

Aesthetic defect of a smile, violation of diction. Due to the complications of the carious process (or periodontal diseases) that developed over _____ years.

Method for determining the loss of masticatory efficiency by Agapov

It should be remembered that the coefficients of masticatory efficiency of teeth by Agapov, starting from the central incisors to the third molars: 2, 1, 3, 4, 4, 6, 5, 0.

In order to determine the loss of masticatory efficiency, it is necessary to combine the coefficients of masticatory efficiency of antagonist teeth located in the place of dentition defects from left to right once, without to plus the coefficients of the antagonist teeth. The resulting sum of coefficients of loss of masticatory efficiency is doubled. For example:

			A										A				
1.8	1.7	1.6	1.5	1.4	1.3	1.2	1.2	2.1	2.2	2.3	2.4	2.5	2.6	2.7	2.8		
4.8	4.7	4.6	4.5	4.4	4.3	4.2	4.1	3.1	3.2	3.3	3.4	3.5	3.6	3.7	3.8		
			A	A						A			A				

$$(4.5 + 4.4 + 3.3 + 3.6) \times 2 = 34\%$$

$$(4 + 4 + 3 + 6) \times 2 = 34\%$$

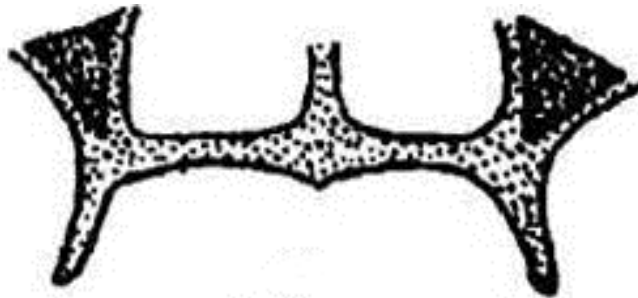
Peculiarities of diagnosing a patient with toothless edentulous jaws

It should be remembered that the extract of all the teeth do not stop the process of atrophy of the alveolar processes of the jaws. Therefore, **the key words** in the narrative of the type of edentulous jaws are the "**degree of atrophy**" and "**the distance from the crests of the alveolar processes to the attachment points**" of the frenulum of lips, tongue, and bands. The places of transition of the flexible mucosa (mucogingival folds, lips, cheeks, floor of the cavity mouth) into the inflexible, covering alveolar processes and the palate.

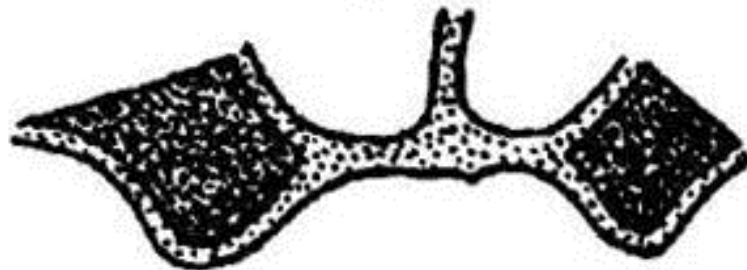Depending on the degree of atrophy of the alveolar processes, the maxillary tubercles, and as a result of this changing distance from the places of attachment of the frenulum, tongue and bands of the mucosa to the crests of the alveolar processes of the maxilla and the height of the arch of the palate.

H.Schreder (1927) classified the upper edentulous jaws into three types:

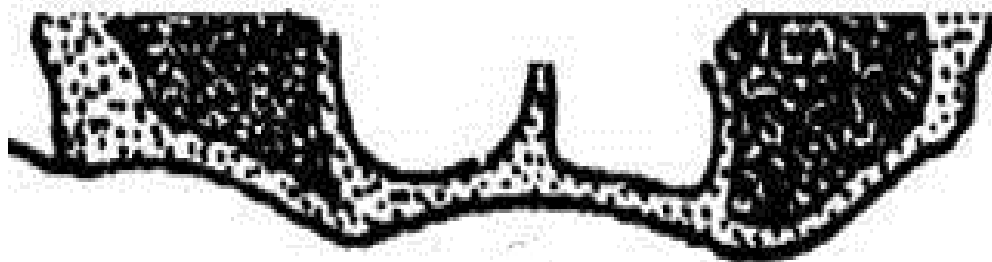
1-й –characterized by a slight atrophy of alveolar processes and tubercles, a high of the arch of the palate. The places of attachment of the frenulum of lips, tongue, bands and mucogingival folds are located at a sufficient distance from the crests of the alveolar processes.



2-й – characterized by an average degree of atrophy of the alveolar processes and tubercles, the arch of the palate is preserved. Frenulum of lips, tongue, bands and mucogingival folds are located near to the crests of the alveolar processes.




3-й – characterized by a significant atrophy of the alveolar processes. The tubercles are atrophied completely. The palate is flat. Frenulum of lips, tongue, bands and mucogingival folds are located on one level with crests of alveolar processes.

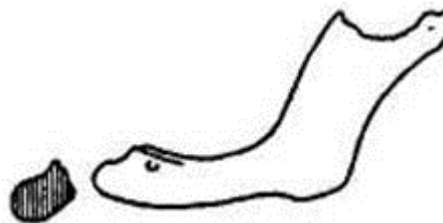


Kehler (1929) classified of the edentulous lower jaw into four types:

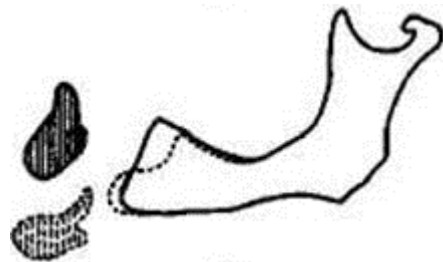
1-й –characterized by a **slight even atrophy** of the alveolar process. The places of attachment of muscles and bands are located at a sufficient distance from the crests of the alveolar processes.



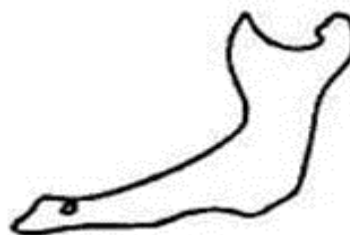
2-й –characterized by a **significant, almost complete, even atrophy** of the alveolar process. The places of attachment of muscles and bands are located almost on the same level as the crest of the alveolar process. The crest of the alveolar process hardly rises above the floor of the cavity mouth, presenting in the anterior part a narrow knife-like formation.



3-й –characterized by a significant atrophy of the alveolar process **in the lateral areas**. And relatively preserved in the front.



4-й –characterized by a **significant atrophy** of the alveolar process **in the anterior region**, with the preservation of the alveolar process in the lateral areas.



The mucous membrane of the prosthetic beds is classified by Supple into 4 classes, depending on the process of atrophy of the alveolar process, the mucosa or a combination of processes.

1 class ("ideal mouth") - alveolar processes and the palate are covered with a uniform layer of flexible mucous membrane, the suppleness of which increases to the posterior third of the palate. The places of attachment of bands and natural folds are located at a sufficient distance from the crests of the alveolar processes.

2 class (hard mouth) - atrophic mucosa covers the alveolar processes and the palate with a thin, as if strained layer. The places of attachment of bands and natural folds are located near to the crests of the alveolar processes.

3 class (soft mouth) - alveolar processes and the palate are covered with loosened mucosa.

4 class (mobility crest) - the excess mucosa is a crest due to the atrophy of the bone of the alveolar process.

Scheme of diagnosis of a patient with edentulous jaws

Edentulous upper jaw _____ type by Schreder, edentulous lower jaw _____ type by Keller. Mucous membrane of prosthetic bed _____ class by Supple. Loss of masticatory efficiency 100% by Agapov.

Violation of diction, norms of aesthetics of the face. Developed due to complications of the carious process (periodontal disease) for _____ years.

1. Planning of orthopedic treatment

Initial definitions: under orthopedic treatment of the patient, it is meant not only to restore the anatomical forms of the crown parts of teeth, dentition, but also to rehabilitate the functions of bite, chewing, swallowing, aesthetic norms of a smile, face and diction.

Purpose of the assignment: mastering and reinforcement of the skills necessary for planning of orthopedic treatment for patients, for work with an outpatient card of a dental patient.

Material security:

- a patient;
- dental unit;
- a large kidney-shaped tray with instruments for examination: a dental mirror, a throat spatula.

Requirements for the doctor:

- it is necessary to conveniently place the patient in the dental chair: head at the level of the doctor's elbow;
- wear latex gloves and a mask;
- the doctor is located in front of the patient, when examining the areas of the upper or lower jaw, the doctor in the right hand holds the probe, in the left - the dental mirror.

Method of conducting

After the diagnosis is made, the next step is planning of the orthopedic treatment. At first, the dentist should analyze the indications and contraindications to orthopedic treatment with non-removable and removable prosthesis designs.

General indications for orthopedic treatment **of defects of the crown parts of teeth** by artificial crowns are a violation of their anatomical shape and color, anomalies of position.

Direct indications for orthopedic treatment by non-removable structures are defects of dentition rows 3 and 4 class by Kennedy small (1-2 teeth) and medium (3-4 teeth) extent in the front.

Defects in the 1st and 2nd class of dentition by Kennedy are direct indications for orthopedic treatment with removable structures.

When orthopedic treatment with non-removable structures it is necessary to take into account the condition of the periodontal tissues of supporting teeth, their stability, the height of the crown parts, the type of occlusion, the presence of traumatic occlusion.

Absolute contraindications to orthopedic treatment by **bridge denture** are large in length defects of dentition, limited by teeth with different functional orientations of periodontal fibers.

Relative contraindications are defects limited by teeth, with pathological mobility of 2 and 3 degree by Entin. Defects limited to teeth with low crown parts, teeth with a small reserve of periodontal forces, i.e. with high crown and short root parts.

Absolute contraindications to orthopedic treatment with removable prosthesis designs are epilepsy, dementia, **relative** - diseases of the oral mucosa: leukoplakia, lupus erythematosus, allergic reactions to acrylic plastics.

The planning treatment plan make dentist after the analysis of indications and contraindications to orthopedic treatment by denture. In this case, it is necessary to answer in a descriptive manner the questions: the chosen prosthesis design, supporting elements and intermediate parts of bridge denture, construction materials, the color of the facieng, the number and material of the teeth, the type and location of the clasps?

Answer the questions of ensuring the patient's anesthetic prepare: premedication, anesthesia operation of preparation of hard tooth tissues.

Answer the questions about the ways of obtaining impressions: what kind of impression material, the assignment of the impressions, the methods of obtaining them, the quantity.

In conclusion, the treatment plan should be agreed with the patient, warned of possible complications, and obtained his consent to implement the plan.

An example of a plan for orthopedic treatment with a non-removable bridge-like denture facing with ceramic.

The patient is shown the treatment of non-removable one-piece cast bridges with supporting elements in the form of complete crowns for 1.5, 1.3, 2.4, 2.6, 3.4, 3.7, facing with a ceramic mass. Color of facing A3. Preparation of hard tissues of supporting teeth under support elements under intraligamentary anesthesia Sol.Septanesti 4% - 1.2 ml. Obtaining two full anatomical working double-layered impressions of "Sielast K". Protection of the stumps of teeth with temporary crowns.

Total. Fixed one-piece-cast bridges - 3
One-piece-cast crowns - 6
Pontic (intermediate parts with cast teeth) - 4
Intraligamentary anesthesia - 6
Sol.Septanesti 4% - 1.8 ml - 1 pc.
Two-layer impressions with "Sielast K" - 2
Consultation - 1

An example of a plan of orthopedic treatment with fixed stamped-soldered bridges.

The patient is recommended to use non-removable stamped-soldered design denture with supporting elements in the form of full metal stamped crowns on 1.5, 1.3, 2.3, 2.5, 4.4, 4.6 and combined pontic, plastic facing "Sinma", color No. 16.

Preparation of hard tissues of supporting teeth under supporting elements with intraligamentary anesthesia Sol. Septanesti 4% - 1.8 ml. Obtaining two full anatomical masters double-layer prints "Stomaflex solid" + "Stomaflex cream".

Total. Non-removable stamped-soldered bridges - 3
Metal stamped crowns - 6
Facets (combined pontic) - 3
Intraligamentary anesthesia - 6
Sol. Septanesti 4% - 1.8 ml - 1 pc.
Two-layer impressions - "Stomaflex Solid + Cream" material - 2
Consultation - 1

An example of a plan of orthopedic treatment with a partial removable lamellar denture on the upper jaw.

The patient is recommended: on the upper jaw - a partial removable lamellar denture with 6 teeth made of composite, color A 3. The basis of the plastic "Ftorax" with two retentive wire loop-like clasps on 1.4 and 2.4. Obtaining two complete anatomical masters and auxiliary impressions of "Stomalgin-04"

Total:

Partial removable lamellar denture on the upper jaw - 1

Composite teeth - 6

Retentive bent wire loop-type clasps - 2

Full anatomical impressions of "Stomalgin-04" - 2

Consultation - 1

An example of a plan for orthopedic treatment with clasp prosthesis on the upper jaw

The patient is recommended:

- full one-piece-cast crowns on 4.3 and 3.3, facing with ceramic color A 3.5 with two attachments MK-1;

- on the lower jaw: clasp denture with 8 teeth made of composite, color A 3.5, with two attachments MK-1;

- preparation of hard tissues of supporting teeth under intra-segmental anesthesia Sol. Ubestesini 3% - 1.8 ml. Obtaining two full anatomical two-layer master and auxiliary impressions "Stomaflex". Protection of the stumps of teeth with temporary crowns.

Obtaining two full anatomical two-layer master and auxiliary impressions with Spidex.

Total:

One-piece-cast metal crowns,

facing with ceramics - 2

Attachments MK-1 - 4

Clasp prosthesis on the lower jaw - 1

Teeth - 8

Full anatomical two-layer impressions "Stomaflex" - 2, "Spidex" - 2

Occlusal impressions "Stomaflex" - 4

Consultation - 1

An example of a plan of orthopedic treatment with complete removable lamellar denture

Recommended:

- On the upper jaw - a complete removable lamellar denture with 14 porcelain teeth;
- On the lower jaw - a complete removable lamellar denture with 14 teeth made of composite. Color C3. Bases from "Etakrila-02".

Obtaining two complete anatomical masters impressions with "Stomalgin-04". Manufacture the individual impression trays from Carboplast. Obtaining two functionally-sucked impressions of "Stomaflex paste" or "Stomaflex cream".

Total:

Complete removable lamellar denture - 2

Porcelain teeth - 14

Composite teeth - 14

Complete anatomical impressions of "Stomalgin-04" - 2

Individual trays from "Carboplast" - 2

Functional prints "Stomaflex cream" - 1

Functional impressions "Stomaflex" paste - 1

Consultation - 1

The next stage after planning treatment and obtaining the patient's compliance to its implementation is the process of orthopedic treatment: anesthesia, preparation of hard tissues of teeth, obtaining impressions etc.

4. Selective grending of teeth, alignment of the occlusal surface, occlusiogram.

Material security

- drill, straight and angled handpiece;
- Abrasive tools: carborundum and diamond heads are spherical, conical, umbrella-like forms of fine and medium grain; waterproof abrasive paper discs, hard and soft rubber polishes;
- remineralizing pastes, fluorine lacquer, polishing brushes;
- two-sided articulation paper in the form of strips and patterns in the shape of the dentition;
- plates of basic and clasp waxes, millimeter paper, dry fuel, matches;
- a phantom patient, models of prosthetic beds with intact dentition and dentition defects, plastered into articulators.

The purpose of the task: to determine and eliminate and prevent the occurrence of traumatic occlusion in patients: direct and indirect traumatic nodes.

Indication: periodontal disease, temporomandibular joints; at the stage of application overlapping and delivery of partial and complete removable lamellar dentures and during the adaptation of patients to them; violations of occlusal relationship of teeth after orthopedic treatment with one-piece-cast non-removable dentures facing with porcelain, plastic, composite or non-removable dentures from plastic, some types of pathological bites, method of fixing the results of orthodontic treatment.

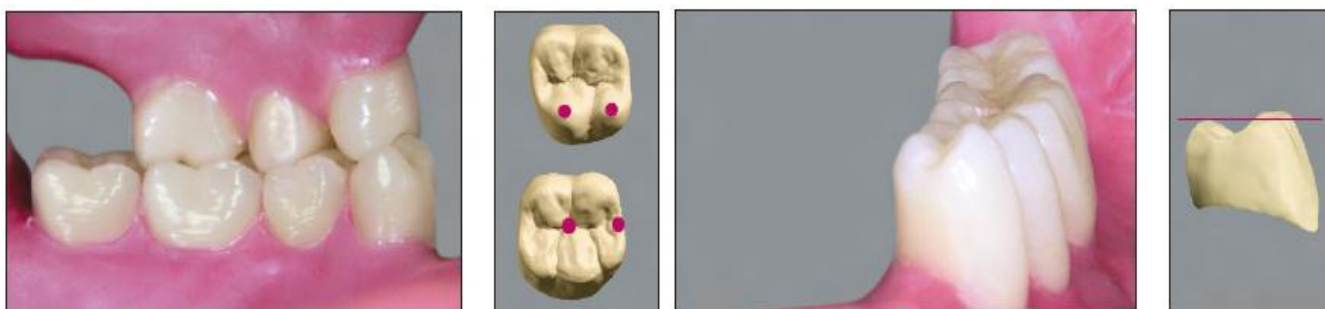
Requirements for the doctor:

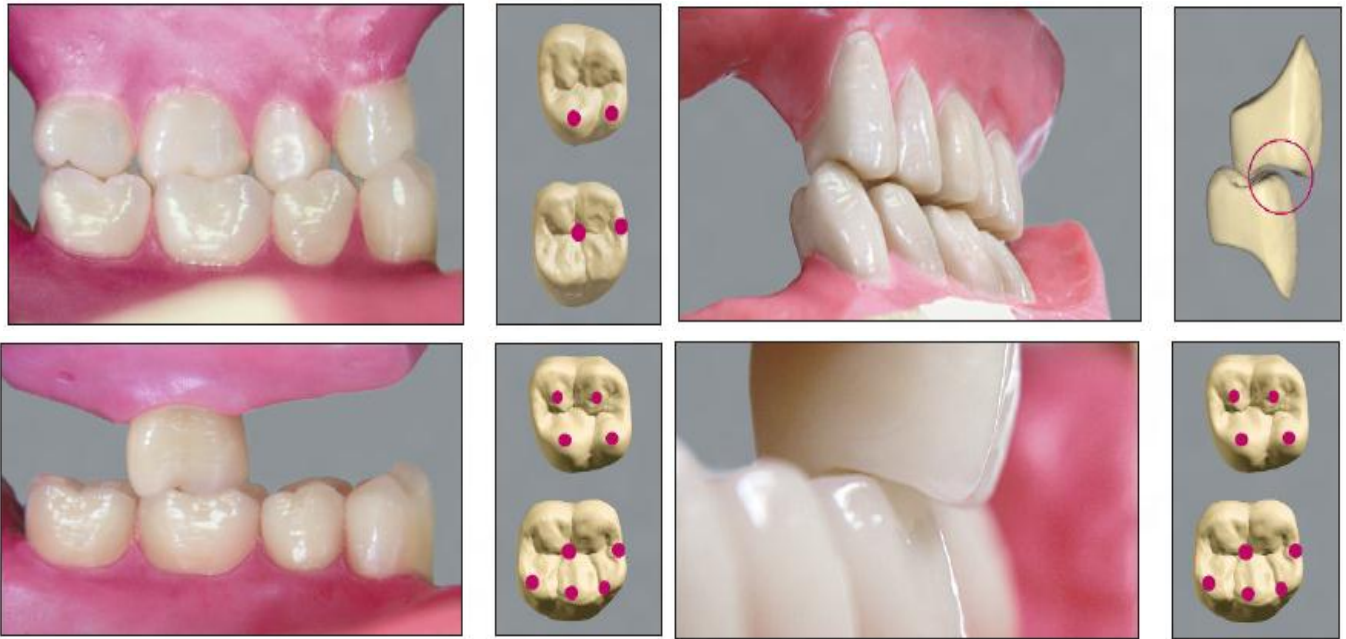
- it is convenient to place the patient in the dental chair: the patient's head is located at the level of the doctor's elbow;
- wear latex gloves and a mask;
- the doctor is located in front of the patient, the thumb of his right hand is fixed on the patient's upper lip when preparing the teeth of the upper jaw or on the chin - when manipulating the teeth of the lower jaw in the same hand, the doctor holds the handpiece, in the left hand - the dental mirror protected by the tongue, cheek, gums from injury with an abrasive tool.

Method of conducting:

detection of points of supracontacts using a base wax plate

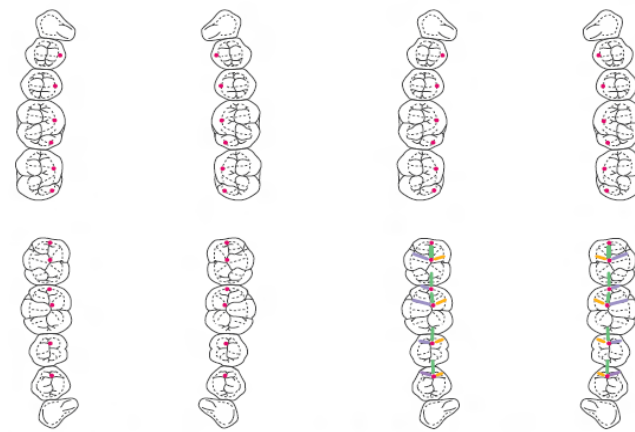
- put a plate of clasp wax between the patient's dentition and propose him to close the dentition;
- control the position of the patient's dentition in the central occlusion;
- propose the patient to open the dentition, remove the plate from the mouth;
- analyze the places of supracontacts on the occlusal surfaces of teeth according to the degree of extrusion of the wax plate and mark them with a marker on the gypsum model.





Detection of supracontacts using paper with millimetric dividing

- fold paper with millimeter divisions in half, dividing outside;
- the paper is placed between two strips of articulatory paper and the insert thus created is positioned between the patient's dentitions;
- propose the patient to close the dentition by controlling the position of the dentition in the central occlusion;
- remove the insert from the oral cavity, analyze the location and areas of the supracontacts of the teeth;
- check the serviceability of the handpiece;
- fix the handpiece of the abrasive tool;
- check the quality of fixation and alignment of the abrasive tool;
- ask the patient to rinse the oral cavity;
- place the articulation paper between the dentitions and ask the patient to close the dentition, sliding the lower incisors along the palatal surface of the upper incisors;



- then move the lower jaw, without opening the teeth, alternately to the right, and then to the left;
- the areas of the supracontacts of the teeth will be intensively colored with articulatory paper;
- to grind them, use shaped heads for the angular turbine handpiece with a diamond grinding medium grain: spherical, conical and umbrella-shaped;
- to smooth and polish the prepared surfaces of the crown parts of the teeth, use abrasive tools in a certain sequence: carborundum fine-grained shaped heads paper, waterproof abrasive discs, hard, and then soft rubber polishes;
- finish the manipulation of the processing of the prepared surfaces with remineralizing pastes.

5. Ligature binding of teeth

The purpose of manipulation: immobilization of jaw fractures with in full fractures and fractures without displacement, dislocation of teeth.

Material security:

- phantom of the patient's head;
- models of prosthetic beds, plastered in the occludator, articulator;
- metal scissors;
- crampon forceps;
- bronze-aluminum alloy wire (length 12-15 cm, diameter 0.5 mm);
- Mikulich's clamp or needle holder;
- Farabefe's hook;
- a large kidney-shaped tray with inspection instruments;
- a glass with water;
- aseptic tablets;
- latex gloves, mask.

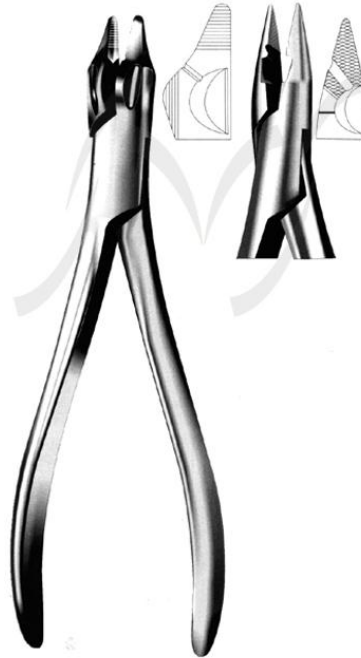
Requirements for the doctor:

- place the patient in the dental chair so that it is convenient: the patient's head should be at the level of the doctor's elbow;
- introduce the patient with the upcoming manipulations; know the technique of ligature binding of teeth.

The instruments should be sterile, the doctor should wear latex gloves, on the face - a mask. To perform auxiliary decontamination it is necessary to use appropriate solutions, for example, "Sterilium".

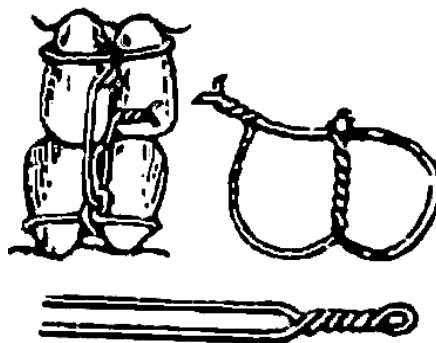
AIVY Binding Scheme:

- The ligature wire is bent in the form of a hairpin, leaving one end longer by 1-1.5 cm;
- With the help of the prosthetic pliers at the end of a hairpin form a loop with a diameter of 2-3 mm;



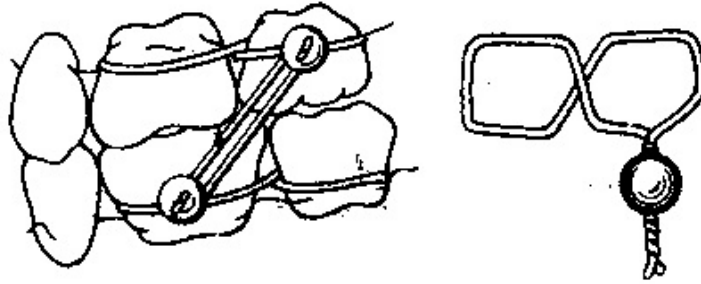
Universal Pliers for Orthodontic & Prosthetic, 150 mm

- Both ends of the wire are carried from the vestibular to the oral side between the teeth included in the binding;
- The long end of the ligature is returned to the vestibular surface through the interdental space located behind the loop and passed through it and the loop;
- The short end is removed to the vestibular surface through the interdental space located in front of the loop and twisted with the long end of the ligature;
- Made a similar binding of teeth - antagonists;
- The fragments are fixed to the teeth of the upper jaw by a separate wire, passed through the loops of the ligature bandage on each side.



HEIKIN Binding Scheme


- The end of the ligature is covered by two nearby teeth from the vestibular and oral side in the “form of an eight”;
- The ends of the ligature, deduced vestibularly, twist in two turns and are divorced;
- put on the ends an aluminum or plastic button with a diameter of 3-4 mm and fix it by twisting or bending the ends;



- Excess ligature ends are cut;
- Made a similar binding of teeth - antagonists;
- Between the buttons put rubber traction.

VILHA Binding Scheme

- The end of the ligature is covered by two nearby teeth from the vestibular and oral side in the form of a figure eight;
- Put on the ends of a leaded pellet twisted from the vestibular side and fix it with a ligature;



- The ligation remains are cut off;
- Conduct a similar binding of teeth - antagonists;
- Overlapping a rubber traction

6. Preparation of hard tooth tissues under a full metal stamped crown

The purpose of manipulation: the creation of the stump of the tooth by preparation for orthopedic treatment with a full metal stamped crown.

Material security:

- straight mechanical handpiece;
- a micromotor or a dental unit with a mechanical drive;
- a set of disks and carborundum heads, articulation paper;
- models of prosthetic beds with intact or filling teeth;
- dental unit;
- a large kidney-shaped tray with instruments for examination: a dental mirror, a throat spatula;
- a glass with a water;
- aseptic tablets;
- latex gloves, mask.

Requirements for the doctor:






- comfortably sit the patient in the chair: the height of the chair, the position of the patient's head, lighting;
- to familiarize the patient with the subsequent operations.

The instrument should be sterile, the doctor's hands - in gloves, on the face - a mask. For auxiliary sterilization it is necessary to use a suitable solution, for example, "Sterilium".

Method of conducting

- anesthetize surgical intervention, carry out if necessary premedication;
- include a saliva ejector and water cooling;
- separate contact surfaces and preparation them;
- preparation the layer of the occlusal surface of hard tissues by 0.3 mm and check it with a probe made of strips of paper under the control of a caliper;
- preparation the oral and vestibular surfaces, carefully smoothing the angles of the transition to approximal surfaces;
- check the correctness of stump formation;
- protect the prepared surface of the tooth stump: it is processed with "Helak", etching gel, washed off with water, applied with an adhesive and lighted with a photopolymer lamp.

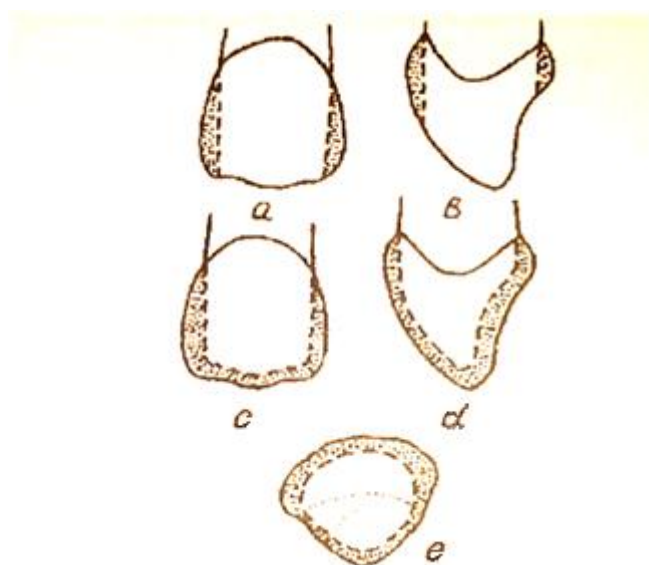
6.1. Priority of application of diamond abrasives of different granularity, designations, properties, abbreviation.

Priority preparation	Ring color	Properties	Value	Abbreviation
1	Black 	Ultra-rough	181 μm	SG
2	Green 	Rude	151 μm	G
3	Colorless	Standard	107-126 μm	S
4	Red 	Thin	40 μm	F
5	Yellow 	Ultra thin	20 μm	C
6	White 	More ultra-thin	15 μm	Uf

6.2. Recommended speed of rotation of abrasive heads in revolutions per minute:

Instrument head diameters in millimeters	The maximum, rpm.	Working turnover per minute.
007 – 010	450.000	100.000 – 220.000
012 – 014	450.000	70.000 – 220.000
016 – 018	450.000	55.000 – 160.000
021 – 023	300.000	40.000 – 120.000
025 – 027	160.000	35.000 – 110.000
029 – 031	140.000	30.000 – 95.000
033 – 040	120.000	25.000 – 75.000
042 – 050	95.000	15.000 – 60.000
055 – 070	60.000	12.000 – 40.000
080 – 100	45.000	10.000 – 20.000
Maximum working granularity F C and UF		
F	40.000	10.000 – 20.000
C – Ultra thin	30.000	8.000 – 15.000
UF	20.000	5.000 – 10.000

For specially marked abrasives		
1	300.000	70.000 – 90.000
2	160.000	40.000 – 85.000
3	140.000	30.000 – 60.000
4	100.000	25.000 – 50.000
5	90.000	20.000 – 40.000



A layer of hard tissues that must be grinding in during preparation to a full metal stamped crown:

- a - Contact surfaces;
- b - Labial and palatal surfaces;
- c - Contact surfaces and a cutting edge;
- d - Labial, palatal surface and cutting edge;
- e - from all vertical walls of the tooth.

7. Preparation of hard tooth tissues under the plastic crown

The purpose of the manipulation: the creation of a stump of the crown part of the tooth, formed under the crown of plastic.

Material security:

- straight mechanical handpiece;
- a micromotor or a dental unit with a mechanical drive;
- a set of disks and carborundum heads, articulation paper;
- models of prosthetic bads with intact or filling teeth;
- dental unit;
- a large kidney-shaped tray with instruments for examination: a dental mirror, a throat spatula;
- a glass with water;
- aseptic tablets;
- latex gloves, mask.

Requirements for the doctor:

- comfortably sit the patient in the dental chair: the criteria - the height of the chair, the position of the patient's head, lighting;
- to familiarize the patient with the subsequent manipulations.
- the instrument should be sterile, the doctor's hands should be in gloves, on the face - a mask; for auxiliary sterilization it is necessary to use a solution of "Sterilium".

Method of conducting

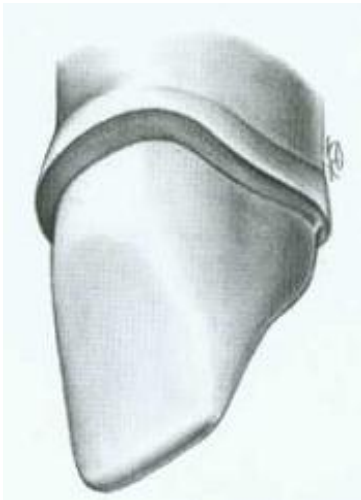- Anesthetize surgical intervention, produce if necessary premedication;
 - include a saliva ejector and water cooling;
- Separate the contact surfaces and preparation them in such a way as to obtain a shape of cone of stump: a slope of not more than 3-5 degrees;
- preparation the cutting surface by 0.8-1.2 mm and check it with a probe made of strips of paper and a caliper;
 - preparation the oral and vestibular surfaces, carefully smoothing the angles of their transition to approximal surfaces;
 - check the general correctness of formation of the stump visually and with the help of a mirror and a probe from all sides;
 - Protect the prepared surface of the tooth stump: for example, treat it with an etching gel, wash it off with water, dry it, apply a Helak solution, wash it off with water, dry it, apply an adhesive and light it with a photopolymer lamp.

When preparing cavities, it is necessary to take into account the topography of the tooth cavity. The shape of the tooth cavity repeats the shape of the tooth crown in a reduced scale, approximately 1: 4. Then older patient, the less the shape of the tooth cavity relative to the external shape of his crown - due to the deposition of the secondary dentin. The thickness of the walls increases more from the vestibular and oral sides than from the contact ones. The causes - is the uneven deposition of the secondary dentin. To prevent the opening of the cavity of the tooth, it is necessary to know its anatomy well.

To do this, **the tooth safety zones** are also identified - the boundaries of the surface of the tooth crowns, within which it is possible to excise hard tissues without the risk of opening the cavity of the tooth and injuring the pulp (Boisson, NG Abolmasov, EI Gavrilov, BS Klyuev). Below are the minimum and maximum distances of the safety zones, depending on the height of the clinical crown of the tooth (low or high).

ANTERIOR GROUP OF TEETH

Incisors



On average, the height of the chamber of the tooth cavity reaches the middle of the clinical crown of the tooth and is located near at the level of the palatine tubercle. Thickness of hard tooth tissues:

- **in the cutting edge area:**

upper jaw - central incisors - 3,0 - 6,0 mm;

lateral incisors - 2,5 - 5,2 mm;

lower jaw - central and lateral incisors - 2,2 - 5,0 mm;

- **in the region of the equator (oral, vestibular surfaces):**

upper jaw - 1,5 - 4,0 mm;

lower jaw - 1,2 - 3,2 mm;

- **in the neck area (oral, vestibular surfaces):**

upper jaw - 1,5 - 3,4 mm;

lower jaw - 1,2 - 3,2 mm.

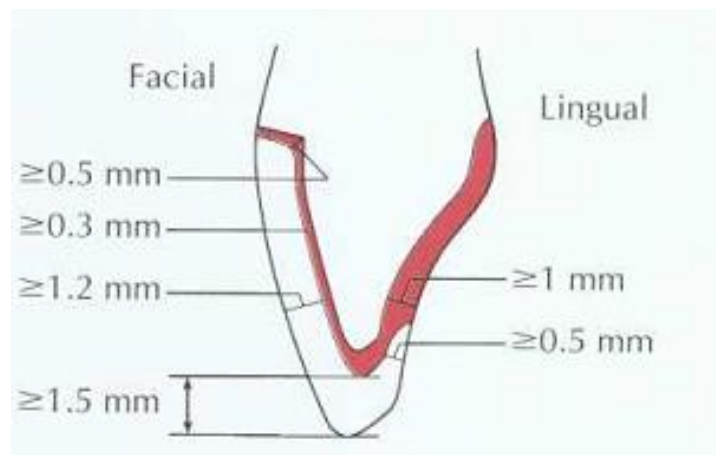


Fig. Recommended minimum dimensions for a plastic (metal-ceramic) restoration on an anterior tooth.

Canines

The tooth cavity is located near of the cutting edge than the incisors, near to the oral and farther from the vestibular surface of the crown, approximately in the middle of the clinical crown of the tooth at the level of the palatal tubercle.

Thickness of hard tissues of tooth relative in the area:

- **in the area of a cutting cusp:**

upper jaw - 2,8 - 5,1 mm;

lower jaw - 2,8 - 5,0 mm;

- **at the level of the equator:**

from the vestibular side on the upper jaw - 2,6 - 3,8 mm;

on the lower jaw - 2,0 - 3,0 mm;

from the oral side on the upper jaw - 1,6 - 4,4 mm;

on the lower jaw - 2,3 - 3,0 mm;

from contact surfaces on the upper jaw - 2,3 - 3,9 mm;

on the lower jaw - 2,6 - 3,0 mm;

- **at the neck:**

from the vestibular side on the upper jaw - 2,6 - 3,8 mm;

on the lower jaw - 2,3 - 3,0 mm;

from the oral side on the upper jaw - 2,5 - 3,8 mm;

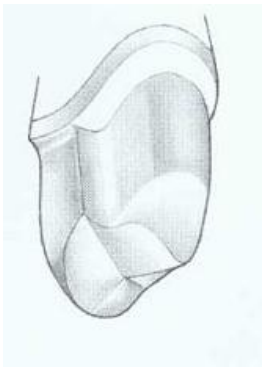
on the lower jaw - 1,9 - 2,9 mm;

upper canines from distal surface - 1.9 - 3.0 mm.

With age, an increase in the thickness of the walls occurs at the cutting edge, less - on the lingual side, at the level of the equator and neck. The thickness of other walls increases insignificantly.

LATERAL GROUP OF TEETH

Premolars



The cavity of the tooth resembles the external contours of the crown, the vestibular part of the tooth cavity is higher than the oral cavity, the chamber of the cavity is often located at the level of the clinical neck of the tooth. The value of hard tooth tissues:

- **at the level of the masticatory surface:**

on the upper jaw - 3,6 - 5,0 mm;

on the lower jaw - 3,8 - 4,6 mm;

- **at the level of the equator of the teeth:**

on the upper jaw - 2,0 - 4,0 mm;

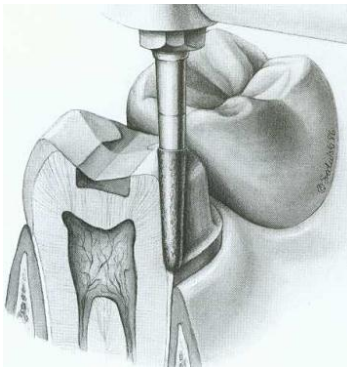
on the lower jaw - 1,7 - 2,5 mm;

- **in the neck area:**

on the upper jaw - from the vestibular, oral surfaces - 2.5 - 4.3 mm;

on the lower jaw - from the vestibular, oral, distal surfaces - 1,8 - 2,5 mm.

Molars



The cavity of the tooth at the molars is quite large. Its shape, as a rule, repeats the shape of the chewing surface of the tooth. The chamber of the tooth cavity is approximately at the level of the clinical neck of the tooth. The value of hard tissues:

• **in the area of the chewing surface of molars is:**

on the upper jaw - 3,2 - 5,2 mm;

on the lower jaw - 3,0 - 5,0 mm;

• **in the area of the equator of the teeth, the thickness can vary within the limits of:**

on the upper jaw - 2,4 - 3,3 mm;

on the lower jaw - 2,4 - 3,7 mm;

• **in the neck area, the value of hard tissues:**

on the upper jaw - from the vestibular, oral, distal surfaces - 2.5 - 3.1 mm;

on the lower jaw - from the vestibular, oral, distal surfaces - 2,4 - 3,0 mm.

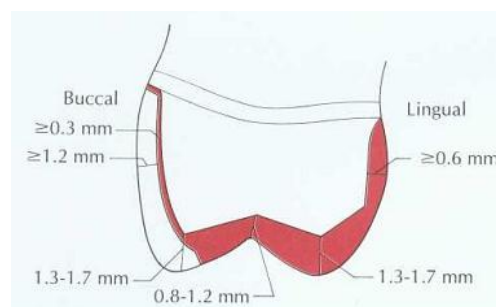


Fig. Recommended minimum dimensions for a plastic (metal-ceramic) restoration on a posterior tooth. Note the significant reduction needed compared to that for a complete cast or partial veneer crown.

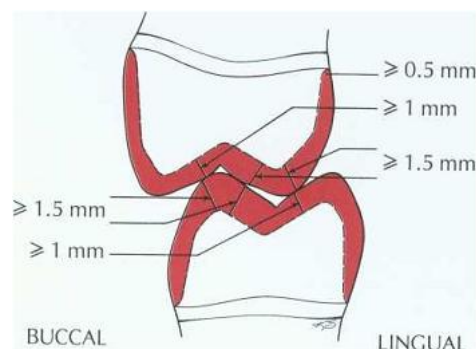


Fig. Recommended dimensions for a complete cast crown. On functional cusps (buccal mandibular and lingual maxillary) the occlusal clearance should be equal to or greater than 1.5 mm. On nonfunctional cusps, a clearance of at least 1 mm is needed. The chamfer should allow for approximately 0.5 mm of metal thickness at the margin.

8. Impression Taking Procedures

Procedure's purpose: A negative imprint (a dental impression) taking from basal seat area for a follow-up gypsum model fabricating.

Material Security:

- Patient;
- Dental Treatment Unit;
- Mask;
- Powdered Latex Gloves;
- Impression Tray;
- Impression Material;
- Flexible Rubber Mixing Bowl;
- Mixing Spatula.

Requirements for a Dentist:

- Dentist and Patient Correct Position selection (Dentist should stand & patient should sit upright. Occlusal plane should be parallel to the floor. MAXILLARY IMPRESSION - dentist should stand at the right rear of the patient. MANDIBULAR IMPRESSION - dentist should stand at the right front of the patient.)
- Check the accuracy of the dental handpiece;
- Fix the abrasive tool;
- Check the quality of fixation and centering of the abrasive tool;
- **Patient Preparation.** The doctor is located in front of the patient; in the study of the area of the upper or lower jaw teeth he holds a probe in his right hand, a dental mirror in his left (the right-handed position). Dental mirror protects tongue, cheek and gum from injury of the soft tissues by an abrasive tool. The hands of the dentist should be in gloves, on the face - a mask.

Patient Preparation Seat patients in an upright position and attach a large patient napkin to prevent spillage of material on clothing. A brief oral examination is necessary prior to taking an alginate impression. The purpose of this exam is to inspect the oral cavity for debris, which should be removed prior to taking the impression. At this time, the operator should examine the palatal region for size, height and possible maxillary or mandibular tori. This will alert the operator to adjust the amount of alginate required for full anatomical coverage, i.e. if the palate is shallow, the operator should remove excess alginate material to avoid gagging the patient. Conversely, patients presenting with a high palate will require additional alginate material in this area to prevent voids. Also at this point, it is imperative that the patient takes out any removable dental appliances, oral

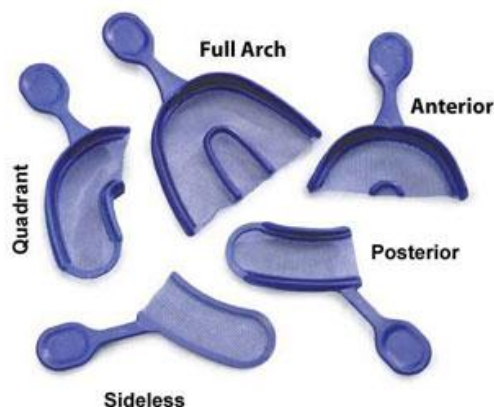
piercings or grills. The operator should observe the lip area for dryness and chapping to see if it is necessary to lubricate the lips with petroleum jelly for the patient's comfort. Ask the patient to rinse with mouthwash to reduce the number of microorganisms in the oral cavity, as well as minimize air bubbles that can be produced by saliva. Paper towels or tissues and an emesis basin are placed within the operator's reach in the event of a gagging episode and subsequent vomiting accident. Explain the procedure to the patient. The operator may ask, "Have you ever had impressions taken before?" Observe the patient's verbal and nonverbal response. Negative responses may indicate a bad prior experience or exposure to preconditioning. Reassuring the patient at this time is crucial. The operator should display a confident attitude. Convey positive information to assure a successful outcome. Basic instructions can be given at this time, such as telling the patients that the pudding-like material will feel cool, that it will set soon and that deep breathing through the nose will make the procedure more comfortable. Not overloading the posterior areas of the tray and removing the impression from the oral cavity as soon as it is set also helps relieve the gag reflex.

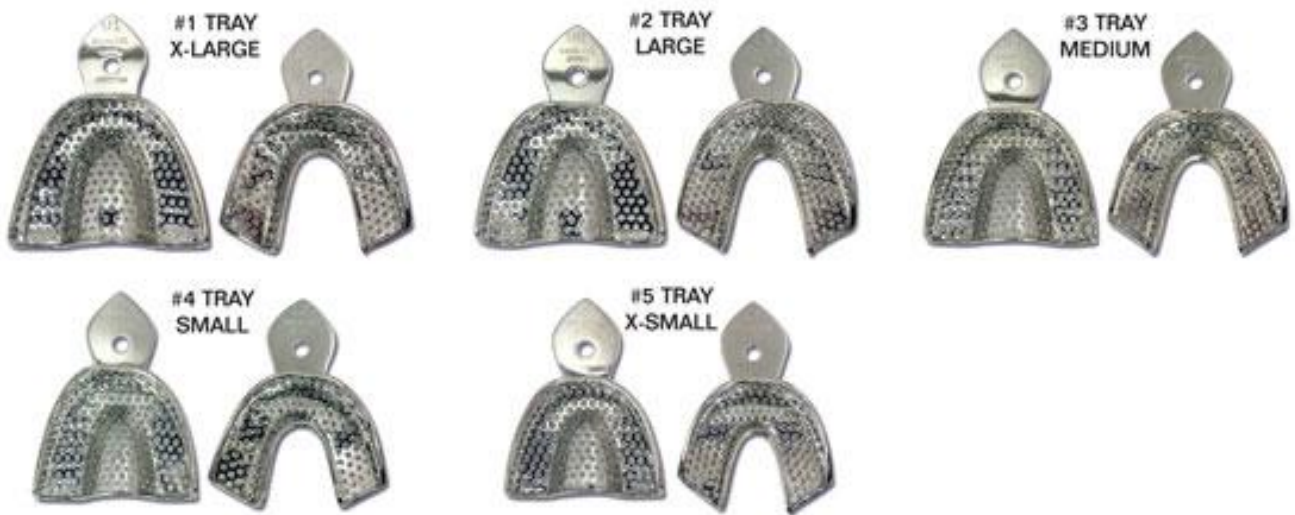Clinical Procedure

1. Tray Selection

Criteria for tray selection includes:

- Trays should extend distally to cover the maxillary tuberosity and cover the mandibular retromolar pad for maximum anatomical reproduction.
- Tray height should fully cover the length of anterior and posterior teeth.
- Tray should extend beyond the facial aspect of the teeth with a few millimeters of space between the tray and soft tissue.
- The tray size should be comfortable for the patient and allow for any tori that are present





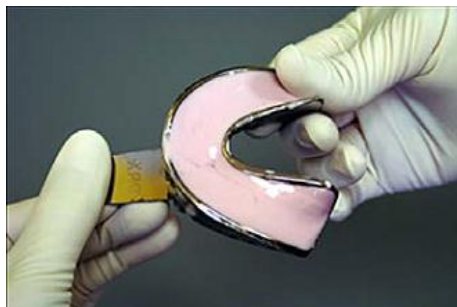2. Adhesives

When using plastic trays, it is recommended that an alginate adhesive be used. Alginate adhesives are supplied in brush-on or spray-on form. It is recommended that the adhesive be placed inside the tray 5-10 minutes prior to the insertion of the mixed alginate material. The purpose of the adhesive is twofold:

- The adhesive holds the impression material to the tray so that the tray and alginate come out of the patient's mouth as one unit.
- To prevent distortion of the impression by securing the alginate tightly against the side of the tray.

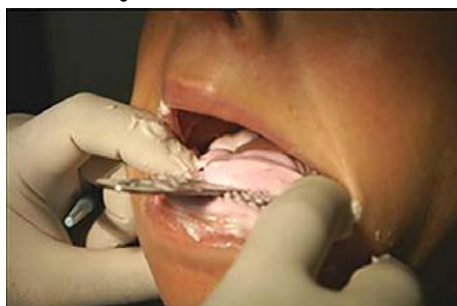3. Impression Material Preparation (Mixing Techniques)

4. Take of the mixed impression material and quickly load it into the impression tray. Create the impression material surface.



Smoothed Alginate impression.

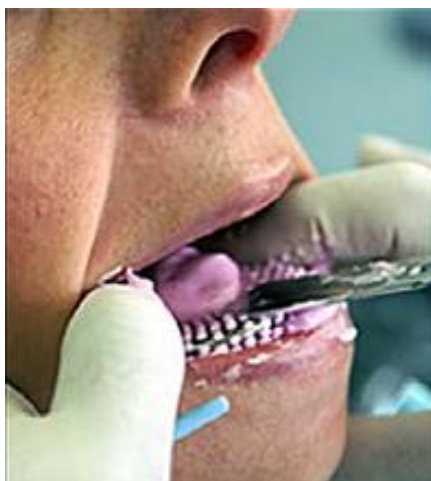5. The tray seating in the oral cavity.



Seating mandibular tray

The following guidelines should be followed for seating a mandibular tray in the oral cavity:

- Have the patient seated in an upright position.
- The operator should be positioned in front of the patient for proper seating of the impression.
- Instruct the patient to open his or her mouth.
- Opening too widely eliminates the elasticity of the cheek, which is necessary for properly seating the impression.
- Retract the cheek with an index finger to provide visibility for placement of the tray.
- Insert the tray from the side and then center it over the arch (Figure 7). The midpoint of the impression tray handle should be perfectly aligned with the patient's midline while the tray handle maintains a parallel position to the floor.
- Press down on the posterior portion of the tray first and continue to the anterior in one smooth motion.
- Roll the lower lip up over the anterior portion of the mandibular tray for finer anatomical detail.
- Instruct the patient to elevate his tongue and then relax it. This technique enhances a more detailed duplication of the lingual aspect.
- Firmly hold the tray with equal bilateral pressure in the patient's mouth while waiting for the final set of the impression material. The firm, equal pressure on both sides of the mouth will prevent distortion

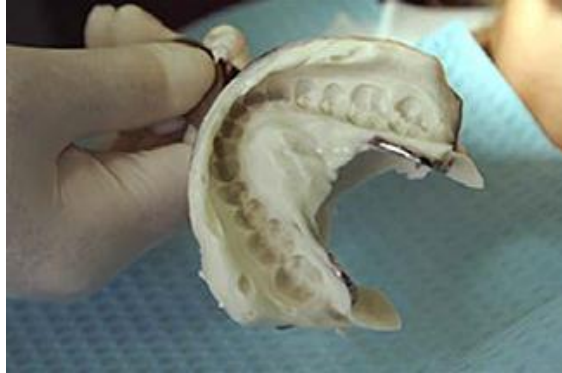

Holding tray in place

- Prior to the removal of the tray, the operator must check to see if the material has set. The operator can easily test for the final set by simply pressing the alginate in the mixing bowl or in the patient's mouth with the operator's finger to observe that no deformation or dent occurs in the material.

6. Removal of Mandibular Impression and Inspection of Impression

The alginate impression should be inspected immediately upon its removal from the oral cavity



Inspecting the impression.

The purpose of inspection is to observe:

- a smooth homogeneous set (a grainy appearance will show if spatulation was inadequate).
- that the impression did not separate from the impression tray
- coverage of the total dentition and its accompanying freni and vestibular anatomy.
- presence of voids and air bubbles.
- no evidence of tray visibility in the incisal and occlusal surfaces.
- sharp anatomical detail.
- presence of blood, saliva and debris

7. Disinfection and Storage

All impressions must be disinfected before being removed from the treatment area.

The following steps should be taken to disinfection the impression:

- Immediately after inspection is completed, rinse the impression for thirty seconds under slow running, room temperature tap water to minimize aerosolization and splatter. Check to see that all blood, saliva, and debris has been removed.
- Spray disinfectant completely covering all areas of the impression and tray; or use the immersion method according to the manufacturer's recommendations.
- After disinfection, rinse the impression under room temperature tap water for thirty seconds.
- Place disinfected impression, wrapped in a moistened paper towel in a plastic bag for storage until poured. (Bags can be purchased commercially or headrest covers may be used.)
- Ideally, the impression should be poured in gypsum within 30 minutes to prevent dimensional distortion. Impressions may be poured in-house or picked up by a commercial dental laboratory. It is inadvisable to mail study model impressions to a laboratory. The time elapsed between the actual impression taking and subsequent pouring of the impression will result in dimensional distortion.

- Patient identification should be made by labeling the bag with the patient's name with a waterproof marker.
- A laboratory prescription should be completed with a waterproof pen and stapled to the storage bag.

Spray silicone impressions with a silicone wetting agent before pouring.

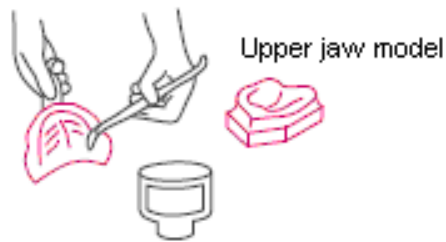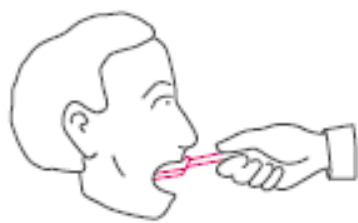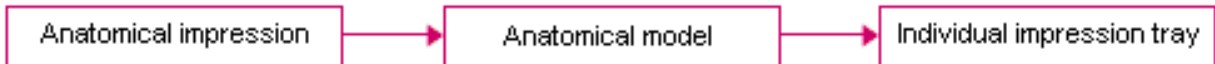Polyether impressions (Impregum™, Permadyne™) should be rinsed briefly under running water (plaster clings firmly to dry polyether producing a rough stone surface).

Alginate impressions should be immersed in a potash alum solution for 5-10 minutes in order to prevent the syneresis phenomena. ("syneresis" – the loss of water that creates distortion through shrinkage).

Laboratory Preparation of the Impression. To prepare the alginate impression for pouring the following must be done immediately before pouring to reduce shrinking of alginate material:

- Remove moist paper towels from alginate impression.
- Remove moist cotton rolls from occlusal and incisal areas.
- Gently shake the impression over the lab sink in order to remove excess moisture.
- Spray the impression with a commercially manufactured debubbler. This serves to reduce the surface tension, thereby enhancing the flow of the plaster and reducing the number of air bubbles on the cast's surface.
- Gently air-dry the impression.
- Inspect impression to confirm that all obvious moisture has been removed.

8.1 The plan of treatment of edentulous patients by complete removable laminar dentures

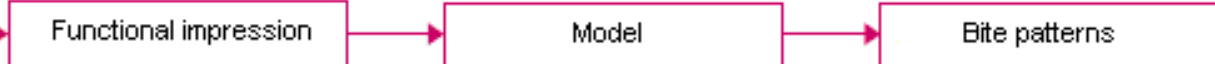


Gypsum model production

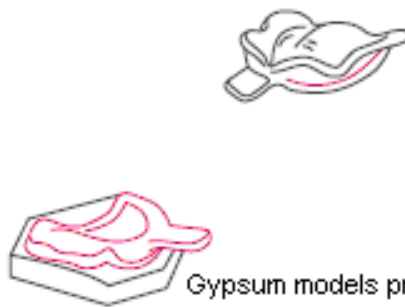
Upper jaw model



Individual impression tray production from "Carboplast"



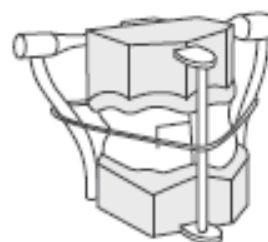
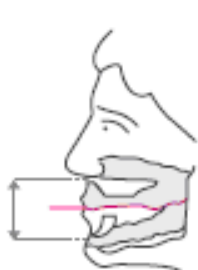Functional tests

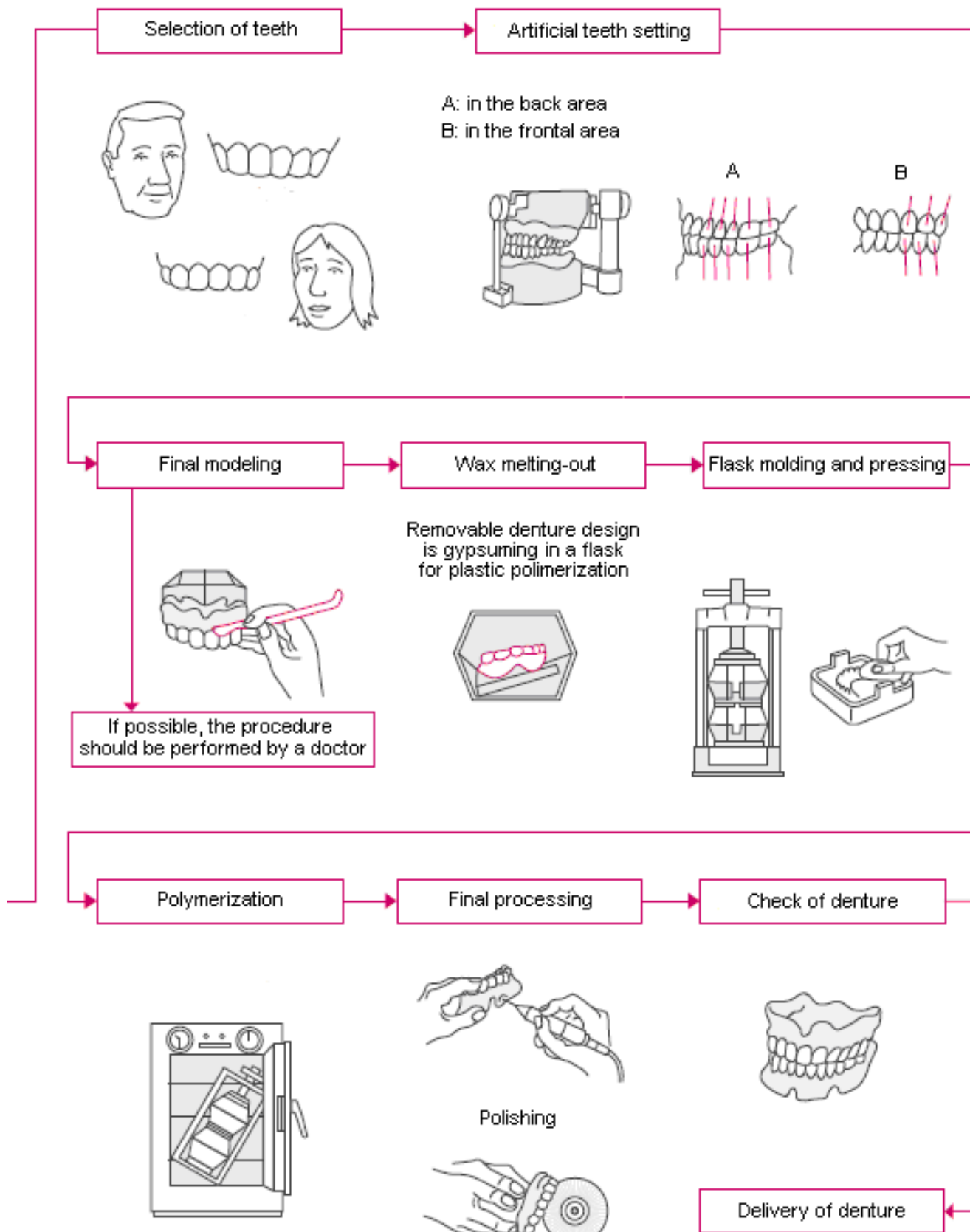


Gypsum models production by functional impression



Bite patterns production






9. Gypsum Model Production

Procedure's purpose: Pouring the impression (gypsum model fabrication)

Laboratory Procedure.

– After unpacking the impression, remove any tissue debris with a brush under running water (Caution: Always wear gloves!) and then place the impression in a disinfectant.



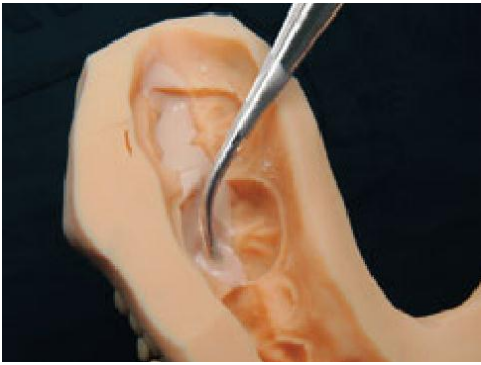
Option A: Measure the correct amount of distilled water in a measuring cylinder according to manufacturer's instructions. Then sprinkle the stone powder loosely into the bowl and allow to soak (10-15 seconds). First thoroughly pre-mix the stone manually, then attach the mixing bowl to the vacuum mixing unit and mix the stone thoroughly for approx. 60 seconds at 350 rpm (adhere to the manufacturer's instructions!).

Option B: Weigh on the scales the correct amount of distilled water. The scales are then set to zero again for weighing the stone. (**Note:** 100 ml = 100 g).

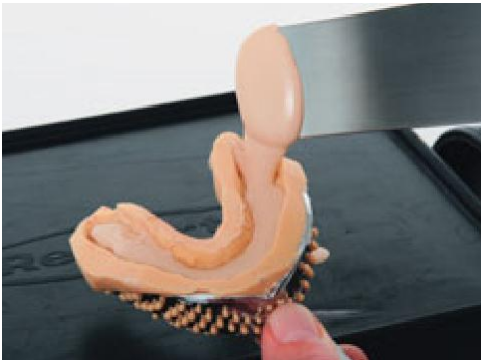Then sprinkle the stone powder loosely into the bowl and allow to soak (10-15 seconds). First thoroughly pre-mix the stone manually, then attach the mixing bowl to the vacuum mixing unit and mix the stone thoroughly for approx 60 seconds at 350 rpm (adhere to the manufacturer's instructions!).



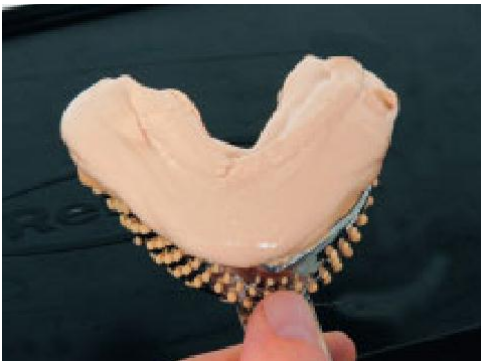– Hold the impression on the edge of the vibrator and pour the teeth carefully in dental stone using a probe to just above the preparation margin on the lowest vibrator setting.



The impression can then be filled evenly with stone from one side using a spatula. (**Note:** Never place the mixing bowl on the vibrator, as the stone would segregate!)



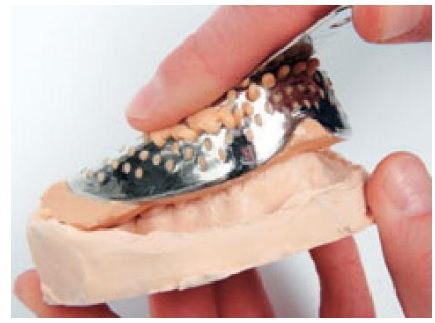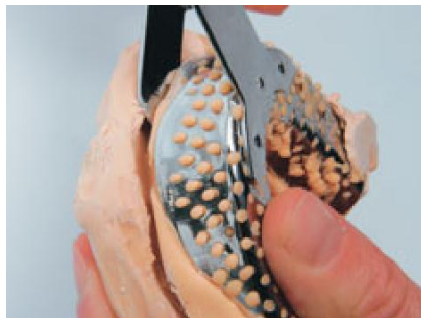
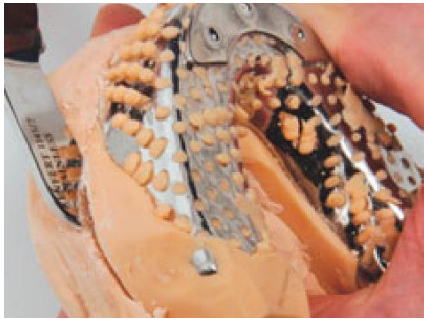Once the stone has a creamy consistency, build up the dental arch without using the vibrator. The result is a stable, large dental arch.



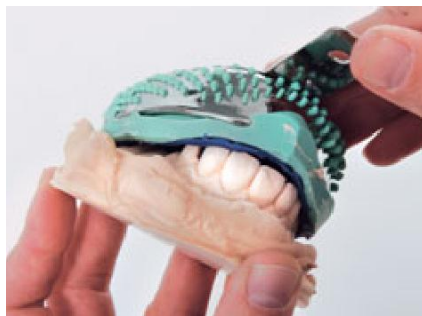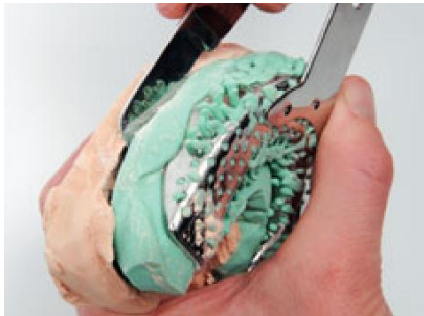Place a vacuum-forming foil on the stone to attain a flat base surface.



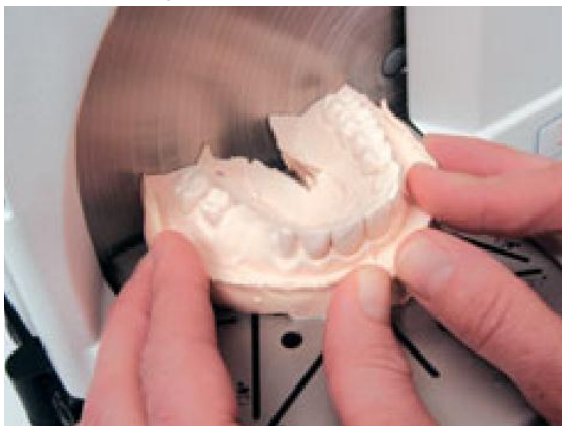
After the stone has set, raise the lower tray slightly from the buccal side with a plaster knife. Then loosen the impression tray evenly on all sides and lift it from the model over the anterior.



First loosen the upper impression in the premolar region with a plaster knife. Then loosen the tray at the back before lifting it from the model over the anterior.



– Trimming



10. Central Jaw Relationship Determination in Edentulous Patient

Initial definition: Central Jaw Relationship Determination – a clinical procedure in edentulous patient treatment.

Procedure's purpose: The development and consolidation of the logical sequence of the practical skills required for a central jaw relationship determination in edentulous patient treatment.

Material Security:

- Patient;
- Wax Patterns, Articulator, Gypsum Models (fabricated from edentulous basal seat area);
- Dental Treatment Unit;
- Fuel tablets, Matches (lighter);
- Fox's occlusal plane indicator (Sapozhnikov, Larin);
- Powdered Latex Gloves;
- Melting Hot Plate, Wax Knife, Water;
- Intraoral Mirror, Throat Spatula;

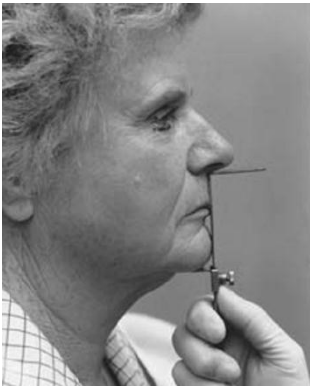Requirements for a Dentist:

- Dentist and Patient Correct Position selection;
- Dentist should stand face to face to the patient, and patient should sit upright;
- The patient head positioned at the elbow level of operator;
- Latex gloves and a mask should be applied;

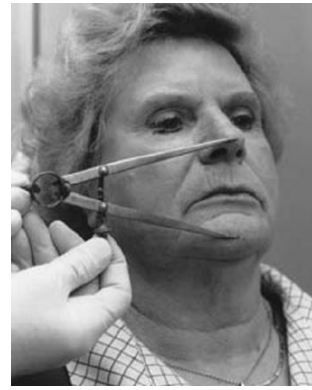Clinical Procedure.

1. The patient should sit upright and take a comfortable position. Before recording the rest vertical dimension, the dentist must be satisfied that the patient is truly relaxed.
2. The rest vertical dimension is measured as the distance between two selected points, one related to the upper jaw and one to the lower jaw.

Two methods are commonly used to make this measurement, the Willis (modification) gauge and the two-dot technique.



(a)



(b)

Fig. Two methods of measuring the rest vertical dimension and the occlusal vertical dimension. (a) The Willis gauge. (b) The two-dot technique; the distance between the dots is measured with a pair of dividers.

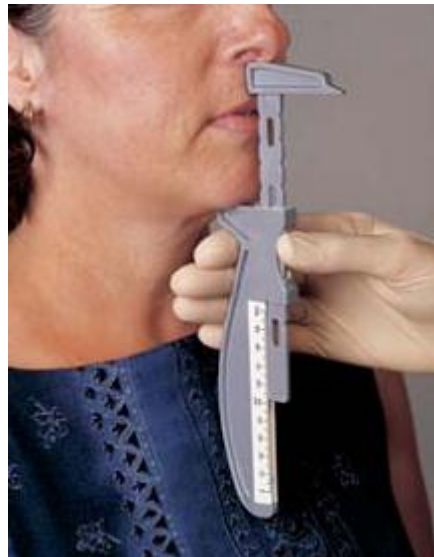

Fig. Willis Autoclavable Bite Gauge

- put the patient on a dental chair in a convenient position;
- two selected points are marked with a marker above and below the patient's mouth slit (rima oris), one related to the maxilla (nose tip) and one related to the mandible (protuberance of the chin);



Control of the rest position

The rest position of the mandible at any one time is the result of a balance of forces as shown in Fig. Both passive and active forces are described. The relative importance of active and passive forces in determining the rest position is a controversial issue. One school of thought maintains that active forces are the major factor, another that passive forces alone are responsible for the true rest position, while yet a third school suggests that the rest position is the product of both active and passive forces in combination.

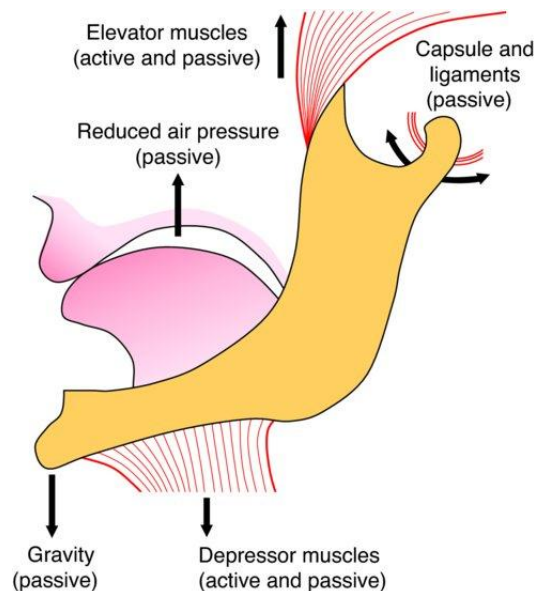
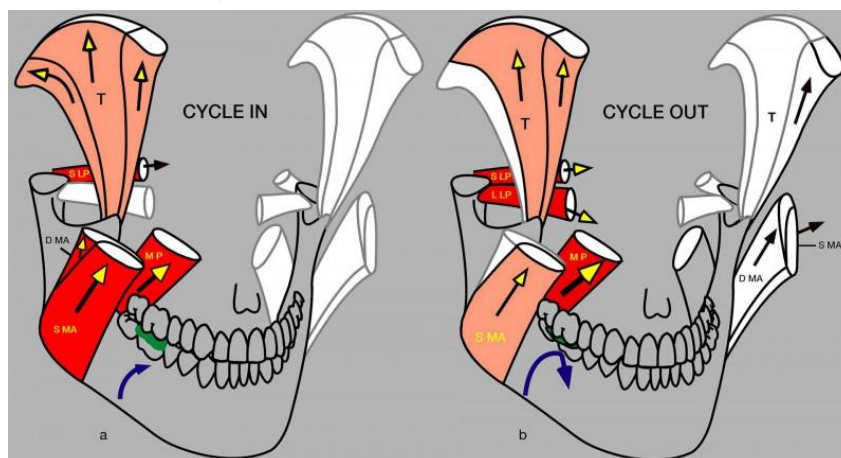


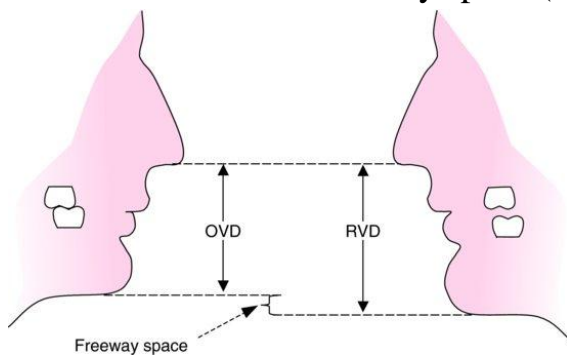
Fig. Forces which determine the rest position of the mandible.

– the mandibular position assumed when the head is in an upright position and the involved muscles, particularly the elevator and depressor groups, are in functional equilibrium in tonic contraction and the condyles are in a neutral and unstrained position; for this involve the patient in a short conversation or ask him to count out loud and then to resolve the lips without tension;

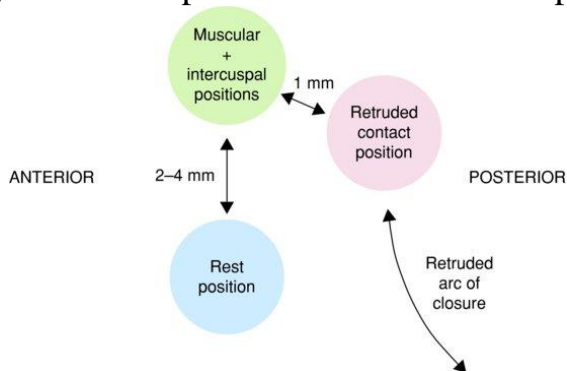


– fix the distance between the selected points. When the upper and lower teeth are in contact is known as the *occlusal vertical dimension*. When the mandible is in its resting

position, this distance is the *rest vertical dimension*. The difference between the measurements is the freeway space (2,0-3,0mm).



Diagrammatic representation of the basic positions of the mandible in the sagittal plane:

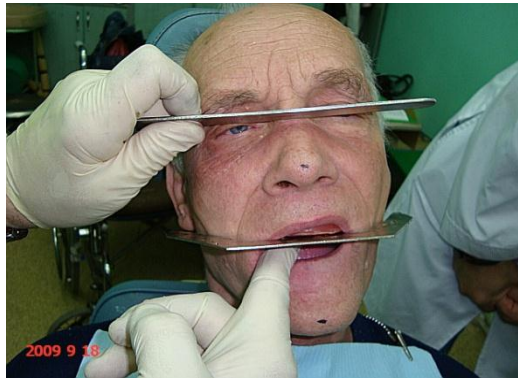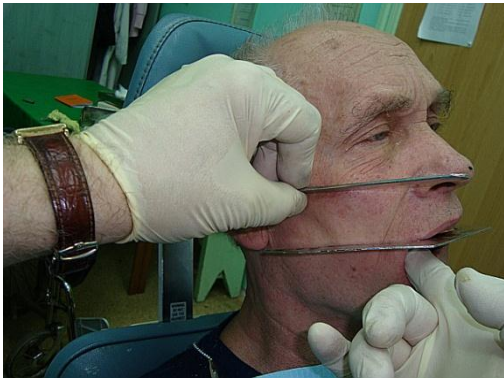
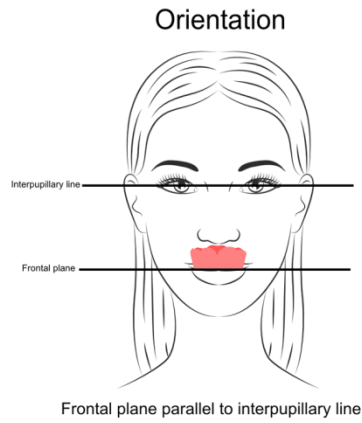

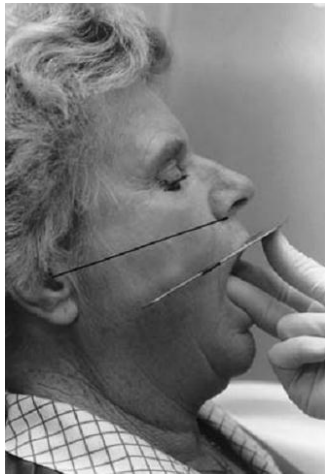
Nomenclature for basic mandibular positions:

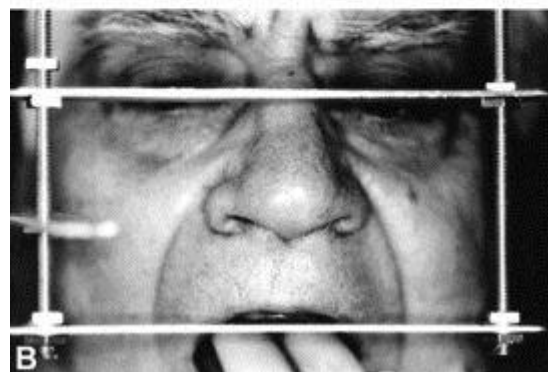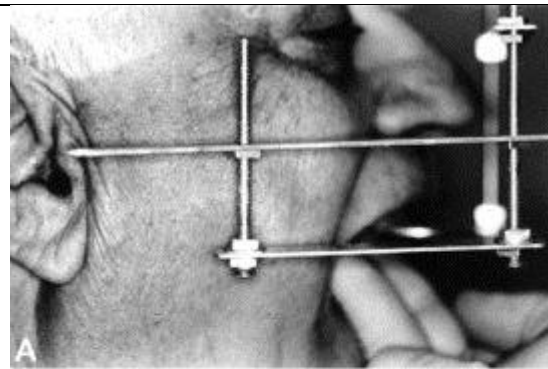
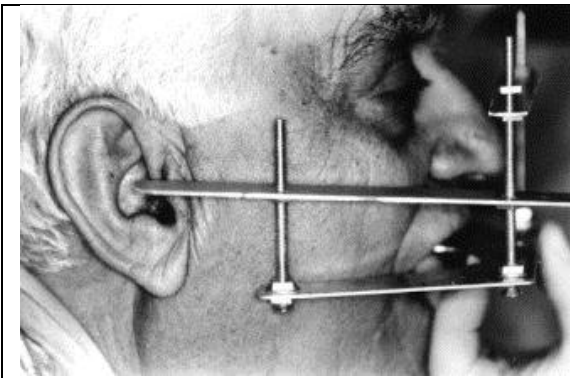
Terms used in book	Alternative terms
Rest position	Physiologic rest position
Muscular position	Habitual position
Intercuspal position	Centric occlusion
	Maximum intercuspation
	Tooth position
Retruded contact position	Centric occlusion
	Centric relation
	Ligamentous position
	Posterior border position
Freeway space	Inter-occlusal rest space

Further:

- simulate the vestibular surface of **roller of the upper bite wax pattern;**
- determine the location of the level of the prosthetic surface of **roller of the upper bite wax pattern;**

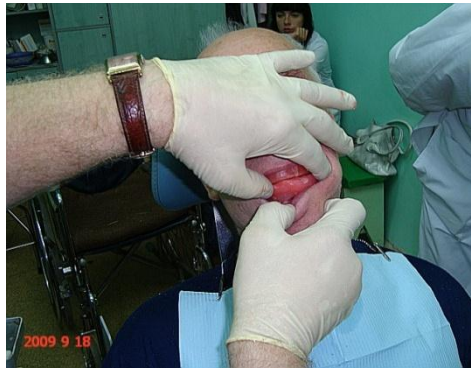

– control the location of the prosthetic surface (frontal plane) with the help of Fox’s occlusal plane indicator (ruler by Sapozhnikov, ruler by Larin);

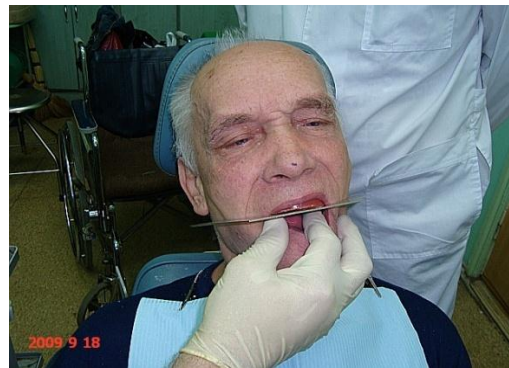
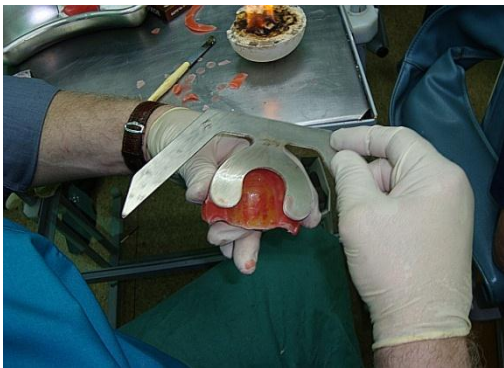
Fox’s occlusal plane guide

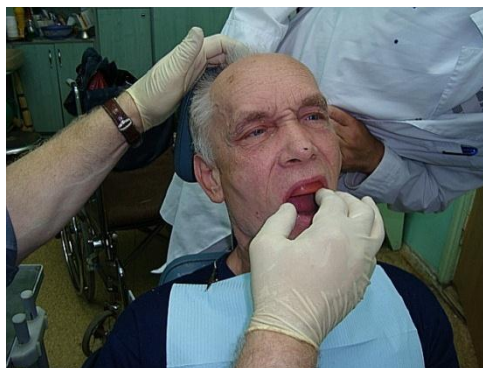A modified occlusal plane device
Husseinovitch I., Chidiac J.J.



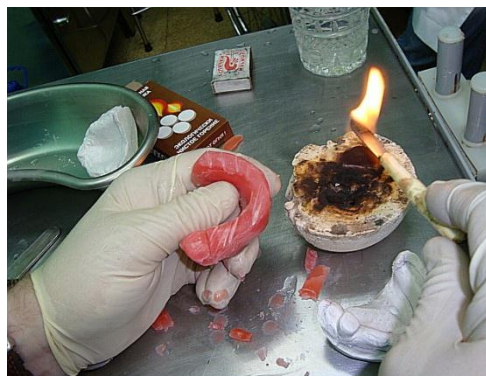– The height of the **lower bite wax pattern** have been corrected and controlled by the **height of the central relationships of the jaws**;



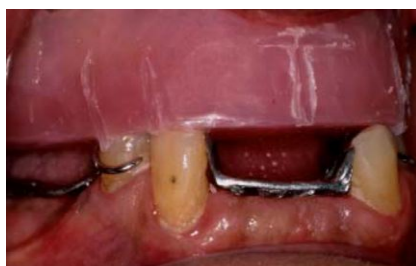– obtained the imprint of the prosthetic surface (frontal plane) of roller of the upper bite wax pattern on the prosthetic surface of roller of the **lower bite wax pattern**;



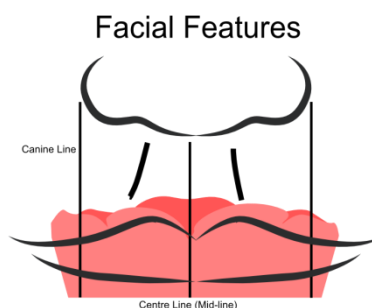
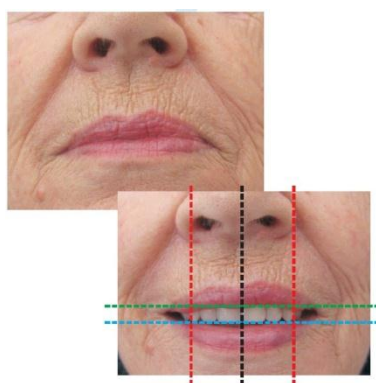
– simulate the vestibular surface of **roller of the lower bite wax pattern**;



– determine and fix **the central relationships position** of the jaws with the help of **bite patterns**;

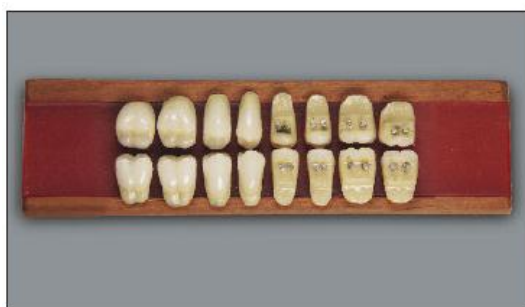
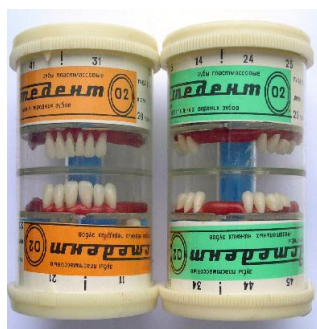
– determine and apply on the vestibular surfaces of **wax rim of bite patterns** the following lines: "**aesthetic centre of the face**", "**of a smile**", "**of the canines**";



Centre Line (Mid-line) to be centralised with the Philtrum.
Canine lines to match the width of the Nose.

– select the material, color, tooth style for the construction of dental rows of removable plate prostheses.



Фасон и форма Mould and shape	Передний верхний зуб Anterior upper teeth			Передний нижний зуб Anterior lower teeth			Исходный зуб Posterior teeth		
	В, мм B, mm	Ш, мм H, mm	Г, мм G, mm	Фасон Mould	В, мм B, mm	Ш, мм H, mm	Фасон Mould	В, мм B, mm	Ш, мм H, mm
22 ○	10,0	7,5	7,5	11	30,0	4,5	11 Ж	36,0	28,0
23 ○; 23 □			8,7						
25 □	12,0		9,0						
25 ○	14,0	8,0	8,7	12	34,0	5,0	12 Ж	39,0	30,5
26 ○	13,0		9,6						
27 ○		8,2	8,0						
28 ○		8,4	9,8						
29 □	14,0	8,3	10,6	13-17	36,5	5,5	13 Ж 48 Ж	39,0	31,5
44*		8,8	11,2						
30 ○	19,0	9,0	9,7						
31 ▽		9,2	11,2	14	39,0	5,8	14 Ж	31,0	31,5
32 ○	18,0	9,4	11,6						

11. Crowns fitting:

- full metal stamped;
- whole-piece-cast metal;
- whole-piece-cast metal, ceramic mass facing / plastic facing; plastic.

Procedure's purpose: checking the congruence of the inner surface of the crown and the stump of the tooth, if necessary - correction.

Material Security:

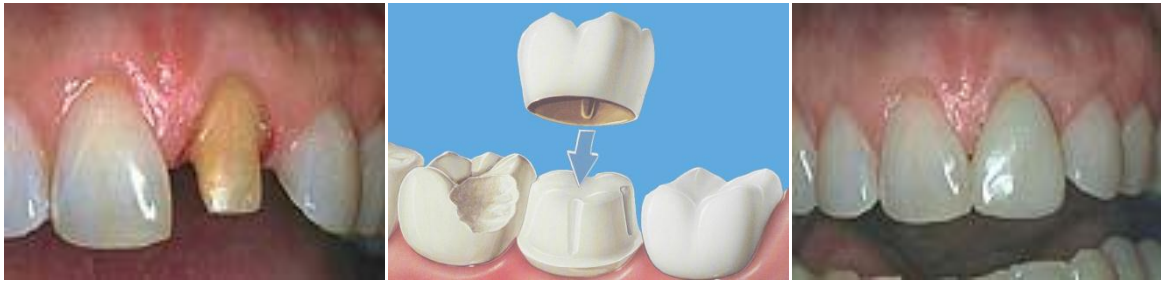- full metal stamped crown; whole-piece-cast metal crown; whole-piece-cast metal crown ceramic mass facing / plastic facing; plastic crown.
- Latex Gloves, Mask;
- Dental Treatment Unit;
- Abrasive Tools Set;
- Straight Dental Hand-Piece and Angled Dental Hand-Piece;
- Dental Crown Extractor;
- A Large Kidney-Shaped Tray with Inspection Tools, Intraoral Mirror, Throat Spatula;
- Arti-Spray;
- Marker or base paste of silicone impression material

Requirements for a Dentist:

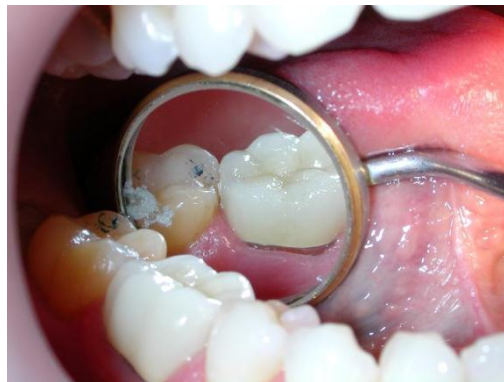- Dentist and Patient Correct Position selection (Convenient to place the patient in the Dental Treatment Unit: the patient's head is located at the level of the doctor's elbow);
- wear latex gloves and mask;
- the dentist is in front of the patient; in preparation, in removing of the crowns from the teeth of the upper jaw, the right thumb fixes on the patient's upper lip, on the chin - in manipulating on the lower jaw; in the same hand the doctor holds the tip, in the left hand - a dental mirror, which protects the tongue, cheek, gum from injury by an abrasive instrument.

Method of conducting:

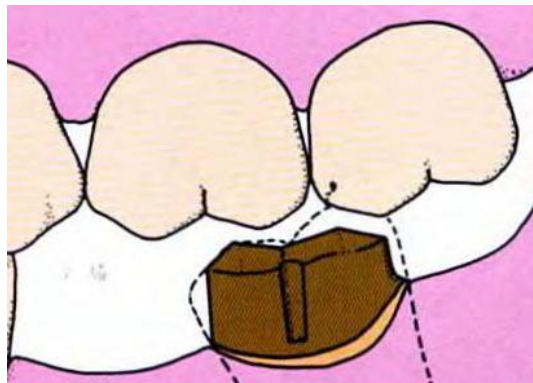
- check the path of introduction / removal of the crown from the stump of the tooth; check the position of the crown relative to the adjacent teeth and antagonist teeth;



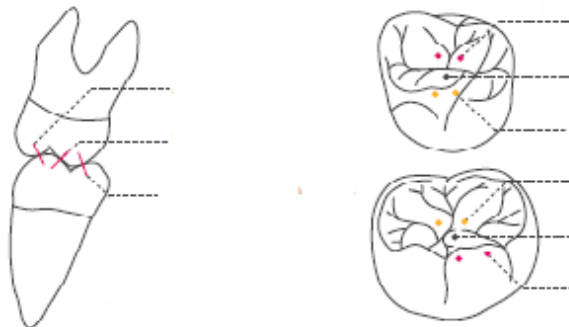- check the restoration quality of the anatomical shape of the crown part of the tooth, contact points with adjacent teeth;



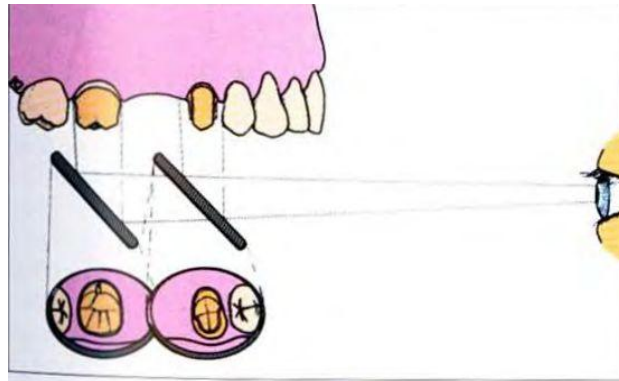
- check the presence of supra- and infra-occlusive contacts with antagonist teeth;



- if a supra-occlusal contact is found, prepare a suitable area of a tooth stump;



- in the case when the neck of the stump of the tooth does not correspond to the edge of the crown, then the corresponding portion of the stump of the tooth is prepared;



- In the presence of a gap between the neck of the stump and the edge of the crown, the entire metal stamped crown is re-stamping, and the cast-iron metal (lined with ceramics, plastic) is made anew. The plastic crown should be newly made.
- The position of the edge of the crown relative to the gingival groove is determined after obtaining a complete anatomical impression with the help of a marker or base paste of the silicone impression material;



- remove the crown from the stump of the tooth and transfer it to the laboratory for correcting the length of the edges;

12. The Single Swaged Crowns Inspection

Procedure's purpose: checking the correspondence of the inner surface of the crown of the tooth and the quality of restoration of the anatomical shape of the crown part of the tooth

Material Security:

- Plaster model or Jaw Phantom with a tooth stump, prepared for a single swaged crown;
- Straight Dental Hand-Piece and Angled Dental Hand-Piece;
- Abrasive Tools Set;
- Anvil and hammer;
- Crampon or Beak-shaped Forceps;
- Tools Set (tweezers, probe, mirror), cotton wool;
- Solution of hydrogen peroxide 3%, Alcohol 70%;
- Dental Crown Extractor;
- Arti-Spray;
- Articulating Paper.

Requirements for a Dentist:

- Conveniently place the patient in the Dental Treatment Unit: adjust the height of the chair, the position of the patient's head and the lighting;
- Tell the patient about the upcoming manipulations;
- Know how to conduct verification of a single swaged crown;
- The tool must be sterile. Wear latex gloves and mask;

Method of conducting:

- Check swaged crown on gypsum column (in accordance with the requirements for a single swaged crown: must restore the anatomical shape of the crown part of the prepared tooth);
- The length of the crown should be at the level of the anatomical neck of the tooth;
- Check the absence of folds and mechanical defects;
- Administered swaged crown into the mouth and check accordance with the requirements for the supporting tooth stump;
- The crown should be densely applied to the stump of the tooth and the minimum to sink under the edge of the gums;
- Crowns should maintain approximate contacts, do not create supracontacts, do not protrude from the dentition;
- If the crown does not meet these requirements, for example, it is long - it should be shortened with an abrasive tool, if the crown is narrow – it is recontouring down by using

an anvil and hammer;

- If the crown is short, very narrow or wide, it must necessarily be remade;
- If the full swaged crown meets all requirements, it is removed from the stump of the supporting tooth and returned to the dental laboratory for further polishing, applying a medical protective covering.

13. Checking of the Framework of Cast-Metal Crowns (with an aesthetic facing by ceramic or plastic masses)

Procedure's purpose: checking the correspondence of the inner surface of a cast-metal crown to the tooth stump and the quality of restoration of the anatomical shape of the crown part of the tooth.

Material Security:

- Plaster model or Jaw Phantom with a tooth stump, prepared for a cast-metal crown;
- Micromotor or dental unit with a mechanical drive;
- Turbine Dental Hand-Piece with outlet to the Compressor;
- Straight Dental Hand-Piece or Turbine Dental Hand-Piece;
- Abrasive Tools Set for Turbine Dental Hand-Piece (disks and diamond heads);
- A set of tools (tweezers, probe, mirror), cotton wool;
- Dental Crown Extractor;
- Corrective silicone material;
- Arti-Spray;
- Articulating Paper.

Requirements for a Dentist:

- Conveniently place the patient in the Dental Treatment Unit: adjust the height of the chair, the position of the patient's head and the lighting;
- To familiarize the patient with the upcoming manipulations;
- To know the procedure of testing the framework of a cast-metal crown.
- Use only sterile instrument, the hands of the doctor should be in gloves, on the face - a mask.
- For auxiliary sterilization use a suitable solution, for example, "Sterilium".

Method of conducting:

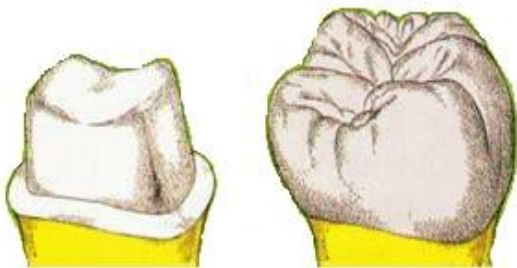
Second visit:

- Check the way of delivery and removal of a cast-metal crown on the model;
- The cap is inserted into the patient's oral cavity and placed on the stump of the prepared tooth;

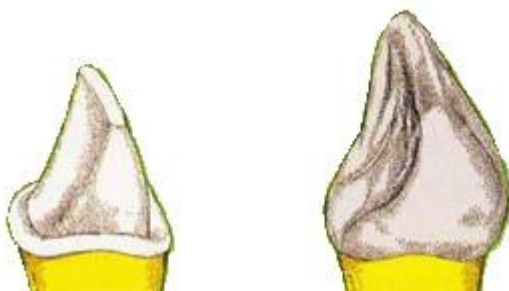
- Check the conformity and accuracy of the fit of a cast-metal crown to the stump of a tooth by using corrective silicone mass;
- Check the absence of supra-occlusive contact with antagonist teeth using articulation paper.

Third visit (with an aesthetic facing by ceramic mass):

- Check the conformity and accuracy of the cast-metal crown by ceramic facing on the model, the absence of supra- and infra-occlusion with antagonist teeth;
- Check the way of delivery and removal of a cast-metal crown by ceramic facing on the model;
- The crown is delivered into the oral cavity of the patient, is installed on the tooth stump. The crown should restore the anatomical shape of the tooth, the approximate contacts should be preserved, not make supra-occlusal contact, not protrude from the dentition;
- Check the conformity and accuracy of the fit of a cast-metal crown to the stump of a tooth by using corrective silicone mass;
- Check the absence of supra-occlusive contact with antagonist teeth using articulation paper.
- The color of the aesthetic facing of the crown is on hold;
- When a cast-metal crown by ceramic facing is in compliance with all requirements, the design is removed from the stump of the supporting tooth and transferred to the dental laboratory for glazing.



Stump of 2.6 tooth prepared with the creation of a shoulder under the cast-metal crown by ceramic mass facing.



Stump of 2.1 tooth prepared with the creation of a shoulder under the cast-metal crown by ceramic mass facing.

14. The frameworks of fixed solid cast bridges checking with supporting elements in the form of full crowns on the phantom

Procedure's purpose: quality check of the restoration of the anatomical shape of the dentition by a non-removable bridge-like denture.

Material Security:

- Micromotor or dental unit with a mechanical drive;
- Straight Dental Hand-Piece;
- Shaped heads set with diamond abrasive;
- Arti-Spray;
- Articulating Paper

Requirements for a Dentist:

- Conveniently place the patient in the Dental Treatment Unit: adjust the height of the chair, the position of the patient's head and the lighting;
- To familiarize the patient with the upcoming manipulations;
- To know the procedure of testing the framework of a cast-metal crown.

Use only sterile instrument, the hands of the doctor should be in gloves, on the face - a mask. For auxiliary sterilization use a suitable solution, for example, "Sterilium".

Method of conducting:

- Check the way of delivery and removal of a cast-metal crown on the model;
- The prosthesis should correspond to the anatomical shape of the prepared teeth, maintain approximate contact, not to overestimate the bite, not to protrude from the dentition;
- In case of detection of supra-occlusal contacts on the occlusal surface of the bridge-like denture (subject to a tight fit of the necks of crowns to the ledges on the stumps of the teeth), correct the appropriate places with diamond shaped heads and articulating paper;

15. Crown's fixation

Procedure's purpose: fixing crowns on teeth stumps with cement for non-removable (fixed) dentures fixation.

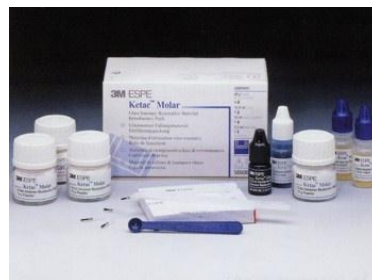Material Security:

- Phantom of the patient's head with models of denture foundation area and stumps of teeth;

- Full metal stamped crown, cast-metal crown, cast-metal crown by ceramic mass facing, plastic crown;
- Fixation cement;
- Glass Slide for material mixing;
- Tweezers, probe, mirror, cement spatula, cotton wool, cotton rollers, Sol. Spiriti aethylici 70%.

Method of fixing a full metal stamped crown

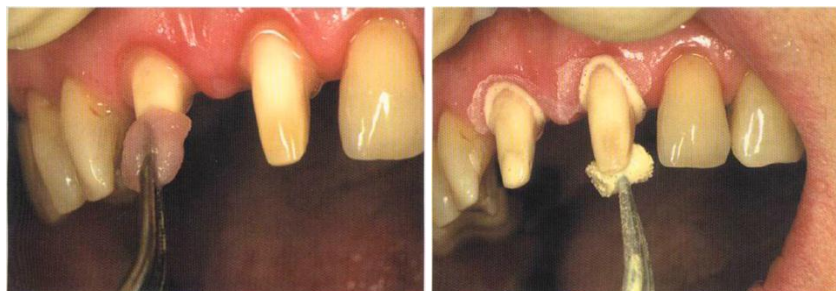Powder and liquid are applied to the glass in the ratio specified in the instructions for cement (glass-ionomer or phosphate-cement).



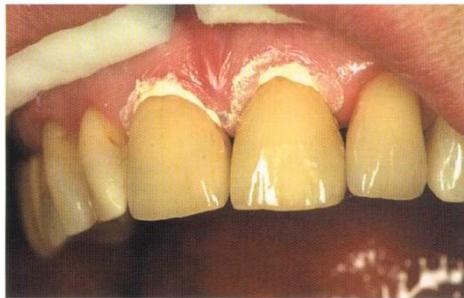Isolate the stump of the abutment tooth with the cotton rollers. Spend processing the stump of tooth by Sol.Spiriti aethylici 70%, air drying is carried out. Cement is kneaded to the consistency of "sour cream". Cement is added into the crown, fill it in 2/3 and put on a stump. The patient is asked to close the dentitions, while controlling the position of the central occlusion. After 10-15 minutes, the remains of cement are cleaned by using a probe and a dental excavator.

Method of fixing a solid cast full crown with ceramic mass facing

The crown is decontaminated with an appropriate solution and air dried under pressure. The tooth stump is isolated from the saliva by rollers, decontaminated, degreased and dried.

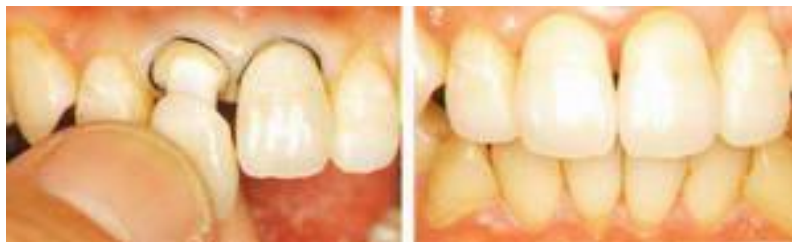

Powder and liquid are applied to the glass slide. The ratio of powder and liquid is specified in the annotations to cement. Mix the powder and liquid to the consistency necessary for its free exit from the edges of the crown. The crown is filled with cement for about 2/3, put cement on its walls and the surface of the stump. A crown is placed on the stump of tooth and the dentist asks the patient to close the teeth tightly, while monitoring the position of the central occlusion.



After 20-30 min, carefully remove excess cement. The patient is explained the need for a gentle regimen during the first 2-3 hours after the crystallization of the cement (phosphate cement).

Method of fixing plastic crowns:



Note: The color of the cement for fixation is selected for each color range of plastic separately. Test mixing is performed before fixing the crown.

With the help of rollers isolate the stump of the tooth. Treat stump with alcohol, dried with air. Knead the cement to the consistency of "sour cream". Cement is applied to the crown, filled with 2/3 of it and put on the stump of tooth. The patient is asked to close the dentitions tightly, while monitoring the position of the central occlusion. After 10-15 minutes, clean the excess cement with an excavator and probe.

Method of fixing solid metal crowns with aesthetic veneering

The oxide film is removed from the inner surface of the crown, decontaminated, treated with alcohol and dried with a stream of air. The stump of tooth is isolated from the saliva by rollers, decontaminated, degreased and dried. Powder and liquid are applied to

the glass slide in the ratio specified in the cement instructions and stirred until the consistency of “liquid sour cream”. The crown is filled with cement for about 2/3. The crown is placed on the stump of tooth and the patient is asked to close the teeth tightly, while monitoring the position of the central occlusion. After 20-30 minutes, the excess cement is carefully removed by using a probe and an excavator.

16. Dental Bridges Cementation

Procedure’s purpose: fixing of dental bridges with cement for non-removable (fixed) dentures design.

Material Security:

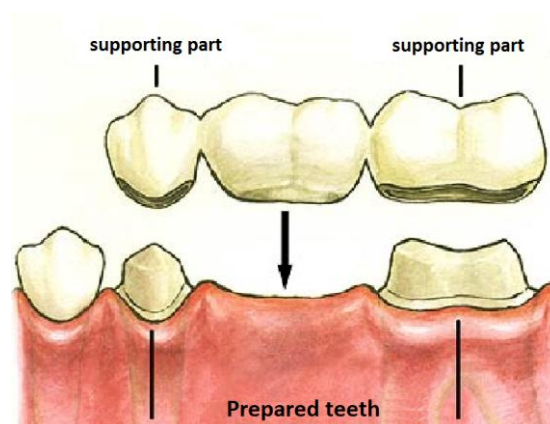
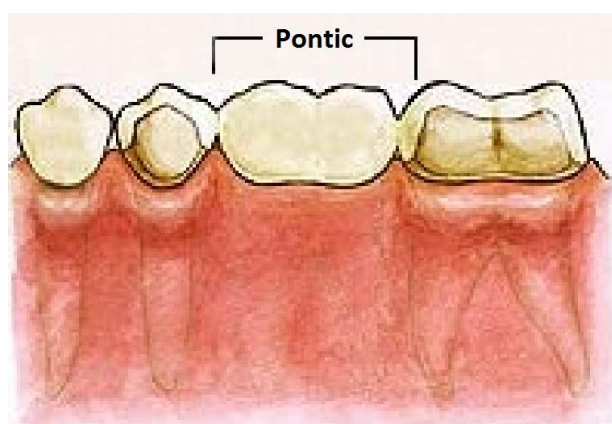
- Phantom of the jaw with stumps of teeth, prepared under the stamped-soldered dental bridge with supporting elements in the form of full crowns;
- Stamped-soldered dental bridge;
- Fixation cement, for example, zinc-phosphate cement “Unifas”;
- Glass Slide for material mixing;
- Tools (tweezers, probe, mirror, cement spatula);
- Cotton wool, cotton rollers, Sol. Spiriti aethylici 70%.

Requirements for a Dentist:

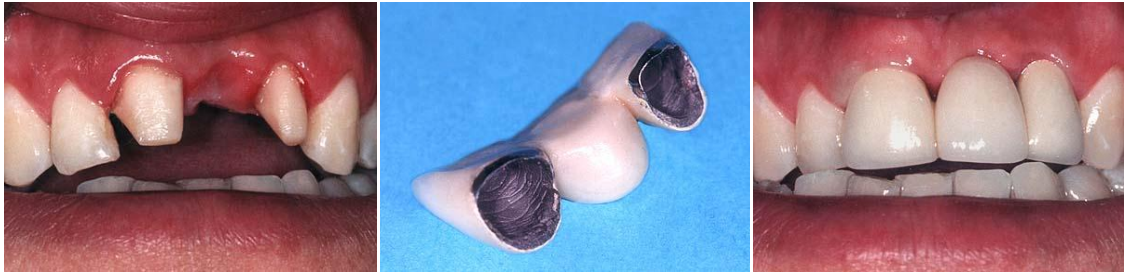- Conveniently place the patient in the Dental Treatment Unit: adjust the height of the chair, the position of the patient's head and the lighting;
- To familiarize the patient with the upcoming manipulations;
- To know the procedure of cementation of fixed dentures design.

Use only sterile instrument, the hands of the doctor should be in gloves, on the face - a mask. For auxiliary sterilization use a suitable solution, for example, "Sterilium".

Method of fixation of a stamped-soldered dental bridge



The required amount of cement powder and liquid is applied to a glass slide (the ratio of powder and liquid is indicated in the abstract to cement). With the help of cotton rollers isolate the supporting stumps of the teeth. Then, with the help of alcohol, the supporting stumps and crowns are treated, dried with air. On a glass slide the cement is mixed to a consistency of “liquid sour cream”. The mixture is put in the crowns at 2/3 of the depth, located into the oral cavity, placed on the stump of the abutment teeth.



The patient is asked to close the teeth tightly. The position of the central occlusion is checked. After 5-10 minutes, the excess cement is carefully removed by using a probe and an excavator.

17. Crown removal

- Full metal stamped crown;
- Cast-metal crown;
- Cast-metal crown by ceramic mass facing;
- Cast-metal crown by plastic facing;
- Plastic crown.

Procedure's purpose:

Non-traumatic removal of the crown from the tooth stump.

Material Security:

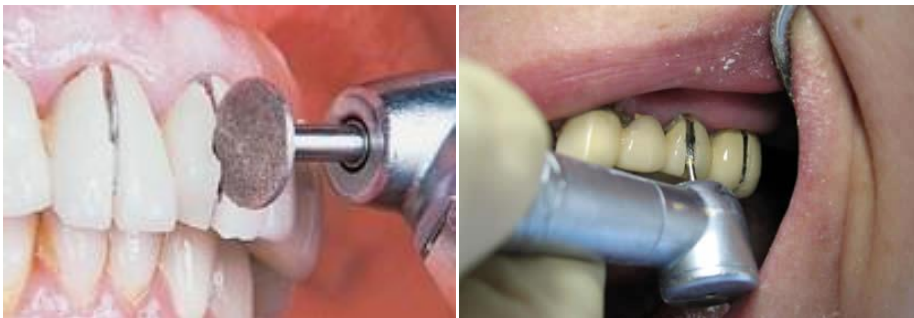- Dental Unit;
- Large kidney-shaped tray with inspection tools: dental mirror, throat spatula;
- A glass of water;
- Antiseptic tablets;
- Intraligamentary Anaesthesia Syringe;
- Cartridge with anaesthetic agent;
- Short Needle;
- A set of shaped heads with a diamond abrasive of coarse grain
- Fissure carbide burs for cutting crowns;
- Sharpened straight elevator;
- Dental crown extractor by Kopp;
- Latex gloves, Mask.

Requirements for a Dentist:

- It is necessary to place the patient comfortably in the dental chair: the patient's head is at the level of the doctor's elbow;
- wear latex gloves and a mask;
- the dentist takes a position in front of the patient, the right thumb fixes the patient's upper lip in preparing, removing crowns from the upper jaw teeth or on the chin - during manipulating the lower jaw teeth area; in the same hand the doctor holds the handpiece, in the left hand - the dental mirror, which protects the tongue, cheek, gum from injury of the soft tissues by an abrasive tool.

Method of conducting:

- Check the accuracy of the dental handpiece;
- Fix the abrasive tool;
- Check the quality of fixation and centering of the abrasive tool;
- Ask the patient to rinse the mouth;
- Anaesthesia intervention procedure;
- Switch on a saliva ejector and water cooling;



- Cut by special diamond drill bit or carbide boron the vestibular surface of a crown until cement appears in the crown lumen;
- Enter the end of the direct elevator, bring under the incision edges of a single crown and turn them down from the tooth stump;
- The end of the direct elevator is inserted deeper under the incision edges, moving it to the occlusal surface of the tooth stump and elevate the crown, relying on the tooth stump, remove it;
- In some cases, Dental Crown Extractor by Kopp is used for remove the crown: it is brought into the operating position and clinging to the edge of the crown, in turn, knock off a crown from the stump of a tooth.

18. Dental Bridge removal

- Metal stamped-soldered dental bridge;
- Solid Cast dental bridge;
- Solid Cast dental bridge by ceramic mass facing;
- Solid Cast dental bridge n by plastic facing;
- Plastic dental bridge.

Procedure's purpose:

Non-traumatic removal of the supporting crowns of the fixed dental bridge from a stumps of supporting teeth.

Material Security:

- Dental Unit;
- Large kidney-shaped tray with inspection tools: dental mirror, throat spatula;
- A glass of water;
- Antiseptic tablets;
- Intraligamentary Anaesthesia Syringe;
- Cartridge with anaesthetic agent;
- Short Needle;
- A set of shaped heads with a diamond abrasive of coarse grain
- Fissure carbide burs for cutting crowns;
- Sharpened straight elevator;
- Dental crown extractor by Kopp;
- Latex gloves, Mask.

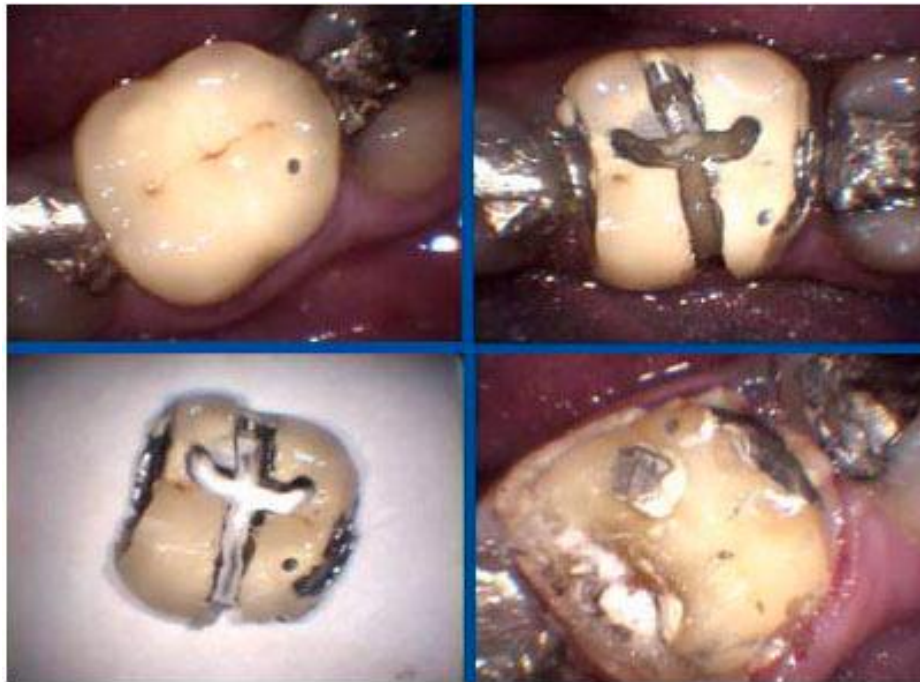
Requirements for a Dentist:

- It is necessary to place the patient comfortably in the dental chair: the patient's head is at the level of the doctor's elbow;
- wear latex gloves and a mask;
- the dentist takes a position in front of the patient, the right thumb fixes the patient's upper lip in preparing, removing crowns from the upper jaw teeth or on the chin - during manipulating the lower jaw teeth area; in the same hand the doctor holds the handpiece, in the left hand - the dental mirror, which protects the tongue, cheek, gum from injury of the soft tissues by an abrasive tool.

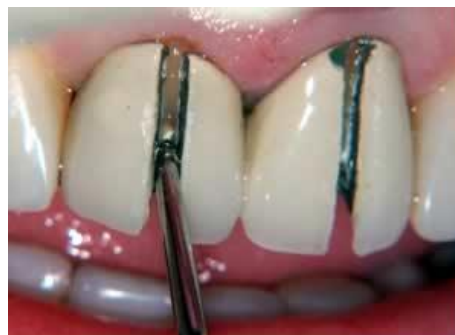Method of conducting:

- Check the accuracy of the dental handpiece;
- Fix the abrasive tool;

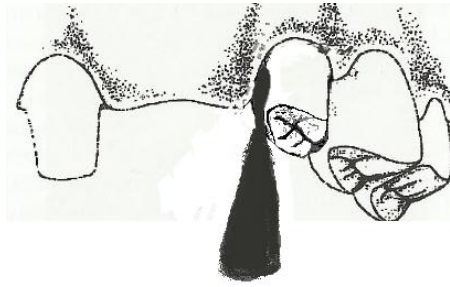
- Check the quality of fixation and centering of the abrasive tool;
- Ask the patient to rinse the mouth;
- Anaesthesia intervention procedure;
- Switch on a saliva ejector and water cooling;
- Cut by special diamond drill bit or carbide boron the vestibular surface of supporting crowns (dental bridge elements) until cement appears in the crown lumen;



- Enter the end of the direct elevator, bring under the incision edges of crowns alternately and turn them down from the stump of the teeth;
- For removal of the bridge prosthesis, you can use a direct elevator, moving it towards the occlusal surfaces of the crown, while avoiding skewing or
- Kopp's Dental crown extractor is used for churning the crown from the stump of the abutment teeth, and also avoiding skewing of the dental bridge during removal.



- Then the tip of the straight elevator is inserted under the edge of the incision, moving it to the occlusal surface of the stump of tooth and, lifting, removes the crown;



- Remove the crowns of the dental bridge;
- Take out the dental bridge design from the mouth cavity;
- Offer the patient to rinse the mouth with an antiseptic solution.

19. Try-in for acrylic partial and complete removable laminar dentures

Procedure's purpose: Try-in for design of partial and complete removable laminar dentures before the laboratory procedure of the final modeling and plastering into the polymerization flask.

Material Security:

- Straight Dental Hand-Piece;
- Micromotor or Dental Unit with a mechanical drive;
- Set of cutters and Bausch occlusion paper;
- Plaster model with partial dentition defect;
- Large kidney-shaped tray with inspection tools: dental mirror, throat spatula;
- A glass of water;
- Antiseptic tablets;
- Latex gloves, Mask.

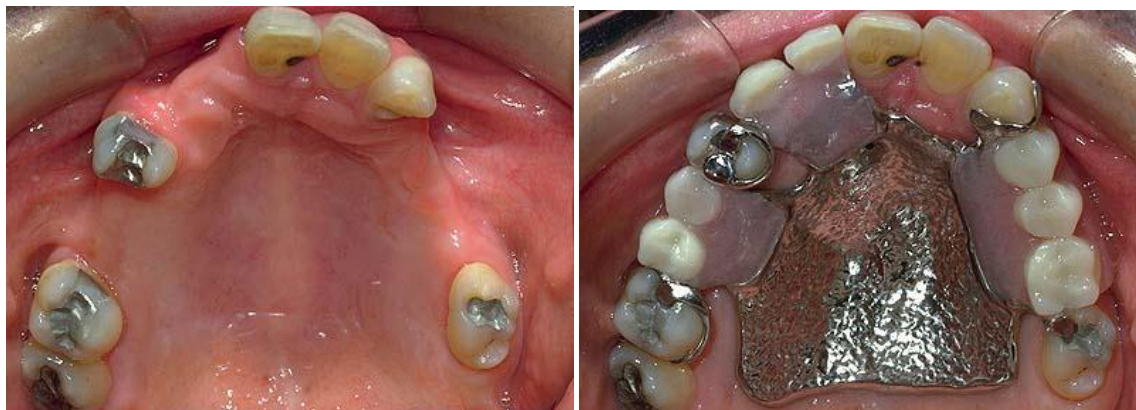Requirements for a Dentist:

- It is necessary to place the patient comfortably in the dental chair: height of the chair, the position of the patient's head, lighting;
- To familiarize the patient with the upcoming manipulations;
- Use only sterile instrument, the hands of the doctor should be in gloves, on the face - a mask.
- For auxiliary sterilization use a suitable solution, for example, "Sterilium".

Method of conducting:

Check the compliance of the prosthesis to the requirements: compliance of the

basis of the denture with the prosthetic seat area borders, the correctness of the artificial teeth setting, the quality of the plastics polymerization, the clasps location.



The prosthesis is inserted into the patient's oral cavity; the prosthesis is placed on the denture foundation area, and checks its position. In case of detection of points and places of supracontacts, detected with articulation paper on the artificial teeth of the denture, grind them with a cutter.

20. Partial and Complete Removable Dentures Bases Correction.

Procedure's purpose:

If there are patient complaints of pain under the base of the denture in functional occlusion – traumatic overhangs on the base must be eliminated, traumatic stomatitis should be prevented, and the process of adaptation to the prosthesis should be optimized.

Material Security:

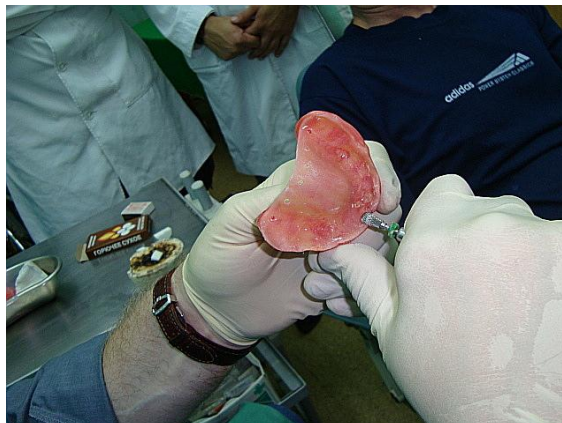- Dental Unit;
- Straight Dental Hand-Piece;
- Abrasive Tools: a set of heads with a diamond abrasive of coarse grain, fissure carbide burs;
- Metal cutters;
- Large kidney-shaped tray with inspection tools: dental mirror, throat spatula;
- Bausch articulating paper;
- A glass of water;
- Antiseptic tablets;
- 70% alcohol, 3% hydrogen peroxide;
- Latex gloves, Mask.

Requirements for a Dentist:

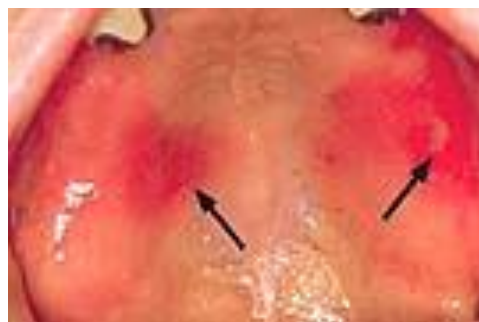- It is necessary to place the patient comfortably in the dental chair: the patient's head is at the level of the doctor's elbow;
- To familiarize the patient with the upcoming manipulations;
- To know the methods of correction the basis of partial and complete dentures;
- Use only sterile instrument, the hands of the doctor should be in gloves, on the face - a mask.
- For auxiliary sterilization use a suitable solution, for example, "Sterilium".

Method of conducting:

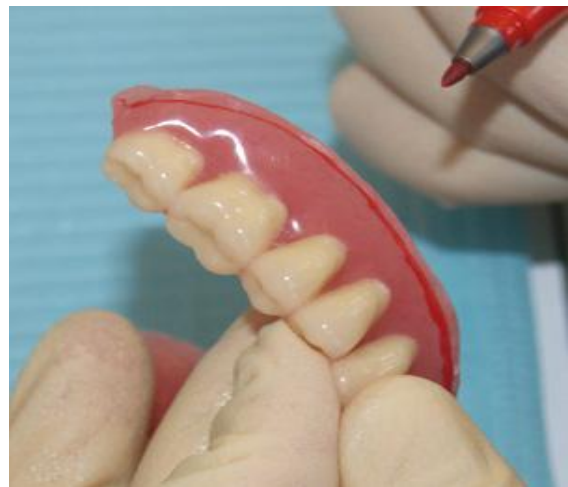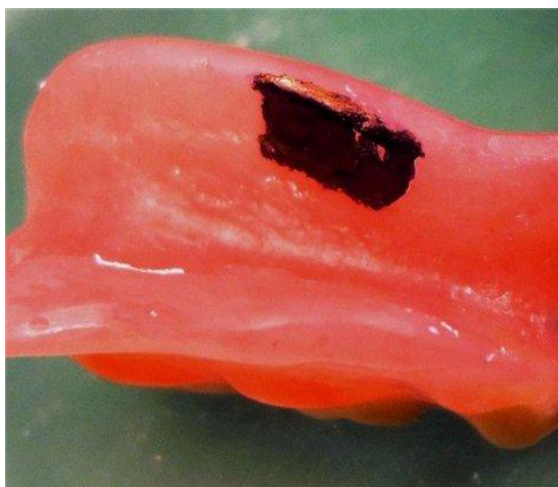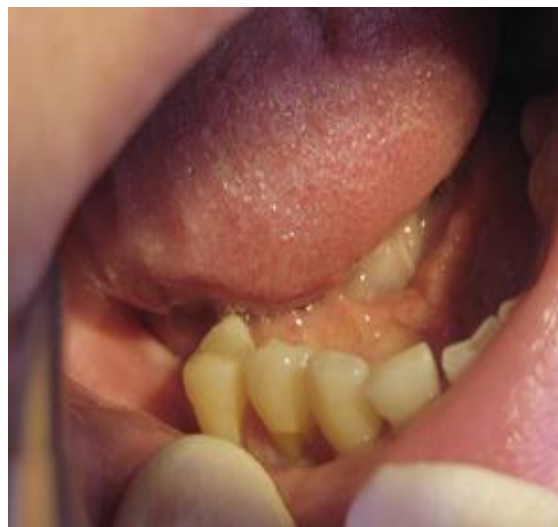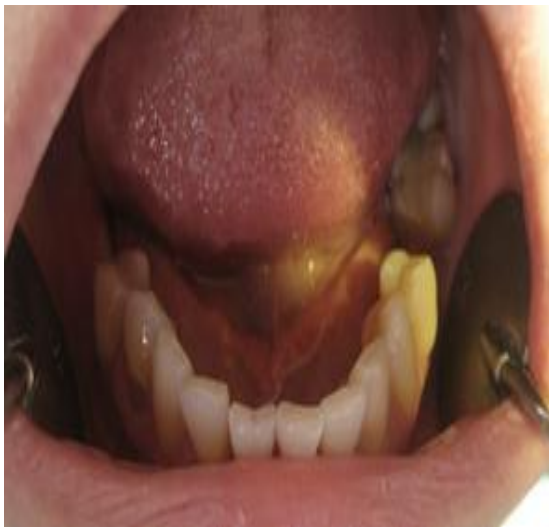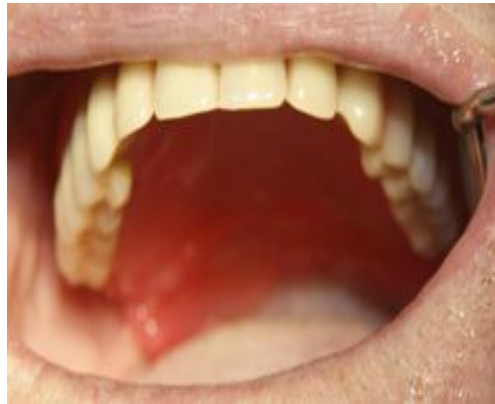- Clarify the patient's complaints;
- Check the accuracy of the dental handpiece;
- Fix the abrasive tool;
- Check the quality of fixation and centering of the abrasive tool;
- Check the uniformity of occlusal contacts of the dentitions in the central and functional occlusions with using articulation paper;
- The most intensely colored contact points are ground using a metal cutter, shape grinding diamond head.



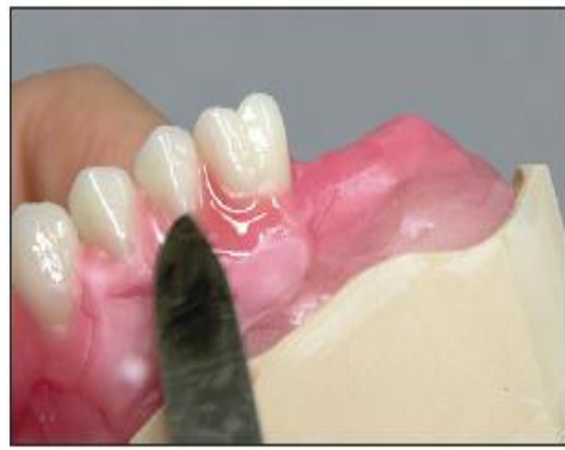
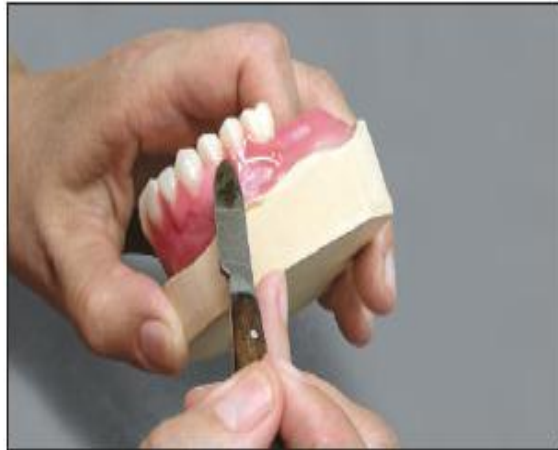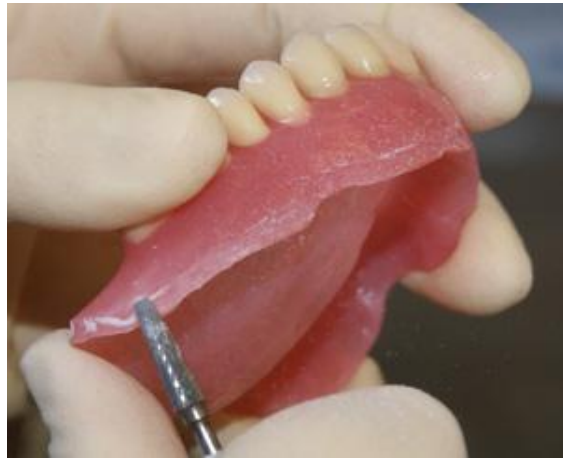- Manipulations are repeated several times;
- Painful places of the oral mucosa at the borders with the base of the denture are determined visually and by palpation using with dental mirror;



– Remove the prosthesis and specify the places of excess pressure of the base on the mucous membrane of the prosthetic seat area by using corrective paste, their topography on the inner surface of the base;



– Places of overpressure on the prosthetic seat area with the base are removed with the metal cutters and carborundum heads;



– Recommendations to the patient should be given verbally and also reinforced with a printed sheet on the denture using. Detailed advice on denture hygiene should be provided in compliance with the rules of oral hygiene and care of the prosthesis. The patient should be encouraged to clean all surfaces of the dentures thoroughly after every meal.

SPECIAL TRAINING TESTS. *Choose the correct answer*

1. A 43 years old man applied to the dental clinic for tooth prosthetics. Objectively: the crown of the 37th tooth is decayed by 2/3, buccal and lingual walls are thin. Occlusion picture shows strong contact with antagonists. How thick should be the layer of tooth surface that must be ground off during reparation for metallic stamped crown?
 - A. 0,28-0,3 mm
 - B. 0,1-0,2 mm
 - C. 0,5-0,6 mm
 - D. 0,6-0,7 mm
 - E. 0,7-0,8 mm

2. During lateral motions of a mandible frontal teeth are deviated. Sideward relocation of incisive point from the central position has an angle of 100–110°C. What is characterized by such value of incisive point deviation?
 - A. Lateral incisive tract
 - B. Lateral articulate tract
 - C. Sagittal incisive tract
 - D. Sagittal articulate tract
 - E. Bennett's angle

3. One of the methods to define central occlusion is to construct a flat that will go through cutting edges of central incisors and distalobuccal tubercles of last molar teeth providing that there is sufficient quantity of teeth. What flat should be constructed?
 - A. Occlusal flat
 - B. Sagittal
 - C. Vertical
 - D. Transversal
 - E. Frankfort

4. A patient came to a dental clinic for dental prosthetics. Objectively: total lack of teeth on the mandible. Sharp and regular atrophy of alveolar part. Frenula attachment and fold position is high. Name the type of atrophy of edentulous mandible using Keller's classification:
 - A. II type
 - B. I type
 - C. III type
 - D. IV type
 - E. V type

5. A 47-year-old patient consulted a dentist about dental cervix exposure on both jaws. Objectively: the dentitions are intact, the dental cervixes are exposed. Untimely teeth contacts are present. It is planned to perform selective grinding. What controlling method should be chosen?
- A. Occlusiography
 - B. Masticatiography
 - C. Chewing test
 - D. Roentgenography
 - E. Gnathodynamometry
6. A 40-year-old patient complains about frequent falling out of a filling. Objectively: the 46 tooth has a carious (Black's class II) cavity. It is planned to restore the anatomic form of the tooth by means of a metal inlay. What is the peculiarity of the cavity preparation for the inlay in this case?
- A. Forming a bevel
 - B. Forming an additional shoulder
 - C. Cavity floor widening
 - D. Preparation for parapulpal posts
 - E. Cavity deepening
7. A 56-year-old patient complains about missing lateral teeth on both sides of mandible. Objectively: the 48, 47, 46, 45, 35, 36, 37, 38 teeth are missing. Make a diagnosis:
- A. Kennedy I dentition defect
 - B. Kennedy IV dentition defect
 - C. Kennedy II dentition defect
 - D. Kennedy III dentition defect
 - E. Betelman II dentition defect
8. A patient ordered partial removable lamellar dentures for the upper and lower jaw. An orthodontist made elastic alginate impressions of both jaws. What is his next step?
- A. To send the impressions for disinfection
 - B. To let the impression dry out in the open air
 - C. To invite a dental mechanic for joint analysis of the impressions
 - D. To send the impressions immediately to the laboratory
 - E. To put the impressions into the microten bag for 90 minutes
9. A patient complains about a cosmetic defect of the 23 tooth. Objectively: the crown of the 23 tooth is decayed by 80%, the root is stable, and the canal is filled up to the top.

After examination it was decided to restore the decayed tooth with a cast stump inlay. The root canal of the 23 tooth should be broadened by:

- A. 2/3 of canal length
- B. 1/2 of canal length
- C. 1/3 of canal length
- D. 1/4 of canal length
- E. By the total canal length

10. A 38-year-old patient consulted an orthopedist about metal taste, dry mouth and tongue burning. Objectively: defects of the lower dental arch were replaced with soldered stainless steel bridges. What examination method would be the most appropriate in this case?

- A. Galvanometry
- B. Masticatiography
- C. Occlusiography
- D. Myography
- E. Electroodontometry

11. A 28-year-old patient complains about a cosmetic defect in the frontal part of his upper jaw. Objectively: the crown part of the 11 tooth is decayed below the gum level. The root is stable, percussion is painless. It is planned to restore the tooth with a stump inlay and cover it with a metal-ceramic crown. What additional method of diagnostics should be applied in this clinical situation?

- A. X-ray diagnostics
- B. Electromyography
- C. Masticatiography
- D. Gnathodynamometry
- E. Electroodontodiagnostics

12. Tooth replacement with complete removable dentures involves adjustment of occlusal relations by different movements of the lower jaw. Transversal movements of the lower jaw are initiated by the following muscle:

- A. External (lateral) pterygoid muscle
- B. Internal (medial) pterygoid muscle
- C. Temporal muscle
- D. Mastication muscle
- E. Digastric muscle

13. A 24-year-old female patient complains about hard tissues defect of the 21 tooth. Objectively: the 21 tooth is destroyed by 1/3 along the cutting edge, it is changed in color. X-ray picture shows that the root canal is filled to the top. It was decided to fabricate a plastic crown. Where should the crown edge be situated against the marginal gingiva?
- A. At a level with gingiva
 - B. 0,5 mm away of gingiva
 - C. 1,0 mm away of gingiva
 - D. 0,5 mm below the gingiva
 - E. 1,0 mm below the gingival
14. A 70-year-old male patient complains about total teeth missing on both jaws. It is planned to fabricate complete removable lower jaw prosthesis. Objectively: alveolar process of the lower jaw is atrophied only in the frontal aspect. Identify the type of lower jaw atrophy according to Keller's classification:
- A. IV
 - B. II
 - C. I
 - D. III
 - E. –
15. A 35-year-old patient has teeth mobility of I degree, the teeth have apparent dental cusps. The dentist recommends to do occlusive teeth grinding. What method is the most objective for determining the grinding topography?
- A. Occlusiography
 - B. Masticatiography
 - C. Roentgenography
 - D. Gnathodynamometry
 - E. Rubinov's masticatory test
16. A patient ordered soldered stainless-steel bridge prostheses. Their fabrication involves calibration of crown sleeves. Which device is used for this purpose?
- A. Samson
 - B. Parker's
 - C. Larin's
 - D. Cope's
 - E. Bromshtrom
17. A 47-year-old patient complains about discoloration of the 11, 12 teeth. Objectively: the 12, 12 are changed in color, canals are filled to the top. It was decided to make metal-

ceramic crowns for the 11, 12 teeth. What is the optimal angle for the preparation of approximal surfaces of abutment teeth?

- A. 5-8 degrees
- B. 15-20 degrees
- C. 10-15 degrees
- D. 20-25 degrees
- E. 30-35 degrees

18. Examination of a 25-year-old male patient revealed maximal number of occlusional contacts of opposing teeth during denture joining. X-ray picture shows that the articular head of the lower jaw is near the base of the slope of articular tubercle. What type of occlusion is present?

- A. Central occlusion
- B. Anterior occlusion
- C. Right lateral occlusion
- D. Left lateral occlusion
- E. Posterior occlusion

19. A 32-year-old female patient complains about a cosmetic defect of the 14, 25 teeth. It is planned to make metal-ceramic crowns. What impression material should be used for making these crowns?

- A. Silicone
- B. Hardening
- C. Wax
- D. Alginate
- E. Zinc oxide eugenol

20. A 45-year-old patient complains of burning tongue, a metallic taste in mouth. Three months ago she got a dental bridge made of gold and supported by the 16, 14 teeth. Oral cavity examination reveals no objective changes. The 36, 37, 46 teeth are sealed with amalgam fillings. What is the most likely cause of this condition?

- A. Galvanic currents
- B. Allergy
- C. Neurologic disorder
- D. Chemical factors
- E. Mechanic trauma

21. A 26-year-old patient presented at a clinic for prosthetics. Objectively: the crown of the 16 tooth is destroyed by 1/3. It is planned to restore its anatomical shape with a metal inlay. What is the first stage of cavity preparation?
- A. Cavity widening and necrosectomy
 - B. Making additional cavities
 - C. Beveling
 - D. Completing the cavity floor
 - E. Completing the cavity walls
22. A 70-year-old patient complains of inability to take food, a cosmetic and phonetic defect due to the complete loss of mandibular teeth. Objectively: the lateral segment of the alveolar process of the mandible is significantly atrophied, while the frontal segment is relatively preserved. Buccal folds are attached at the crest of the alveolar process. These clinical presentations correspond with the following class of edentulous jaws according to Keller classification:
- A. Class III
 - B. Class IV
 - C. Class II
 - D. Class V
 - E. Class I
23. Prior to installation of complete removable dentures, it is necessary to verify the occlusal relation with different movements of the mandible. What muscle is responsible for transversal movements of the mandible?
- A. Outer (lateral) pterygopalatine
 - B. Masticatory
 - C. Digastric
 - D. Inner (medial) pterygopalatine
 - E. Temporal
24. A 53-year-old male patient has a history of generalized periodontitis. It is planned to fabricate fixed splints for both jaws intended to stabilize the teeth along the entire dental arch. Which of the maxillary pillars will have the functional significance for the distribution of masticating pressure?
- A. Frontonasal, zygomatic, pterygopalatine, palatine
 - B. Frontonasal, pterygoid, palatine
 - C. Zygomatic, pterygoid, palatine
 - D. Frontonasal, zygomatic, palatine
 - E. Frontonasal, zygomatic, pterygopalatine

25. Objective examination of a 67-year-old patient with the edentulous maxilla revealed minor uniform atrophy of the alveolar processes. Maxillary prominences were well preserved, the frenulum and bucco-alveolar folds were attached at the base of the alveolar process, the palate was deep, and the torus palatinus was expressed insignificantly. These clinical presentations correspond with the following class of atrophy according to Schroeder classification:

- A. 1
- B. 5
- C. 2
- D. 4
- E. 3

26. A 34-year-old female patient presented to a dental clinic for the prosthetics of the mandibular teeth. Objectively: the mandibular teeth exhibit the I-II class mobility. Which of the following examination methods should be applied?

- A. Radiography
- B. Rheotachygraphy
- C. Face-bow record
- D. Galvanometry
- E. Myotonometry

27. A 43-year-old male patient awaits fabrication of full swaged crowns for the 26 and 27 teeth. What material should be used for the dental dies?

- A. Low-fusible alloy
- B. Stainless steel
- C. Silver-palladium alloy
- D. Cobalt-chromium alloy
- E. Solder alloy

28. A 44-year-old male patient needs a cast splint for the mandible. Objectively: there is a bilateral terminal defect of the mandibular dental arch. The tooth crowns are high, the teeth are intact, and there is I-II class mobility. What impression material should be used?

- A. Stomalgin
- B. Gypsum
- C. Stens
- D. Dentafol
- E. Repin

29. A 65-year-old female patient complains of complete edentulousness. Examination of the oral cavity revealed that alveolar process of the edentulous mandible was markedly atrophied in the frontal region, while it was expressed in the distal region. Specify the class of atrophy according to Keller classification:
- A. Class IV
 - B. Class II
 - C. Class III
 - D. Class I and III
 - E. Class I
30. A 44-year-old female patient presented to a dental clinic for prosthetics. Objectively: the 17, 16, 15, 14, 12, 25, 26 teeth are missing; the 18, 28 teeth are preserved. Make a diagnosis according to Kennedy classification of partial edentulousness:
- A. Class III subclass 2
 - B. Class II, subclass 4
 - C. Class III, subclass 1
 - D. Class III, subclass 3
 - E. Class II, subclass 2
31. A month after cementing a porcelain- fused-to-metal crown for the 23 tooth, the patient complained of its decementation. On examination the tooth stump was of sufficient height, the stump walls were convergent to the vertical axis at an angle of about 30degrees. What is the required angle of wall convergence?
- A. Up to 8 degrees
 - B. 20-25 degrees
 - C. 27-35 degrees
 - D. 25-30 degrees
32. 18-20 degrees A removable denture is being made for a patient. At the stage of designinig the denture accessory material "Isocol" is used. What group does it belong to?
- A. Insulation
 - B. Polishing
 - C. Modeling
 - D. Forming
 - E. Impression
33. A woman with complaints of restricted mouth opening has made an appointment with a prosthodontic clinic. What muscles are responsible for the downwards movement of the lower jaw?

- A. Mylohyoid muscle, digastric muscle, geniohyoid muscle
- B. Orbicular muscle of mouth, mylohyoid muscle
- C. Temporal muscle, lateral pterygoid muscle, digastric muscle.
- D. Geniohyoid muscle, medial pterygoid muscle

34. Masticatory muscle, medial pterygoid muscle An 18-year-old student needs prosthetic porcelain-fused-to-metal denture for the 11, 21 teeth. There are no contraindications for the use of such construction. What is the most appropriate material for taking impressions?

- A. Sielast
- B. Repin
- C. Orthocor
- D. Stomalgin
- E. Stens

35. A 26-year-old patient needs an inlay for a class V cavity of the 35 tooth. During the cavity preparation a prosthodontist has accidentally opened the pulp. What might be the most probable cause of this complication?

- A. Forming a flat floor
- B. Forming divergent walls
- C. Forming convergent walls
- D. Forming a bevel
- E. Absence of an additional cavity

36. A 18-year-old female patient ordered a metal-ceramic crown for the 24 tooth. It is necessary to choose an optimal impression material for combined impression of the upper jaw. What material should be used for a preliminary impression?

- A. Stens
- B. Dentafol
- C. Orthocar
- D. Wax
- E. Protacryl

37. A 73-year-old patient consults a dental orthopedist about total edentia. Objectively: there is insignificant regular atrophy of the alveolar process of mandible, the process is covered with mucous membrane of moderate elasticity. According to Keller's classification, such manifestations are characteristic for the following type of edentulous jaw:

- A. First
- B. Third

- C. Fifth
- D. Second
- E. Fourth

37. An 18-year-old student needs prosthetic metal-ceramic denture for the 11, 21 teeth. There are no contraindications for the use of such construction. What is the most appropriate material for taking impressions?

- A. Sielast
- B. Stomalgin
- C. Orthocor
- D. Stens
- E. Repin

38. A 32-year-old female patient needs dental prosthetics. After the objective examination it was decided to use ceramic-metal crown. What impression material should be used for taking impressions for this construction?

- A. Stomaflex
- B. Plaster
- C. Stomalgin
- D. Stens
- E. Orthocor

39. A 29-year-old female patient presented to a dental clinic for prosthetics. Objectively: there is a carious cavity on the masticatory and mesial surfaces of the 24 tooth. Interdental contact is inadequate. Classify this cavity according to Black's classification:

- A. II
- B. I
- C. IV
- D. III
- E. V

40. A 45-year-old patient presented to a prosthodontics clinic. During the objective examination the doctor checked the sagittal movements of the lower jaw. What muscles are responsible for sagittal movements of the lower jaw?

- A. Lateral pterygoid muscles
- B. Medial pterygoid muscles
- C. Mandibulohyoid muscle
- D. Digastric muscle
- E. Mentohyoid muscle

Notes

Color edition of the textbook published by the personal funds of the authors