

UDC 611.611 – 053.88/9

D. G. Shuha
Kharkiv National Medical University

MORPHOMETRIC CHARACTERISTICS OF THE RENAL PYRAMIDS OF THE HUMAN KIDNEY INFERIOR EXTREMITY, CONSISTING OF TWO EXCRETORY SECTORS

On the topographical sections 89 human kidneys studied the morphological characteristics of the renal pyramids of the lower end of the kidney. The data obtained can be used in operational nephrology for developing new methods of organ interventions on the kidney.

Key words: kidney, kidney pyramid, individual anatomical variability.

The work is done in accordance with the scientific theme: "Anatomy of the human kidney applied to minimally invasive surgical interventions"; the state registration number: 0109U001746.

Currently available information about the structure of human kidneys reflect different aspects of their morphology at macro and micro structural level [1, 2, 3, 6]. However, many important questions, devoted to the anatomy of renal parenchyma and individual human renal pyramids, are still not completely reflected in scientific literature devoted to nephrology surgical practice [3, 5, 7]. The inferior extremity of the kidney is of particular interest in surgical nephrourology, as it requires some surgical intervention most of all. This study aims to contribute on creation of the anatomical basis for the development of modern organ operations techniques on the kidney.

The aim was to study the features of individual anatomical variability on renal pyramids sections of the kidney inferior extremity at mature people and the elderly.

As a research material were used obtained with a macrotom topographical sections of 89 human kidney inferior extremities, distributed by age groups, in each of which we have studied a number of renal pyramids, their topography and morphometric characteristics.

Morphometric characteristics of renal inferior extremity pyramids consisting of two excretory sectors are displayed in table 1.

Table 1

The number and morphometric characteristics of the renal inferior extremity pyramids of the two sector kidney

Pyramid	N	Base diameter (mm)			Height (mm)			Volume (mm ³)		
		average	min	max	average	min	max	average	min	max
PR i	37	14,33	3,7	26,6	12,74	4	24	1202,26	42	4095,5
PR ipl	35	14,75	6,2	23,5	14,75	6,2	24	1724,21	55,7	4478,0
PR ips	12	8,84	3,4	18,3	8,94	4	18,5	392,21	27	1436,7
PR ipm	34	11,19	5	21,1	11,24	5	20	941,66	45	3166,4
PR ial	35	14,32	6	23	14,37	7	23	1777,58	54,6	5501,1
PR ias	14	9,66	6	17	9,94	6	18	533,54	106,2	1646,0
PR iam	38	13,09	5	29,7	12,93	5	29,7	1207,97	44,4	5775
onli	205	13,1	3,4	29,7	12,71	4	29,7	1254,35	27	5775,0

The largest average base diameter of renal pyramids in the kidney inferior extremity including two excretory sectors defined in the lower posterolateral pyramid (PRipl) is 14,75 mm and the smallest in the lower posteromedial pyramid (PRips) is 8,84 mm.

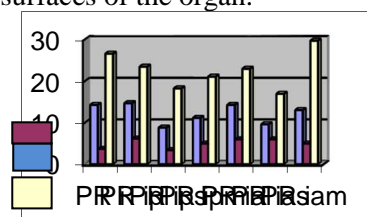
It should be noted that the two mentioned renal pyramids are arranged on the rear surface of the inferior extremity of the kidneys. The absolute minimum value and the base diameter of the renal pyramids belong to the same surface of the kidneys. Thus, the minimum diameter of the smallest foundation, we have identified in the lower the posterior-median pyramid (PRips), is 3,4 mm and the highest minimum diameter of 6.2 mm is defined in the lower posterolateral (PRipl) pyramid.

We measured the height of the inferior extremity pyramids all of the kidneys having two excretory sector. The lowest average height we noted in the lower anteromedian pyramid (PRias) on the front surface, and at the lower posterior median pyramid (PRips) on the rear surface of the organ it is 9.94 mm and 8.94 mm accordingly.

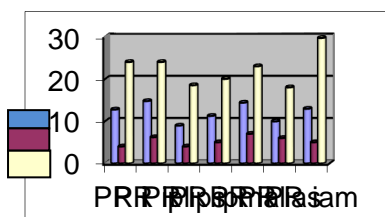
The largest average height is revealed in the lower lateral pyramids on both (front and back) surfaces of inferior extremity of the kidneys and is 14.37 mm and 14.75 mm accordingly. The smallest absolute value of the height belongs to two pyramids: the lower renal pyramid (PRi) and the lower

posterolateral pyramid (PRipl) 4 mm, and the highest minimum belongs to the lower anterolateral pyramid (PRial) 7 mm. The maximum height indexes of the inferior extremity pyramids of the kidney are reasonably expressed. Thus, the height of the lower anteromedian renal pyramids (PRias) is 18 mm and the height of the lower anteromedial pyramid (PRiam) is 29 mm.

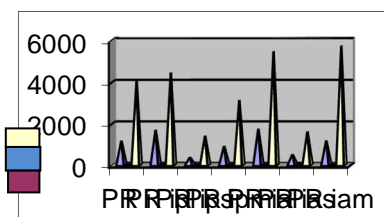
It should also be noted that the values of the pyramids height on the front surface of the inferior extremity of the kidney predominate over those on the rear surface of the organ inferior extremity. The pyramid inferior extremity volume of the two sector kidney also varies quite clearly. The average volume of the lower posterior median pyramid (PRips) is 392.21 mm³, while the average volume of the lower anterolateral pyramid (PRial) exceeds it about three times and is 1777.58 mm³. Noteworthy is the fact that in the two-sector kidney the lowest average volumes of the pyramids both on the front and on the rear surfaces belong to the lower anteromedian renal pyramid (PRias) and to the lower posterior-median pyramid (PRips), and the highest average volumes of the pyramids in the kidney inferior extremity we noted at the lower posterolateral pyramid (PRipl) and the lower anterolateral pyramid (PRial) on both surfaces of the organ.



an average index; a minimum figure; a maximum figure; Picture. 1. Histograms: base diameters of the renal pyramids in the inferior extremity of the kidneys, including two excretory sectors.



an average index; a minimum figure; a maximum figure; Picture 2. Histograms: indicators of renal pyramids heights of the kidneys inferior extremity, including two excretory sectors.



an average index; a minimum figure; a maximum figure; Picture 3. Histograms: volumes of the renal pyramids of the kidney inferior extremity, including two excretory sectors.

This suggests a redistribution of the renal parenchyma in the development process to the lateral surfaces of the organ on both surfaces thereof. At the same time, we noticed that the lower anteromedian renal pyramid (PRias) has the smallest gap between minimum and maximum volume figures (106.2 mm³ and 1646 mm³, accordingly). The difference between the minimum and the maximum figures of the other inferior extremity pyramids is much more expressed.

Thus, the minimum volume of the lower anteromedial pyramid (PRiam) is 44.4 mm³, and the maximum is 5775.0 mm³. The smallest minimum volume identified in the lower posterior median pyramid (PRips) is 27,0 mm³, to it also belongs the smallest maximum amount of 1436.7 mm³, that in spite of small volume indexes of the pyramid shows its stable presence in the two sector kidney inferior extremity.

Summary

1. The total pyramids volume of the front surface of the kidney inferior extremity which excretory tree contains two excretory sectors is more than the total volume of the pyramids located on the rear surface of the inferior extremity of such organ.
2. The largest by volume are lateral pyramids on both surfaces, the volume of the anterolateral pyramid (PRial) is more than the volume of the posterolateral pyramid (PRipl).

Literature

1. Burykh M. P. Surgical anatomy of the lower segment of the human kidney / M. P. Burykh // Materials for the macro-microscopic anatomy. - Kharkiv, - 1976. P. 65-66.
2. Burykh M. P. Pyramid pyelocaliceal system of kidneys of newborns / M. P. Burykh // Actual problems of morphology: II Congress of anat., gistol., embryologists, topographic anatomists. USSR: mes. of reports. - Poltava, - 1985. 34 p.
3. Burykh M. P. Stereotopometry of pyelocaliceal complex of human kidney used in organ preserving surgery / M. P. Burykh // Archive of anat., gistol. and embryology, - 1988. - № 4. P. 69-74.
4. Dgebuadze M. A. Comparative analysis of the age kidneys morphological changes in the experiment / M. A. Dgebuadze, R. G. Khetsuriani // Morphology. - 2004. T. 126, № 4. 40-43.
5. Lopatcin N.A. Long term survival rates of patients with renal tumors. Nephron sparing surgery in open nephrostomy / N.A. Lopatcin // – European Urology XIV Congress of the European Association of Urology. April 7-11, - 1999, Stockholm, - 85 p.
6. Stabredov A. V. Kidney volume change in prenatal and early postnatal ontogenesis / A. V. Stabredov, I. A. Usmanov // Morphology. - 2008. T. 133, № 2. 128.
7. Trofimov I. A. Transdermal puncture radiographic endourological intervention onto the upper urinary tracts at oncologic patients / I. A. Trofimov, B. I. Dolgushin // Medical imaging. - 2002. - № 1. P. 91-99.

Реферати

**МОРФОМЕТРИЧЕСКИЕ ХАРАКТЕРИСТИКИ
ПОЧЕЧНЫХ ПИРАМИД НИЖНЕГО КОНЦА ПОЧКИ
ЧЕЛОВЕКА, СОСТОЯЩЕЙ ИЗ ДВУХ
ЭКСКРЕТОРНЫХ СЕКТОРОВ**

Шуба Д. Г.

На топографических срезах 89 почек человека изучены морфометрические характеристики почечных пирамид нижнего конца почки. Полученные данные могут быть использованы в оперативной нефрологии для разработки новых методик органосохраняющих вмешательств на почке.

Ключевые слова: почка, почечные пирамиды, индивидуальная анатомическая изменчивость.

Статья надійшла 6.03.2015 р.

**МОРФОМЕТРИЧНІ ХАРАКТЕРИСТИКИ
НИРКОВИХ ПІРАМІД НИЖНЬОГО КІНЦЯ
НИРКИ ЛЮДИНИ, ЩО СКЛАДАЄТЬСЯ З ДВОХ
ЕКСКРЕТОРНИХ СЕКТОРІВ**

Шуба Д. Г.

На топографічних зрізах 89 нирок людини вивчені морфологічні характеристики ниркових пірамід нижнього кінця нирки. Отримані дані можуть бути використані в оперативній нефрології для розробки нових методик органозберігаючих втручань на нирці.

Ключові слова: нирка, ниркові піраміди, індивідуальна анатомічна мінливість.

Рецензент Волошин М.А.