

AZƏRBAYCAN RESPUBLİKASI SƏHIYYƏ NAZİRLİYİ

AZƏRBAYCAN
TİBB JURNALI



AZERBAIJAN MEDICAL JOURNAL
АЗЕРБАЙДЖАНСКИЙ МЕДИЦИНСКИЙ ЖУРНАЛ

Rüblük elmi-praktik jurnal 2023, № 3

1925-ci ildən nəşr edilir

REDAKSİYA HEYƏTİ

Rafiq Məmməd həsənov (*baş redaktor*)

Fuad İslamzadə (*baş redaktor müavini*)

Cəmil Əliyev, Elmar Qasimov,
Əhliman Əmiraslanov, İvan Dedov, Mehmet Haberal

EDITORIAL STAFF

Rafiq Mammadhasanov (*Editor-in-Chief*)

Fuad Islamzada (*Deputy Editor-in-Chief*)

Ahliman Amiraslanov, Elmar Gasimov,
Jamil Aliyev, Ivan Dedov, Mehmet Haberal

BAKI

REDAKSIYA ŞURASI

Adil Baxşəliyev (Bakı, Azərbaycan)
Amaliya Əyyubova (Bakı, Azərbaycan)
Cəbrayıl Məmmədov (Bakı, Azərbaycan)
David Virsaladze (Tbilisi, Gürcüstan)
Əlihüseyn Hidayətov (Bakı, Azərbaycan)
Əzizağa Talışinski (Bakı, Azərbaycan)
Fariz Babayev (Bakı, Azərbaycan)
Məmməd Nəsirov (Bakı, Azərbaycan)
Nadejda Demixova (Sumı, Ukrayna)
Niyazi Novruzov (Naxçıvan, Azərbaycan)
Paşa Musayev (Bakı, Azərbaycan)
Rauf Şahbazov (Sirakuz, ABŞ)
Rəna Şirəliyeva (Bakı, Azərbaycan)
Rizvan Abdullayev (Xarkov, Ukrayna)
Sabir Əliyev (Bakı, Azərbaycan)
Mansur Bünyatov (Bakı, Azərbaycan)
Vaqif Şadlinski (Bakı, Azərbaycan)
Valentin Fadeyev (Moskva, Rusiya)
Yaqub Qurbanov (Bakı, Azərbaycan)

EDITORIAL BOARD

Adil Bakhshaliyev (Baku, Azerbaijan)
Amaliya Ayyubova (Baku, Azerbaijan)
Jabrail Mammadov (Baku, Azerbaijan)
David Virsaladze (Tbilisi, Georgia)
Alihuseyn Hidayatov (Baku, Azerbaijan)
Azizagha Talishinskiy (Baku, Azerbaijan)
Fariz Babayev (Baku, Azerbaijan)
Mammad Nasirov (Baku, Azerbaijan)
Nadiia Demikhova (Sumy, Ukraine)
Niyazi Novruzov (Nakhchivan, Azerbaijan)
Pasha Musayev (Baku, Azerbaijan)
Rauf Shahbazov (Syracuse, USA)
Rana Shiraliyeva (Baku, Azerbaijan)
Rizvan Abdullayev (Kharkiv, Ukraine)
Sabir Aliyev (Baku, Azerbaijan)
Mansur Bunyatov (Baku, Azerbaijan)
Vagif Shadlinski (Baku, Azerbaijan)
Valentin Fadeyev (Moscow, Russia)
Yagub Gurbanov (Baku, Azerbaijan)

Azərbaycan Respublikası
Mətbuat və İnformasiya Nazirliyində
qeydə alınmışdır. Şəhadətnamə №354

Redaksiyanın ünvanı: Azərbaycan,
Bakı-AZ1122, H.Zərdabi küç., 96

ISSN 0005-2523

№ k: (+99450) 371-66-04

E-mail: tibbjurnali@gmail.com

www.azmedjournal.com

Azərbaycan Tibb Jurnalında
dərc olunan məqalələr haqqında
Elsevier EMBASE
(Excerpta Medica), SCOPUS və
eLIBRARY.RU
bibliyoqrafik dərgilərində
məlumat verilir

İÇİNDƏKİLƏR

KLİNİK TƏDQIQATLAR

A.Ə.Abdullayeva

Hiss dəstəsinin sağ ayaqçığının idiopatik blokadası olan uşaqlarda ürək ritminin variabelliyyəsinin dövrü parametrləri

R.Y.Abdullayev, V.A.Kapustnik, V.D.Markovski, F.İ.Kulikova, A.Q.Kiriçenko, N.V.Tomax

Gecikmiş postinfarkt dövrədə ürəyin remodelləşməsinin xüsusiyyətləri

Y.İ.Bayramov

Tam çıxarılan lövhəli protezlərin funksionallığının müqayisəli qiymətləndirilməsi

O.S.Çinyak, O.İ.Kolenko, İ.Q.Mudrenko, V.S.Liçko, A.A.Demixov, N.V.Demixova

Müxtəlif variantlı demensiyası olan xəstələrdə baş beyinin funksional vəziyyəti və gecə pozuntularının xüsusiyyətləri

S.O.Dubina, S.İ.Serbin, S.V.Bondarenko, S.İ.Daniçenko, B.N.Filenko, M.N.Koptev, A.V.Piroq-Zakaznikova

Yaşlı insanlarda göz yuvasının morfometrik göstəricilərinin kompüter-tomografiya vasitəsilə qiymətləndirilməsi

O.V.Koval, O.V.Şerbina, M.N.Zhaivoronok, T.A.Dudnik, L.N.Vasko

Yoğun bağırsağ şişlərinin diaqnostikasında virtual kolonoskopiyanın və ultrasəs müayinəsinin imkanları

C.P.İsayev, H.H.Məmmədova

Koronavirus infeksiyasının hematoloji əlamətlərinin xəstəliyin ağırlıq dərəcəsindən asılılığı

İ.V.Korpusenko, N.N.Nor, V.P.Krişen, N.V.Trofimov, B.E.Kudryavtseva, B.V.Quzenko, A.N.Makarenko, A.N.Kiriçenko

Xronik xoraların vakuüm-terapiya üsulu ilə müalicəsinin klinik-immunoloji aspektləri

K.V.Qarkavenko, V.V.Lazurenko, R.Y.Abdullayev, V.Q.Karpenko, İ.A.Vasilyeva, N.M.Pasiasvili

Ekstragenital patolojiya fonunda anomal uşaqlıq qanaxmaları olan qadınlarda endometriyumun ultrasəs keçiriciliyyəsinin xüsusiyyətləri

S.Q.Quliyeva

Uşaqlarda diş sırasının II sinif sagittal anomaliyalarının yaranmasının etioloji faktorları

N.F.Lətifova, İ.C.Şahverdiyeva, G.R.Vahabova, S.R.Quliyeva, D.M.Əliyeva

Şəkərli diabet fonunda ağırlaşan müxtəlif böyrək patologiyaları zamanı qan serumunda L-FABP və katelisidin səviyyəsi

V.B.Nəzirova, T.V.Mehdiyev, F.Ə.Quliyev

Arterial hipertenziyalı xəstələrdə β -fibrinogen G/A-455 geni polimorfizminin lipid mübadiləsi göstəriciləri ilə assosiasiyası

X.Q.Quliyeva

Koronavirus infeksiyasının hamiləliyin və doğuşun gedişinə, ananın, dölün və yenidoğulmuşun vəziyyətinə təsiri

T.M.Musayeva

Ürəyin işemik xəstəliyi zamanı tətbiq edilən kardioreabilitasiya tədbirlərinin endotelin funksiyasına təsiri

C O N T E N T S

CLINICAL RESEARCH

5 A.A.Abdullayeva

Periodic parameters of heart rhythm variability in children with ideopathic right bundle branch block

9 R.Ya.Abdullaiev, V.A.Kapustnik, V.D.Markovsky, F.I.Kulikova, A.G.Kyrychenko, N.V.Tomakh

Characteristics of late post-infarction cardiac remodeling

15 Y.I.Bayramov

Comparative assessment of the functionality of fully removable plated dentures

23 O.S.Chyniak, O.I.Kolenko, I.H.Mudrenko, V.S.Lychko, A.A.Demikhov, N.V.Demikhova

The functional state of the brain according to these neurophysiological methods of study and features of night disorders in patients with various variants of dementia

32 S.O.Dubyna, S.I.Serbin, S.V.Bondarenko, S.I.Danylchenko, B.N.Fylenko, M.N.Koptev, A.V.Pyrog-Zakaznikova

Morphometric characteristics of the orbit in adults

39 O.V. Koval, O.V.Shcherbina, M.M.Zhaivoronok, T.A.Dudnik, L.N.Vasko

Possibilities of virtual colonoscopy and ultrasonography in the diagnosis of colon tumors

46 J.P.Isayev, H.H.Mammadova

Dependence of hematological symptoms of coronavirus infection on the severity of the disease

51 I.V.Korpusenko, N.N.Nor, V.P.Kryshen,

N.V.Trofimov, V.E.Kudryavtseva, B.V.Guzenko, A.N.Makarenko, A.N.Kyrychenko

Clinical and immunological aspects of the treatment of chronic wounds using VAC-therapy

58 K.V.Garkavenko, V.V.Lazurenko, R.Ya.Abdullaev, I.A.Vasilyeva, V.G.Karpenko, N.M.Pasieshvili

Ultrasound features of the endometrium in women with abnormal uterine bleeding on the background of extragenital pathology

65 S.G.Guliyeva

Etiological factors are leading to the formation of Sagittal anomalies in schoolchildren studied 2nd class

71 N.F.Latifova, I.J.Shahverdiyeva, G.R.Vahabova, S.R.Guliyeva, D.M.Aliyeva

Serum levels of L-FABP and cathelicidin as diagnostic markers for kidney pathologies in diabetic patients

75 V.B. Nazirova, T.V.Mehdiyev, F.A.Guliyev

Association of the β -fibrinogen G/A-455 polymorphism with lipid metabolism in patients with arterial hypertension

81 K.G.Guliyeva

The impact of acute coronavirus infection on the course of pregnancy, childbirth, the condition of the mother, fetus and newborn

86 T.M.Musayeva

The impact of cardiac rehabilitation on endothelial dysfunction in coronary artery disease

DOI: 10.34921/amj.2023.3.009

K.V.Qarkavenko¹, V.V.Lazurenko¹, R.Y.Abdullayev¹,
V.Q.Karpenko¹, İ.A.Vasilyeva², N.M.Pasiaşvili³

EKSTRAGENİTAL PATOLOGIYA FONUNDA ANOMAL UŞAQLIQ QANAXMALARI OLAN QADINLARDA ENDOMETRİUMUN ULTRASƏS KEÇİRİCİLİYİNİN XÜSUSİYYƏTLƏRİ

¹Xarkov Milli Tibb Universiteti, ²V.N.Karazin adına Xarkov Milli Universiteti,

³Xarkov Vilayət Klinik Perinatal Mərkəzi, Xarkov, Ukrayna

Məqalədə yaşı 40-dan 55-ə qədər olan və anomol uşaqlıq qanaxmaları (AUQ) müşahidə edilən 45 qadının uşaqlıq damarlarının dopplerometriyasından alınan nəticələr təqdim edilmişdir. Onlardan 25 nəfərdə qanaxmalar metabolik sindrom (MS) fonunda olmuş (əsas qrup), 20 qadında isə MS olmamışdır (müqayisə qrupu). Kontrol qrupuna normal aybaşı tsikli olan 20 qadın daxil edilmişdir. Xəstə qadınların hamısında həkimə müraciət etdiyi ilk gündə uşaqlıq və uşaqlıq artımlarının ultrasəs müayinəsi (USM) aparılmışdır. Kontrol qrupda isə qadınlar aybaşı tsiklinin 5-8-ci gününü USM edilmişdir. MS fonunda AUQ olan pasiyentlərdə uşaqlıq divarının qalınlığının kontrol qrupu ilə müqayisədə 3 dəfə, həcmnin isə 1,6 dəfə çox olduğu aşkara çıxmışdır ($p < 0,05$), yalnız AUQ olan pasiyentlər qrupundan 7 nəfərdə (35 %) uşaqlığın boşluğunda polipəbənzər törəmələr aşkar edilmişdir; MS-lə birgə AUQ olan qadınlardan isə yalnız 3 nəfərdə (15 %) belə dəyişiklik nəzərə çarpmışdır. Müəyyən edilmişdir ki, AUQ olan qadınların radial və bazal arteriyalarında rezistentlik indeksi kontrol qrupdakına nisbətən aşkar şəkildə ($p < 0,05$) azalmışdır. MS fonunda AUQ olan qadınlarda endometriyumun qalınlığı və həcmi statistik etibarlı şəkildə artmışdır.

Tədqiqatın nəticələri göstərir ki, metabolik sindrom endometriyum hiperplaziyasının inkişafına səbəb olan əsas amillərdən biri olub, uşaqlıq qanaxmalarının törənməsinə şərait yaradır. Ultrasəs dopplerometriyası bu qadınlarda damar müqavimətinin azaldığını müəyyən etməyə imkan verir.

Açar sözlər: anomol uşaqlıq qanaxması, metabolik sindrom, ultrasəs müayinəsi

Ключевые слова: аномальные маточные кровотечения, метаболический синдром, ультразвуковое исследование

Key words: abnormal uterine bleeding, metabolic syndrome, ultrasound

K.V.Garkavenko¹, V.V.Lazurenko¹, R.Ya.Abdullaev¹,
İ.A.Vasilyeva², V.G.Karpenko¹, N.M. Pasiëshvili³

ULTRASOUND FEATURES OF THE ENDOMETRIUM IN WOMEN WITH ABNORMAL UTERINE BLEEDING ON THE BACKGROUND OF EXTRAGENITAL PATHOLOGY

¹Kharkov National Medical University, Ukraine

²Kharkov National University named after V.N. Karazin, Ukraine

³Kharkiv Regional Clinical Perinatal Center, Ukraine

The article presents the results of dopplerometry of the uterine vessels in 45 women aged 40-55 years with abnormal uterine bleeding (AUB) – in 25 of them against the background of the metabolic syndrome (MS), which made up the main group and in 20 without MS (comparative group). The control group consisted of 20 women with a normal menstrual cycle. All women with AUB underwent ultrasound of the uterus and appendages on the day of treatment, and women in the control group – on the 5-8th day of the menstrual cycle. Ultrasound in patients with AUB against the background of MS revealed a threefold increase in the thickness and 1.6 times in the volume of the endometrium compared with the control group ($p < 0.05$). The presence of polypoid formations in the uterine cavity was detected in 7 (35%) patients with AUB, in 3 (15%) women with AUB against the background of MS. It was found that in women with AUB,

compared with women in the control group, the indices of resistance ($P<0.05$) and pulsation ($P<0.001$) significantly decreased in the radial and basal arteries. In women with AUB against the background of MS, the thickness ($P<0.05$) and volume ($P<0.001$) of the endometrium significantly increased.

The results of the study show that the metabolic syndrome is one of the factors in the development of endometrial hyperplasia, which is the cause of abnormal uterine bleeding. Doppler ultrasound in these women reveals a significant decrease in vascular resistance.

The problem of abnormal uterine bleeding (AUB) occupies one of the leading places in gynecological practice, and the issue of optimizing the diagnosis of the causes of AUB in women with extragenital pathology remains an urgent task of modern gynecology [1, 2]. Among the extragenital diseases that have a pathogenetic significance in the development of AUB, the most common are obesity, diabetes mellitus, hypertension, dyslipidemia, the components of the so-called metabolic syndrome (MS) [3, 4].

Metabolic syndrome (Raven's syndrome or syndrome X, the "deadly quartet") is a pathogenetically interrelated metabolic disorders in one patient, which include obesity, hypertension, lipid metabolism disorders (hypertriglyceridemia, low high-density lipoprotein levels), insulin resistance or impaired tolerance, which is the main cause of type 2 diabetes mellitus [5]. MS has been called a pandemic of the 21st century, which attracts the attention of many researchers. It is known that the metabolic syndrome occurs in 60% of women of perimenopausal age and is a socially significant problem of modern society [6]. The prevalence of metabolic syndrome in the United States among women over 50 reaches 23.4%, which is due to the onset of menopause, excessive nutrition and insufficient physical activity. This mainly concerns people living in industrialized countries and leading a sedentary lifestyle [7]. It has been proven that the metabolic syndrome is associated with endothelial dysfunction and atherosclerosis. Visceral adipose tissue, rich in adipocytes, also has a great influence on the development of the metabolic syndrome [8]. Metabolic syndrome causes changes in the hypothalamic-pituitary-ovarian complex, which is manifested by symptoms of dyshormonal disorders of the reproductive system, including uterine bleeding. At least 20-30% of women with metabolic syndrome have menstrual irregularities, which is manifested by dysmenorrhea, AUB [3, 4, 9].

It is known that AUB is often caused by the development of endometrial hyperplasia, which occurs in 15-65% of gynecological diseases and in 20-30% turns into a malignant process [1, 10, 11]. Obesity and type 2 diabetes mellitus are considered risk factors for the development of endometrial hyperplasia; endometrial hyperplasia is observed in 70% of patients with metabolic syndrome [12-14].

Based on the above, optimization of the diagnosis of the state of the endometrium in patients with abnormal uterine bleeding and the most common extragenital pathology is an urgent task of modern gynecology.

The aim of the study was to evaluate the role of ultrasound and Doppler in the diagnosis of changes in the endometrium in women with abnormal uterine bleeding on the background of the metabolic syndrome.

Materials and methods. 65 women of late reproductive and perimenopausal age were examined, 45 (69.2%) of them with AUB, divided into 2 clinical groups: 25 women with AUB had signs of metabolic syndrome (main group), 20 women had only symptoms of AUB (group comparisons). The control group consisted of 20 (30.8%) women with a normal menstrual cycle.

The age of the patients ranged from 40 to 55 years, in the main group (MG) averaged 48.5 ± 3.6 years, in the comparison group – 44.3 ± 4.1 years, in the control group – 39.4 ± 5.5 years. Ten (40%) patients of the main group of the group had a history of untimely menarche, 13 (52%) had inflammatory diseases of the internal genital organs, and 5 (20%) had surgery for ovarian tumors. The body mass index in the main group was 34.5 ± 1.6 kg/m², in the comparison group – 27.1 ± 1.8 kg/m² ($p<0.05$). Waist circumference in the main group was 94.3 ± 2.7 cm, in the comparison group – 76.2 ± 3.1 cm ($p<0.05$). Obesity in the main group was noted in 19 (76%) patients, dyslipidemia in 6 (24%), arterial hypertension in 9 (36%), type 2 diabetes mellitus in 4 (16%) patients, respectively.

The diagnosis of metabolic syndrome was made in accordance with the criteria of WHO (1998) and the International Diabetes Federation (2005) with a combination of two of the following factors: the

presence of impaired glucose tolerance or insulin resistance of diabetes mellitus, increased blood pressure (140/90 mm Hg. Art.), impaired fat metabolism (triglycerides > 1.7 mmol / l or 150 mg / dl) and / or high-density lipoproteins (HDL) <1.0 mmol / l (39 mg / dl); abdominal obesity (waist/hip ratio >0.85 or body mass index >30 kg/m²), microalbuminuria (urinary albumin excretion >20 µg/min or albumin/creatinine ratio >30 mg/g [5, 7].

Examination of patients included general clinical, laboratory and instrumental studies, consultations of a therapist, an endocrinologist. Doppler ultrasound of the uterus and appendages was performed on a Toshiba (Canon) Xario 200 device using transabdominal (PVU-375BT, 3.6-9.2 MHz/convex) and transvaginal (PVU-781V convex) transducers. Hysteroscopy was performed using a hysteroscopescope Karl Storz (Germany), histological examination of the endometrium was carried out in the pathoanatomical department of the regional clinical hospital. Statistical processing was carried out using the methods of variation statistics (the arithmetic mean (M), standard deviation and errors of the mean (m) were calculated, the study groups were compared using the Student's t test (t), p<0.05 was taken as the level of statistical significance) with application of the program "Statistica 6.0".

Results of the study and their discussion.

Ultrasound of the internal genital organs in the Doppler mode was performed for all patients with AUB on the day of treatment, and for women in the control group - on the 5-8th day of the menstrual cycle. In the main group, endometrial hyperplasia was predominant, in the comparison group - endometrial polyps.

The position of the uterus in anteflexio was noted in 16 (64%) women in the main group, in 18 (90%) women in the comparison group, and also in all women in the control group (p<0.05). Asymmetry in the thickness of the anterior and

posterior walls of the uterus was observed in 5 (20%) patients of the main group and in 3 (15%) patients of the comparison group. M-echo thickness > 12 mm with increased echogenicity of the endometrium and the presence of hyperechoic inclusions was recorded in 20 (80%) women of the main group and 12 (60%) women of the comparison group (p<0.05), which had clinical signs of uterine bleeding.

On ultrasound, the average thickness of the M-echo in patients of the main group (AMU + MS) was 15.7±0.9 mm, in the comparison group (only AUB) – 11.2±0.7 mm, in the control group – 5, 2±0.3 mm, respectively. Endometrial volume in these groups was 5.2±0.7 cm³, 3.3±0.4 cm³ and 2.4±0.2 cm³, respectively. As can be seen from the table, the thickness of the M-echo among women of the main group with high reliability (P<0.001) exceeded the data of the comparative and control groups, and the indicator of the comparative group was also significantly (P<0.001) higher than that of the control group. The volume of the endometrium in women with AUB against the background of the metabolic syndrome was significantly higher than in the comparative (p<0.05) and control (p<0.001) groups. In the comparative group, the volume of the endometrium with low significance (p<0.05) exceeded that of the control group (Table 1).

The presence of polypoid formations in the uterine cavity was detected in 7 (35%) women of the main group, in 3 (15%) women of the comparison group. Endometrial polyps were determined in the form of oval or rounded formations of increased echogenicity of various

Table 1. Average values of the size of the endometrium (M±m)

Parameters	I group, (main) AUB+MS n=25	II group (comparative) AUB n=20	Control group n=20
	1	2	3
Thickness M-exo, mm	15,7±0,9 P 1-2<0,001 P 1-3<0,001	11,2±0,7 P 2-3<0,001	5,2 ±0,3
V endometrium, sm ³	5,2±0,7 P 1-2<0,05 P 1-3<0,001	3,3±0,4 P 2-3<0,05	2,4±0,2

Note: P 1-3 - comparison of the results of the main and control groups; P 1-2 - comparison of the results of the main and comparative groups; P 2-3 - comparison of the results of the comparative and control groups.

localization, homogeneous echostructure, clear and even contour, sizes from 5 mm to 15 mm, on average 8.7 ± 3.5 mm (Fig. 1). Signs of adenomyosis were found in 4 (16%) patients of the main group and in 5 (25%) women of the comparison group, which manifested themselves with increased echogenicity and asymmetry of the uterine walls, thickening of the endometrium. Leiomyoma nodes were identified in 3 (12%) patients of the comparison group and in 4 (20%) of the main group, which had a clear capsule, different localization and size. In the control group, pathological conditions of the myometrium and endometrium were not observed.

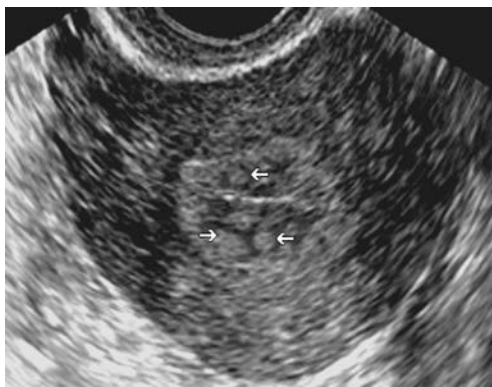


Fig. 1. Polyposis of the endometrium. The arrows show multiple formations in the uterine cavity of increased echogenicity, round or oval in shape, with a clear contour

Doppler values of the uterine arteries are presented in Table 2. The lowest index of resistance and pulsation was recorded among women of the main group (0.56 ± 0.03 and 0.73 ± 0.05). In the comparison group, these indicators were 0.59 ± 0.03 and 0.97 ± 0.06 , in the control group 0.67 ± 0.04 and 1.24 ± 0.09 , respectively. The value of the resistance index in the main group differed with low significance ($P < 0.05$) from that of the control group. At the same time, the pulsation index in the main group with high reliability ($P < 0.001$) exceeded the corresponding indicator of the comparative and control groups. A similar trend persisted when comparing the indices of resistance and pulsation in women of the main, comparative and control groups. In the basal arteries, the minimum significant difference ($P < 0.05$) in the value of the pulsation index was noted even between the main and comparative groups. In the uterine and arcuate arteries, there was no

difference in the value of the resistance index between the main and comparative groups, and in the pulsation index it had a minimal significant ($P < 0.05$) value (Fig. 2-4).

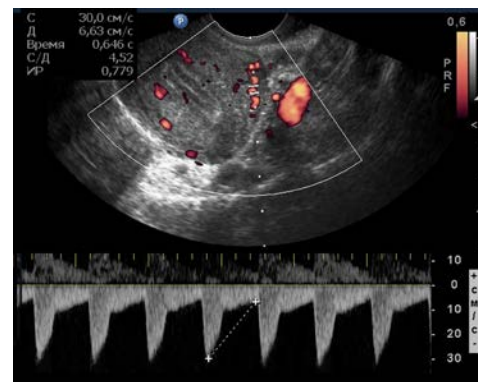


Fig. 2. Registration of blood flow in the arcuate arteries in a woman with a normal menstrual cycle and no uterine pathology. The blood flow resistance index is 0.78

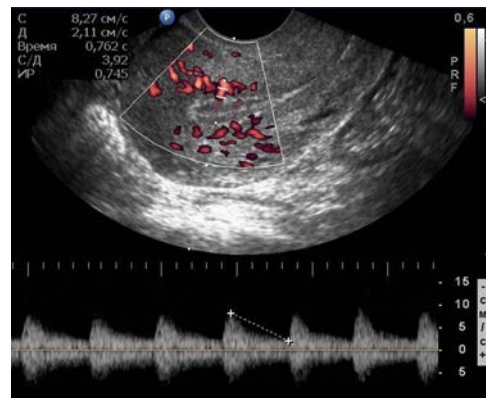


Fig. 3. Registration of blood flow in the basal arteries in a woman with a normal menstrual cycle and no uterine pathology. The blood flow resistance index is 0.74

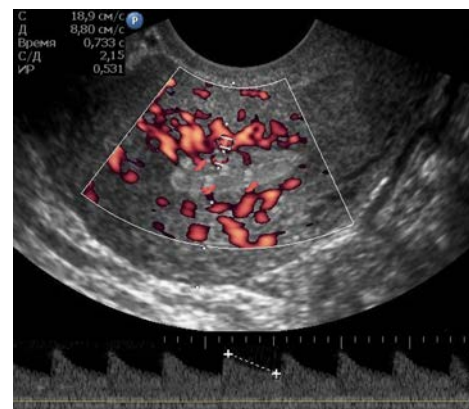

Fig. 4. Registration of blood flow in the arcuate arteries in a woman with a endometrial poliposis. The blood flow resistance index is 0.53

Table 2. Indexes of peripheral resistance to blood flow in the uterine, arcuate, radial and basal arteries

Doppler parameters	Main group (n=25)	Comparative group (n=20)	Control group (n=20)
	1	2	3
PI, uterine arteries	1,06±0,09 P 1-2<0,05 P 1-3<0,01	1,43±0,12	1,64±0,17
RI, uterine arteries	0,67±0,04	0,73±0,04	0,76±0,05
PI, arcuate arteries	0,95±0,06 P 1-2<0,05 P 1-3<0,001	1,21±0,09	1,53±0,14
RI, arcuate arteries	0,61±0,03 P 1-3<0,05	0,68±0,03	0,72±0,04
PI, radial arteries	0,84±0,05 P 1-2<0,05 P 1-3<0,001	1,08±0,09	1,31±0,12
RI, radial arteries	0,58±0,03 P 1-3<0,05	0,62±0,03	0,69±0,04
PI, basal arteries	0,73±0,05 P 1-2<0,001 P 1-3<0,001	0,97±0,06 P 2-3<0,05	1,24±0,09
RI, basal arteries	0,56±0,03 P 1-3<0,01	0,59±0,03	0,67±0,04

Note: P 1-3 - comparison of the results of the main and control groups; P 1-2 - comparison of the results of the main and comparative groups; P 2-3 - comparison of the results of the comparative and control groups.

All women from AUB group underwent hysteroresectoscopy with removal of polyps and endometrial biopsy. Histological examination of the obtained material in the main group revealed predominantly glandular-polyposous endometrial hyperplasia, as well as glandular-cystic, angiomatous endometrial polyps with foci of necrosis and dysplasia; in the comparison group - predominantly glandular-fibrous polyps of the proliferative type, coinciding with the literature data [14].

Treatment of AUB in women with metabolic syndrome was carried out in 2 directions: to eliminate the cause of AUB by a surgical method (hysteroresectoscopy) and to reduce the risk factors for complications of the metabolic syndrome. A healthy lifestyle is one of the main approaches to the treatment of metabolic syndrome, which includes correcting excess weight and increasing physical activity. The main goals of drug therapy for the metabolic syndrome include correction of dyslipidemia, normalization of blood pressure levels,

treatment of diabetes mellitus and prediabetes, which coincides with modern approaches to the treatment of metabolic syndrome [15].

Previously published works show the role of Doppler ultrasound in the differential diagnosis of simple and proliferating uterine leiomyoma [16]. The results of our studies have shown that in women with abnormal uterine bleeding against the background of the metabolic syndrome, the indices of vascular resistance in the radial and basal arteries are significantly low compared not only with healthy women, but also with women with only abnormal uterine bleeding, which indicates an increase in blood flow in areas of endo- and myometrium. It should be noted that in women with abnormal uterine bleeding against the background of metabolic syndrome, endometrial hyperplasia was predominant, and in women without metabolic syndrome, endometrial polyps were found. The ultrasound picture of hyperplastic processes in women with abnormal uterine bleeding against the background of the

metabolic syndrome was distinguished by distinct polymorphism, but most often there was a heterogeneity of the endometrial structure and was characterized by a change in the median M-echo (thickness > 12 mm), increased echogenicity, the presence of hyperechoic inclusions, and an increase in the peripheral resistance index.

Analysis of the sonographic characteristics of the venous collectors of the small pelvis showed varicose veins of the parametrium in 3 (15%) women of the comparison group and in 8 (32%)% of the patients of the main group in the form of an increase in the average diameter of the veins by 1.5 times compared with the control group. Hemodynamic disturbances of blood flow in the pelvic organs were detected in almost 70% of patients with abnormal uterine bleeding against the background of metabolic syndrome in the form of venous stasis, which may be due to this extragenital pathology.

The analysis of the echographic picture of the endometrium demonstrates that ultrasound with color Doppler mapping is a valuable method that contributes to a significant impro-

vement in the diagnosis of endometrial hyperplasia, the definition of polyps, and in most cases corresponds to the histological diagnosis. Thus, it is advisable to conduct an ultrasound examination in all patients with abnormal uterine bleeding to determine the ultrasonographic signs of pathological changes in the endometrium and the choice of treatment tactics.

Conclusions:

1. Metabolic syndrome negatively affects the gynecological health of a woman, contributing to the occurrence of abnormal uterine bleeding, mainly due to endometrial hyperplasia;

2. Doppler ultrasound with the determination of peripheral resistance indices in the radial, arcuate and basal arteries allows you to determine the nature of structural changes in the endometrium and assess the degree of hemodynamic disturbances in these vessels in women with abnormal uterine bleeding;

3. The final treatment and diagnostic method of endometrial hyperplasia is hysteroresectoscopy with mandatory histological examination of the endometrium.

Information about the conflict of interest. The authors declare no conflict of interest related to the publication of this article.

REFERENCES

1. Sytnik PO. Abnormal uterine bleeding: modern analysis of etiopathogenesis, diagnosis and treatment. *Ukrainian medical journal*. 2021;4(144). doi: 10.32471/umj.1680-3051.144.213540.
2. Davis E, Spartzak PB. Abnormal Uterine Bleeding. 2021 Apr 1. In: StatPearls [Internet]. Treasure Island (FL): StatPearls Publishing; 2021 Jan-. PMID: 30422508.
3. Tatarchuk TF, Kosey NV, Reheda SI, Tutchenko TM, Hlamazda MI. The role of reproductive health disorders in the development of metabolic syndrome in women. *Journal of the national academy of medical sciences of Ukraine*. 2019;20(1):77-87.
4. Sinkina AA, Nikitina IM. Menstrual dysfunction in adolescent girls associated with metabolic syndrome (literature review). *Actual Problems of Pediatrics, Obstetrics and Gynecology*. 2022;2:144-9. doi:10.11603/24116-4944.2021.2.12887
5. Nilsson PM, Tuomilehto J, Rydén L. The metabolic syndrome - What is it and how should it be managed? *Eur J Prev Cardiol*. 2019;26(2_suppl):33-46. doi: 10.1177/2047487319886404
6. Suliga E, Ciesla E, Gluszek-Osuch M, Lysek-Gladysinska M, Wawrzycka I, Gluszek S. Breastfeeding and Prevalence of Metabolic Syndrome among Perimenopausal Women. *Nutrients*. 2020;12(9):2691. doi: 10.3390/nu12092691.
7. Rochlani Y, Pothineni NV, Kovelamudi S, Mehta JL. Metabolic syndrome: pathophysiology, management, and modulation by natural compounds. *Ther Adv Cardiovasc Dis*. 2017;11(8):215-25. doi: 10.1177/1753944717711379
8. Min SH, Yang Q, Docherty SL, Im EO, Hu X. Symptom Clusters and Key Symptoms Among Midlife Perimenopausal and Postmenopausal Women With and Without Metabolic Syndrome. *Nurs Res*. 2022;71(4):E28-38. doi: 10.1097/NNR.0000000000000591
9. Cybulska AM, Schneider-Matyka D, Bosiacki M, Chlubek D, Panczyk M, Grochans E. The Levels of Bioelements in Postmenopausal Women with Metabolic Syndrome. *Nutrients*. 2022;14(19):4102. doi: 10.3390/nu14194102
10. Ring KL, Mills AM, Modesitt SC. Endometrial Hyperplasia. *Obstet Gynecol*. 2022;140(6):1061-75. doi: 10.1097/AOG.0000000000004989

11. Sanderson PA, Critchley HO, Williams AR, Arends MJ, Saunders PT. New concepts for an old problem: the diagnosis of endometrial hyperplasia. Hum Reprod Update. 2017;23(2):232-54. doi: 10.1093/humupd/dmw042
12. Aldarazi K, Omran H, Jassim NM. Endometrial hyperplasia in asymptomatic subfertile population. J Gynecol Obstet Hum Reprod. 2022;51(4):102337. doi: 10.1016/j.jogoh.2022.102337
13. Mielikhova T, Gryshchenko O, Lazurenko V, Safonov R, Alekseeva O. Optimization of diagnostic studies in patients with adenomiosis and/or hyperplastic processes of endometrium. Reproductive endocrinology. 2021; 58:34–9. doi: 10.18370/2309-4117.2021.58.34-39
14. Wouk N, Helton M. Abnormal Uterine Bleeding in Premenopausal Women. Am Fam Physician. 2019;99(7):435-43.
15. Bozkurt B, Aguilar D, Deswal A, Dunbar SB, Francis GS, Horwich T, et al. Contributory Risk and Management of Comorbidities of Hypertension, Obesity, Diabetes Mellitus, Hyperlipidemia, and Metabolic Syndrome in Chronic Heart Failure: A Scientific Statement From the American Heart Association. Circulation. 2016;134(23):e535-78. doi: 10.1161/CIR.0000000000000450.
16. Abdullaiev R.Ya. Kulikova F.I., Shcherbina O.V., Leshcheva T.V., Kryzhanovskaya I.V. Ultrasound differential diagnosis of uterine leiomyomas. EC Gynaecology 11.9 (2022): 18-26.

**К.В.Гаркавенко¹, В.В.Лазуренко¹, Р.Я.Абдуллаев¹,
И.А.Васильева², В.Г.Карпенко¹, Н.М.Паснешвили³**

УЛЬТРАЗВУКОВЫЕ ОСОБЕННОСТИ ЭНДОМЕТРИЯ У ЖЕНЩИН С АНОМАЛЬНЫМИ МАТОЧНЫМИ КРОВОТЕЧЕНИЯМИ НА ФОНЕ ЭКСТРАГЕНИТАЛЬНОЙ ПАТОЛОГИИ

¹*Харьковский национальный медицинский университет, Украина*

²*Харьковский национальный университет им. В.Н. Каразина, Украина*

³*Харьковский областной клинический перинатальный центр, Украина*

Резюме. В статье представлены результаты доплерометрии сосудов матки у 45 женщин в возрасте 40-55 лет с аномальными маточными кровотечениями (АМК) – у 25 из них на фоне метаболического синдрома (МС), которые составили основную группу и у 20 без МС (сравнительная группа). Контрольную группу составили 20 женщин с нормальным менструальным циклом. Всем женщинам с АМК УЗИ матки и придатков проводилось в день обращения, а женщинам контрольной группы – на 5-8 день менструального цикла. При УЗИ у пациенток с АМК на фоне МС было обнаружено трехкратное увеличение толщины и в 1,6 раза объема эндометрия по сравнению с контрольной группы ($p < 0,05$). Наличие полиповидных образований в полости матки было выявлено у 7 (35%) пациенток с АМК, у 3 (15%) женщин с АМК на фоне МС. Установлено, что у женщин с АМК по сравнению с женщинами контрольной группы в радиальных и базальных артериях достоверно снижались индексы резистентности ($p < 0,05$) и пульсативности ($p < 0,001$). У женщин с АМК на фоне МС достоверно увеличивалась толщина ($p < 0,05$) и объем ($p < 0,001$) эндометрия.

Результаты исследования показывают, что метаболический синдром является одним из факторов развития гиперплазии эндометрия, которая является причиной аномальных маточных кровотечений. Ультразвуковая доплерометрия у этих женщин выявляет достоверное снижение сосудистого сопротивления.

Correspondence author:

Abdullaiev Rizvan Yagubovich; Department of Ultrasound Diagnostics, Kharkiv National Medical University, Kharkiv, Ukraine

E-mail: rizvanabdullaiev@gmail.com