

УДК: 616.74-007.15-039.36-053.2
DOI: 10.24061/2413-4260.XIII.2.48.2023.19

CLINICAL VARIANT OF OSSIFYING MYOSITIS IN PEDIATRIC PRACTICE

**H.S. Senatorova, T.V. Frolova,
A.V. Senatorova, E.V. Kikhtenko,
N.S. Osman**

Kharkiv National Medical University
(Kharkiv, Ukraine)

Summary

Introduction. Ossifying myositis is a pathological process in muscles characterized by the formation of ossification in soft tissues. At present, the etiological factors of the disease remain not fully elucidated. The triggering factors of the disease are considered to be traumatic injuries, invasive medical manipulations against the background of genetic predisposition.

Aim. Invite attention of general practitioners and pediatricians to a rare disease, namely progressive ossifying fibrodysplasia in children and the peculiarities of its diagnosis.

Results. The article presents a clinical case of progressive ossifying fibrodysplasia (Munchmeyer's disease) in a 4-year-old girl. At birth, the child was diagnosed with a foot deformity characteristic of this pathology (shortening of the first metatarsal finger, flexion-rotation contracture of both feet). The clinic of the disease manifested itself at the age of 3 years, when, after falling on the back, a dense formation was noticed in the area of the left shoulder blade. Half a year after the fall, swelling and pain appeared in the sacro-coccygeal region of the spine. The girl was consulted by an orthopedist, dermatologist, and oncologist. During the examination of the child, characteristic clinical features of progressive ossifying fibrodysplasia were revealed, namely, deformation and fixed position of the chest, tense neck muscles, sharp limitation of movements in all parts of the spine, limitation of bending in the left elbow joint, clinodactyly, valgus deformity of the big toes. During the ultrasound examination, the following changes were diagnosed: swelling of muscle tissue in the neck area, subscapular area on the left and sacrococcygeal joint; multiple hypoechoic formations of irregular shape, heterogeneous echo structure with hyperechoic inclusions with an acoustic shadow; a focal change in the muscle structure in the form of a loss of the characteristic pinnate structure of the perimysium. The diagnosis was confirmed histologically. No characteristic changes were found in clinical and biochemical studies. The girl is under supervision. No worsening of the child's condition has been recorded over the past four years.

Keywords: Children; Progressive Ossifying Fibrodysplasia; Calcification.

Introduction. Ossifying myositis (OM) is a pathological process in muscles characterized by radiological and histological signs of bone formation (osteoid induction) in soft tissues.

The cause of OM can be trauma [1, 2] (post-traumatic ossifying myositis (M61.0)), calcification and ossification of muscles after burns (M61.3), paralytic calcification and ossification of muscles (M61.2), Munchmeyer's disease or progressive ossifying fibrodysplasia (M61.1) [3, 4]. The leading pathophysiological links are muscle hypoxia, inflammation and genetic predisposition [5-8]. Fibrodysplasia Ossificans Progressiva (FOP) is a rare, disabling genetic condition characterized by congenital malformations of the big toes and progressive heterotopic ossification (HO). FOP is a plastic process in which calcification of muscle tissue occurs, followed by muscle ossification. The basis of the disease is a genetic mutation of the activin receptor type 1 gene (ACVR1), the BMP1 gene, which encodes the synthesis of bone morphogenic protein. The mutation can be sporadic or have a family character [9-11]. In the second case, the disease has an autosomal dominant type of inheritance with variable gene expression and complete penetrance. The population frequency is 1:2000000. The onset of the disease occurred at an early age [12-14]. The disease was first described by the German doctor E. Munchmeyer in 1869. In 1988, The International Fibrodysplasia Ossificans Progressiva Association (www.ifopa.org) was created. There are three stages of development of FOP [1]:

Stage I (infiltration) – growth of young degenerative tissue and secondary degenerative changes in muscles. Histologically, inflammatory changes in the intermuscular connective tissue with its swelling are revealed.

II stage - fibrous induration of connective tissue, its scarring with secondary atrophy of muscle tissue.

III stage (ossification) – the formation of bone tissue in places of soft tissue damage.

The first clinical signs appear from birth in the form of shortening of the first toe. The disease begins with the appearance of swelling, most often in the area of the shoulder girdle. The density of the focus increases, hardens, the process captures the entire musculoskeletal system, a second skeleton is formed. The appearance of the patient is compared to a "tin soldier". There are practically no data on the damage to internal organs. Exacerbation of the disease is often associated with traumatization, in that case also with conducting a biopsy. Laboratory markers of the disease are unknown. The principles of therapy have not been developed.

This disease has an unfavorable course in terms of recovery. One of the severe complications of FOP in children is muscle ossification (calcinosis). It should be noted that every second child of preschool age with FOP has calcification. Older children - in 44-37.4 %, and in adults - in 7.9-17 % of cases [15-17]. The genesis of calcinosis in FOP has not been fully elucidated. It is believed that it corresponds to the degree of activity and prevalence of the inflammatory necrotic process

with subsequent sclerosis and calcinosis [18-21]. Calcifications are localized in the thickness of the affected muscles in the form of individual foci that merge or plates. The occurrence of calcifications is accompanied by fever, burning, pain, the appearance of elastic, bulging or dense formations [12]. The prognosis of the disease is unfavorable. Mortality is most often associated with hypoventilation of the lungs as a result of damage to the intercostal muscles and the development of pneumonia [22-24].

There is currently no effective treatment. In most cases, clinical symptoms disappear on their own. The basis of helping children is a protective regime, the exclusion of intramuscular injections, vaccination, which can only be carried out based on vital signs. Vaccinations should not be given during exacerbations and should be avoided for 6-8 weeks after the exacerbation symptoms have resolved. Medical treatment during exacerbation includes oral non-steroidal anti-inflammatory drugs in age-related doses, prednisolone at a dose of 2 mg/kg/day (up to 100 mg per day), COX-2 inhibitors, muscle relaxants, local administration of anti-inflammatory drugs [9].

Goal. To draw the attention of general practitioners and pediatricians to a rare disease, namely Fibrodysplasia Ossificans Progressiva in children and the peculiarities of its diagnosis.

Description of a clinical case.

Girl E., 4 years old, was hospitalized with complaints of formations in the area of the neck, shoulder girdle, back, restriction of movement when raising the arms up.

From the medical history, it is known that the parents and two other children in this family are healthy. Child from 12th pregnancy, 3rd birth at 38 weeks. The child was born with a weight of 3680 g, a length of 53 cm with congenital shortening of the first metatarsal finger, flexion-rotation contracture of both feet. At the age of 1 month, the girl underwent surgery for pylorostenosis. Throughout her life, she suffered from acute respiratory infections and chicken pox. From infancy, parents paid attention to the hyperergic reaction at the sites of mosquito bites (long-term, persistent infiltration and hyperemia of skin areas). At the age of three, after falling on his back, his parents noticed a dense formation in the area of the left shoulder blade. An X-ray examination and a consultation with an orthopedist did not reveal any pathology. Six months after the fall, the parents noted swelling and pain in the sacrococcygeal region of the spine. According to the results of electromyography, there is no damage to the structures of the brachial nerve plexus, there are no peripheral nerves of the upper limbs, and there is no muscle denervation. The conclusion of the oncologist and dermatologist: aggressive dismoid fibromatosis. Tomoxifen is recommended. The parents did not perform the prescribed treatment. Local treatment of the formation with hydrocortisone ointment was carried out, which did not have a positive effect.

During the examination in the hospital, the general condition of the girl was moderate due to damage to the musculoskeletal system: restriction of movement of all parts of the spine, hypertonic of the neck muscles and decreased muscle tone of both limbs and trunk. Physical and mental development of the child corresponds to the age. Attention is drawn to the stiffness of the gait, the head is slightly tilted forward, the deformation and fixed position of the chest, the neck muscles are tense,

the sharp limitation of movements in all parts of the spine, the limitation of bending in the left elbow joint, clinodactyly, valgus deformation of the big toes (Fig. 1.1.), on the left biceps is dense to the touch. In the area of the neck, head, and subscapular areas, dense, painless, immobile formations are palpable, rising 1.0-1.5 cm above the skin surface (Fig. 1.2). Lymph nodes are not palpable. No violations of the internal organs were detected.

A comprehensive examination was carried out:

1. General blood analysis: erythrocytes — $4.2 \cdot 10^{12}/l$, hemoglobin — 104 g/l, leukocytes — $6.2 \cdot 10^9/l$, platelets — $310 \cdot 10^9/l$, eosinophils — 5%, lymphocytes — 48%, band neutrophils — 2%, segmented neutrophils — 40%, monocytes — 5%, ESR — 12 mm/h. Conclusion: mild stage anemia.

2. Biochemical examination of blood: total bilirubin — 7.8 $\mu\text{mol}/l$, thymol test — 2.0 U, AlAT — 17 U/l, AsAT — 19 U/l, total protein — 72.1 g/l, urea — 4.05

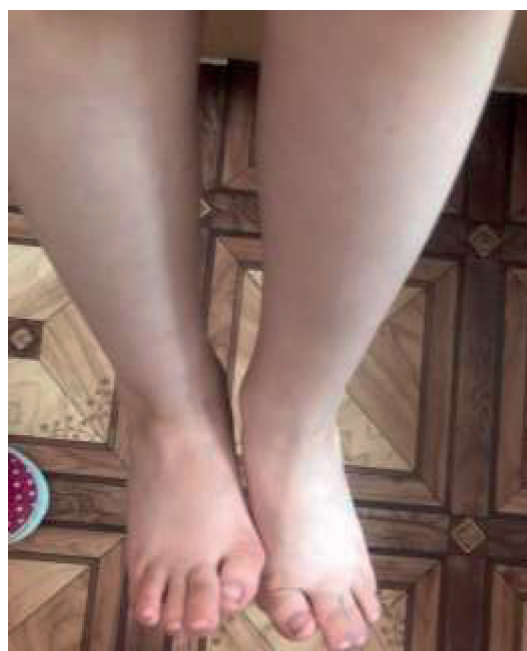

Fig. 1.1. Progressive ossifying fibrodysplasia. Shortening and valgus deformity of the first toes.

$\mu\text{mol}/l$, creatinine — 42 $\mu\text{mol}/l$, glucose — 3.7 $\mu\text{mol}/l$, CRP — negative, CK — 177.0 U/l, calcium — 2.2 mmol/l , phosphorus — 1.56 mmol/l , total alkaline phosphatase — 1623 Units/l.

3. Immunological research: IgG — 8.2 g/l, IgA — 0.77 g/l, IgM — 0.7 g/l, antibodies to striated muscles were not detected. CIC — 0.023 g/l (n), AHA-negative.

4. General analysis of urine, coprological examination — without special features.

5. ECG: decrease in voltage.

6. Echo— minimal regurgitation on the mitral valve, left to right shunt in the central part of the interatrial septal of 3 mm.

7. US of the abdominal organs: parenchymal cyst of the left kidney measuring 0.8x0.8 cm.

8. According to ultrasound examination, swelling of muscle tissue in the neck area, subscapular area on the left and sacrococcygeal joint was determined. In the soft tissues of the upper and lower limbs and on the back surface of the back, multiple hypoechoic formations of

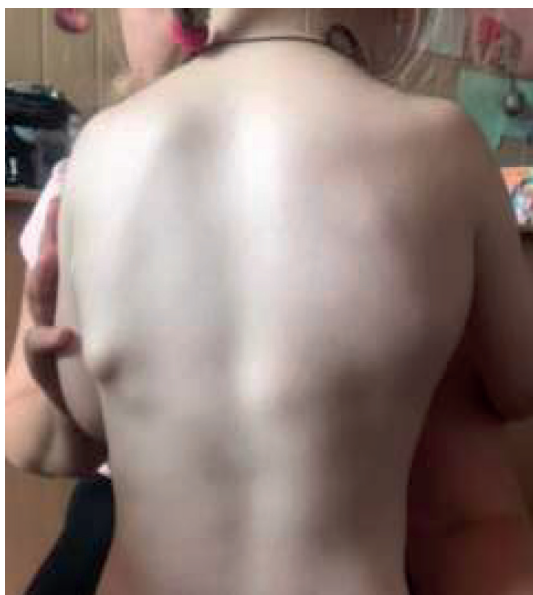

Fig. 1.2. Progressive ossifying fibrodysplasia. Tumor-like formations in subscapular areas.

an irregular shape, heterogeneous echostructure with hyperechoic inclusions with an acoustic shadow are visualized. These formations are visualized mainly in muscle tissue with spread to subcutaneous fat tissue. A focal change in the muscle structure is visualized in the form of a loss of the characteristic pinnate structure of the perimysium, a diffuse decrease in echogenicity, and multiple intra-muscular ossification.

9. Histological examination. The results of the biopsy of the infiltrate in the left subscapular area are shown in Figures 2.1-2.4.

Taking into account the results of the obtained examinations, namely clinical (deformation and fixed position of the chest, strained neck muscles, sharp limitation of movements in all parts of the spine, limitation of bending in the left elbow joint, clinodactyly, valgus deformation of the big toes) and histological (signs of atrophy muscle fibers with the appearance of layers of connective tissue that surround muscle fibers; focus of angiomatosis, moderate lymphocytic infiltration) data established a diagnosis: Fibrodysplasia Ossificans Progressiva (FOP) (M61.1). Left kidney cyst, functioning oval window.

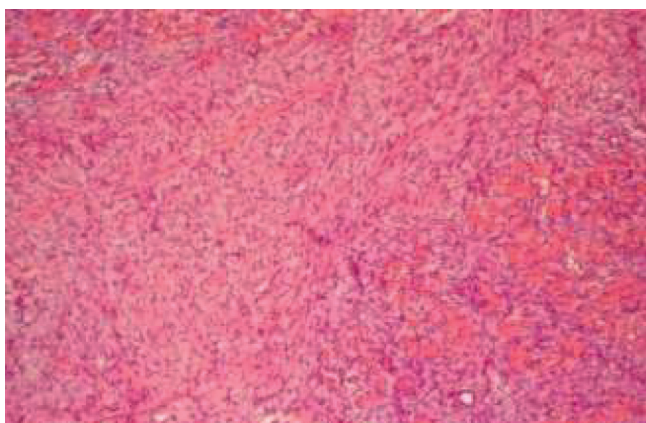


Fig. 2.1. The muscle bundle is surrounded by a large layer of connective tissue. Neoplasm of the connective tissue between individual muscle fibers. Signs of uneven atrophy without signs of necrobiosis, necrosis, and subsequent petrification in the muscle fibers. H&E stain. 200x magnification.

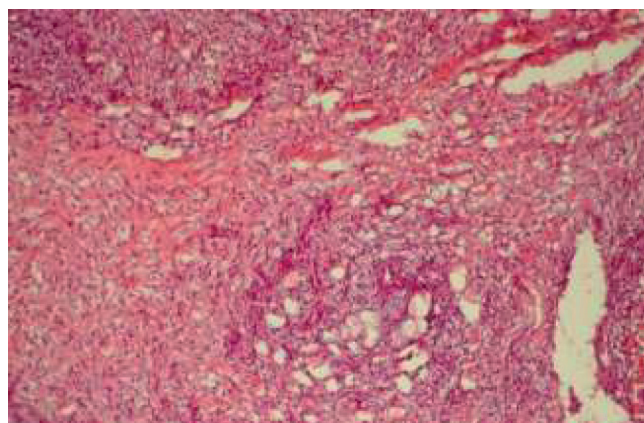


Fig. 2.2. A focus of angiomatosis, surrounded by connective tissue of varying degrees of maturity and focal moderate lymphocytic infiltration. H&E stain. 200x magnification.

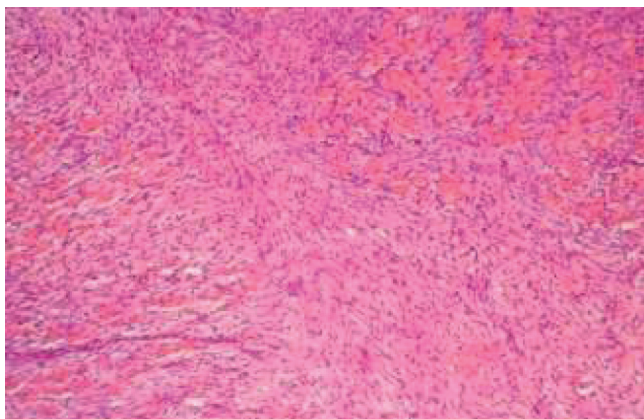


Fig. 2.3. Muscle bundles and individual muscle fibers surrounded by connective tissue of varying degrees of maturity. Signs of an increase in morphofunctional activity and proliferation of fibroblast cells (top left). Uneven atrophy of muscle fibers. H&E stain. 200x magnification.

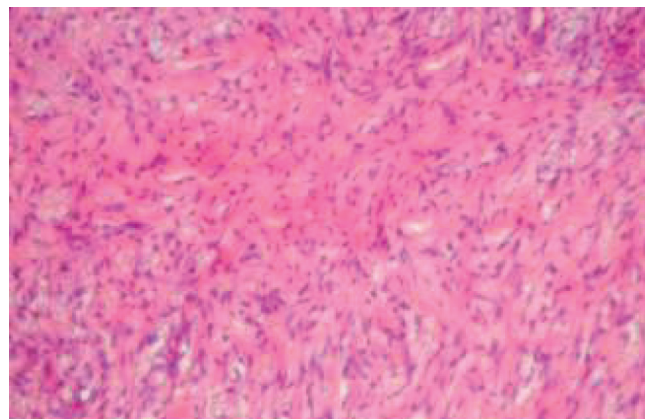


Fig. 2.4. Connective tissue, partially mature with rough, randomly spaced bundles of collagen fibers and signs of fibroblast proliferation. H&E stain. 400x magnification.

Recommendations provided:

1. Observation of the pediatrician and orthopedist in dynamics.
2. Therapeutic and protective mode (avoid potentially traumatic games).
3. In case of soft tissue injury or after an infection: prednisolone 2 mg/kg/day – 4 days, ibuprofen in an age-related dosage.

4. Medical refusal from vaccination (except for emergency indications).

During the last four years, the child's condition has not deteriorated, the child is under the supervision of doctors.

Conflict of interest: none.

Financing: self-financing.

Reference:

1. Gugala Z, Olmsted-Davis EA, Xiong Y, Davis EL, Davis AR. Trauma-Induced Heterotopic Ossification Regulates the Blood-Nerve Barrier. *Front Neurol* [Internet]. 2018[cited 2023 May 12];9:408. Available from: <https://www.frontiersin.org/articles/10.3389/fneur.2018.00408/full> doi: 10.3389/fneur.2018.00408
2. Davis EL, Davis AR, Gugala Z, Olmsted-Davis EA. Is heterotopic ossification getting nervous?: The role of the peripheral nervous system in heterotopic ossification. *Bone*. 2018;109:22-7. doi: 10.1016/j.bone.2017.07.016
3. Akesson LS, Savarirayan R. Fibrodysplasia Ossificans Progressiva. 2020 Jun 11 [updated 2023 May 11]. In: Adam MP, Mirzaa GM, Pagon RA, Wallace SE, Bean LJH, Gripp KW, et al, editors. *GeneReviews®* [Internet]. Seattle (WA): University of Washington, Seattle; 1993–2023.
4. Pignolo RJ, Shore EM, Kaplan FS. Fibrodysplasia ossificans progressiva: diagnosis, management, and therapeutic horizons. *Pediatr Endocrinol Rev*. 2013;10(2):437-48.
5. Ошлянська О.А. Арцимович А.Г. Самоненко Н.В. Рідкісні хвороби: два випадки прогресуючої осифікуючої фібродисплазії у практиці дитячого ревматолога. *Український ревматологічний журнал*. 2019;78(4):53-60. doi:10.32471/rheumatology.2707-6970.78.13031
6. De Brasi D, Orlando F, Gaeta V, De Liso M, Acquaviva F, Martemucci L, et al. Fibrodysplasia Ossificans Progressiva: A Challenging Diagnosis. *Genes (Basel)* [Internet]. 2021[cited 2023 May 12];12(8):1187. Available from: <https://www.mdpi.com/2073-4425/12/8/1187> doi: 10.3390/genes12081187
7. Kaplan FS, Xu M, Glaser DL, Collins F, Connor M, Kitterman J, et al. Early diagnosis of fibrodysplasia ossificans progressiva. *Pediatrics* [Internet]. 2008[cited 2023 May 12];121(5):e1295-300. Available from: <https://www.ncbi.nlm.nih.gov/pmc/articles/PMC3502043/pdf/nihms417228.pdf> doi: 10.1542/peds.2007-1980
8. Shah ZA, Rausch S, Arif U, El Yafawi B. Fibrodysplasia ossificans progressiva (stone man syndrome): a case report. *J Med Case Rep* [Internet]. 2019[cited 2023 May 12];13(1):364. Available from: <https://jmedicalcasereports.biomedcentral.com/articles/10.1186/s13256-019-2297-z> doi: 10.1186/s13256-019-2297-z
9. <https://www.ifopa.org/>
10. Sun D, Liu P, Wang Z, Mu J, Cao J. Fibrodysplasia ossificans progressiva: A rare disease with spinal deformity and severe hip dysfunction. *Front Pediatr* [Internet]. 2022[cited 2023 May 12];10:981372. Available from: <https://www.frontiersin.org/articles/10.3389/fped.2022.981372/full> doi: 10.3389/fped.2022.981372
11. Haga N, Nakashima Y, Kitoh H, Kamizono J, Katagiri T, Saijo H, et al. Fibrodysplasia ossificans progressiva: Review and research activities in Japan. *Pediatr Int*. 2020;62(1):3-13. doi: 10.1111/ped.14065
12. Mishra D, Dhooria A. A Rare Grotesque Skeletal Deformity: Munchmeyer's Disease. *Mediterr J Rheumatol* [Internet]. 2021[cited 2023 May 12];32(1):91. Available from: <https://www.ncbi.nlm.nih.gov/pmc/articles/PMC8314880/pdf/MJR-32-1-91.pdf> doi: 10.31138/mjr.32.1.91
13. Sheth SB, Santhosh Kumar SN, Sabhlok S, Singh M. Munchmeyer's disease-a rare case report and review of literature. *Dentomaxillofac Radiol* [Internet]. 2014[cited 2023 May 12];43(5):20140022. Available from: <https://www.birpublications.org/doi/reader/10.1259/dmfr.20140022> doi: 10.1259/dmfr.20140022
14. Bhansali SP, Tiwari AD, Mittal S, Pareek S, Nasir I. Fibrodysplasia ossificans progressiva or Munchmeyer's disease: A rare case report. *Natl J Maxillofac Surg*. 2021;12(1):120-3. doi: 10.4103/njms.NJMS_52_19
15. Zhvania M. Juvenile dermatomyositis and calcinosis. *Georgian Med News*. 2015;(244-245):56-61.
16. Mandengue CE, Nouedoui C, Atangana PJ. Unrecognized juvenile dermatomyositis complicated by calcinosis universalis: a case report from Cameroon. *Med Sante Trop*. 2013;23(4):458-61. doi: 10.1684/mst.2013.0248
17. Wang A, Morgan GA, Paller AS, Pachman LM. Skin disease is more recalcitrant than muscle disease: A long-term prospective study of 184 children with juvenile dermatomyositis. *J Am Acad Dermatol*. 2021;84(6):1610-8. doi: 10.1016/j.jaad.2020.12.032
18. Li D, Tansley SL. Juvenile Dermatomyositis-Clinical Phenotypes. *Curr Rheumatol Rep* [Internet]. 2019[cited 2023 May 12];21(12):74. Available from: <https://link.springer.com/content/pdf/10.1007/s11926-019-0871-4.pdf?pdf=button> doi: 10.1007/s11926-019-0871-4
19. Santili C, Akkari M, Waisberg G, Kessler C, Alcantara Td, Delai PL. Calcinosis universalis: a rare diagnosis. *J Pediatr Orthop B*. 2005;14(4):294-8. doi: 10.1097/01202412-200507000-00012
20. Shah R, Ellis S. Subcutaneous fat calcinosis in adult-onset dermatomyositis. *BMJ Case Rep* [Internet]. 2011[cited 2023 May 12];2011:bcr0520114268. Available from: <https://casereports.bmj.com/content/casereports/2011/bcr.05.2011.4268.full.pdf> doi: 10.1136/bcr.05.2011.4268
21. de Ruiter RD, Smilde BJ, Pals G, Bravenboer N, Knaus P, Schoenmaker T, et al. Fibrodysplasia Ossificans Progressiva: What Have We Achieved and Where Are We Now? Follow-up to the 2015 Lorentz Workshop. *Front Endocrinol (Lausanne)* [Internet]. 2021[cited 2023 May 12];12:732728. Available from: <https://www.frontiersin.org/articles/10.3389/fendo.2021.732728/full> doi: 10.3389/fendo.2021.732728
22. Lin H, Shi F, Gao J, Hua P. The role of Activin A in fibrodysplasia ossificans progressiva: a prominent mediator. *Biosci Rep* [Internet]. 2019[cited 2023 May 12];39(8):BSR20190377. Available from: <https://portlandpress.com/bioscirep/article/39/8/BSR20190377/219360/The-role-of-Activin-A-in-fibrodysplasia-ossificans> doi: 10.1042/BSR20190377
23. Kaplan FS, Glaser DL, Hebela N, Shore EM. Heterotopic ossification. *J Am Acad Orthop Surg*. 2004;12(2):116-25. doi: 10.5435/00124635-200403000-00007
24. Sferopoulos NK, Kotakidou R, Petropoulos AS. Myositis ossificans in children: a review. *Eur J Orthop Surg Traumatol*. 2017;27(4):491-502. doi: 10.1007/s00590-017-1932-x

КЛІНІЧНИЙ ВИПАДОК ОСИФІКУЮЧОГО МІОЗИТУ У ПРАКТИЦІ ЛІКАРЯ-ПЕДІАТРА

Г.С. Сенаторова, Т.В. Фролова, А.В. Сенаторова, О.В. Кіхтенко, Н.С. Осман

Харківський національний медичний університет
(м. Харків, Україна)

Резюме

Вступ. Осифікуючий міозит – патологічний процес у м'язах, що характеризується формуванням осифікатів у м'яких тканинах. На тепер етіологічні фактори захворювання залишаються не до кінця з'ясованими. Пусковими факторами захворювання вважаються травматичні ушкодження, інвазивні медичні маніпуляції на тлі генетичної схильності.

Мета дослідження. Привернути увагу лікарів загальної практики і лікарів-педіатрів до рідкісного захворювання, а саме прогресуючої осифікуючої фібродисплазії у дітей та особливостей її діагностики.

Результати. У статті представлено клінічний випадок прогресуючої осифікуючої фібродисплазії (хвороба Munchmeuer) у дівчинки 4 років. При народженні у дитини була діагностована характерна для даної патології деформація стоп (укорочення I пальця плюснової кістки, згинально-ротаторна контрактура обох стоп). Клініка захворювання проявилась у віці 3-х років, коли після падіння на спину було помічено щільнеутворення в ділянці лівої лопатки. Через пів року після падіння з'явилась набряклість та болочість у крижово-куприковому відділі хребта. Дівчинка була консультована ортопедом, дерматологом, онкологом. При огляді дитини були виявлені характерні клінічні особливості прогресуючої осифікуючої фібродисплазії, а саме деформація і фіксоване положення грудної клітки, натягнуті м'язи шиї, різке обмеження рухів у всіх відділах хребта, обмеження згинання в лівому ліктьовому суглобі, клінодактилія, вальгусна деформація великих пальців ніг. При ультразвуковому дослідженні були діагностовано наступні зміни: набряк м'язової тканини в ділянці шиї, підлопаткової ділянці ліворуч і крижово-куприковому зчленуванні; множинні гіпоехогенні утворення неправильної форми, неоднорідної ехоструктури з гіперехогенними включеннями з акустичною тінню; осередкова зміна м'язової структури у вигляді втрати характерної перистої структури перимізія. Діагноз підтверджено гістологічно. Характерних змін в клінічних та біохімічних дослідженнях виявлено не було. Дівчинка перебуває під наглядом. За останні чотири роки погіршення стану дитини не зафіксовано.

Ключові слова: діти; прогресуюча осифікуюча фібродисплазія; кальциноз.

Contact Information:

Hanna Senatorova – Doctor of Medical Science, Full Professor, Professor of the Department of Pediatrics No. 1 and Neonatology, Kharkiv National Medical University (Kharkiv, Ukraine)
e-mail: hs.senatorova@knmu.edu.ua
ORCID ID: <http://orcid.org/0000-0001-6725-4695>
Scopus Author ID: <https://www.scopus.com/authid/detail.uri?authorId=6506164318>

Tetyana Frolova – Doctor of Medical Science, Full Professor, Head of the Department of Propaedeutics of Pediatrics No. 1, Kharkiv National Medical University (Kharkiv, Ukraine)
e-mail: tv.frolova@knmu.edu.ua
ORCID ID: <http://orcid.org/0000-0002-6861-8902>
Scopus Author ID: <https://www.scopus.com/authid/detail.uri?authorId=57204251212>

Olena Kikhtenko – Doctor of Medical Science, Docent, Associate Professor of the Department of Pathological Anatomy, Kharkiv National Medical University (Kharkiv, Ukraine)
e-mail: ov.kykhtenko@knmu.edu.ua
ORCID ID: <http://orcid.org/0000-0001-8713-6645>

Nataliya Osman – Candidate of Medical Science, Assistant Professor of the Department of Pediatrics No. 1 and Neonatology, Kharkiv National Medical University (Kharkiv, Ukraine)
e-mail: ns.osman@knmu.edu.ua
ORCID ID: <http://orcid.org/0000-0002-8621-4389>
Scopus Author ID: <https://www.scopus.com/authid/detail.uri?authorId=57923505100>

Контактна інформація:

Сенаторова Ганна Сергіївна – доктор медичних наук, професор, професор кафедри педіатрії №1 та неонатології, Харківський національний медичний університет (м. Харків, Україна)
e-mail: hs.senatorova@knmu.edu.ua
ORCID ID: <http://orcid.org/0000-0001-6725-4695>
Scopus Author ID: <https://www.scopus.com/authid/detail.uri?authorId=6506164318>

Фролова Тетяна Володимирівна – доктор медичних наук, професор, завідувачка кафедри пропедевтики педіатрії №1, Харківський національний медичний університет (м. Харків, Україна)
e-mail: tv.frolova@knmu.edu.ua
ORCID ID: <http://orcid.org/0000-0002-6861-8902>
Scopus Author ID: <https://www.scopus.com/authid/detail.uri?authorId=57204251212>

Кіхтенко Олена Валеріївна – доктор медичних наук, доцент, доцент кафедри патологічної анатомії, Харківський національний медичний університет (м. Харків, Україна)
e-mail: ov.kykhtenko@knmu.edu.ua
ORCID ID: <http://orcid.org/0000-0001-8713-6645>

Осман Наталія Сергіївна – кандидат медичних наук, асистент кафедри педіатрії №1 та неонатології, Харківський національний медичний університет (м. Харків, Україна)
e-mail: ns.osman@knmu.edu.ua
ORCID ID: <http://orcid.org/0000-0002-8621-4389>
Scopus Author ID: <https://www.scopus.com/authid/detail.uri?authorId=57923505100>



Received for editorial office on 14/02/2023
Signed for printing on 17/05/2023