

МІНІСТЕРСТВО ОХОРОНИ ЗДОРОВ'Я УКРАЇНИ
Харківський національний медичний університет

**RICKETS. HYPERVITAMINOSIS D.
TETANY**

Practical policies for students

**РАХІТ. ГІПЕРВІТАМІНОЗ D.
СПАЗМОФІЛІЯ**

Методичні вказівки для студентів

Затверджено
вченою радою ХНМУ.
Протокол № 11 від 19.11.2015.

**Kharkiv
KhNMU
2016**

Rickets. Hypervitaminosis D. Tetany : practical policies for students /
comp. Yu. V. Odinets, N. I. Makieieva, V. A. Golovachova, Yu. S. Trynduk. –
Kharkiv : KhNMU, 2016. – 16 p.

Compilers Yu. V. Odinets
 N. I. Makieieva
 V. A. Golovachova
 Yu. S. Trynduk

Рахіт. Гіпервітаміноз D. Спазмофілія : метод. вказ. для студентів /
упоряд. Ю. В. Одинець, Н. І. Макєєва, В. О. Головачова, Ю. С. Триндюк. –
Харків : ХНМУ, 2016. – 16 с

Упорядники Ю. В. Одинець
 Н. І. Макєєва
 В. О. Головачова
 Ю. С. Триндюк

Rickets is a disease of growing organism, which appears as a result of polyhypovitaminosis with primary insufficiency of vitamin D, that leads to disturbances in metabolism of phosphorus and calcium and processes of ossification with changes of organs and systems function.

Rickets is a disease of children of first two years. Its diagnostics is based on clinical manifestations involving nervous, osseous, muscular systems and laboratory and instrumental investigations.

The incidence of rickets in Europe is similar to that in the United States. In sunny areas, such as in the Middle East, rickets may occur when infants are bundled in clothing and are not exposed to sunlight. In some parts of Africa, deficiency of calcium, phosphorus, or both in the diet may also lead to rickets, especially in societies where corn is predominant in the diet.

The frequency of rickets has been increasing internationally. Possible reasons include recommendations for children to wear sunscreen while outdoors and a tendency for children to spend more time indoors, watching television or playing electronic games, instead of playing outdoors.

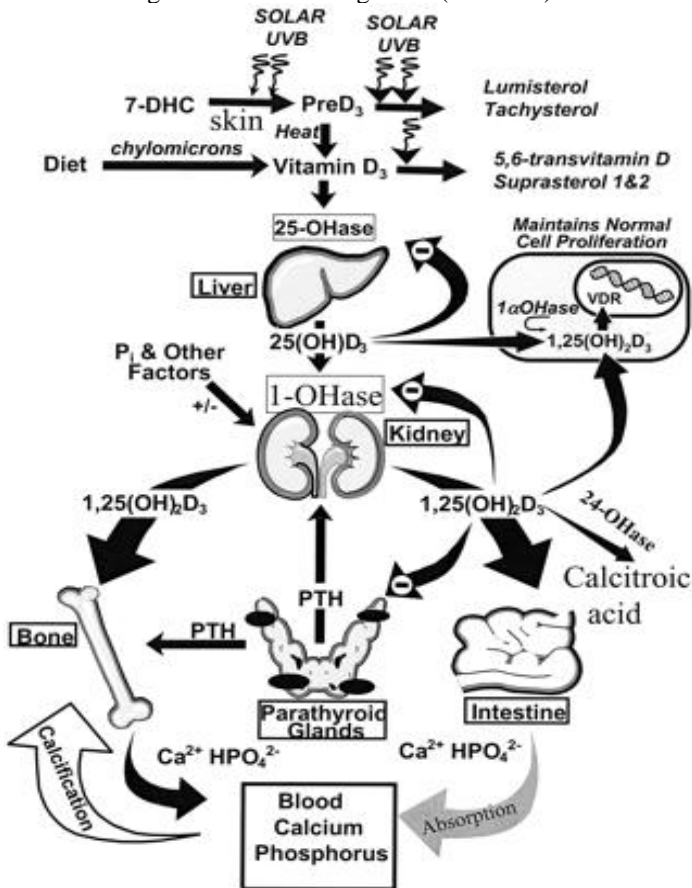
Etiology

- ◎ *Inadequate exposure to sunlight* – This causes a deficiency in cutaneously synthesized vitamin D;
- ◎ *Diets low in calcium, phosphorus and vit D*, e.g. exclusive breastfeeding into late infancy or, rarely, toddlers on supervised ‘dairy-free’ diets;
- ◎ *Prematurity* predisposes to rickets because the most intensive income of Ca and P from mother to fetus takes place during last months of pregnancy, so a baby born earlier than 30 weeks of gestation very often has osteopenia – more low content of mineral substances in bone;
- ◎ *Syndromes of malabsorption, chronic diseases of liver and kidney*, which lead to disorders of formation of active forms of vit D;
- ◎ *Dysbacteriosis and diarrhea*;
- ◎ *Medications* - Some medications are associated with vitamin D deficiency – drugs such as Dilantin, phenobarbital, and rifampin can induce hepatic p450 enzymes to accelerate the catabolism of vitamin D;
- ◎ *Hereditary anomalies of metabolism of vit D, Ca, P*: hereditary type I vit D-resistant (or dependent) rickets – Fanconi’s syndrome (renal loss of phosphate), familial (X-linked) hypophosphataemic rickets (renal tubular defect in phosphate transport);
- ◎ *Pigmentation of skin* decreases intensity of cholecalciferol formation in skin;
- ◎ *Ecological factors*: excess of strontium, plumbum and others metals in soil, water, food leads to partial substitution of Ca by these substances.

Pathophysiology

During exposure to sunlight, 7-dehydrocholesterol (7-DHC) in the skin absorbs solar UVB radiation and is converted to previtamin D₃ (preD₃). Once formed, previtamin D₃ undergoes thermally induced transformation to vitamin D₃.

Additional exposure to sunlight converts previtamin D₃ and vitamin D₃ to biologically inert photoproducts. Vitamin D originating from the diet or from the skin enters the circulation and is metabolized to calcidiol (25(OH)D₃) in the liver by vitamin D 25-hydroxylase (25-OHase). 25(OH)D₃ reenters the circulation and is converted to calcitriol (1,25(OH)₂D₃) in the kidney by 25(OH)D₃ 1 α -hydroxylase (1-OHase). A variety of factors, including serum phosphorus (P_i) and PTH, regulate the renal production of 1,25(OH)₂D. 1,25(OH)₂D regulates calcium metabolism through interactions with its major target tissues, ie, bone and intestine. 1,25(OH)₂D₃ also induces its own destruction by enhancing the expression of 25(OH)D 24-hydroxylase (24-OHase). 25(OH)D is metabolized in other tissues for regulation of cellular growth (Picture 1).



Picture 1. Pathway of vitamin D production

In the vitamin D deficiency state, hypocalcemia develops, which stimulates excess secretion of parathyroid hormone. In turn, renal phosphorus loss is enhanced, further reducing deposition of calcium in the bone.

Excess parathyroid hormone also produces changes in the bone similar to those occurring in hyperparathyroidism. Early in the course of rickets, the calcium concentration in the serum decreases. After the parathyroid response, the calcium concentration usually returns to the reference range, though phosphorus levels remain low. Alkaline phosphatase, which is produced by overactive osteoblast cells, leaks into the extracellular fluids, so that its concentration rises to anywhere from moderate elevation to very high levels.

Intestinal malabsorption of fat and diseases of the liver or kidney may produce the clinical and secondary biochemical picture of nutritional rickets. Anti-convulsant drugs (eg, phenobarbital, phenytoin) accelerate metabolism of calcidiol, which may lead to insufficiency and rickets, particularly in children who have darkly pigmented skin and those who are kept primarily indoors (eg, children who are institutionalized).

Classification

Vitamin D – deficient rickets, classical	Vitamin D – dependent rickets	Vitamin D – resistant rickets	Secondary rickets
Variants: <ul style="list-style-type: none"> • Calcium depletion • Phosphorus depletion • With correct level of Ca and P in serum of blood 	1. Type I – genetic defect of synthesis 1,25(OH) ₂ D in the kidney	1. Hereditary hypophosphatemic rickets with hypercalciuria	1. Disease of kidney, obstruction of biliary tract
Course of rickets: <ul style="list-style-type: none"> • acute • subacute • recurrent 	2. Type II – genetic resistance of receptors organ-targets to 1,25(OH) ₂ D	2. Fanconi syndrome	2. Malabsorption syndrome
Degree of severity: I – mild II – moderate III – severe		3. Distal renal tubular acidosis	3. Cytomegalic inclusion disease (cystinuria, (hyper) tyrosinemia at al.)
Periods of disease: 1) Initial 2) Height 3) Reparation 4) Residual effects		4. X-linked hypophosphatemic rickets Stages of disease: <ul style="list-style-type: none"> • Active • Remission (complete and no complete) 	4. Medicines induced (phenobarbital, anticonvulsive, glucocorticoid)

Variants of rickets:

- ⊙ Calcium depletion – deformations of bones, symptoms of osteomalacia, syndrome of affection nervous system - excitability, interrupted sleep, sweating and quick persistent red dermographism, decrease level of Ca, acute course of rickets;
- ⊙ Phosphorus depletion – decrease level of P, muscular hypotonia, symptoms of hyperplasia of osteoid tissue;
- ⊙ Without significant quantitative changes of level Ca and P in blood – subacute course of rickets.

Degree of severity of rickets:

I – mild (initial period of disease): syndrome of affection nervous system – excitability, interrupted sleep, sweating and quick persistent red dermographism; syndrome of lesion of osseous tissue – low-grade, may be deformation of skull, craniotabes.

II – moderate (height period of disease): syndrome of lesion of osseous tissue - symptoms of osteomalacia, symptoms of hyperplasia of osteoid tissue; moderate diminution of strength of muscle tone.

III – severe (height period of disease): most evident symptoms of osteomalacia, symptoms of hyperplasia of osteoid tissue; severe diminution of strength of muscle tone; hypermobility; increase of liver and spleen, functional changes of cardio-vascular system, respiratory tract, digestive tract, hypochromic anemia.

Course of rickets:

- Acute – rapid of disease progression, symptoms of osteomalacia, most evident syndrome of affection nervous system;
- Subacute – symptoms of hyperplasia of osteoid tissue, moderate diminution functions of internal organs;
- Recurrent – rotation period of exacerbation of disease and remission of disease.

Signs and symptoms of rickets in children

Clinical manifestations:

a) syndrome of affection of nervous system is observed in 100 % of cases and is revealed at initial period of disease as excitability, interrupted sleep, sweating, and quick persistent red dermographism. At the height of disease flaccidity, lag of motor development or rarely nervous-psychical retagration (only in grave forms of disease) a;

b) syndrome of lesion of osseous system is revealed in 100 % of cases. There are the following symptoms:

– symptoms of osteomalacia which manifest in form of softening of the big fontanel's edges, craniotabes, softening of ribs (Harrison's groove), kyphosis, bandy and baker's legs;

- symptoms of hyperplasia of osteoid tissue – increase of frontal and occipital tubers, costochondral prominence ("rachitic rosary"), bracelets on the upper and lower extremities, threads of pearls on finger's phalanges;
- symptoms of hypoplasia of osseous tissue – tardy closing of fontanel, delayed dental eruption, in severe cases – lag of growth of tubular bones in length. In acute course of rickets symptoms of osteomalacia prevail, in subacute – symptoms of hyperplasia of osteoid tissue;
- c) muscular hypotonia is seen in 98.8 % of patients. Its development leads to delay of static abilities;
- d) changes of internal organs: cardio-vascular system, respiratory tract, digestive tract and so on, increase of liver and spleen.

Clinical features of rickets:

General: failure to thrive, listlessness, protruding abdomen, muscle weakness (especially proximal), fractures.

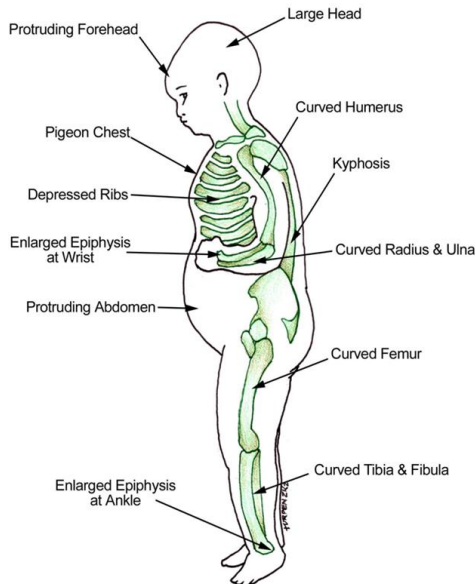
Head: craniotabes, frontal bossing, delayed fontanelle closure, delayed dentition; caries, craniosynostosis.

Chest: rachitic rosary, Harrison groove, respiratory infections and atelectasis.

Back: scoliosis, kyphosis, lordosis.

Extremities: enlargement of wrists and ankles, valgus or varus deformities, anterior bowing of the tibia and femur, coxa vara.

Hypocalcemic symptom: tetany, seizures, stridor due to laryngeal spasm.



Picture 2. Clinical signs of rickets

Clinical features of rickets:

General: failure to thrive, listlessness, protruding abdomen, muscle weakness (especially proximal), fractures.

Head: craniotabes, frontal bossing, delayed fontanelle closure, delayed dentition; caries, craniosynostosis.

Chest: rachitic rosary, Harrison groove, respiratory infections and atelectasis.

Back: scoliosis, kyphosis, lordosis.

Extremities: enlargement of wrists and ankles, valgus or varus deformities, anterior bowing of the tibia and femur, coxa vara.

Hypocalcemic symptom: tetany, seizures, stridor due to laryngeal spasm.

Osseous changes of rickets can be recognized after several months of vit D deficiency. In breast-fed infants whose mothers have osteomalacia, rickets may develop within 2 mo. Florid rickets appears toward the end of the 1st and during the 2nd yr of life. Later in childhood, manifest vit D deficient rickets is rare.

One of the early signs of rickets, craniotabes, is due to thinning of the outer table of the skull and detected by pressing firmly over the occiput or posterior parietal bones. A Ping-Pong-ball sensation will be felt. Low-birth-weight infants are particularly susceptible to the early development of rickets and to craniotabes. Craniotabes may disappear before the end of the 1st yr, although the rachitic process continues. The softness of the skull may result in flattening and, at times, permanent asymmetry of the head. The anterior fontanel is larger than normal; its closure may be delayed until after the 2nd yr of life. The central parts of the parietal and frontal bones are often thickened, forming prominences or frontal bossing, which give the head a box-like appearance (caput quadratum). Eruption of the temporary teeth may be delayed, and there may be defects of the enamel and extensive caries. The permanent teeth that are calcifying may also be affected; the permanent incisors, canines, and first molars usually show enamel defects.

Palpable enlargement of the costochondral junctions (the “rachitic rosary”). The sides of the thorax become flattened. The sternum with its adjacent cartilage appears to be projected forward, producing the so-called pigeon breast deformity. Along the lower border of the chest develops a horizontal depression, Harrison groove, which corresponds with the costal insertions of the diaphragm.

Slight to moderate degrees of lateral curvature (scoliosis) are common, and a kyphosis may appear in the dorsolumbar region of rachitic children when sitting. Lordosis of the lumbar region may be seen in the erect position.

In children with lordosis, there is frequently a concomitant deformity of the pelvis, which is also retarded in growth. The pelvic entrance is narrowed by a forward projection of the promontory; the exit, by a forward displacement of the caudal part of the sacrum and the coccyx. In the female, these changes, if

they become permanent, add to the hazards of childbirth and may necessitate cesarean section.

Thickening of the wrist and ankles are other early evidences of osseous changes. The enlarged epiphyses can be seen or palpated but are not distinct in roentgenograms because they consist of cartilage and uncalcified osteoid tissue. Bending of the softened shafts of the femur, tibia, and fibula results in bowlegs or knock-knees; the femur and the tibia may also acquire an anterior convexity. Coxa vara is sometimes the result of rickets. Greenstick fractures occur in the long bones; often there are no clinical symptoms.

Increased sweating, particularly around the head, may also be present.

Relaxation of ligaments helps to produce deformities and partly accounts for knock-knees, overextension of the knee joints, weak ankles, kyphosis, and scoliosis.

The muscles are poorly developed and lack tone. As a result, children with moderately severe rickets are late in standing and walking. Potbelly depends to a large extent on weakness of the abdominal muscles.

Laboratory studies

1. common blood analysis – hypochromic anemia;
2. biochemical analyses of blood:
 - a) increase of alkaline phosphatase at the initial period of disease;
 - b) hypophosphatemia of a slight degree at the initial period of disease but marked at its height (normal level of phosphorus in blood – 0.97–1.62 mmol/l);
 - c) hypocalcemia of moderate or high degree at the height of disease (normal level of calcium in blood is 2.25– 2.75 mmol/l);
3. X-ray: disorders of periosteal and enchondral ossification in the bone's growth zone are revealed. Bone becomes low contrasted, cortical stratum becomes thinner, zones of enlightenment appear (Loozer's zones). Strip of preliminary calcification disappears (preparatory zone), the edge becomes illegible, loosened. Growth zone dilates, becomes fungus-like or glass-like. Epiphyseal nucleus appears lately.

Treatment of rickets

The replacement of Vitamin D may correct rickets using methods – of ultraviolet light and medicine.

Rickets heals promptly with 4 000 IU of oral vitamin D per day administered for approximately one month.

Parents are instructed to take their infants outdoors for approximately 20 minutes per day with their faces exposed. Children should also be encouraged to play outside.

Foods that are good sources of vitamin D include cod liver oil, egg yolks, butter and oily fish. Some foods, including milk and breakfast cereals, are also fortified with synthetic vitamin D.

1. Special therapy: Vitamin D therapy

A. General method: Vitamin D₃ (cholecalciferol) 2 000–5 000 IU/day for 2–4 weeks, then change to preventive dosage – 400 IU.

B. A single large dose: For severe case, or Rickets with complication, or those who can't bear oral therapy. Vitamin D₃ 200 000–300 000 IU, im, preventive dosage will be used after 2–3 months.

2. Calcium supplementation: dosage: 1–3 g/day only used for special cases, such as baby fed mainly with cereal or infants under 3 months of age and those who have already developed tetany.

3. Plastic therapy: in children with bone deformities after 4 years old plastic surgery may be useful.

Prevention of rickets

Prenatal prevention of rickets is carried out by obstetricians.

Prenatal specific prevention of rickets

Groups	Beginning of specific prophylaxis	Daily dose of vit D	Duration of vit D intake
Healthy pregnant	28–32 wk of gestation	500 IU	Every day during 6–8 wk
Pregnant from the group of risk (gestosis, diabetes mellitus, rheumatic fever, chronic disease of liver and kidneys, clinical signs of hypocalcaemia, disorders of bone mineralization)	28–32 wk of gestation	1 000–2 000 IU	Every day during 8 wk

Postnatal specific prevention of rickets

Groups	Beginning of specific prophylaxis	Daily dose of vit D	Duration of vit D intake
Mature healthy children	From the 2-th mo of life	500 IU	Every day during 3 yr excluding 3 summer mo (course dose for year – 180 000 IU)
	During 2-th, 6-th, 10-th mo of life	2 000 IU	Every day during 30 days, then up to 3 yr, 2–3 courses a year with interval 3 mo (course dose for every year – 180 000 IU)

Groups	Beginning of specific prophylaxis	Daily dose of vit D	Duration of vit D intake
Mature healthy children from the risk groups for rickets: children born by mothers with obstetrical and extragenital pathology; children suffering from malabsorption syndrome, with congenital hepatobiliar disorders, from twins, from the delivery with short interval between pregnancies, children on early artificial feeding	From 2–3 wk of life or	Depending on the state of children and living conditions 500–1 000 IU or	Every day up to 3 yr old age excluding summer mo
	From 2–3 wk of life and in the 6-th, 10-th mo of life	1 000–2 000 IU 2000 IU	Every day during 30 days, then up to 3 yr old age 2–3 courses every year with internal not less than 3 mo

Non-specific prevention signifies rational feeding, individual care, sufficient stay outdoors, gymnastics, massage.

Hypervitaminosis D

Hypervitaminosis D is a disease, which is stipulated by the toxic action of vitamin D and is characterized with intoxication of different degree, affection of organs and systems and development of hypercalcemia.

Diagnostic criteria

I. Clinical:

1. Syndrome of toxicosis:

Toxicosis of 1 degree – decrease of appetite, irritability, disorders of sleep, delay of weight increase, subfebrile temperature.

Toxicosis of 2 degree – pallor of skin, vomits, decrease of weight, functional disorders of internal organs and systems.

Toxicosis of 3 degree – anorexia, persistent vomits, dehydration, considerable loss of weight, complications such as pneumonia, pyelonephritis, myocarditis, pancreatitis.

2. Syndrome of functional disorders of nervous system:

flaccidity, apathy, alternating with excitability, irritability, drowsiness, hyperesthesia, sweating, meningism, encephalitic reactions, depression of consciousness, convulsions.

3. Cardio-vascular syndrome:

tachycardia, muffled cardiac sounds, systolic murmur, cyanosis, dyspnea, enlargement of liver, edemas. ECG disorders – dilation of QRS-complex, lengthening of PQ interval, smoothing of T-wave, diphasic T-wave in lead V₄.

4. Gastro-intestinal syndrome:

decrease of appetite up to anorexia, vomit, persistent constipation, rarely diarrhea, enlargement of liver and spleen.

5. Renal syndrome:

dysuric symptoms, polyuria, probably oliguria up to anuria, azotemia.

6. Changes in osseous system:

consolidation of the skull bones, early closure of big fontanel, craniostenosis.

II. Laboratory:

- blood: leucocytosis, elevated ESR;
- biochemical changes: hypercalcemia, hypophosphatemia, hypomagnesemia, hypokalemia, elevated levels of citrates and cholesterin;
- urine: increase of calcium, Sulkowitch's test is positive;
- stool: neutral fat;
- acid-base equilibrium – metabolic acidosis.

Classification of Hypervitaminosis D

Course	Form	Period
Acute (as neurotoxicosis or toxicosis with dehydration of 1–3 degree)	Nervous	Clinical manifestations
Chronic	Gastro-intestinal Renal Cardio-vascular	Residual signs

Treatment of Hypervitaminosis D

1) To cancel immediately vit D, and limited quantity of cow milk (that is rich in calcium).

2) Intensive detoxicative therapy: i.v. injections of albumin, 5 % solution of glucose with Ringer's solution, cocarboxylase, vit C, prednisolone (1–2 mg/kg), vit A (5–10 000 IU/day), vit E, furosemid (1 mg/kg 3 times/d), thyrocalcitonin (75–150 U i.m. every day), 3 % solution of ammonium chloride (1 teaspoonful 3 times a day), almagel, cholestiramine (0.5 g/kg 3 times/day), Trilon B 50 mg/kg 2–3 times/d orally, in severe cases – i.v. are used.

Tetany

Tetany is a disease stipulated by the disturbances of mineral metabolism, hypofunction of parathyroid glands and manifesting with elevated excitability of nervous-muscular apparatus and development of clonotonic convulsions.

Diagnostic criteria

I. Anamnestic data.

Wrong formula feeding, abuse of cow milk, groats and flour meals, insufficient stay at the fresh air, absence of rickets' prevention are revealed in the case history.

II. Clinical signs.

Tetany develops in children suffering from rickets. As a rule, children younger than 2–3 years may be ill both with rickets and tetany.

Clinically we can distinguish latent and manifest tetany.

Symptoms of latent tetany:

a) Chvostec's symptom – symptom of facial nerve, tapping on the place of outlet of facial nerve causes spastic contraction of mimicry facial muscles;

b) Weis's symptom – irritation of the place of outlet of trigeminal nerve (near the external acoustic meatus) leads to contraction of mimicry muscles;

c) Trousseau's symptom – squeezing of nerve-vascular bundle on the shoulder causes spastic contraction of hand's muscles – “obstetrician's hand“;

d) Lust's symptom – peroneal symptom, tapping lower the head of the fibula causes dorsal flexion and opening of feet's fingers;

e) Maslov's symptom – prick on the heel causes apnoe instead of quickening of breathing;

f) Erb's symptom – closing of cathode on the muscle leads to its spasm while strength of the current is less than 5 mA.

Symptoms of manifest tetany:

a) laryngospasm – convulsive spasm of true glottis during inspiration accompanied by “cock-cry” and development of cyanosis attack;

b) carpo-pedal spasm – tonic convulsions of extremities' muscles;

c) general tonic convulsions of body's muscles, mimic muscles (epileptoid convulsions) with unconsciousness;

d) expiratory apnoe – stop of respiration on expiration with development of attack of general cyanosis.

Convulsive spasm of a heart muscle leading to child's death is possible.

III. Laboratory diagnostics.

Hypocalcemia (to 1,2–1,5 mmol/l), quantity of inorganic phosphorus is relatively elevated. Alkalosis is seen in some children.

Differential diagnosis is conducted with hyperthermic convulsions, complicated pneumonia, meningitis, viral diseases, and epilepsy.

Treatment of Tetany

I. First aid.

- At a laryngospasm – to clap on cheeks, to wash by cold water;
- At cramps – Seduxen (0,5 % solution, 0,1 mg/kg), simultaneously a calcium drug – 20 mg/kg calcium IV over 10–20 minutes
- Equal to: 2 mL/kg 10 % calcium gluconate 0.7 mL/kg 10 % calcium chloride

II. Correction of a feed (limitation of the cow milk, increase vegetables and fruits).

- Drugs of calcium (10 % solution of calcium of a gluconate at the rate of 50 mg/kg/day).
- After normalization of a level of calcium in a blood - treatment by vitamin D3 (2 000–5 000 IU 30–45 days depending on a degree of gravity of a rickets).

Control questions

1. What is formed during first hydroxylation?
A. *tachysterol* C. *1,25-OH-D3* E. *vitamin D2*
B. *calcitriol* D. *Calcidiol*
2. What are the actions of 1,25 DHC on the child's body?
A. *increased mineralization*
B. *decreased PTH secretion*
C. *increased absorption of Ca in intestine*
D. *increased reabsorption of P in the kidney*
E. *everything is correct*
3. Flattening of occiput, rickets rosary, increase of frontal and parietal eminences, enlargement of big fontanel are present in a baby of 4 months. What additional examinations are necessary for verification of the diagnosis?
A. *Urine test, coprocytogram*
B. *Blood test and urine test*
C. *Proteinogram, indices of acute phase*
D. *Calcium and phosphorus in blood, functional liver tests*
E. *Hemorenal tests, hematocrit*
4. A baby of 3 months from twins is presented with the following: he poorly supports his head, craniotables, increase of head circumference, enlargement of liver up to +4 cm are present. Level of serum calcium is 1,6 mmol/l, alkaline phosphatase – 7,5 mmol/l. What is the diagnosis?
A. *Rickets of III degree, acute course*
B. *Rickets of I degree, subacute course*
C. *Rickets of II degree, recurrent course*
D. *Rickets of II degree, period of convalescence*
E. *Rickets, period of residual signs*
5. There are rickets' rosary and O-shaped legs in a boy of 3 years old. Level of serum calcium is 2,6 mmol/l, P – 1,9 mmol/l, alkaline phosphatase is normal. What is the diagnosis?
A. *Rickets of II degree, period of height of disease*
B. *Rickets of II degree, period of convalescence*
C. *Rickets, period of residual signs*
D. *Rickets of III degree, period of convalescence*
E. *Rickets of I degree, initial period*

6. Softening of fontanel's edge, flattening of occiput, parietal and frontal bossing, rickets' rosary, muscular hypotonia and enlargement of liver +3 cm are revealed in a boy of 6 months old. Ca in blood was 2,0 mmol/l, level of alkaline phosphatase in blood was elevated. What daily dose of vitamin D is it necessary to prescribe?

- A. 7 000 IU
B. 1000 IU
C. 3 000 IU
D. 10000 IU
E. 500 IU

7. Diagnosis of rickets of II degree is established in a baby of 5 months. What daily dose of vitamin D is he in need of?

- A. 10 000 IU
B. 1000 IU
C. 500 IU
D. 3 000 IU
E. 7 000 IU

8. Diagnosis of rickets, residual signs is established in a child of 3 years old. Please, prescribe treatment.

- A. Vitamin D 500 IU daily
B. Health promotion program
C. Calcium gluconate p.o.
D. Vitamin D and calcium p.o.
E. Vitamin D 2000 IU daily

9. A baby is 10 days. He was born at gestational age of 29–30 weeks with body weight 1100 g. What dose of vitamin D is necessary for prophylaxis of rickets?

- A. 3 000 IU
B. 500 IU
C. 5 000 IU
D. 1 000 IU
E. 10 000 IU

10. Sonorous inspiration, short-term apnoe, paleness and afterwards cyanosis and unconsciousness appeared in a baby of 9 months during cry. Signs of rickets were revealed objectively. Ca in blood was 1,6 mmol/l. What is your diagnosis?

- A. Epilepsy
B. Tetany, manifest form, laryngospasm
C. Tetany, latent form
D. Stenosing laryngotracheitis
E. Foreign body of respiratory tract

11. Hoarse inspiration, paleness and afterwards cyanosis and unconsciousness appeared in a baby of 11 months with signs of rickets of II degree during cry. What urgent actions are necessary in this patient?

- A. Lasix i.v.
B. Seduxen i.m.
C. Irritation of nasal mucous and skin, shaking of a baby
D. Cordiamine i.v.
E. Magnesium sulfate i.m.

12. Anorexia, vomiting, muscular weakness and increased anxiety are seen in a baby of 2 months. From anamnesis it is known that a child received vitamin D 30 000 IU daily during 14 days. Objectively: general condition is severe, signs of dehydration, liver is +4 cm below rib's arch. What diagnosis is most probable?

- A. Functional disorders of stomach
B. Tetany
C. Rickets, period of height of disease
D. Hypervitaminosis D
E. Pylorostenosis

List of references

1. Allgrove J. Calcium deficiency rickets: extending the spectrum of 'nutritional' rickets / J. Allgrove, M. Z. Mughal // *Arch Dis Child*. – 2014. – Vol. 99, N 9. – P. 794–795.
2. Caruso T. J. Images in clinical medicine. Severe vitamin D deficiency – rickets / T. J. Caruso, G. Fuzaylov // *N. Engl. J. Med*. – 2013. – Vol. 369, N 9. – P. 11.
3. Chesney R. W. The Decade of Ideas Leading to a Cure for Rickets / R. W. Chesney // *The Journal of Pediatrics*. – 2011. – Vol. 160, Iss. 3. – P. 508–510.
4. Elder C. J. Rickets / C. J. Elder, N. J. Bishop // *The Lancet* – 2014. – Vol. 383, N 9929. – P. 1665–1676.
5. Feldman D. Vitamin D / D. Feldman, J. W. Pike, J. S. Adams – Two-Volume Set, 2011. – 2144 p.
6. Hochberg Z. Vitamin D and Rickets / Z. Hochberg – Rambam Medical centrum, 2003. – 250 p.
7. Holick M. F. High prevalence of vitamin D inadequacy and implications for health / M. F. Holick // *Mayo Clin. Proc*. – 2006. – Vol. 81. – P. 353–373.
8. Holick M. F. Resurrection of vitamin D deficiency and rickets / M. F. Holick // *J. Clin. Invest*. – 2006. – Vol. 116, N 8. – P. 2062–2072.
9. Holick M. F. Vitamin D. In modern nutrition in health and disease / M. F. Holick // USA : Lippincott Williams & Wilkins, 2005. – P. 329–345.
10. Odinets Y. V. Pediatrics / Y. V. Odinets, A. F. Ruchko, I. N. Poddubnaya. – Kharkov : Kruk, 2003. – 224 p.
11. Spence J. T. Secondary Prevention of Vitamin D-Deficiency Rickets / J. T. Spence, J. R. Serwint // *Pediatrics*. – 2004. – Vol. 113, N 1. – P. 70–72.
12. Thacher T. D. Vitamin D treatment in calcium-deficiency rickets: a randomised controlled trial / T. D. Thacher, P. R. Fischer, J. M. Pettifor // *Arch Dis Child*. – 2014. – Vol. 99, N9. – P. 807–811.
13. Whyte M. P. Rickets and osteomalacia / M. P. Whyte, R. V. Thakker // *Medicine*. – 2013. – Vol. 41, Iss. 10. – P. 594–599.

Навчальне видання

РАХІТ. ГІПЕРВІТАМІНОЗ D. СПАЗМОФІЛІЯ

Методичні вказівки для студентів

Упорядники Одинець Юрій Васильович
 Макєєва Наталія Іванівна
 Головачова Вікторія Олександрівна
 Триндюк Юліанна Сергіївна

Відповідальний за випуск Ю. В. Одинець



Комп'ютерна верстка О. Ю. Лавриненко

Формат 60×84/16. Ум. друк. арк. 1,0.
Зам. № 16-3378.

**Редакційно-видавничий відділ
ХНМУ, пр. Леніна, 4, м. Харків, 61022
izdat@knu.kharkov.ua**

Свідоцтво про внесення суб'єкта видавничої справи до Державного реєстру видавництв, виготівників і розповсюджувачів видавничої продукції серії ДК № 3242 від 18.07.2008 р.

**RICKETS.
HYPERVITAMINOSIS D.
TETANY**

Practical policies for students