

# Noninvasive fetal electrocardiography for the detection of fetal arrhythmias

Joachim A. Behar<sup>1</sup>  | Laurent Bonnemains<sup>2</sup> | Vyacheslav Shulgin<sup>3</sup>  | Julien Oster<sup>4\*</sup>  | Oleksii Ostras<sup>5\*</sup> | Igor Lakhno<sup>6\*</sup>

<sup>1</sup>Biomedical Engineering Faculty, Technion—Israel Institute of Technology, Haifa, Israel

<sup>2</sup>INSERM IADI, Nancy and University Hospital of Strasbourg, Strasbourg, France

<sup>3</sup>Aerospace Radio-Electronic Systems Department, National Aerospace University, Kharkiv Aviation Institute, Kharkiv, Ukraine

<sup>4</sup>IADI, U1254, INSERM, Université de Lorraine, Nancy, France

<sup>5</sup>Fetal Cardiology Unit, Ukrainian Children's Cardiac Center, Kyiv, Ukraine

<sup>6</sup>Obstetrics and Gynecology Department, Kharkiv Medical Academy of Postgraduate Education, Kharkiv, Ukraine

## Correspondence

Joachim A. Behar, Biomedical Engineering Faculty, Technion—Israel Institute of Technology, Haifa, Israel.  
Email: jbehar@technion.ac.il

## Funding information

The Center for Absorption in Science, Ministry of Aliyah and Immigrant Absorption, State of Israel (JB)

## Abstract

**Objective:** To assess whether noninvasive fetal electrocardiography (NI-FECG) enables the diagnosis of fetal arrhythmias.

**Methods:** A total of 500 echocardiography and NI-FECG recordings were collected from pregnant women during a routine medical visit in this multicenter study. All the cases with fetal arrhythmias ( $n = 12$ ) and a matching number of control ( $n = 14$ ) were used. Two perinatal cardiologists analyzed the extracted NI-FECG while blinded to the echocardiography. The NI-FECG-based diagnosis was compared with the reference fetal echocardiography diagnosis.

**Results:** NI-FECG and fetal echocardiography agreed on all cases ( $Ac = 100\%$ ) on the presence of an arrhythmia or not. However, in one case, the type of arrhythmia identified by the NI-FECG was incorrect because of the low resolution of the extracted fetal P-wave, which prevented resolving the mechanism (2:1 atrioventricular conduction) of the atrial tachycardia.

**Conclusion:** It is possible to diagnose fetal arrhythmias using the NI-FECG technique. However, this study identifies that improvement in algorithms for reconstructing the P-wave is critical to systematically resolve the mechanisms underlying the arrhythmias. The elaboration of a NI-FECG Holter device will offer new opportunities for fetal diagnosis and remote monitoring of problematic pregnancies because of its low-cost, noninvasiveness, portability, and minimal setup requirements.

## 1 | INTRODUCTION

Fetal cardiac arrhythmias (ARRs) are defined as any irregular fetal cardiac rhythm or regular rhythm at a rate outside the reference range of 100 to 200 beat per minute (bpm).<sup>1</sup> ARR are discovered in about 1% of fetuses with about 10% of these being considered potential sources of morbidity.<sup>2</sup> Although most fetal ARR are benign, some can cause fetal hydrops and lead to fetal death.<sup>3</sup> This means that up to one fetus in 100 need their ARR to be closely monitored and if indicated treated in utero using antiarrhythmic therapy.<sup>4</sup> Thus, there is a clear

motivation for elaborating a portable system, which enables the diagnosis and remote monitoring of the fetal heart.

The principal method of fetal heart rhythm assessment is fetal echocardiography. It allows a correct detection of both atrial and ventricular activity either in motion mode (M-Mode) or in pulsed wave (PW) Doppler mode. However, continuous echocardiographic recordings are usually short (typically limited to a few seconds per loop<sup>5</sup>), require the physician to manipulate the probe manually, and can only be performed within a clinical environment. Conventional cardiotocography is more accessible; however, it only allows to monitor the ventricular ejection of blood and is therefore unable to provide any information on atrial activity nor on atrioventricular conduction. In addition, it is unable to extract the beat-to-beat variability of the fetal heart rate because of the averaging nature of the

\*Co-senior authorship

Part of the work was presented at the 15th Annual Meeting of the "Filiale de Cardiologie Pédiatrique et Congénitale" (FCPC), affiliated to the French Society of Cardiology, in Lille, 12–14 September 2018.

autocorrelation function used for estimating the fetal heart rate.<sup>6,7</sup> Magnetocardiography provides perinatal cardiologists with the electrocardiogram waveform tracing, but this hardware is not available in low- and middle-income countries due to its high cost.<sup>8</sup> Another recording modality, the STAN (STAN, Neoventa Medical, Molndal, Sweden) invasive fetal electrocardiography (ECG) monitor has shown some improved fetal outcome over cardiotography at delivery.<sup>9</sup> However, this technique is invasive and can only be used at delivery. Noninvasive fetal electrocardiography (NI-FECG) is a promising noninvasive fetal diagnosis and monitoring alternative, which presents a number of advantages: low cost, possibility of local analysis (no need of long distance referral for pregnant women), information on atrial and ventricular activity, motion estimation,<sup>10</sup> and possibility of continuous long-term remote monitoring. The results of recent studies have shown the ability of the NI-FECG to provide an accurate estimate of the fetal heart rate.<sup>11-16</sup> However, to date, the clinical usability of NI-FECG has rarely been studied. This work investigates the feasibility and interest for a fetal Holter ECG device in the context of fetal ARR detection.

## 2 | METHODS

A total of 500 echocardiography and corresponding NI-FECG recordings were collected from pregnant women during a routine medical visit in this multicenter study. All the cases diagnosed with fetal ARR (n = 12, median gestational age of 36 weeks, range 22-41 weeks) by echocardiography and a matching number of control diagnosed with a normal rhythm (NR, n = 14, median gestational age of 21 weeks, range 20-36 weeks) were used. Thus, a total of 24 pregnant women (two of whom had NR twins, which we kept) were included in this analysis. The prevalence of fetuses having an ARR was 2.3% in our population. Table 1 summarizes the characteristics of the dataset.

Echocardiography and NI-FECG were collected during a routine medical visit, ie, in a clinical setting. The details of the recorded fetal cases are given in Table S2. All pregnant women were included after a conventional examination at the Kharkiv municipal perinatal center (ARRs 6-10, Table S1, recorded between December 2013 and August 2017) or at the Ukrainian Children's Cardiac Center in Kyiv (ARR 1-5, 11, and 12 and all NRs, Table S1, recorded between July 2013 and January 2014). The study complies with the Declaration of Helsinki regarding medical research involving human subjects. It was approved by the Bioethics Committee of the Kharkiv Medical Academy of Postgraduate Education and Ukrainian Children's Cardiac Center and registered under the ID 0105U002865.

Echocardiographic examinations were conducted in accordance with AIUM recommendations<sup>17</sup> and included M-mode, B-mode,

**TABLE 1** Summary of the fetal cases recorded

	ARR Cases	NR Cases
Sample size	12	14
Average NI-FECG record length (min:s)	13:03	10:06
Gestational age, weeks ( $\mu \pm \sigma$ )	32 $\pm$ 6.8	23 $\pm$ 4.8
Number of events detected ( $\mu \pm \sigma$ )	46.8 $\pm$ 34.5	2 $\pm$ 2.6
P-wave visibility (%)	83	57

Abbreviations: ARR, arrhythmia; NR, normal rhythm.

### What's already known about this topic?

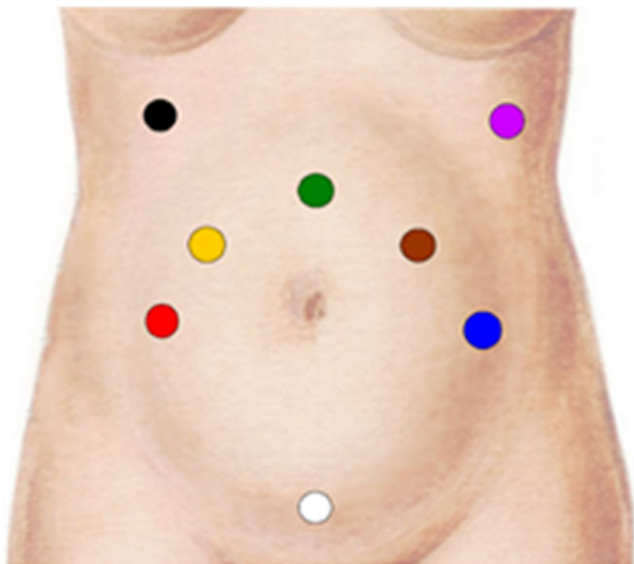
- Several studies have shown the ability of NI-FECG to accurately estimate the fetal heart rate.
- Some studies showed that conduction information can be retrieved from the morphology of the reconstructed NI-FECG.
- However, the potential of NI-FECG for providing clinically actionable information has rarely been assessed.

### What does this study add?

- We show, for the first time, that NI-FECG allows to identify fetal arrhythmias and in most cases provides additional information on the rhythm disturbances than echocardiography.
- We identify the main engineering issues remaining in the current state of the technology for making NI-FECG a competitive diagnosis and monitoring option.
- We provide a unique open access dataset of NI-FECG with arrhythmias. This will allow further research and reproducibility of our analysis.

color-flow mapping, and pulsed Doppler techniques in every case. The Philips iU22 Ultrasounds was used (Philips Healthcare, Bothell, Washington). Protocols of investigation were based on segmental approach. For heart rhythm evaluation, simultaneous assessment of atrial and ventricular contractions were conducted using M-mode sonography of the atrium and ventricle as well as Doppler sonography of the mitral inflow-aortic outflow (when the inflow waves could be clearly identified).

NI-FECG was recorded following the echocardiography during the same routine medical visit. Typically, the time interval between the echocardiography and NI-FECG was less than half an hour. NI-FECG were recorded using the Cardiolab Babycard equipment ("KhAI Medica," Ukraine)<sup>18,19</sup>: the equipment consisted of five to six abdominal electrodes placed on the maternal abdomen and two chest (ground and maternal electrocardiography [MECG]) electrodes (Figure 1). The electrodes were connected to the Cardiolab portable ECG monitoring device for the recording of the following signals: 1 chest lead and 4 to 5 abdominal leads. Data were acquired at a sampling frequency of 500 Hz (ARRs 6-9, Table S1) or 1000 Hz (ARRs 1-5 and 10-11 and all NRs, Table S1) and with a 16-bit resolution and a range of  $\pm 8$  mV. Data were recorded continuously for variable durations with a minimum of 7 minutes and up to 32 minutes (see Table S1). The variation in the electrode number and sampling frequency comes from technical improvements made to the research monitoring system during the trial. We contributed our dataset publicly on [physionet.org](http://physionet.org).

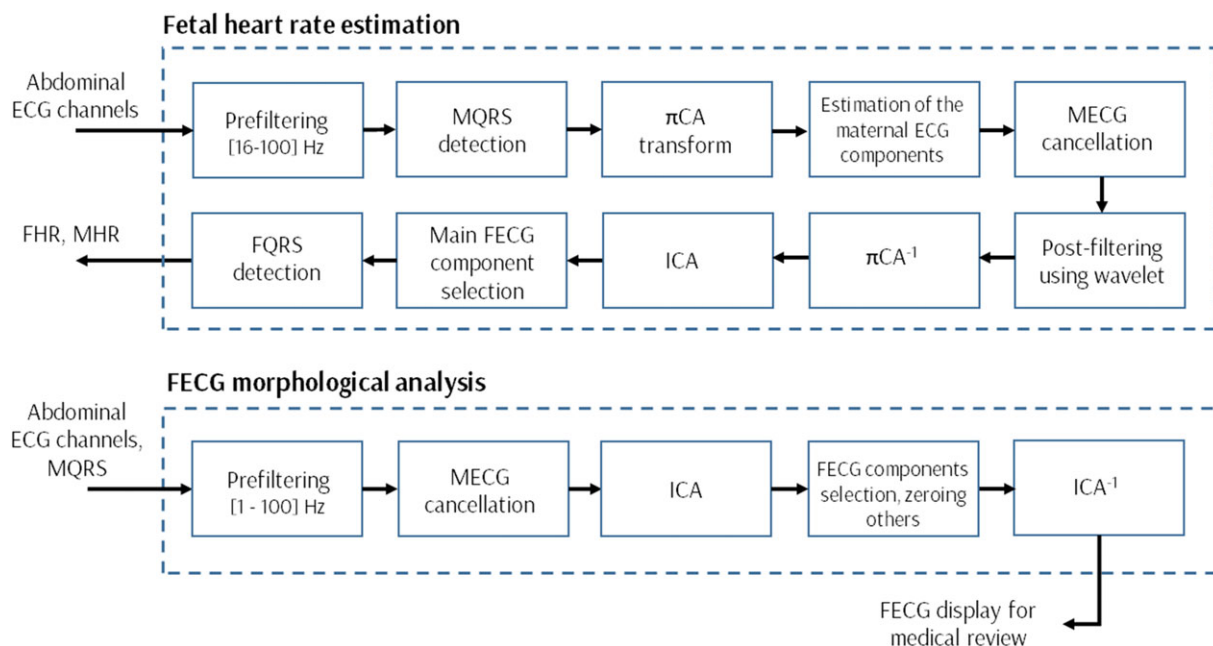


**FIGURE 1** Block diagram of the fetal heart rate (FHR) and fetal electrocardiography (ECG) morphology estimations.  $\pi$ CA: Periodic component analysis; ICA: Independent component analysis; MQRS: Position of the maternal R-peaks; MECG: maternal ECG; FECCG: fetal ECG; FQRS: position of the fetal R-peaks. The superscript  $-1$  specify an inverse transform [Colour figure can be viewed at [wileyonlinelibrary.com](http://wileyonlinelibrary.com)]

The methods for separating the fetal ECG from the abdominal mixture were presented in previous studies<sup>18,19</sup> and are summarized in Figure 2, and an example is given in the supplementary material (slides 53-65); briefly, in a first step, the data are prefiltered, the maternal R-

peaks (MQRS on the chest lead) are detected, using the detected maternal R-peaks; periodic component analysis ( $\pi$ CA)<sup>20</sup> is used to extract and estimate the maternal ECG in the component space. Then, the averaged maternal ECG cycle is subtracted to each individual maternal beats in order to remove the maternal ECG contribution to each of the channels as estimated by  $\pi$ CA. The residual signals (ie, after maternal cancellation) is locally filtered (around the MQRS position) using wavelet in the source space and then back projected to the original observation space using the inverse  $\pi$ CA transform. Finally, an independent component analysis (ICA) step is applied for the FECCG component extraction, and the fetal R-peaks are detected in the ICA-estimated source space. This first step allows robust estimation of the fetal heart rate. In a second step, the abdominal signal is processed with a weaker prefiltering step (1-100 Hz); in order to preserve the fetal ECG morphology, the maternal ECG is cancelled, ICA transform is performed, and finally fetal component(s) are selected and back projected in the observation space. The results is a set of abdominal FECCG channels free of maternal components and which can be used for morphological analysis. The reasons for performing morphological analysis in the observation space and not the ICA are explained in the study of Andreotti et al.<sup>21</sup>

Automatic extraction of the NI-FECCG and fetal heart rate estimation were performed using the Cardiolab CS software (Scientific and research center "KhAI Medica," Ukraine). The raw maternal ECG, extracted NI-FECCG, and fetal R-peak locations (FQRS) were exported to text file for postprocessing in MATLAB (MathWorks, Natick, Massachusetts). An event detector algorithm was run to automatically detect abnormal rhythm events. Such events were defined as (a) a rapid change in the periodicity of the heart beats, (b) a rhythm below



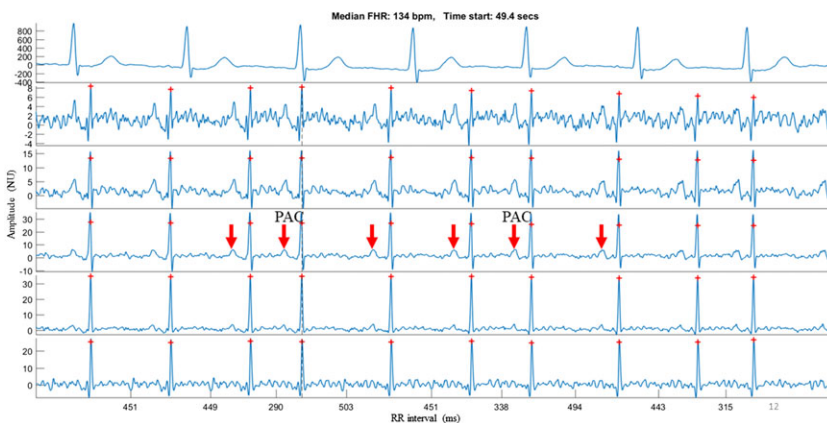
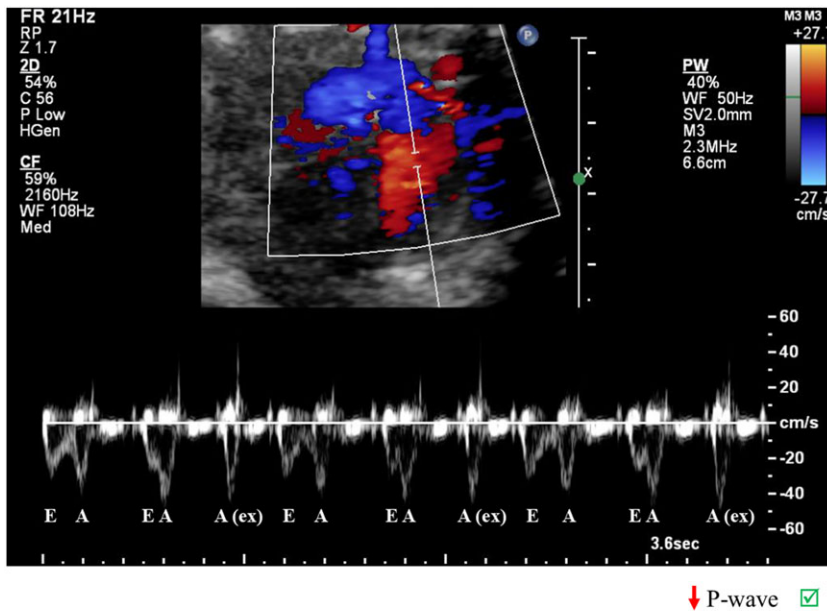
**FIGURE 2** Electrodes disposition and noninvasive fetal electrocardiography (NI-FECCG) extraction. A, Cardiolab Babycard (scientific and research center "KhAI Medica," Ukraine)<sup>18,19</sup> electrode placement as shown on the figure: 1-5 abdominal electrodes (red, yellow, green, brown, and blue) with common reference (white), active ground (black), and one chest electrode (purple). Leads are defined as:  $V_{Ab1} = V_{red} - V_{white}$ ,  $V_{Ab2} = V_{yellow} - V_{white}$ ,  $V_{Ab3} = V_{green} - V_{white}$ ,  $V_{Ab4} = V_{brown} - V_{white}$ ,  $V_{Ab5} = V_{blue} - V_{white}$ ,  $V_{Th1} = V_{purple} - V_{white}$ ; B, the abdominal electrocardiography (ECG) mixture is then separated to extract the NI-FECCG; C, abnormal rhythms events can be identified from the extracted NI-FECCG signal. For all ECG figures, the red crosses indicate the location of the fetal beats [Colour figure can be viewed at [wileyonlinelibrary.com](http://wileyonlinelibrary.com)]

100 bpm (bradycardia), or (c) a rhythm exceeding 200 bpm (tachycardia).<sup>1</sup> When an abnormal rhythm event was detected by the algorithm, a 4.5-second NI-FECG strip of the NI-FECG trace was automatically generated at this time location (eg, Figure 3B). The corresponding maternal ECG traces were also presented to the perinatal cardiologists.

The 26 NI-FECG recordings were randomized, and the generated event strips of each randomized recording were presented to two perinatal cardiologists for diagnosis. Analysis was made in the similar manner as a Holter data review. The perinatal cardiologists were blinded to the echocardiographic diagnosis. In addition to the figures generated by the event detector, the experts also had access to the whole recordings from the Cardiolab CS software ("KhAI Medica," Ukraine), which allowed to scroll through the entire recording if needed. The perinatal cardiologists first performed their diagnosis independently. In a second phase, they discussed each case and agreed on an adjudicated diagnosis and whether they considered the overall case as NR or having an ARR. Following their adjudications, the NI-FECG-based diagnoses were compared with the echocardiographic ones. In addition, the perinatal cardiologists noted whether the atrial activity (P-wave) was visible for each NI-FECG case. For the ARR cases, the P-wave was deemed visible if it could be seen during the ARR events on at least one of the NI-FECG-extracted

abdominal channel and thus allowed to characterize the mechanism of the ARR. For NR cases, the P-wave was deemed visible if it could be seen during most of the recording on at least one NI-FECG-extracted channel.

The following medical terminology was used in this study: extrasystoles were characterized by their origin and referred as premature atrial contractions (PAC), premature junctional contractions (PJC), and supraventricular extrasystoles (SVES). SVES encompass both PAC and/or PJC and is used when the exact origin of the premature beat (either atrial or junctional) could not be specified by the expert perinatal cardiologists. We distinguish between "blocked" and "nonconducted" beats; "blocked" beats are characteristic of atrioventricular node dysfunction while "nonconducted beats" are suggestive of normal atrioventricular refractoriness. A sequence of a few rapid beats (with a minimum of three) is called "salvo." In order to identify PJC from echocardiography, M-mode was used to identify the atrial and ventricular contractions, and atrial to ventricular (AV) and ventricular to atrial (VA) delays were computed. The presence of PJC was then defined according to Fouron<sup>22</sup>: PJC correspond to the situations where the onset of atrial and ventricular contractions are simultaneous (or VA is very small). On the contrary, the presence of PAC imply either a unique isolated A wave or an A wave before next V wave (and thus  $VA > AV$ ).



**FIGURE 3** Trigeminy (ARR 3). Example observed in ARR 3. A, Trigeminy observed using fetal echocardiography, pulsed wave (PW), left ventricular inflow pattern. B, Trigeminy captured using the noninvasive fetal electrocardiography (NI-FECG) (see the N-N-Ex-N-N-Ex pattern). The P-waves are visible on some of the extracted NI-FECG channels including for the extrasystoles thus allowing to characterize the extrasystoles as premature atrial contraction (PACs) [Colour figure can be viewed at [wileyonlinelibrary.com](http://wileyonlinelibrary.com)]

### 3 | RESULTS

The recording of NI-FECG was successful for all the pregnant women who were included. Table 1 presents the average duration of the 26 extracted NI-FECG, the gestational age at the time of the recording, and the number of abnormal rhythm events detected by the NI-FECG event detection algorithm. This data is also available for each individual case in Table S1. The numbers of detected events were in the range of 7 to 118 for the ARR fetuses in comparison with 1 to 10 for the NR fetuses. On the basis of the review of these events, the perinatal cardiologists accurately recognized the following rhythm disorders in our dataset: six extrasystoles (eg, Figure 3), two tachyarrhythmia (eg, supplementary PowerPoint ARR 8), one bradyarrhythmia (supplementary PowerPoint ARR 2), one irregular atrial rhythm, and one case with blocked normal P-waves (Figure 4). Table 2 shows the overall diagnosis obtained by the fetal echocardiography and the NI-FECG (see column "ARR/NR"). NI-FECG and fetal echocardiography agreed in all cases (26/26) on whether the fetus was NR or ARR (see Table 2).

Table 2 shows the precise diagnosis obtained by the fetal echocardiography and the NI-FECG for the ARR cases. In 19/26 cases, the diagnoses were identical. In seven cases, the diagnoses differed: in three cases (ARR 1, ARR 6, and ARR 7), one type of extrasystoles was identified by the short echocardiography whereas two types of extrasystoles were identified on the longer NI-FECG strips; in one case (ARR 9), the NI-FECG and echocardiography both identified extrasystoles but disagreed on their origin (ie, junctional versus atrial); for case ARR 10, the same events (blocked normal P-waves) were detected on the NI-FECG and fetal echocardiography, but the interpretation of the events differed. In ARR 5, both NI-FECG and the

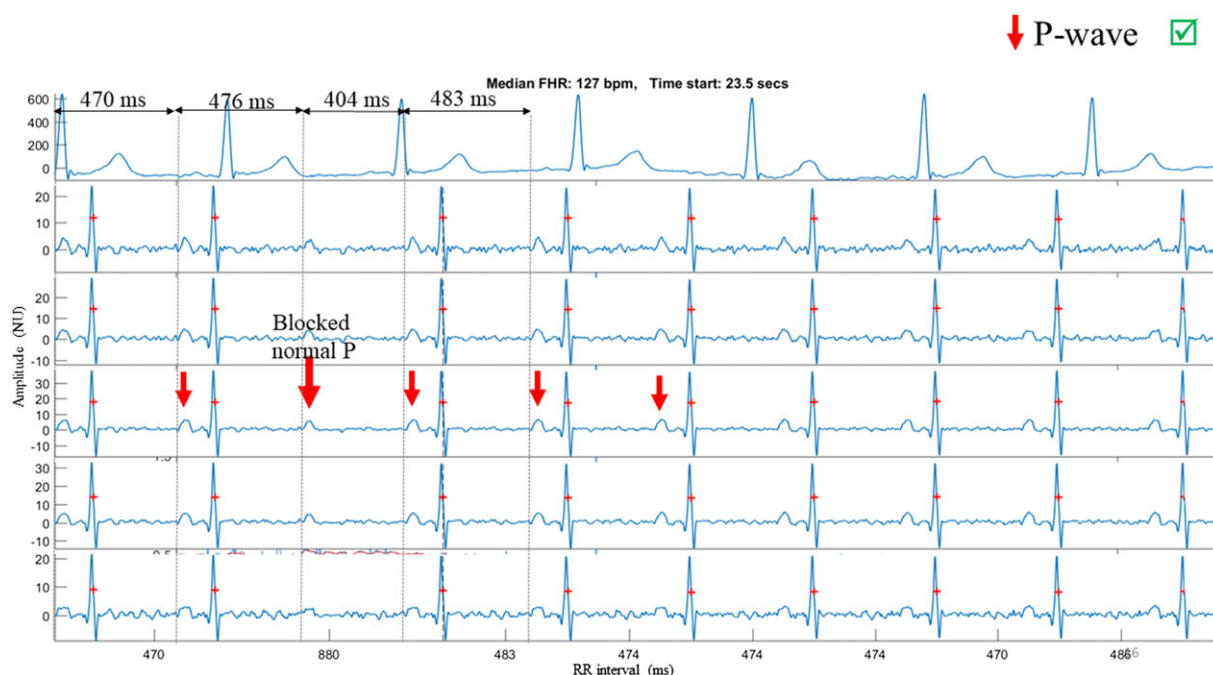
echocardiography identified the tachycardia. However, based on the NI-FECG, the perinatal cardiologists could only specify that the mechanism was supraventricular while the echocardiography showed it was of junctional origin. In the case of ARR 11, the NI-FECG-based diagnosis identified that the fetus was arrhythmic but it did not identify the correct arrhythmia i.e. atrial tachycardia with 1:2 AV conduction due to the impossibility of resolving the P-wave for this case.

The NI-FECG based diagnosis usually had additional information in comparison with the fetal echocardiography (see Table 2, "Refinement" column) such as the presence of salvo (ARR 6) or intermittent bundle branch block (ARR 1).

### 4 | DISCUSSION

Our first main conclusion is that NI-FECG can be used for the diagnosis of fetal ARRs. NI-FECG was able to accurately flag all the cases with rhythm disturbances (Table 2). For all the NR records, the number of events detected by our algorithm was very low (Table 1 and Table S1), and in most cases, these were due to noise.

Our second main conclusion is that NI-FECG provides, in a majority of cases, additional information compared with fetal echocardiography (see Table 2). This is because the NI-FECG allows to appreciate over a longer time period the rhythm abnormalities and thus can provide more details on the abnormal rhythm events that are present. In case ARR 10, this led to a more precise diagnosis: based on the short fetal echocardiography, the diagnosis was second degree atrioventricular block whereas occurrence of these blocked normal P-wave were judged too rare over the longer NI-FECG recording, and thus this case was diagnosed as "isolated blocked normal P-wave."



**FIGURE 4** Blocked P-wave (ARR 4). Example observed on ARR 4. The noninvasive fetal electrocardiography (NI-FECG) shows the presence of a P-wave which is not conducted to the ventricle (ie, blocked) and thus does not give rise to a QRS complex. The original fetal echocardiography did not capture such events. This refinement obtained using the NI-FECG can be clinically relevant as this could be the beginning of a second degree intermittent atrioventricular block. P-wave are indicated by the red arrows [Colour figure can be viewed at [wileyonlinelibrary.com](http://wileyonlinelibrary.com)]

**TABLE 2** Comparison of echocardiography and ECG diagnosis for the arrhythmic cases

Case	ARR/NR		Echo Arrhythmia Diagnosis	NI-FECG			
	Echo	ECG		NI-FECG arrhythmia Diagnosis	Refinement	Error	P-wave Visibility
ARR 1	ARR	ARR	PAC	PAC and PJC	Intermittent BBB Nonconducted PAC		✓
ARR 2 <sup>a</sup>	ARR	ARR	Atrial bradycardia	Atrial bradycardia			✓
ARR 3	ARR	ARR	PAC	PAC	One PAC salvo		✓
ARR 4	ARR	ARR	PAC	PAC	Few normal blocked P-waves. Could be the beginning of a second degree intermittent AV-block.		✓
ARR 5	ARR	ARR	Paroxysmal junctional tachycardia	Paroxysmal SV tachycardia	PAC		✗
ARR 6	ARR	ARR	PJC	PAC and PJC	Nonconducted PAC. Two atrial salvo, blocked normal P-wave.		✓
ARR 7	ARR	ARR	PJC	PAC and PJC	Blocked normal P-wave (likely) nonconducted PAC	J <> A	✓
ARR 8	ARR	ARR	Atrial tachycardia PAC	Atrial tachycardia PAC	Nonconducted PAC PAC salvo		✓
ARR 9	ARR	ARR	PJC	PAC		J <> A	✓
ARR 10	ARR	ARR	Intermittent second degree AVB	Blocked normal P-wave. Could be the beginning of a second degree AVB	Too few events to be called second degree AVB		✓
ARR 11	ARR	ARR	Atrial tachycardia, generally 2:1 AV conduction	Blocked P-wave or sinus pause		Inaccurate	✗
ARR 12	ARR	ARR	Irregular atrial rhythm	Irregular atrial rhythm			✓

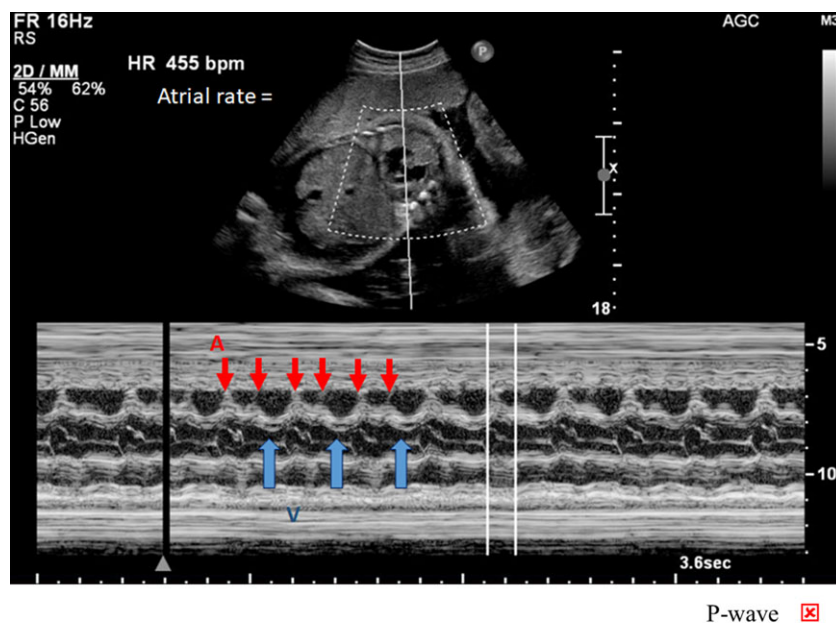
Abbreviations: ARR, arrhythmia; AVB, atrioventricular block; BBB, bundle branch block; NR, normal rhythm; PAS, premature atrial contractions; PJC, premature junctional contractions; SVES, supraventricular extrasystoles.

<sup>a</sup>Twin of NR 13.

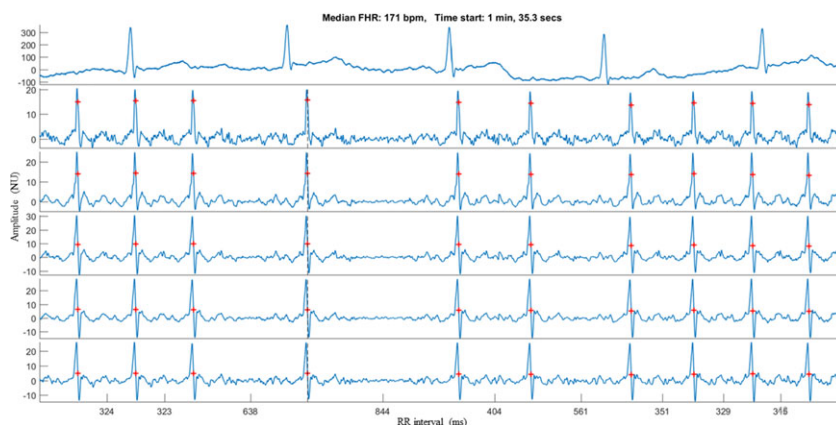
Our third main conclusion is that the NI-FECG provides additional fetal monitoring opportunities; (a) abnormal rhythm events can be automatically detected on the NI-FECG using an event detection algorithm. These events can be presented to a perinatal cardiologist, similar to a usual Holter review. Such event detector can be run on long-term NI-FECG recordings during home monitoring and thus may provide a better appreciation on whether or not the fetus presents a rhythm disorder. In particular, for intermittent fetal tachycardia, the durations and frequency of the tachycardia episodes could be obtained and assist in the decision making as per whether treatment is or not indicated. It can also detect intermittent ARR, which could be easily missed during the short standard fetal echocardiography examination; (b) NI-FECG can allow for the characterization of some bundle branch blocks conduction events as shown for ARR 1. Such events cannot be diagnosed by conventional fetal echocardiography; (c) The NI-FECG can provide a very precise RR interval time series and therefore open for the possibility of fetal heart rate variability studies with standard heart rate variability measures used in adult human and animal studies.<sup>23</sup>

Our fourth main conclusion is that in the current state of the NI-FECG technology, the technique does not allow to systematically resolve the mechanisms of the ARRs. This stems from the difficulty in appreciating the atrial activity (ie, the P-wave) on the NI-FECG

traces. The cardiologist could appreciate the atrial activity (P-wave) in the NI-FECG in only 69% of the cases, because of the low signal to noise ratio (see Table 2 and Supplementary PowerPoint). This figure is close to the one reported by Chia et al<sup>24</sup> who reported detecting 74.6% of the P-waves on averaged beats of their dataset. However, even in the cases where the P-wave could be identified visually, the resolution was low, and the perinatal cardiologists often had to spend time interpreting the traces. In ARR 11, although the two perinatal cardiologists identified an ARR for this fetus, they both made an incorrect diagnosis (Table 2 and Figure 5). Indeed, in order to diagnose an atrial tachycardia with 2:1 AV conduction, it is necessary to be able to clearly appreciate the atrial activity (ie, P-wave) on the NI-FECG strip. In the current state of the art NI-FECG does not always allow to identify these important events. A better resolution of the P-wave is also required to resolve first degree atrioventricular block from the NI-FECG for a precise measurement of the PR interval. In addition, the length and shape of the P-wave will also be influenced by the position of the electrodes with respect to the fetal heart. This phenomena is known as P-wave dispersion<sup>25</sup> in adult electrocardiography, and its importance and influence in NI-FECG interpretation has not been explored. Thus, in the current state of the art, we identify the limited P-wave resolution from the extracted NI-FECG to be the main limitation of this monitoring technique for ARR diagnosis.



**FIGURE 5** Atrial tachycardia with 2:1 AV conduction (ARR 11). Example observed on ARR 11. This is an important case where the perinatal cardiologists correctly identified that this fetus had an abnormal rhythm based on the noninvasive fetal electrocardiography (NI-FECG) but made an incorrect diagnosis due to the impossibility to appreciate the atrial activity (ie, P-wave) on the NI-FECG. A, An event detected on the NI-FECG strip. B, Fetal echocardiography (M-mode) showing the presence of an atrial tachycardia with 2:1 AV conduction [Colour figure can be viewed at [wileyonlinelibrary.com](http://wileyonlinelibrary.com)]



## 4.1 | Previous work

Few studies have focused on the clinical usability of NI-FECG: Graatsma et al<sup>26</sup> demonstrated the feasibility and accuracy of long-term transabdominal fetal electrocardiogram recordings throughout pregnancy using a portable NI-FECG monitor. However, the authors only included normal pregnancies in their study and thus did not prove that NI-FECG can actually identify fetal pathological events either in the context of a short term diagnosis examination or during a long-term monitoring. We recently presented<sup>27</sup> two fetal cases with atrioventricular block, which could be identified on the NI-FECG traces, highlighting the potential of NI-FECG for ARR diagnosis. However, our study was limited to only two cases, and the atrioventricular block events were searched for manually within the NI-FECG strip, ie, there was a prior on what rhythm abnormality to look for. Similarly, Yumoto et al<sup>28</sup> identified a single case of slow-rate ventricular tachycardia using the NI-FECG but with the prior knowledge on the diagnosis performed using echocardiography. Komaromy et al<sup>29</sup> demonstrated the feasibility of NI-FECG and/or scalp ECG to identify persistent fetal ARRs in 68 fetuses. Although this was a seminal work in using the NI-FECG for fetal ARR detection, the study had a number of limitations: (a) for the cases that were recorded using NI-FECG, the rhythm was assessed on the abdominal fetal-maternal ECG mixtures (as opposed to the extracted NI-FECG), which limits the reliability of the diagnosis because of the complexity in interpreting such a mixture of fetal-maternal signals. In particular, it does not provide any insights on the morphology of the FECG (eg, presence or absence of P-wave, shape of the QRS complex) and was therefore limited to presumptive diagnosis based on a visual inspection of the RR intervals variability. In addition, such an approach limits the analysis to cases where the FECG can be visually identified on the abdominal mixture, which is not systematically the case<sup>30</sup>; (b) such an analysis is time consuming for a perinatal cardiologist to review as no automated abnormal rhythm events detection algorithms were used to identify segments with rhythms of interest on the NI-FECG strips; (c) NI-FECG was only recorded or used for a subset of the patients, and it is unclear from the paper whether the NI-FECG-based diagnosis was compared with the reference scalp ECG diagnosis. We addressed these limitations in our study. Finally studies from Chia et al,<sup>24</sup> Clifford et al,<sup>12</sup> and Behar et al<sup>11</sup> looked into the extraction of clinical parameters from the NI-FECG morphology. Although these were original studies, all the fetuses included had no reported cardiac condition thus limiting the conclusions on whether the estimation of these physiological parameters is accurate enough and useful to provide actionable medical information.

## 4.2 | Limitations

The recordings were performed in the clinic and not within the patient home or during the mother's daily activity as would a standard Holter ECG. In order to be a viable option, fetal Holter must be evaluated on longer recordings and outside a clinical setting. Our rhythm detection algorithm is very sensitive to noise and thus will label any noisy NI-FECG segment as being an event. This can easily lead to an overload of the number of segments for the perinatal cardiologist to review. To

overcome this problem, signal quality indices<sup>31</sup> can be used to exclude NI-FECG segments of poor quality from the study and thus reduce the number of false positive detections. The ARR cases that were recorded had a high gestational age. Since most ARRs are usually detected in the mid to late second trimester (ie, GA of 20-27), it will be important to obtain more recordings of ARR with earlier gestational ages. Finally, the sample size used in this feasibility study ( $n = 26$ , with 12 arrhythmic fetuses) will need to be increased in order to capture a larger variety of fetal ARRs (types and manifestation) and to test our algorithms on wider range of heart rates. Elaborating such a database with enough arrhythmic cases involves the recording of a few thousands of fetuses.

## 4.3 | Perspectives

We have shown that the NI-FECG allows to identify subjects with fetal ARRs and that moreover in most cases it can provide additional information on the rhythm abnormalities than fetal echocardiography. NI-FECG presents some important advantages: the possibility for performing longer recording, which enables additional information, the ease of use and semiautomated analysis (no medical professional is required to constantly hold and place the monitoring device), and finally the access to additional conduction information (eg, detection of defects such as bundle branch block [BBB]). However, the low resolution of the extracted P-wave limits the identification of the mechanisms responsible for the ARRs and in one instance (Atrial tachycardia with 2:1 AV conduction) led to an inaccurate diagnosis. This motivates the development of improved algorithms aiming at better reconstructing the morphology of the NI-FECG on a beat-to-beat basis with a special emphasis on the P-wave. Another potential advantage of the NI-FECG is the measurement of clinically relevant conduction intervals such as the QT interval, which is not directly accessible from echocardiography. NI-FECG has shown to be able to provide an estimate of the QT interval length.<sup>11</sup> However, whether the precision of the estimated QT is sufficient for the detection of fetuses with long QT syndrome has yet to be demonstrated.

The NI-FECG could be used as a first intention diagnosis tool for identifying fetal ARRs when it is suspected. In particular, NI-FECG could be used in remote areas where the access to a perinatal cardiologist and echocardiography is challenging. Another opportunity is to use NI-FECG as a Holter remote monitor for fetuses that were diagnosed with an ARRs and need to be followed up. For example, in the case of diagnosed isolated extrasystoles (which represent ~85% of the case of fetal ARRs) the patient could be followed up with a Fetal Holter monitor to detect its potential evolution into sustained tachyARR.<sup>2</sup> A broader scope of usage for a fetal Holter is the continuous remote monitoring of patients with problematic pregnancies such as heart defect, autoimmune pregnancy with anti-SSA antibodies or for the monitoring of intrauterine growth restricted fetuses.

## 5 | CONCLUSION

This is the first study looking at the detection and diagnosis of a range of ARRs using the NI-FECG technique and comparing the diagnosis against the reference fetal echocardiography. There are two main



findings from this research: (a) it is possible to identify fetal ARRs using the NI-FECG technique; (b) improvement in algorithms for reconstructing the P-wave is critical to systematically resolve the mechanisms underlying the ARRs. This second findings offers a clear perspective for future research to the NI-FECG signal processing community.

This paper is a proof of concept and a first step toward the creation of a fetal Holter ECG device for diagnosing and monitoring fetal ARRs. Such a device will offer new opportunities for remote fetal monitoring because it is low cost, noninvasive, portable, and requires a minimal setup.

## FUNDING INFORMATION

The work was supported by the Center for Absorption in Science, Ministry of Aliyah and Immigrant Absorption, State of Israel (salary support for JB). The funding bodies had no role in the study design, data collection, and the decision to submit the article for publication.

## CONTRIBUTION TO AUTHORSHIP

J.B., L.B., I.L., and J.O. conceived and designed the research. Data were recorded by I.L. and O.O. Data were processed and prepared by J.B. and V.S. Diagnostic annotations were performed by O.O., L.B., and I.L. J.B. and L.B. drafted the manuscript. J.B., L.B., V.S., J.O., O.O., and I.L. critically revised the manuscript. All authors qualify for authorship on the paper are listed on the paper and approved the final version of the manuscript.

## ETHICS APPROVAL

Bioethics Committee of the Kharkiv Medical Academy of Postgraduate Education and registered under the ID 0105 U002865.

## ACKNOWLEDGEMENTS

None.

## CONFLICTS OF INTEREST

The authors report no conflicts of interest.

## ORCID

Joachim A. Behar  <https://orcid.org/0000-0001-5956-7034>

Vyacheslav Shulgin  <http://orcid.org/0000-0002-4128-8085>

Julien Oster  <http://orcid.org/0000-0001-6090-0834>

## REFERENCES

- Simpson JM. Fetal arrhythmias. *Ultrasound Obs Gyn*. John Wiley & Sons. Ltd. 2006;27(61):599-606.
- Parilla B, Strasburger J. Fetal arrhythmias. *Glob Libr Womens Med* [Internet]. 2009 [cited 2018 Apr 1]; Available from: <http://editorial.glowm.com/>
- Maeno Y, Hirose A, Kanbe T, Hori D. Fetal arrhythmia: prenatal diagnosis and perinatal management. *J Obs Gynaecol Blackwell Publishing Asia*. 2009;35(4):623-629.
- Vergani P, Mariani E, Ciriello E, et al. Fetal arrhythmias: natural history and management. *Ultrasound Med Biol*. 2005;31(1):1-6.
- Quiñones MA, Otto CM, Stoddard M, Waggoner A, Zoghbi WA. Doppler Quantification Task Force of the Nomenclature and Standards Committee of the American Society of Echocardiography. Recommendations for quantification of Doppler echocardiography: a report from the Doppler Quantification Task Force of the Nomenclature and Standards Committee of the American Society of Echocardiography. *J Am Soc Echocardiogr Elsevier*. 2002;15(2):167-184.
- Reinhard J, Hayes-Gill B, Yi Q. Comparison of non-invasive fetal electrocardiogram to Doppler cardiocogram during the 1st stage of labor. *J Perinat Med*. 2010;38(2):179-185.
- Farmakides G, Weiner Z. Computerized analysis of the fetal heart rate. *Clin Obstet Gynecol*. 1995;38(1):112-120.
- Cuneo B, Strasburger J, Yu S, Horigome H. In utero diagnosis of long QT syndrome by magnetocardiography. *Circulation*. 2013;128(20):2183-2191.
- Norén H, Blad S, Carlsson A, et al. STAN in clinical practice—the outcome of 2 years of regular use in the city of Gothenburg. *Am J Obs Gynecol Elsevier*. 2006;195(1):7-15.
- Biglari H, Sameni R. Fetal motion estimation from noninvasive cardiac signal recordings. *Physiol Meas*. 2016;37(11):2003-2023.
- Behar J, Zhu T, Oster J, et al. Evaluation of the fetal QT interval using non-invasive fetal ECG technology. *Physiol Meas*. 2016;37(9):1392-1403.
- Clifford GD, Sameni R, Ward J, Robinson J, Wolfberg AJ. Clinically accurate fetal ECG parameters acquired from maternal abdominal sensors. *Am J Obstet Gynecol*. 2011;205(1):47.e1-47.e5.
- Behar J, Andreotti F, Zaunseder S, Oster J, Clifford GD. A practical guide to non-invasive foetal electrocardiogram extraction and analysis. *Physiol Meas*. 2016;37(5):R1-R35.
- Behar J. Extraction of clinical information from the non-invasive fetal electrocardiogram. Doctoral dissertation. In: *University of Oxford*; 2014.
- Sameni R, Jutten C, Shamsollahi MB. A deflation procedure for subspace decomposition. *IEEE Trans Signal Process*. 2010;58(4):2363-2374.
- Sameni R, Jutten C, Shamsollahi MB, Clifford GD. Extraction of fetal cardiac signals. US Patent no 8,805,485; 2014.
- Fetal Echocardiography Task Force; American Institute of Ultrasound in Medicine Clinical Standards Committee; American College of Obstetricians and Gynecologists; Society for Maternal-Fetal Medicine. AIUM practice guideline for the performance of fetal echocardiography. *J Ultrasound Med*. 2013;32(6):1067-1082.
- Shulgin V, Shepel O. *Computer Diagnostic System for Fetal Monitoring During Pregnancy*. In: *Modern Problems of Radio Engineering, Telecommunications, and Computer Science*. Ukraine: Lviv-Slavske; 2014.
- Viunytyskiy O, Shulgin V. Signal processing techniques for fetal electrocardiogram extraction and analysis. In: *37th International Conference on Electronics and Nanotechnology (ELNANO)*. IEEE; 2017:325-328.
- Sameni R, Jutten C, Shamsollahi MB. Multichannel electrocardiogram decomposition using periodic component analysis. *IEEE Trans Biomed Eng*. 2008;55(8):1935-1940.
- Andreotti F, Behar J, Zaunseder S, Oster J, Clifford GD. An open-source framework for stress-testing non-invasive foetal ECG extraction algorithms. *Physiol Meas*. 2016;37(5):627-648.
- Fouron JC. Fetal arrhythmias: the Saint-Justine hospital experience. *Prenat Diagn*. 2004;24(13):1068-1080.
- Behar JA, Rosenberg AA, Weiser-Bitoun I, Shemla O, Alexandrovich A, Konyukhov E, Yaniv Y. PhysioZoo: a novel open access platform for heart rate variability analysis of mammalian electrocardiographic data. *Front Physiol*. 2018;9:1390.
- Chia EL, Ho TF, Rauff M, Yip WCL. Cardiac time intervals of normal fetuses using noninvasive fetal electrocardiography. *Prenat Diagn*. 2005;25(7):546-552.

25. Okutucu S, Aytemir K, Oto A. P-wave dispersion: what we know till now? *JRSM Cardiovasc Dis*. 2016;5. 204800401663944
26. Graatsma E, Jacod B, van Egmond L, Mulder E, Visser G. Fetal electrocardiography: feasibility of long-term fetal heart rate recordings. *BJOG-Int J Obs Gy*. 2009;116(2):334-338.
27. Lakhno I, Behar JA, Oster J, Shulgin V, Ostras O, Andreotti F. The use of non-invasive fetal electrocardiography in diagnosing second-degree fetal atrioventricular block. *Matern Heal Neonat Perinat BioMed Central*. 2017;3(1):14.
28. Yumoto Y, Satoh S, Koga T, Nagata H, Nagamatsu RNH. Prenatal diagnosis of slow-rate ventricular tachycardia using fetal electrocardiography. *Prenat Diagn*. 2004;24(6):463-467.
29. Komaromy B, Gaal J, Lampe L. Fetal arrhythmia during pregnancy and labour. *BJOG-Int J Obs Gy*. 1977;84(7):492-496.
30. Behar J, Oster J, Clifford GD. Combining and benchmarking methods of foetal ECG extraction without maternal or scalp electrode data. *Physiol Meas*. 2014;35(8):1569-1589.
31. Behar J, Oster J, Qiao Li, Clifford GD. ECG signal quality during arrhythmia and its application to false alarm reduction. *IEEE T Bio-Med Eng*. 2013;60(6):1660-1666.

#### SUPPORTING INFORMATION

Additional supporting information may be found online in the Supporting Information section at the end of the article.

**How to cite this article:** Behar JA, Bonnemains L, Shulgin V, Oster J, Ostras O, Lakhno I. Noninvasive fetal electrocardiography for the detection of fetal arrhythmias. *Prenatal Diagnosis*. 2019;1-10. <https://doi.org/10.1002/pd.5412>