

## Фотодинамічна терапія в лікуванні трофічних виразок у хворих з хронічною венною недостатністю

Ю. В. Іванова<sup>1,2</sup>, С. М. Граматюк<sup>2</sup>, І. А. Криворучко<sup>1</sup>, О. О. Зарудний<sup>3</sup>, К. В. Мясоедов<sup>1</sup>

<sup>1</sup>Харківський національний медичний університет,

<sup>2</sup>Інститут клітинної біореабілітації МОЗ України, м. Харків,

<sup>3</sup>Інститут загальної та невідкладної хірургії імені В. Т. Зайцева НАМН України, м. Харків

## Photodynamic therapy in treatment of trophic ulcers in patients, suffering chronic venous insufficiency

Yu. V. Ivanova<sup>1,2</sup>, S. M. Gramatyuk<sup>2</sup>, I. A. Kryvoruchko<sup>1</sup>, O. O. Zarudnyi<sup>3</sup>, K. V. Miasoiedov<sup>1</sup>

<sup>1</sup>Kharkiv National Medical University,

<sup>2</sup>Institute of Cellular Biorehabilitation, Kharkiv,

<sup>3</sup>Zaytsev Institute of General and Urgent Surgery, Kharkiv

### Реферат

**Мета.** Розробка комплексного підходу до лікування трофічних виразок венної етіології з використанням фотодинамічної, тканинної терапії та сучасних ранових покриттів.

**Матеріали і методи.** У дослідження було включено 24 пацієнти з венними виразками на фоні посттромбофлебійної хвороби віком від 31 до 79 років. Групу порівняння склали 14 пацієнтів, які отримували стандартне лікування (венотонічні препарати, еластична компресія, місцеве застосування багатокомпонентних мазей залежно від фази ранового процесу). В основну групу увійшли 10 пацієнтів, у яких застосовували розроблену методику фотодинамічної терапії. Для лікування пацієнтів використовували фотонні матриці Коробова «Барва Флекс» зі спектральним діапазоном 700–630 нм, що відповідало червоному світлу. Як фотосенсибілізатор використовували гель «Левудерм» (6% гель фосфату 5-амінолевулінової кислоти, яка є природним попередником ендogenous фотосенсибілізатора протопорфірину IX).

**Результати.** Перехід ранового процесу у другу фазу у групі порівняння був тривалим, у 50% пацієнтів епітелізація не завершилася до 45-ї доби лікування. В основній групі під впливом запропонованого методу лікування зменшився термін появи грануляцій і заповнення рани зрілою грануляційною тканиною, а також пришвидшилась епітелізація на 29,8% порівняно із стандартною терапією.

**Висновки.** Дане дослідження обмежене через невеликий розмір вибірки. Необхідні подальші контрольовані дослідження для з'ясування механізмів, що лежать в основі впливу 5-амінолевулінової кислоти – фотодинамічної терапії на рановий процес.

**Ключові слова:** хронічна венна недостатність; трофічна виразка; фотодинамічна терапія.

### Abstract

**Objective.** Elaboration of complex approach to treatment of trophic ulcers of venous etiology, using photodynamical tissue therapy and modern types of the wound coverage.

**Materials and methods.** Into the investigation 24 patients were included, suffering venous ulcers on background of postthrombophlebitic disease and ageing from 31 to 79 yrs old. Into the comparison group there were included 14 patients, in whom a standard treatment (venotonic preparations, elastic compression, local application of multicomponent ointments depending on the wound phase present) was used. Into the main group 10 patients were included, in whom the elaborated procedure of photodynamical therapy was applied. In treatment of the patients the Korobov's photonic matrix «Barva Flex», owing spectral diapason 700–630 nm, corresponding to red light, was applied. Gel «Levuderm» (6% gel 5-aminolevulinic acid phosphate, which constitutes a natural predecessor of endogenous photosensitizer protoporphyrin IX) was applied.

**Results.** Transition of the wound process to the second stage in the comparison group was durable, in 50% of patients epithelization did not complete up to 45th day of treatment. In the main group, under the impact of the treatment method proposed, the term of granulations appearance have had shortened as well as filling in of the wound by mature granulation tissue, and epithelization have accelerated by 29.8%, comparing with standard therapy.

**Conclusion.** This investigation owes a shortage because of insufficient volume of sampling. Thus, it is necessary to perform further controlled investigations to discover the mechanisms of basic impact of the 5-aminolevulinic acid photodynamical therapy on the wound healing process.

**Keywords:** chronic venous insufficiency; trophic ulcer; photodynamical therapy.

### Introduction

Chronic venous insufficiency (CVI) of the lower extremities is an extremely important medical, social and economic problem due to the high incidence of the disease. The problem of CVI has moved beyond the perception that it is a purely surgical problem. Socio-economic and psychological as-

pects have been added, which must be taken into consideration. The triad of clinical, socio-economic and psychological factors determine its significance [1,2].

According to independent experts of the WHO, this pathology occurs in 15.0–50% of the adult population in most countries of Europe and North America [3, 4]. In Ukraine, 15.0% of

15 million people suffering from CVI of the lower extremities have soft tissue trophic disorders. Recent world literature suggests that despite significant advances in the diagnosis and treatment of CVI, the disease does not tend to decline and there is no significant progress in improving treatment outcomes [5,6].

CVI is not just a nosological form but a pathological condition, which is caused by the two most common causes: varicose veins and post-thrombotic syndrome (PTS). There are two levels distinguished by modern researchers in the mechanism of formation and progression of CVI and subsequent trophic changes: macrohemodynamic and microcirculatory. Increasing venous hypertension as a result of outflow failure lies in the background of mentioned mechanisms [7,8].

The most severe manifestation of CVI is a trophic ulcer (TU). The pathophysiology of which can be represented as follows. A chronic increase in venous pressure, most pronounced in the distal parts of the tibia, leads to an increase in the volume of plasma permeating from the capillaries and leads to tissue oedema and hypoxia. Under conditions of chronic venous stasis leukocytes are fixed to endothelium of capillaries and then migrate into tissues. In this case toxic components are released from leukocytes: cytokines, leukotrienes, free oxygen radicals, proteolytic enzymes, etc., which cause inflammatory reaction and significant disturbances in microcirculation system. The final link in the above pathogenetic chain is the development of cellulitis, dermatitis and, consequently, TU [9,10]. In case of PTS the most patients have an unfavourable course of the disease, leading to performance impairment in 40.0–70.0% of observations [11–12].

Venous TU do not heal for a long time and recur repeatedly. Conservative treatment of venous TU involves systemic drugs, elastic compression, physiotherapy, and local treatment of venous TM as a preparation for surgery [13–15]. [13–15].

Traditional antibiotic prophylaxis and treatment of TU is known to be unsuccessful due to the rapid evolution of the wound microflora, a change in its biological characteristics, and the rapid development of resistance to antibacterial drugs [16]. The use of antibacterial agents directly in the focus of purulent infection, in conditions of acidosis and high concentration of low and medium molecular weight products of biodegradation, is ineffective. Even intravenous administration does not provide a sufficient concentration of antibiotics in the wound for a long time, due to haemodynamic and morphological changes in the pathological focus and surrounding tissues [17–20].

Thus, the problem of wound infection cannot be solved by new drugs, because the main importance in the fight against surgical infection belongs to the protective abilities of the organism itself, its reactivity and the creation of early optimal conditions for the vital activity of cells and tissues. Currently, a new medical technology – photodynamic therapy (PDT) – is being intensively developed all over the world. The essence of the method lies in the fact that many biological objects (tumour cells, microbes, blood cells) accumulate certain dyes – photosensitizers, which makes them sensitive to the effects

of light energy and low-intensity laser radiation of the appropriate wavelength. The sensitized tissues and cells undergo a photochemical reaction resulting in generation of singlet oxygen, free radicals and highly reactive biological agents, which are particularly detrimental to tumour cells, microorganisms, etc. In this regard, PDT has found wide application in the treatment of skin cancer and other neoplasms. In recent years, scientific publications have appeared dedicated to the application of PDT in the treatment of purulent wounds, in which the advantages of PDT over conventional therapy, in particular a evident antibacterial and anti-inflammatory effect, have been noted [21–23].

PDT is a method used in medicine for the treatment of some cancers and bacterial infections. The method is based on the combined effect of photosensitizer, light and singlet oxygen on tumour tissues or bacteria [21].

The damaging effects of PDT on microorganisms are caused by singlet oxygen and free radicals. This is why there is no resistance to the damaging effects of PDT on microorganisms. It is extremely important that the bactericidal property does not have a systemic, detrimental effect on the normal microflora of the body [2, 4]. In this case, photodynamic damage and the bactericidal effect are limited by the zone of laser irradiation of sensitized tissues, it allows to avoid the side effect observed when using systemic antibiotics and antiseptics to treat surgical infection. PDT of purulent wounds with hematoporphyrin derivatives usage has a positive effect on the course of the wound process, which is manifested by a antibacterial effect, accelerated wound clearance from purulent-necrotic detritus and shortened healing time of wound defects [23–25]. Despite the mentioned positive effects, the works on PDT of purulent wounds using first-generation photosensitizers are pretty rare, no chlorine-type photosensitizers were used, this direction is at the stage of clinical experience accumulation and currently has not found wide application in purulent surgery.

The aim of the study was to develop an integrated approach to the treatment of trophic ulcers of venous etiology using photodynamic therapy, tissue therapy and modern wound coverings.

## Materials and methods

The study enrolled 24 patients aged 31 to 79 years with venous TU against the background of DM treated in the clinic of the Zaycev Institute of General and Urgent Surgery. All patients had PTS in anamnesis. The time of shin (lower third and upper third) and foot TU formation before hospitalization ranged from 2 to 36 months.

The comparison group consisted of 14 patients treated traditionally (venotonic drugs, elastic compression, local application of multicomponent ointments depending on the phase of the wound process) and the main group (10 patients) in whom the elaborated treatment technique was applied. Two patients of the main group were diagnosed with a both venous and arterial pathology:– obliterating atherosclerosis of the arteries and PTS.

Chronic venous insufficiency was assessed according to the modified CEAP classification (1994) and its clinical section (C – clinical) was used.

Apart from general clinical, biochemical methods of investigation all the patients underwent vein Doppler ultrasound.

In all patients wound exudate was subjected to microbiological examination, quantitative and qualitative composition of microflora as well as sensitivity of microflora to antibiotics were determined. Identification of the isolated strains was performed using common bacteriological methods (morphological, tinctural, cultural, biochemical properties, and pathogenicity), following the Bergi classification (2011).

Planimetric study was performed according to the method of L. N. Popova (1941). Wound characteristics were evaluated during the course of treatment: dynamics of granulation growth and wound epithelization.

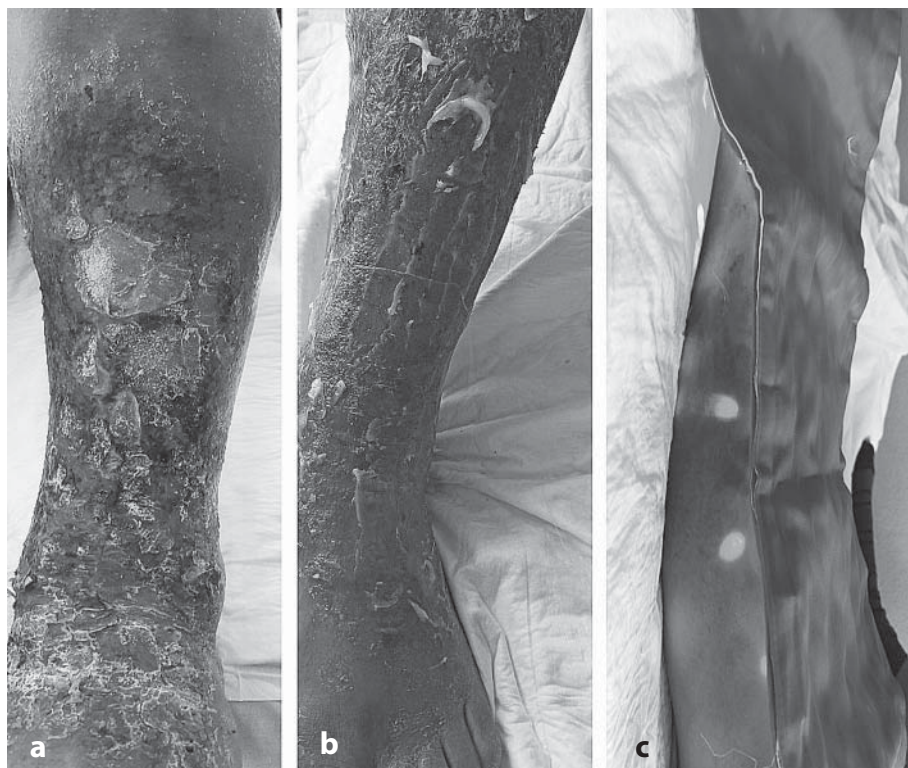
Devices for PDT. For the treatment of patients we used photonic matrices "Barva Flex" Korobov with a spectral range: 700–630 nm, which corresponded to red light.

We used Levuderm gel (6% 5-aminolevulinic acid phosphate gel) as an FS preparation. 5-aminolevulinic acid (5-ALA) is known to be a natural precursor of the endogenous photosensitizer protoporphyrin IX (PP-IX). 5-ALA itself is not a photosensitizer and does not accumulate in cells, but when administered exogenously, it temporarily "overloads" the normal heme biosynthesis pathway. Due to reduced activity of ferrochelatase, an enzyme limiting the rate of this process, as well as iron deficiency, an intermediate product of biosynthesis, PP-IX, accumulates in tumour tissue, unlike in normal tissue. PP-IX is a rather active PS due to the presence of an intense absorption band with a maximum at 630 nm and the ability to efficiently generate singlet oxygen. In addition, due

to selective accumulation of PP-IX specifically in malignant cells, ALK is an effective fluorescent tumour marker.

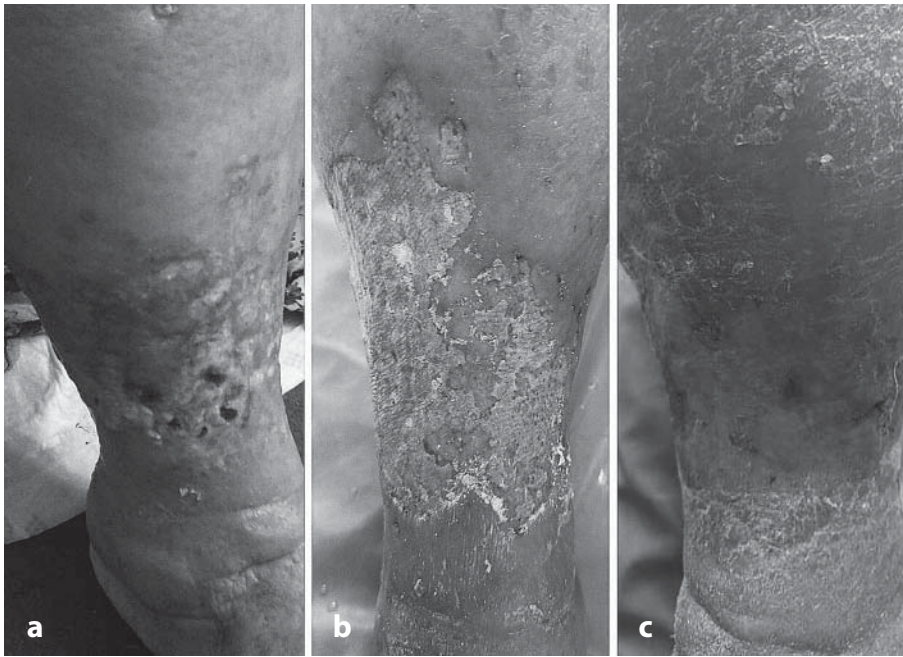
In patients with venous TU in the main group treatment was carried out according to the developed technology: in the first stage 1–2 sessions of PDT were held: after cleansing the wound surface with physiological NaCl solution, Levuderm gel (6% gel phosphate of 5-aminolaevulinic acid) was applied and covered with a bandage for 2 hours, after which the gel residue was removed and irradiation with Korobov photonic matrices "Barva Flex" with a wavelength of 660 nm was performed. Energy applied to the wound averaged 30–40 J/cm<sup>2</sup>. The power density of the light was in the range 0.1–1.0 W/cm<sup>2</sup>, and the exposure time to the wound varied depending on the wound area (*Fig. 1*). Starting from the first day of the postoperative period, along with the standard prescribed therapy, the complex of local treatment included phototherapy with red light (wavelength 660–630 nm, the duration of the session – 10–15 min, the number of sessions – 7–14). The duration of the first phase of treatment did not exceed 7 days.

At the second stage of treatment, the wound defect was closed using different variants of wound coverings (as an alternative to autodermoplasty) – lyophilised xenografts, synthetic Polycaprolacton (PCL) and Polilactide (PLA) wound coverings and human amniotic membrane. Then, during the next dressing, sclerobliteration of the incompetent perforations was performed under ultrasound guidance. Ethoxysclerol 1–3% was used as a phleboscclerosing agent. Foam was obtained according to the Tessari method (air-to-preparation ratio 4:1). Due to dispersibility, static charge and surface tension forces, the microfoam takes up the entire venous capacity in the area of trophic disorders and blocks the incompetent perforator veins.



*Fig. 1.*  
*Patient A, 56 years old. PTS,*  
*microbial eczema of the right shin:*  
*a) before treatment;*  
*b) photosensitizer applied;*  
*c) irradiation with A. M. Korobov's*  
*photon matrix.*





*Fig. 2.*  
*Patient S., 71 years old. PTUB, trophic ulcers*  
*of the right lower leg:*  
*a) before treatment;*  
*b) 5 days of treatment;*  
*c) 27 days of treatment.*

In the subsequent stages of treatment, wounds were irradiated with red light (wavelength 660–630 nm), with the duration of the sessions being 10–25 minutes, number of sessions being 3–6. Wearing compression stockings was recommended for the period of treatment in case of ankle–brachial index was higher than 0,6.

The efficacy of treatment was assessed basing on the patient's subjective feelings, objective studies of the nature and dynamics of wound healing (presence of discharge, degree of granulation and epithelization, wound healing rate), the number of postoperative complications and treatment time of the patients were also evaluated. The rate of marginal epithelialization was determined by the formula of A.N. Povova (1945).

In addition, we evaluated the severity of lipodermatosclerosis (basing on ultrasound examination (ultrasound)) in the long-term follow-up.

A study participation agreement was signed by all patients. The entire list of investigations and the treatments used was approved by the Ethical Committee of the Zaitsev Institute of General and Urgent Surgery.

Statistical analysis was performed using Statistica 10.0, values were presented as absolute values, arithmetic mean with standard deviation of arithmetic mean. Differences were considered statistically significant with a significance level of  $p < 0.05$ .

## Results

According to the microbiological study, a polyresistant and pan-resistant Gr.+ (in most patients) and Gr.– microflora, as well as microbial associations were detected in both groups of patients.

*S. aureus* (60% of the main group and 57.1% of the control group) with an average wound colonization of  $6,14 \pm 0,33 \times 10^9$  CFU, *St. epidermicus* (20% of the main group and 21.4% of the control group) with an average colonization of  $5,51 \pm 0,52 \times 10^9$  CFU, Gram–negative flora in monoculture was identified in

10% of main group patients, *Ps. Aeruginosa* and in 7.1% of the comparison group – (*E. coli*) with an average colonization of  $1,15 \pm 0,25 \times 10^9$  CFU), in 10% and 14.3% (respectively, by groups) of patients there were identified microbial associations. Systemic antibacterial therapy was not administered to the patients of the main group.

On the background of the first phase of treatment, positive changes in the microbial flora of the wounds were observed in the patients of the main group: decontamination of the wounds was observed on the 2–3rd day in 4 cases, while the level of microbial wounds was lower than the critical level ( $< 10^5$ ) in the remaining patients, with isolated staphylococci and streptococci which required a second session of PDT.

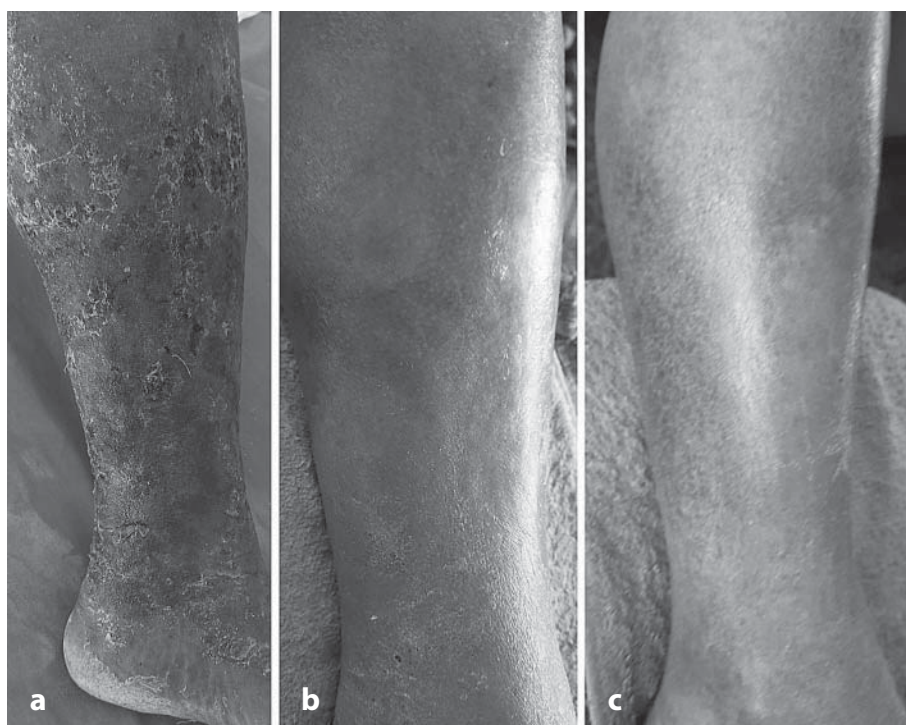
On 2–3 days after the first PDT session, the perifocaloedema decreased, and by the 7th–10th day, the granulation condition and the degree of wound epithelization improved significantly which allowed to perform closure of the wound surface within these terms by one of the described methods, after that sclerosation of incompetent perforator veins was performed.

In comparison group time to preparation to the vein intervention averaged  $46,3 \pm 2,8$  days.

In patients of the main group in which the closure of wound defects was performed using xenogeneleucophilized skin the dynamics of regression of the wound area on the 4th–5th day was  $39,24 \pm 2,42\%$  comparing to the initial area, on the 15th–17th day the wounds healed. In patients with PCL and human amniotic membrane wound closure after perforating foam sclerosation therapy the wound area decreased by  $50,63 \pm 2,1\%$  on the 4th–5th day. The ulcers healed on day 10–14 (Fig. 2).

The average period of stay in the hospital of the main group patients was  $22,6 \pm 2,4$  days. Spontaneous epithelialisation was achieved in all of these patients.

In the follow-up period (30 days after the treatment) 4 patients from the main group were examined. The regression of lipodermatosclerosis was noteworthy, both clinically



*Fig. 3.*  
*Patient A, 56 years old. PTFB:*  
*a) 14th day of treatment;*  
*b) 21st day of treatment;*  
*c) 35th day of treatment.*

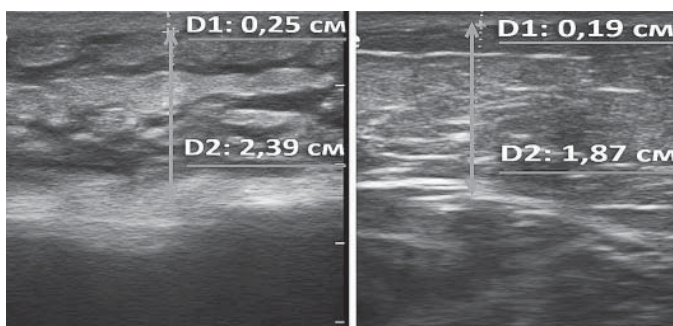
and according to ultrasound examination of the subcutaneous tissue (Fig. 3, 4).

The results of the treatment show that the transition of the wound process into the second phase was long in the comparison group, while in 7 (50%) patients epithelialization was not completed by the 45th day.

### Discussion

One of the most severe complications of PTS is the formation of TU, which is an enormous medical and socio-economic problem. Their healing, according to some authors' data, occurs in only 50% of patients by 4 months of treatment, and relapse occurs within the first year in 30% of cases. For patients with poor tolerance to compression therapy, this figure rises to 78.0% after 2 years. In 0.3% of cases the ulcers do not heal for a long time and recur repeatedly despite advanced compression treatment [26].

Venous ulcers of the lower extremities pose a real threat in many aspects: physical, functional, psychological and finan-



*Fig. 4.*  
*Patient A, 56 years old. Skin and subcutaneous tissue ultrasound*  
*(D1 – skin thickness, D2 – subcutaneous tissue thickness;*  
*a) before treatment; b) 35 days after treatment.*

cial. One of the main reasons for these facts is late detection and initiation of treatment of the disease. It is not possible to completely eliminate the risk of developing this pathology, although there are hygienic measures that, when followed in high-risk groups, can reduce it.

Surgical intervention has been and remains the main method of treatment of decompensated chronic venous insufficiency. Traditional techniques of treatment of patients with trophic disturbances of the lower limbs in 30,0–45,0% do not provide stable clinical improvement due to high frequency of postoperative complications: from 31,3% to 75,0% in general surgery hospitals and from 4,3% to 9,6% – in specialized hospitals [3, 14].

The works of domestic and foreign authors have proved the important role of valve insufficiency of the lower leg perforating veins in the development of trophic disorders in chronic venous insufficiency. The modern conditions determine: 1) the priority of minimally invasive technologies providing a radical cure with a high aesthetic result; 2) an equally important requirement for surgical techniques is the possibility of their outpatient use. The use of ultrasound-guided interventions in many areas of medicine has led to the introduction of echosclerotherapy, puncture electrodestruction and laser coagulation of incompetent perforators into phlebology practice [7].

At the same time, wound infection control is a key part of the treatment of these patients. Traditionally prescribed topical treatment regimens for TM are long-lasting and ineffective [18], therefore, PDT, which was originally used to treat skin cancer and some other types of cancer, seems promising. However, it has been shown to be effective in the treatment of benign inflammatory skin diseases [26].

PDT has a bactericidal effect and has undeniable advantages over traditional antibiotic therapy; its effectiveness does not



depend on the spectrum of sensitivity of pathogens to antibiotics and does not contribute to the development of microflora resistance [26]. The efficacy of PDT has been found to vary depending on the nature of the bacterial flora isolated from the wound contents. The mechanism of PDT is based on the basic principles of photobiology. Bunsen–Roscoe law: the photochemical effect is determined by the dose of the initiating radiation and is calculated as the product of the light flux power by the exposure time. Stark–Einstein law: one molecule of a substance participating in a photochemical reaction absorbs one quantum of light. Grotthus–Drawper law: the radiation used to initiate a photochemical reaction must have a wave of the appropriate length, since only absorbed light can initiate the reaction [27].

In addition, in some treated patients, we observed a regression of lipodermosclerosis in the long term. Studies show that when normal cells or fibroblast cells from sclerotically altered skin were treated with ALK–FDT, the levels of matrix metalloproteinases (MMP–1 and MMP–3) increased, which has been interpreted as an anti–sclerotic effect of ALA–FDT [29], while data from other authors show a decrease in MMP levels, which enhances the UV–induced MMP secretion by various cells, including infiltrated inflammatory cells [28, 29].

Thus, the authors' proposed method of treating TU in patients with PTS can optimise the wound process, reduce the time of granulation development and wound filling with mature granulation tissue, and increase epithelialisation rate by 29.8% compared to conventional therapy.

Our study is limited by the small sample size. Further controlled studies are needed to clarify the mechanisms underlying the effects of ALA–FDT on the wound process.

**Funding.** There were no external sources of funding and support. No fees or other compensation were paid.

**Authors' contribution.** All authors made the same contribution to this article.

**Competing interests.** The authors have no conflict of interest.

**Consent for publication.** All authors approved the paper to be published.

## References

1. Kudykin MN, Izmailov SG, Beschastnov VV, Kletsin AE, Vasyain AN. Analysis of the reasons for the return of trophic ulcers of venous etiology. Q: How to improve outcomes in patients with vascular disease. XXIII international conference Krasnodar, June 16–18, 2008 Krasnodar; 2008.185 – 7. Russian.
2. Hoods IM. Current issues in the treatment of venous ulcers. *Clinical phlebology*. 2015; 8(1): 15–6. Ukrainian.
3. Wittens C, Davies AH, Bækgaard N, Broholm R, Cavezzi A, Chastanet S, et al. Editor's Choice – Management of Chronic Venous Disease: Clinical Practice Guidelines of the European Society for Vascular Surgery (ESVS). *Eur J Vasc Endovasc Surg*. 2015 Jun;49(6):678–737. doi: 10.1016/j.ejvs.2015.02.007. Epub 2015 Apr 25. Erratum in: *Eur J Vasc Endovasc Surg*. 2020 Mar;59(3):495. PMID: 25920631.
4. Rabe E, Pannier F. Epidemiology of chronic venous disease. In: 16 World congress of the Union Internationale de Phlebology. e–abstract book. Monaco; 2009:72.
5. Chernukha LM. Vein disease is a problem that needs to be addressed. *Health of Ukraine*. 2011;(6):2–3. Russian.
6. Chernukha LM. Modern approaches to the treatment of chronic venous diseases: news from the European Venous Forum. *Health of Ukraine*. 2012;(4):10–3. Russian.
7. Chernukha LM, Gooch AA, Vlaikov GG. Pathogenetic substantiation of active surgical tactics and the main concept of conservative rehabilitation treatment in patients with severe forms of chronic venous insufficiency of the lower extremities. *Clinical phlebology*. 2009;(1). C. 105–9. Russian.
8. Scotton MF, Miot HA, Abbade LP. Factors that influence healing of chronic venous leg ulcers: a retrospective cohort. *An Bras Dermatol*. 2014 May–Jun;89(3):414–22. doi: 10.1590/abd1806–4841.20142687. PMID: 24937814; PMCID: PMC4056698.
9. Bilyaeva OO, Rogovsky VM, Yatsun VV. Autodermoplasty in the complex treatment of chronic venous insufficiency of the lower extremities in the stage of trophic disorders. *Tauride Medical and Biological Bulletin*. 2011;14(4):20–3. Ukrainian.
10. Wenger IC, Bedenyuk AD, Romanyuk TV. Trophic ulcers of venous origin – tactics of surgical treatment. *Hospital Surgery*. 2011;(10):57–60. Ukrainian.
11. Tolstykh PI, Tamrazova OB, Pavlenko VV, Kuleshov IYu, Tolstykh MP. Long–term non–healing wounds and ulcers (pathogenesis, clinic, treatment). Moscow: Deepak; 2009. 168 p. Russian. ISBN: 978–5–98580–046–3.
12. Leaper DJ, Schultz G, Carville K, Fletcher J, Swanson T, Drake R. Extending the TIME concept: what have we learned in the past 10 years?. *Int Wound J*. 2012 Dec;9 Suppl 2(Suppl 2):1–19. doi: 10.1111/j.1742–481X.2012.01097.x. PMID: 23145905; PMCID: PMC7950760.
13. Huch AA, Chernukha LM, Smorzhevsky VI. Trophic disorders of lower extremity tissues in patients with morbid obesity. *Clinical phlebology*. 2013;6(1):144–5. Russian.
14. Rusyn VI, Korsak VV, Mitrovka BA. Complex treatment of patients with trophic ulcers of venous origin. *Clinical phlebology*. 2013;6(1):170. Ukrainian.
15. Villavicencio JL. Leg ulcers of venous origin: From ancient to modern times. *J Vasc Surg Venous Lymphat Disord*. 2013 Jan;1(1):96–9. doi: 10.1016/j.jvsv.2012.08.003. Epub 2012 Dec 8. PMID: 26993903.
16. Frykberg RG, Banks J. Challenges in the Treatment of Chronic Wounds. *Adv Wound Care (New Rochelle)*. 2015 Sep 1;4(9):560–82. doi: 10.1089/wound.2015.0635. PMID: 26339534; PMCID: PMC4528992.
17. Gethin G, Cowman S, Kolbach DN. Debridement for venous leg ulcers. *Cochrane Database Syst Rev*. 2015 Sep 14;2015(9):CD008599. doi: 10.1002/14651858.CD008599.pub2. PMID: 26368002; PMCID: PMC6486053.
18. Brothers KM, Stella NA, Hunt KM, Romanowski EG, Liu X, Klarlund JK, Shanks RM. Putting on the brakes: Bacterial impediment of wound healing. *Sci Rep*. 2015 Sep 14;5:14003. doi: 10.1038/srep14003. PMID: 26365869; PMCID: PMC4650533.
19. Swanson T, Grothier L, Schultz G. Wound Infection Made Easy. *Wounds International* 2014. Available from: www.woundsinternational.com.
20. Snyder RJ, Bohn G, Hanft J, Harkless L, Kim P, Lavery L, et al. Wound Biofilm: Current Perspectives and Strategies on Biofilm Disruption and Treatments. *Wounds*. 2017 Jun;29(6):S1–S17. PMID: 28682297.
21. Gilchrist BA. Biochemical and molecular changes in photodamaged skin. In: Gilchrist BA, editor. *Photodamage*. Cambridge: Blackwell Science Ltd; 1995. 168–84.
22. Karrer S, Bosserhoff AK, Weiderer P, Landthaler M, Szeimies RM. Influence of 5–aminolevulinic acid and red light on collagen metabolism of human dermal fibroblasts. *J Invest Dermatol*. 2003 Feb;120(2):325–31. doi: 10.1046/j.1523–1747.2003.12037.x. PMID: 12542540.
23. Szeimies RM, Landthaler M, Karrer S. Non–oncologic indications for ALA–PDT. *J Dermatolog Treat*. 2002;13 Suppl 1:S13–8. doi: 10.1080/095466302317414654. PMID: 12060512.
24. Orringer JS, Hammerberg C, Hamilton T, Johnson TM, Kang S, Sachs DL, et al. Molecular effects of photodynamic therapy for photoa-

- ging. Arch Dermatol. 2008 Oct;144(10):1296–302. doi: 10.1001/archderm.144.10.1296. PMID: 18936392.
25. Chu ES, Wong TK, Yow CM. Photodynamic effect in medulloblastoma: downregulation of matrix metalloproteinases and human telomerase reverse transcriptase expressions. Photochem Photobiol Sci. 2008 Jan;7(1):76–83. doi: 10.1039/b703417b. Epub 2007 Nov 2. PMID: 18167600.
26. Boyko VV, Ivanova YuV, Mushenko EV, Korobov AM. Combined therapy of complicated surgical infections caused by multi-drug resistant microflora in patients with diabetic foot. Photobiology and Photomedicine. 2016;(1–2):51–9. Russian.
27. Massagué J. The transforming growth factor-beta family. Annu Rev Cell Biol. 1990;6:597–641. doi: 10.1146/annurev.cb.06.110190.003121. PMID: 2177343.
28. Hase T, Shinta K, Murase T, Tokimitsu I, Hattori M, Takimoto R, et al. Histological increase in inflammatory infiltrate in sun-exposed skin of female subjects: the possible involvement of matrix metalloproteinase-1 produced by inflammatory infiltrate on collagen degradation. Br J Dermatol. 2000 Feb;142(2):267–73. doi: 10.1046/j.1365-2133.2000.03296.x. Erratum in: Br J Dermatol 2000 Aug;143(2):470. PMID: 10730759.
29. Sternlicht MD, Werb Z. How matrix metalloproteinases regulate cell behavior. Annu Rev Cell Dev Biol. 2001;17:463–516. doi: 10.1146/annurev.cellbio.17.1.463. PMID: 11687497; PMCID: PMC2792593.

Надійшла 02.06.2021