

GENERAL CHARACTERISTICS OF DERMATOGLYPHIC FEATURES OF HUMAN HANDS AND FEET IN TERMS OF IDENTIFICATION

Dunaev O.V.¹, Kozlov S.V.², Popadynets O.G.³

¹Kharkiv National Medical University, Kharkiv, Ukraine

²Dnipro State Medical University of the Ministry of Health of Ukraine, Dnipro, Ukraine

³Ivano-Frankivsk National Medical University, Ivano-Frankivsk, Ukraine

Summary. The article presents generalized data on the possibility of using dermatoglyphic characteristics of a person in terms of the latest approaches to the identification of an unknown person. Morphological characteristics of papillary patterns of hands and feet, their topography and types are given. Quantitative and qualitative features of dermatoglyphs are presented, which may be useful in terms of factor features for the identification of an unknown person. Data on the possibility of using artificial neural networks in forensic identification examinations using dermatoglyphs are given.

Keywords: dermatoglyphics, identification of the person.

Introduction. Human dermatoglyphic patterns are one of the main identifying features that remain unchanged throughout life. However, there is scientific evidence that with age the comb pattern loses clarity, the comb count decreases, the pattern deforms (changes in height, the appearance of minutes, etc.), ie there is a problem of determining signs of aging dermatoglyphic parameters, as evidenced by some theoretical findings on this problem. [1,3,7]

The unique morphological structure of the papillary pattern, which is essentially a genetically determined manifestation of the phenotype, as well as the fact that dermatoglyphic parameters consist of structural elements easily accessible to quantitative and qualitative study, determine a wide range of dermatoglyphics in practical medicine. [4,6,8]

On the distal phalanges of the fingers, the palmar surface of the hands and the plantar surface of the foot are the papillae of the dermis, which form a dermatoglyphic pattern. The study of the above papillary, as well as flexor patterns, is a dermatoglyph. The study of patterns on the distal phalanges of the fingers is called fingerprinting.

There are three main types of simple patterns on the distal phalanges of the fingers and toes, as well as on the toe pads of the hands and feet: arc (A), ulnar loop (fibular) (Lu, Lf) or radial (tibial) (Lb, Lt) and curl (W) (fig. 1).

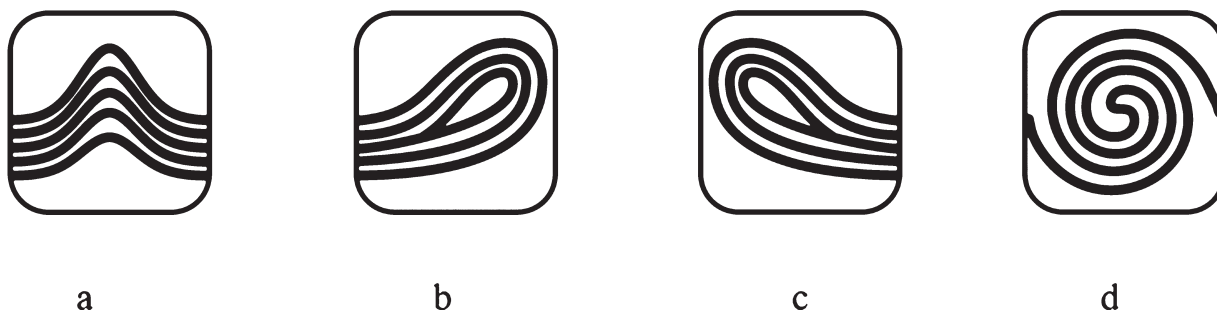


Fig. 1. Types of skin patterns: a – arc, b – radial loop (tibial), c – ulnar loop (fibular), d – curl.

Arcs can vary in width (wide, medium, narrow) and height (high, medium, low). Determination of the width and height of the arc is based on the calculation of the ratio of its largest dimensions in the vertical and horizontal planes.

Loops can be high, medium and low, as well as wide, medium and narrow, which is determined by the ratio of the width of the base of the loop and the vertical lowered through its top to the horizontal line of its base.

Curls can be simple or complex (to simplify calculations, we've combined them), high, medium, and low, as well as wide, medium, and narrow, determined by the ratio of their largest vertical and horizontal sizes through the center of the pattern.

All these figures form a central pattern, which is bordered by papillary lines that go in different directions from it. At the meeting points of line flows, deltas or triradii are formed, the number of which is always greater than one (fig. 2).



Fig. 2. Triradius (delta).

The human palm in the dermatoglyphic aspect contains the palm fields, under the finger triradii and the main palm lines.

To simplify the method of studying the dermatoglyphic parameters of the palm, we determined the palm angles atb, atc, atd, btc, btd, ctd on both hands using a graphic editor KOMPAS – 5, and also calculated delta and comb accounts of the palm, types of patterns on the toes (fig. 3, 4).

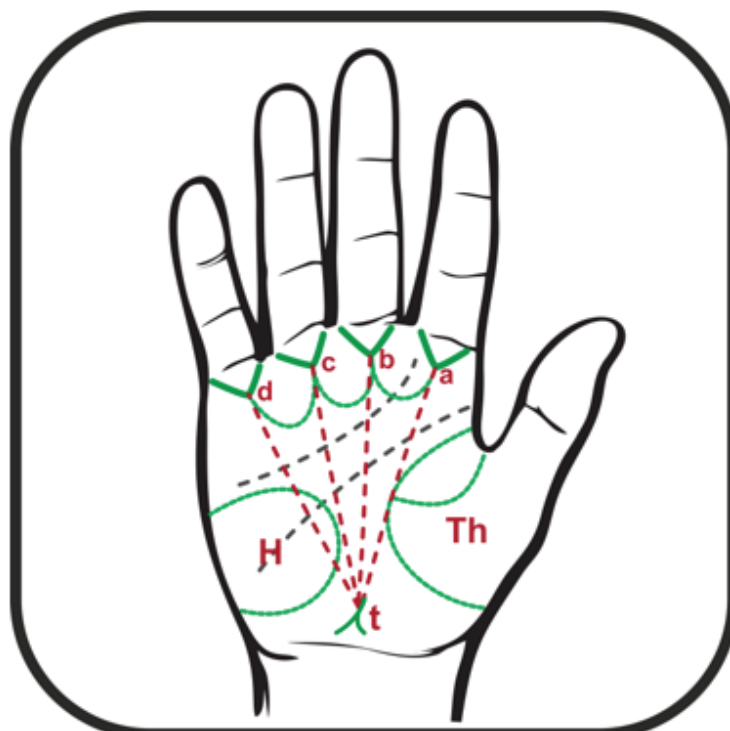


Fig. 3. Scheme of measuring palm angles.

In the study of dermatoglyphs of the feet, the type of pattern on the toe pads, delta and comb counts, the direction of papillary lines in the calcaneus (heel) area were determined (fig. 4).

Thus, in addition to the type of pattern, its height, width, type of flow of lines, you can also determine the relative indicators that indicate the density, frequency, ratio and prevalence of patterns:

- delta account and comb account (number of skin combs between the center of the edge of the pattern);
- furugati index (number of curls/number of loops \times 100);

- denmeyer index (number of arcs/number of curls×100);
- field index (number of arcs/number of loops×100) d;
- gapel index (number of curls on I-III fingers/0,5 number of curls on IV-V fingers).

Dermatoglyphic study of the hand and foot was performed according to the method proposed by I. V. Paliychuk and L. E. Kovalchuk [2] in the modification proposed by N. M. Kozan, V. D. Mishalov, Yu. Z. Kotsyubynska (2017).

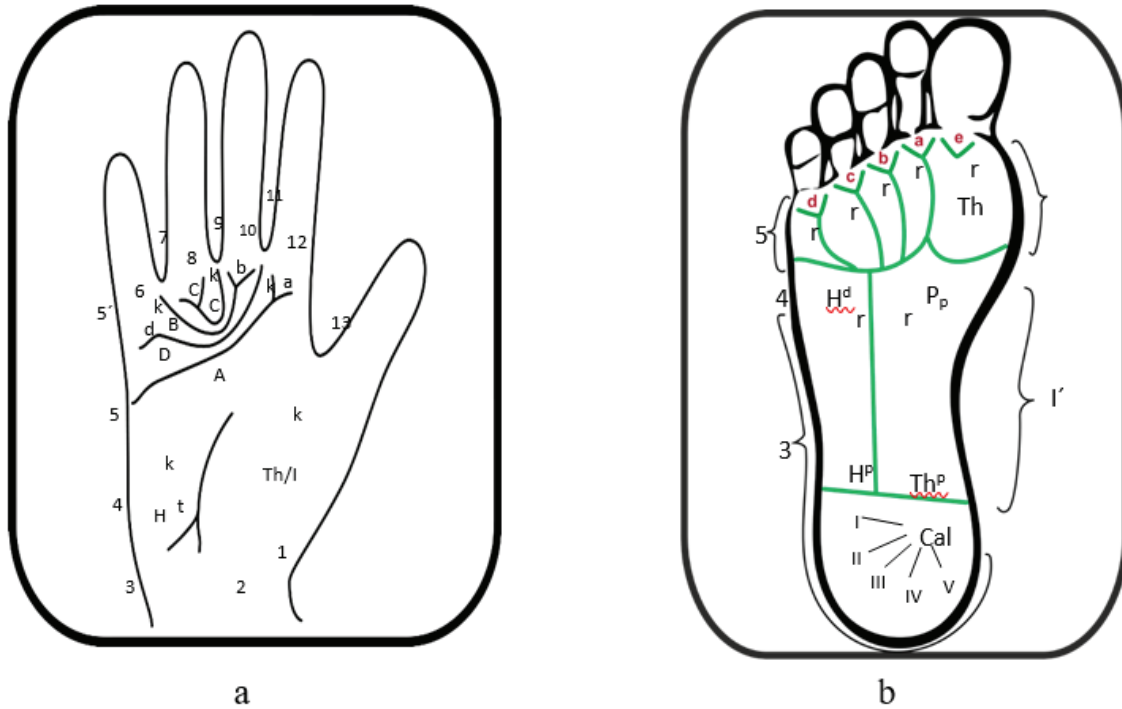


Fig. 4. Scheme of palm (a) and sole patterns (b): a: 1-13 – palm fields; a, b, c, d – finger triradii, starting from them the main palmar lines A, B, C, D; t – the main (axial) triradius of the palm; k – zones of palm patterns; b: 1-14 – sole fields; a, b, c, d, e – finger, Pr – lower additional triradii; I-V is the direction of the papillary lines in the calcaneus (heel) area.

For dermatoglyphic examination of the palms and soles, we used macrophotographs of the entire palm and the upper third of the plantar surface of the foot. The obtained data were transferred to a personal computer, where with the help of graphic programs (drawing and design editor KOMPAS-GRAFIK 5) they were processed, studying the qualitative and quantitative indicators of dermatoglyphs of hands and feet (fig. 5).

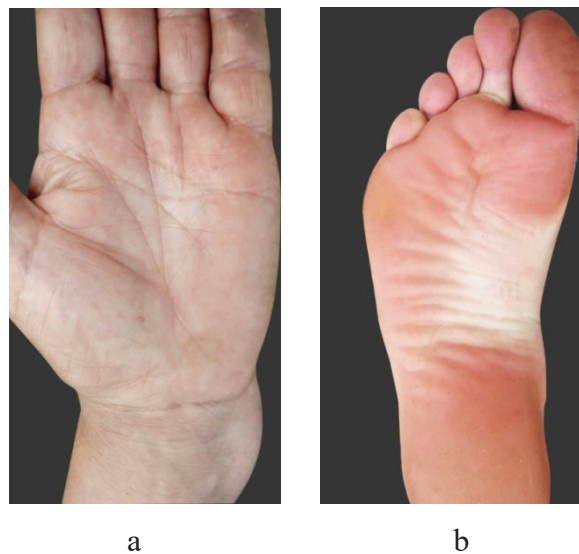


Fig. 5. Digital photographs of dermatoglyphs of hands (a) and feet (b).

Digital images allow you to get a clear image of the comb pattern of the distal phalanges of the fingers, because when obtaining fingerprints in the traditional way possible pattern defects (fuzzy, blurred, missing fragment), and when counting the number of combs and deltas, you can increase the image folds of the palms, etc.

Currently, there is a wide range of different software that can improve image quality. The most common and powerful tool in digital image processing is the Adobe product package – Adobe Creative Cloud. In our work we used Photoshop SS and Illustrator CC. These programs have a large number of tools that can improve the image quality in a particular case, but usually for a satisfactory result it is necessary to use several of them – increase (decrease) contrast, lighting, focusing, etc. These actions usually have built-in functions in photo editors (fig. 6).

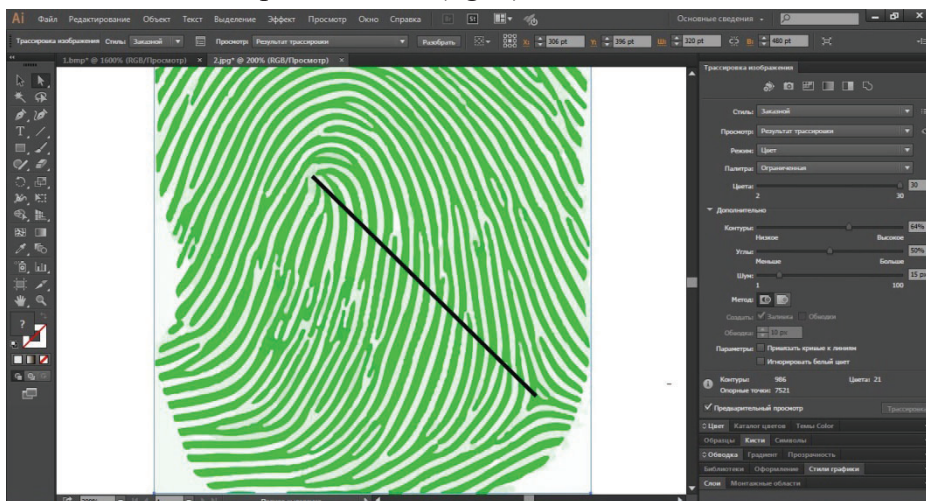


Fig. 6. Material processing in Adobe Illustrator CC.

The purpose of improving image quality is to obtain reliable data for further statistical processing. Researchers solve data processing problems in different ways, but in most cases, this stage is reduced to filling the database (array) of data, its structuring and formalization with further processing in programs for statistical analysis.

The dermatoglyphic method, as a source of initial identification features, is a budget option for rapid identification of an unknown person. The proposed method can greatly facilitate and systematize the work of a forensic expert in the identification of an unknown person.

Dermatoglyphic examination of the skin relief is possible using many methods. For a long period in Ukraine, the most common method was the use of printing ink. It is characterized by simplicity in practice, low cost of consumables and cost-effective. However, in addition to the advantages, this method has a number of disadvantages: the inconvenience associated with contamination of the extremities with printing ink, the quality of the prints is not always satisfactory, which requires a repeat procedure and entails additional time. There are also inconveniences associated with processing the data obtained and creating electronic archives. To improve this method, the researchers proposed to digitize the obtained fingerprints on paper using scanning.

Dermatoglyphics For Prediction (DFP) computer identification program based on artificial neural networks. It does not require significant budgetary costs of data acquisition, training of specialists in its maintenance, and the construction of the neural network, its training and examination are short in time. In the study, the reliability of the results ranged from 73 to 90 % (automatically calculated by the software Dermatoglyphics For Prediction (DFP)), which is significantly higher than previously obtained results. [9]

Prospects for further research are beyond doubt, as the integrated use of all available identification methods accelerates, reduces the cost and improves the quality of identification forensic examinations.

Література

1. Войченко ВВ, Мішалов ВД, Мамедов ШМо, В'юн ВВ, Івашина ОХ. Комплексний підхід при проведенні судово-медичної ідентифікації загиблих під час збройних конфліктів та катастроф. Судово-медична експертиза. 2017;1:20-5.
2. Ковальчук ЛЄ, винахідник; Івано-Франківський національний медичний університет, патентовласник. Спосіб отримання дерматогліфіки долонь правої та лівої рук. Патент України № 40653. 2009 Кві 27.
3. Козань НМ. Діагностика загальних фенотипових ознак людини шляхом комплексного дослідження дерматогліфічних особливостей кисти та стопи [дисертація]. Київ; 2018. 418 с.
4. Gunas VI. Modeling using discrimination analysis, priority of practically healthy men to northern or other administrative-territorial regions of Ukraine on the basis of dermatoglyphic indicators features. Світ медицини та біології. 2018;1(63):9-14. doi: 10.26724/2079-8334-2018-1-63-9-14
5. Mishalov VD, Gunas VI. Discriminating models of dermatoglyphic priority of practically healthy men to southern or other administrative-territorial regions of Ukraine. Судово-медична експертиза. 2018;1:17-21.
6. Mishalov VD, Gunas IV, Kryvda GF, Bachinsky VT, Voichenko VV. Actually questions of forensic medical dermatoglyphics. Судово-медична експертиза. 2018;1:15-7.
7. Mishalov VD, Kryvda GF, Bachinskiy VT, Voichenko VV. History of development and up-to-date tendency. Судово-медична експертиза. 2017;1:86-8.
8. Mishalov VD, Serebrennikova OA, Klimas LA, Gunas VI. Regional trends indicators finger dermatoglyphics among modern Ukrainians. Biomedical and Biosocial Anthropology. 2018;30:5-12. doi: 10.31393/bba30-2018-01
9. Kotsyubynska Yu, Kozan N, Chadyuk V. «Classification tree» for prediction ethnoterritorial affiliation unknown person. In: The III-rd congress of legal medicine service from the Republic of Moldova dedicated to the 70-th anniversary of the centre of legal medicine; 2021 Sep 30-Oct 2; Chisinau. Chisinau; 2021. p. 110-4.

References

1. Voichenko VV, Mishalov VD, Mamedov ShMo, V'iun VV, Ivashyna OKh. Kompleksnyi pidkhid pry provedenni sudovo-medychnoi identyfikatsii zahyblykh pid chas zbroinykh konfliktiv ta katastrof [A comprehensive approach for the forensic identification of victims during armed conflicts and disasters]. Sudovo-medychna ekspertyza. 2017;1:20-5. (in Ukrainian)
2. Koval'chuk LIe, vynakhidnyk; Ivano-Frankivs'kyi natsional'nyi medychnyi universytet, patentovlasnyk. Sposib otrymannia dermatohlifyky dolon' pravoї ta livoї ruk [The method of obtaining dermatoglyphics of the palms of the right and left hands]. Patent Ukrainy № 40653. 2009 Kvi 27. (in Ukrainian)
3. Kozan' NM. Diahnostyka zahal'nykh fenotypovykh oznak liudyny shliakhom kompleksnoho doslidzhennia dermatohlifychnykh osoblyvostei kysti ta stopy [Diagnosis of general human phenotypic traits by a comprehensive study of dermatoglyphic features of the hand and foot] [dysertatsiia]. Kyiv; 2018. 418 s. (in Ukrainian)
4. Gunas VI. Modeling using discrimination analysis, priority of practically healthy men to northern or other administrative-territorial regions of Ukraine on the basis of dermatoglyphic indicators features. Svit medytsyny ta biolohii. 2018;1(63):9-14. doi: 10.26724/2079-8334-2018-1-63-9-14
5. Mishalov VD, Gunas VI. Discriminating models of dermatoglyphic priority of practically healthy men to southern or other administrative-territorial regions of Ukraine. Sudovo-medychna ekspertyza. 2018;1:17-21.
6. Mishalov VD, Gunas IV, Kryvda GF, Bachinsky VT, Voichenko VV. Actually questions of forensic medical dermatoglyphics. Sudovo-medychna ekspertyza. 2018;1:15-7.

7. Mishalov VD, Kryvda GF, Bachinskiy VT, Voichenko VV. History of development and up-to-date tendency. *Sudovo-medychna ekspertyza*. 2017;1:86-8.
8. Mishalov VD, Serebrennikova OA, Klimas LA, Gunas VI. Regional trends indicators finger dermatoglyphics among modern Ukrainians. *Biomedical and Biosocial Anthropology*. 2018;30:5-12. doi: 10.31393/bba30-2018-01
9. Kotsyubynska Yu, Kozan N, Chadyuk V. «Classification tree» for prediction ethnoheritrial affiliation unknown person. In: *The III-rd congress of legal medicine service from the Republic of Moldova dedicated to the 70-th anniversary of the centre of legal medicine; 2021 Sep 30-Oct 2; Chisinau. Chisinau; 2021. p. 110-4.*

ЗАГАЛЬНА ХАРАКТЕРИСТИКА ДЕРМАТОГЛІФІЧНИХ ОЗНАК РУК І НІГ ЛЮДИНИ В АСПЕКТІ ПИТАННЯ ІДЕНТИФІКАЦІЇ ОСОБИ

Дунаєв О.В.¹, Козлов С.В.², Попадинець О.Г.³

¹ Харківський національний медичний університет, м. Харків, Україна

² Дніпровський державний медичний університет МОЗ України, м. Дніпро, Україна

³ Івано-Франківський національний медичний університет, м. Івано-Франківськ, Україна

Резюме. У статті представлені узагальнені дані стосовно можливості використання дерматогліфічних характеристик людини в плані новітніх підходів до ідентифікації невідомої особи. Подані морфологічні характеристики папілярних візерунків рук і ніг, їхні топографія та види. Представлені кількісні й якісні ознаки дерматогліфів, що можуть бути корисними в плані факторних ознак для ідентифікації невідомої особи. Надані дані щодо можливості застосування штучних нейронних мереж при проведенні судово-медичних ідентифікаційних експертиз з використанням дерматогліфів.

Ключові слова: дерматогліфіка, ідентифікація особи.

Відомості про авторів:

Дунаєв О.В. – доктор медичних наук, професор кафедри судової медицини, медичного правознавства ім. засл. проф. М.С. Бокаріуса Харківського національного медичного університету, м. Харків, Україна, e-mail: dunaev1969@ukr.net ORCID ID: 0000-0003-0459-9041

Козлов С.В. – доктор медичних наук, професор кафедри патологічної анатомії і судової медицини Дніпровського державного медичного університету МОЗ України, м. Дніпро, Україна, e-mail: tanatholog@i.ua, ORCID ID: 0000-0002-7619-4302

Попадинець О.Г. – доктор медичних наук, професор, завідувач кафедри анатомії людини Івано-Франківського національного медичного університету, м. Івано-Франківськ, Україна, e-mail: anatomy@ifnmu.edu.ua, ORCID ID: 0000-0002-2093-5984

Information about authors:

Dunaev O. V. – Doctor of Medical Sciences, Professor of the Department of Forensic Medicine, Medical Law named after prof. M. S. Bokarius, Kharkiv National Medical University, Kharkiv, Ukraine, e-mail: dunaev1969@ukr.net ORCID ID: 0000-0003-0459-9041

Kozlov S. V. – Doctor of Medical Sciences, Professor of the Department of Pathological Anatomy and Forensic Medicine of the Dnipro State Medical University of the Ministry of Health of Ukraine, Dnipro, Ukraine, e-mail: tanatholog@i.ua, ORCID ID: 0000-0002-7619-4302

Popadynets O. G. – Doctor of Medical Sciences, Professor, Head of the Department of Human Anatomy, Ivano-Frankivsk National Medical University, Ivano-Frankivsk, Ukraine, e-mail: anatomy@ifnmu.edu.ua, ORCID ID: 0000-0002-2093-5984