

НАЦІОНАЛЬНА АКАДЕМІЯ МЕДИЧНИХ НАУК УКРАЇНИ
ДУ «ІНСТИТУТ ПРОБЛЕМ ЕНДОКРИННОЇ ПАТОЛОГІЇ
і.м. В. Я. ДАНИЛЕВСЬКОГО НАМН УКРАЇНИ»

NATIONAL ACADEMY OF MEDICAL SCIENCES OF UKRAINE
SI «V. DANILEVSKY INSTITUTE FOR ENDOCRINE PATHOLOGY PROBLEMS
OF THE NAMS OF UKRAINE»

ПРОБЛЕМИ ЕНДОКРИННОЇ ПАТОЛОГІЇ

Щоквартальний науково-практичний журнал

PROBLEMS
OF ENDOCRINE PATHOLOGY

Every quarter

№ 1 (79) '2022

Scopus®

INDEX COPERNICUS
INTERNATIONAL

ULRICHSWEB™
GLOBAL SERIALS DIRECTORY

Google
scholar

Vernadsky
National Library
of Ukraine

Crossref

Український
Ветеринарний
Журнал
Львів

Харків
Ukraine, Kharkiv

РЕДАКЦІЙНА КОЛЕГІЯ

Ю. І. Караченцев (головний редактор),
М. Р. Микитюк (заступник головного редактора),
В. В. Полторак (заступник головного редактора з наукових питань), **О. В. Козаков** (заступник головного редактора з організаційних питань),
Н. С. Красова (відповідальний секретар),
Р. С. Ніколаєв (редактор матеріалів з клінічної ендокринології), **Ж. А. Лешенко** (редактор матеріалів з експериментальної ендокринології).

Т. Л. Архипкіна, Л. О. Атраментова, А. І. Божков, В. О. Бондаренко, Н. М. Бречка, О. А. Гончарова, Н. І. Горбенко, М. Ю. Горшунська, О. В. Грищенко, Л. В. Журавльова, А. Є. Коваленко, С. М. Коваль, О. І. Ковзун, Н. О. Кравчун, П. Г. Кравчун, В. В. Ліпсон, Н. Г. Малова, К. В. Місюра, О. Г. Резніков, Н. Ю. Селюкова, В. О. Сергієнко, Л. Ю. Сергієнко, Т. М. Тихонова, М. Д. Тронько, А. М. Урбанович, В. В. Хазієв, О. О. Хижняк.

РЕДАКЦІЙНА РАДА

В. Мирзазаде (Азербайджан), Р. Б. Базарбекова (Казахстан), О. Р. Гіоргадзе (Грузія), І. І. Дедов (Росія), Р. А. ДеФронзо (США), Є. Йенсен (Нідерланди), В. М. Лісовий, Є. В. Лучицький, А. Люгер (Австрія), Б. М. Маньковський, М. Мінков (Австрія), Т. В. Мохорт (Білорусь), В. І. Паньків, Н. О. Перцева, О. О. Сергієнко, В. Спалоне (Італія), С. Д. Тржецинський, О. М. Хвисьюк, Цинь Чуан (Китай), А. Штірбан (Німеччина).

EDITORIAL BOARD

Yu. I. Karachentsev (Editor in Chief),
M. R. Mykytyuk (Deputy Editor-in-Chief),
V. V. Poltorak (Deputy Editor-in-Chief for scientific questions), **A. V. Kozakov** (Deputy Editor-in-Chief for Organizational Affairs), **N. S. Krasova** (Executive Secretary), **R. S. Nikolaiev** (Material Editor of Clinical Endocrinology), **Zh. A. Leshchenko** (Material Editor of Experimental Endocrinology).

T. L. Arkhyapkina, L. O. Atramentova, A. I. Bozhkov, V. O. Bondarenko, N. M. Brechka, O. A. Goncharova, N. I. Gorbenko, M. Yu. Gorshunska, O. V. Gryshchenko, L. V. Zhuravlyova, A. Ye. Kovalenko, S. M. Koval, O. I. Kovzun, N. A. Kravchun, P. G. Kravchun, V. V. Lipson, N. G. Malova, K. V. Misiura, O. G. Reznikov, N. Yu. Seliukova, V. A. Serhiyenko, L. Yu. Sergiyenko, T. M. Tykhonova, M. D. Tronko, A. M. Urbanovych, V. V. Khaziyev, O. O. Khyzhnyak.

EDITORIAL COUNCIL

V. Mirzazade (Azerbaijan), R. B. Bazarbekova (Kazakhstan), O. R. Giorgadze (Georgia), I. I. Dedov (Russia), R. A. DeFronzo (USA), E. Jansen (Netherlands), I. Luchytskyi, V. M. Lisovyy, A. Luger (Austria), B. M. Mankovsky, M. Minkov (Austria), T. V. Mokhort (Belarus), V. I. Pankiv, N. O. Pertseva, V. A. Serhiyenko, O. O. Sergiyenko, V. Spallone (Italy), S. D. Trzhetsinskiy, O. M. Khvysyuk, Qin Chuan (China), A. Shtirban (Germany).

Матеріали номера затверджено вченою радою ДУ «ІПЕП» від 01.02.22, протокол № 1.
Підписано до друку 02.02.22 р.

Розмноження в будь-який спосіб матеріалів, опублікованих у журналі, допускається лише з дозволу редакції. Відповідальність за зміст рекламних матеріалів несе рекламодавець.

ПРОБЛЕМИ ЕНДОКРИННОЇ ПАТОЛОГІЇ Щоквартальний науково-практичний журнал Заснований у 2002 р.

Адреса редакції:

вул. Алчевських, 10, м. Харків, 61002
ДУ «Інститут проблем ендокринної патології
ім. В. Я. Данилевського НАМН України»
Тел.: (057) 700-45-39. Факс: (057) 700-45-38.
E-mail: journal@ipep.com.ua
<http://www.jpep.endocrinology.org.ua>

Свідоцтво про державну реєстрацію
КВ № 5851 від 11.02.02.

ISSN 2227-4782 (Print)
ISSN 2518-1432 (Online)

Передплатний індекс 06725.

Журнал включено до переліку наукових фахових видань України (категорія «А»).
Наказ МОН України від 18.12.2018 № 1412 (в галузі медицини, 222).
Наказ МОН України від 28.12.2019 № 1643 (в галузі біології, 091).

Журнал індексується в міжнародних наукометричних базах **Scopus**, **Index Copernicus**, **Google Scholar**, **Crossref**, внесено до міжнародних баз даних **Ulrich's Periodicals Directory**, реферується у видавництвах «Джерело» (Україна).

PROBLEMS OF ENDOCRINE PATHOLOGY Quarterly Scientific and practical journal Founded in 2002

Editorial address:

Alchevskikh str., 10, Kharkiv, Ukraine 61002
SI «V. Danilevsky Institute for Endocrine Pathology
Problems of the NAMS of Ukraine», Kharkiv
Tel.: +38 (057) 7004539. Fax: +38 (057) 7004538
E-mail: journal@ipep.com.ua
<http://www.jpep.endocrinology.org.ua>

Certificate of registration
KB № 5851 from 11.02.02.

ISSN 2227-4782 (Print)
ISSN 2518-1432 (Online)

Subscription index 06725.

The journal included in the list of scientific professional editions of Ukraine (category «A»).
Order MES of Ukraine № 1412 from 18.12.2018 (medicine, 222).
Order MES of Ukraine № 1643 from 28.12.2019 (biology, 091).

The journal is indexed in international scientometric databases **Scopus**, **Index Copernicus**, **Google Scholar**, **Crossref**, included in the international database **Ulrich's Periodicals Directory**, reviewed by the publishing house «Dzherelo» (Ukraine).

Формат 60x84/8. Папір офсетний. Друк офсетний. Ум. друк. арк. 15,58.
Наклад 800 прим. Зам. № .

ТОВ «Імпрес Принт», вул. Пушкінська, 56, Харків, 61002.
Тел.: (057) 714-42-11, 752-08-38.

EXPERIMENTAL STUDIES

<i>N. M. Brechka, V. V. Kozar, Ye. M. Korenieva, V. A. Bondarenko, O. V. Dolzhykova, N. O. Tkachenko, V. V. Borozhenets, O. S. Protsenko, E. I. Zalubovskaya.</i> Correlation of inflammation with structural and functional changes in the rats' prostate gland with chronic prostatitis under the exposure of chondroitin sulphate	65
<i>A. R. Gevorkyan, D. O. Ippolitov, T. V. Bocharova.</i> Circadian disruption as a factor of impaired adaptive T-cell immunity response	72
<i>N. I. Gorbenko, O. Yu. Borikov, O. V. Ivanova, T. V. Kiprych, K. V. Taran.</i> The impact of succinate derivative phensuccinal on mitochondrial function and redox status in the heart of rats with type 2 diabetes.....	78
<i>O. M. Demchenko, O. G. Rodinsky, Yu. V. Kozlova, S. V. Kozlov, G. O. Rodinska, G. I. Titov.</i> Formation of protective behavior of young rats in conditions of thyroid dysfunction	85
<i>D. S. Nosivets, V. I. Opryshko, T. M. Shevchenko.</i> Effect of non-steroidal anti-inflammatory drugs and paracetamol on the functional state of the thyroid gland in experimental osteoarthritis with hypothyroidism	93

REVIEW

<i>A. Yusra, A. Waluyo.</i> Family support toward adherence and glycemic control of type 2 diabetes patient: a systematic review	100
--	-----

TO PRACTICING ENDOCRINOLOGIST

<i>N. M. Zherdova, O. A. Stepura, E. A. Iskanderova, S. I. Mazii, Y. V. Strighak, K. M. Khorievina.</i> Possibilities of correction of hyperammonia in the treatment of type 2 diabetes mellitus.....	112
<i>M. M. Popov, T. I. Liadova, V. B. Olenych, O. V. Ohnivenko, O. M. Savvo, O. Yu. Sukhonosova.</i> Chemical characteristics of peripheral blood granulocyte biomembranes in frequently ill children with autonomic dysfunction syndrome and overweight	118

CHRONICLE OF EVENTS

REPORT on the scientific-practical conference with online broadcast for endocrinologists, therapists, pediatricians, cardiologists, neurologists, general practitioners — family medicine and other specialists «Endocrine pathology in the age aspect», November 18–19, 2021	125
Publishing report	130
Information for authors.....	132

ЕКСПЕРИМЕНТАЛЬНІ ДОСЛІДЖЕННЯ**CORRELATION OF INFLAMMATION
WITH STRUCTURAL AND FUNCTIONAL CHANGES
IN THE RATS' PROSTATE GLAND
WITH CHRONIC PROSTATITIS
UNDER THE EXPOSURE OF CHONDROITIN SULPHATE***

N. M. Brechka ^{1,2}, V. V. Kozar ², Ye. M. Korenieva ¹, V. A. Bondarenko ¹,
O. V. Dolzhykova ², N. O. Tkachenko ³, V. V. Borozenets ³, O. S. Protsenko ³, E. I. Zalubovskaya ⁴

¹ *SI «V. Danilevsky Institute for Endocrine Pathology Problems
of the NAMS of Ukraine», Kharkiv, Ukraine*

² *National University of Pharmacy, Kharkiv, Ukraine*

³ *V. N. Karazin Kharkiv National University, Kharkiv, Ukraine*

⁴ *Kharkiv National Medical University, Kharkiv, Ukraine
natalia01073@gmail.com*

Chronic prostatitis is a common urological condition among men in the world. It has been shown that only 5 to 10% of patients with prostatitis have acute or chronic bacterial infection, while the majority of men with prostatitis (about 90-95 %) have chronic pelvic disease without facts of infection (category III). For example, it has been found that in the United States, the prevalence of chronic prostatitis (CP)/chronic pelvic pain syndrome (CPPS) or nonbacterial chronic prostatitis ranges from 1.8% to 6.3%. With a prevalence of 1.8 % equivalent to approximately 2 million cases, the total annual cost of treatment per patient

is \$ 4,397. In addition, young and middle-aged men first of all suffer from chronic prostatitis [1]. According to statistics, about 10% of urological patients in Ukraine are diagnosed with CP/CPPS [2].

The etiology and pathogenesis of CP/CPPS remain substantially uncertain. To date, the triggers of chronic prostatitis CP/CPPS are considered chronic inflammation and/or hypothermia, the mutual influence of autoimmune, neuroendocrine and psychological factors.

In patients with CP/CPPS in urine and prostate secretions, but not in sperm have been observed an increase in the number of leuko-

* The work was performed in the SI «V. Danilevsky Institute for endocrine pathology problems of National Academy of Medical sciences of Ukraine» within the framework of the topic «Determining the role of vitamin D deficiency and insufficiency in the development of gonadal dysfunction, justification of approaches to their therapy» (state registration number 0119U102387).

The institution that finances the study is the National Academy of Medical Sciences of Ukraine.

The authors assume responsibility for the published work.

The authors guarantee absence of competing interests and their own financial interest when carrying out the research and writing the article.

The manuscript was received by the editorial staff 24.11.2021.

cytes compared with the control group of men without prostate disease. At the same time, the bacterial spectrum haven't had difference from the IC group. These studies confirm that the etiology and pathogenesis of CP/CPPS don't depend on the microbial factor, but there is an inflammatory process [3]. Inflammation is associated with an increase in the concentration of pro-inflammatory cytokines (interleukin-1, tumor necrosis factor- α , interferon- γ) and the activity of autoimmunity (the reaction of T-cell proliferation to prostate antigens), intraprostatic urinary reflux, increased intraprostatic stress, etc. [4]. A large number of studies concerning the treatment of CP with the use of pharmacological drugs, physiotherapeutic, surgical and other procedures and the ambiguity of their results indicate that, unfortunately, there is still no consensus regarding the standards of treatment of the disease [5].

As far as inflammation is an important component of CP, in researches much attention is paid to inflammation, the effect of drugs on

the molecular pathways of inflammation activation, on the regulation of the synthesis of pro- and anti-inflammatory cytokines, etc. [1].

At the same time, in our opinion, the role of another significant participant in inflammation, namely, connective tissue, is underestimated, since it is known that severe, permanent or prolonged trauma leads to dysregulation of connective tissue, because it is the environment where all stages of damage (inflammation, fibrosis, etc.) pass off. These processes, in turn, lead to dysfunction/loss of the functional state of the organ, and therefore the therapeutic reconstruction of the structure and function of the connective tissue of the prostatic gland can be another important strategy for the pharmacotherapy of CP/CPPS.

The aim of the work was to evaluate and compare changes of inflammation markers and histological structure of prostate tissue in rats with experimental chronic prostatitis under conditions of Chondroitin sulfate use.

MATERIALS AND METHODS

These experimental studies were carried out in compliance with the main rules of the European Convention on the Protection of Vertebrate Animals Used for Experimental and Scientific Purposes (Strasbourg, 1986) and the provisions of the General Ethical Principles for Animal Experiments (Kyiv, 2001) [6].

The experimental studies were carried on white mature male Wistar rats with weight of 270–370 g. Non-bacterial prostatitis was caused by local irrigation of the previously exposed surgical access to isthmus and ventral parts of the prostate for 5 seconds by an applicator for the wart removal Wartner®, the wounded surface was sewed in afterwards. All manipulations with animals were performed under ether anesthesia [7]. This model is characterized by necrotic-fibrotic changes as a result of direct cryo-traumatic damage to the prostate, hemodynamic disorders and inflammation [7].

To assess the anti-inflammatory and prostatoprotective properties, we used the introduction of the substance Chondroitin sulfate (manufactured by Sigma, USA) and the reference drug Prostapant forte (manufactured by

Schwabe, Germany). The drugs were administered three days before the simulation of cryotraumatic prostatitis and within 11 days after cryotrauma. On the 12th day, animals were taken out of the experiment by rapid decapitation under light ether anesthesia. Animals were divided into the 5 groups (8 animals in each group): group 1 — intact control (IC); group 2 (control) — falsely operated rats (C FO) — small incision in the abdominal cavity in the area of the ventral part of the prostate; group 3 — control pathology (CP) (local irrigation of the anterior surface of the central part of the prostate (isthmus and ventral parts) within 5 seconds with an applicator for wart removal Wartner®; group 4 — control pathology + administration of Prostapant forte (CP+PF) at a dose of 35 mg/kg; group 5 — control pathology + administration of Chondroitin sulfate substance (CP + CS) at a dose of 60 mg/kg.

The state of inflammation was assessed by the level of C-reactive protein (CRP), the number of leukocytes, the erythrocyte sedimentation rate in the blood, and during pharmacological correction. CRP was determined by the semiquantitative method of latex agglutina-

tion according to [8]. The sensitivity of the diagnosticum was 0.5 mg/l CRP. The number of leukocytes, ESR was determined by standard methods [7].

The state of the connective tissue was assessed according to the results of histological examination of the prostate, for this it was fixed in a 10% formalin solution, carried out using alcohols of increasing strength, and fill with celoidin-paraffin.

Histological preparations of the prostate after stained with hematoxylin and eosin was studied by microscopy (size, shape of acini, stroma and the integrity of the epithelial lining, etc.) [9]

RESULTS AND THEIR DISCUSSIONS

It is known trauma cause inflammation. In our research, there was an increase in the number of leukocytes, ESR, the concentration of CRP appropriate to 1,8; 1,5 and 2 times compared with group of IC ($p \leq 0.05$) (Table 1) in the group of C FO animals. The combination of trauma and a cold agent (cryotrauma), as expected, was accompanied by a more expressed inflammatory process, which was characterized by an increase in the number of leukocytes and ESR compared to the group of falsely operated rats (1.5, 1.2 and 2 times, respectively, $p \leq 0, 05$).

In the group of animals receiving the studied drugs, a decrease in the manifestations of

Statistical processing of the obtained results was performed using parametric and non-parametric methods. As a result of the normal distribution, the arithmetic mean and its statistical error were calculated ($\bar{X} \pm S_{\bar{X}}$); if the data were not consistent with the normal distribution, the median (Me), minimum and maximum data (min÷max) were calculated. Newman-Keuls method, nonparametric Wilcoxon–Mann–Whitney U-test and Kruskal–Wallis H-test were used to analyze differences. Critical level of significance was assumed to be equal to or less than 0.05 ($p \leq 0.05$).

inflammation was observed not only in comparison with the group CP, but also in the group C FO, as evidenced by a decrease in leukocytosis, ESR and CRP ($p \leq 0,05$).

As mentioned earlier, the connective tissue is exactly the field of the pathological process development in the tissue, particularly inflammation. And the use of CS, which today is not classified as a drug for the treatment of prostatitis, turned out to be effective in reducing the manifestations of inflammation. The effect of CS on leukocytes, ESR, CRP haven't had difference from the reference drug, and also slightly exceeded the average values in the CP + PF group.

Table 1

Peripheral blood indicators under the impact of drugs on model of the prostate cryotrauma and subject to pharmacological correction, (n = 8), ($\bar{X} \pm S_{\bar{X}}$)

Animal group	Indicators				
	Leukocytes, $10^9 / l$	ESR, mm / hr	Me	min ÷ max	$\bar{X} \pm S_{\bar{X}}$
IC	9,88 ± 1,06	9,00 ± 0,95	2	2÷2	2,00 ± 0,00
C FO	18,00 ± 2,26 ¹⁾	13,50 ± 1,20 ¹⁾	4 ¹⁾	2÷4	3,80 ± 0,70
CP	27,00 ± 1,86 ^{1) 2)}	16,25 ± 0,93 ^{1) 2)}	8 ^{1) 2)}	8÷8	8,00 ± 0,00
CP + PF	15,00 ± 1,32 ^{2) 3)}	11,50 ± 1,46 ^{2) 3)}	4 ³⁾	2÷4	3,30 ± 0,67
CP + CS	14,00 ± 1,46 ^{2) 3)}	10,25 ± 1,07 ^{2) 3)}	2 ^{2) 3) #}	2÷4	2,70 ± 0,67

Note:

¹⁾ Statistically significant differences compared to IC group data, $p \leq 0,05$,

²⁾ Statistically significant differences compared to C FO group data, $p \leq 0,05$,

³⁾ Statistically significant differences compared to CP group data, $p \leq 0,05$,

Statistical differences with tendency to CP+PF group data, $p \leq 0,05$.

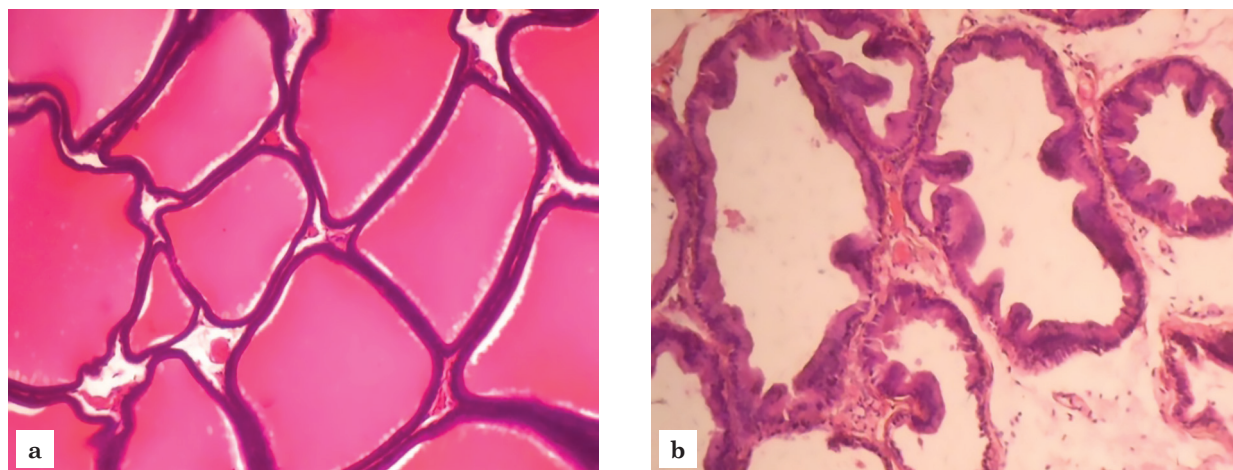


Fig. 1. The prostate gland of IC group: the normal state of the acini of the prostatic glands in the ventral lobule (a) and in the isthmus between the ventral lobules (b). Hematoxylin-eosin. $\times 200$.

Therefore, inflammation, as one of the important pathogenetic factors of prostatitis, is positively influenced by both chondroprotective and prostateprotective drugs.

The results of histological examination of preparations of prostate showed that in the IC and C FO groups in the ventral lobule and in the area of the isthmus between the ventral lobules of the prostate, the acini of the prostate glands were predominantly rounded or partly oval in shape, their contours were well-defined, and the wall tension was good. The wall is lined with a single-layer cuboidal or simple columnar epithelium, which is in the part of the glands assembled in small folds. The nuclei of epithelial cells are basally located; at the lumen of the acini, eosinophilic secretions of different density are often visible. Paraprostatic tissues are not changed (Fig. 1).

12 days after cryotrauma in rats of the CP group in the prostate tissue, a specific productive inflammation have observed in the glandular tissue and in the surrounding paraprostatic tissue, collapse of the walls, their thickening in most acini, destruction of a part of the acini and thinning of their walls, distinct sinuosity, stretching of the lumen acini, death and necrosis of a part of acini, desquamation of degenerated cells, lime deposition, as well as edema of a loose fibrous stroma with hemorrhagic effusion.

The interacinar tissue is infiltrated with lymphocytes, histiocytes, plasma cells, hemorrhages, edema and protein effusion have seen in places (Fig. 2).

As seen in Fig. 3, the comparison drug Prostaplant Forte in the same mode of administration promoted a completely preservation

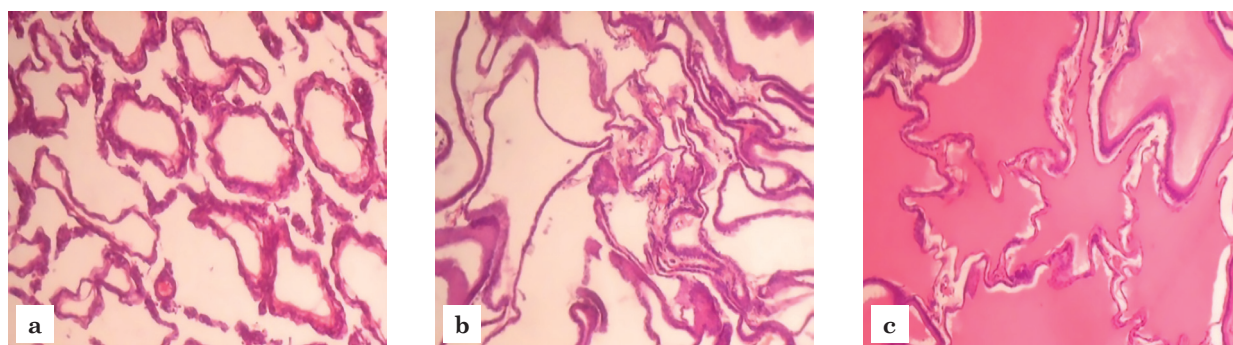


Fig. 2. Rat prostate gland after cryotrauma:
a — collapse of the walls, their thickening in most acini;
b — destruction of part of the acini, thinning of the walls;
c — expressive tortuosity of the contours, stretching of the lumen of the acini.
Hematoxylin-eosin. $\times 100$.

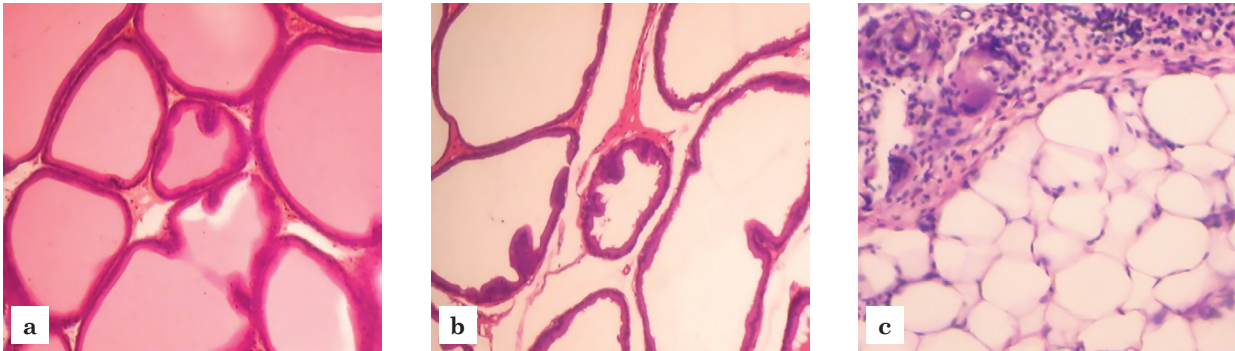


Fig. 3. The prostate gland of a rat, which was injected with Prostaplant forte against the background of cryotrauma:

a, b — the state of acini of different prostatic glands is not changed;
c — focal inflammation reaction in paraprostatic tissue.

Hematoxylin-eosin. $\times 200$.

of the state of a significant number of acini of the prostatic glands in the ventral lobule of the prostate, the disappearance or reduction of inflammation in the interacinar stroma and paraprostatic tissue. There was no edema and interacinar protein effusion.

At the same time, the structure of the acini in the isthmus between the ventral lobules of the prostate has not yet fully recovered, in some acini the wall was focal destroyed, stretching and thinning of the epithelial lining was track down, and the tortuosity of the acini contours was increased.

After the course of administration of the CS substance, the morphofunctional state of many prostatic glands of the investigated prostate zones improved in comparison with the group CP. There was no inflammatory response in the paraprostatic tissue and in the interacinar stroma in the overwhelming majority of rats. The state of acini of different types of prostatic glands is actually unchanged.

The structure of the acini in the isthmus between the ventral lobes of the prostate have not had difference from the IC group. However, there were still acini of the prostatic glands in the ventral zone of the prostate, which were characterized by increased size, increased tortuosity of the form, thinning or focal damage to the integrity of a small amount epithelial lining.

In this way, the results of the laboratory and histological studies in the conditions of simulating prostatopathy have been shown that markers of inflammation of the blood and prostate tissue have parallel unidirectional changes. Both drugs have a distinct anti-inflammatory effect and they are able to protect prostate tissue from destructive changes resulting from inflammation. The effectiveness of CS did not concede to the comparison drug Prostaplant forte, and was even partly more effective in normalizing the concentration of CRP and reconstruction of prostate tissue.

CONCLUSIONS

1. In experimental cryo-traumatic prostatitis prostatic protector Prostaplant Forte and chondroprotector Chondroitin sulfate show anti-inflammatory properties, as evidenced by a decrease in the number of leukocytes and erythrocyte sedimentation rate, the concentration of C-reactive protein in the blood, and decrease destructive changes in the prostate tissue.
2. In terms of anti-inflammatory properties, the chondroprotector Chondroitin sulfate is

not concede to the prostatic protector Prostaplant Forte; but in terms of effectiveness to reconstruction of prostatic tissue and to decreasing the level of inflammation markers in the blood, it even slightly exceeds the effect of the reference drug.

3. These results indicate that the use of a combination of prostatic protectors and drugs capable of affecting the metabolism and reconstruction of connective tissue is promising for the treatment of prostatitis.

REFERENCES

- Zhang R, Chomistek AK, Dimitrakoff JD, et al. *Med Sci Sports Exerc* 2015;47(4): 757-764. <https://doi.org/10.1249/MSS.0000000000000472>.
- Berger RE. *J Urol* 2011;170(17): 1219-1224. <https://doi.org/10.1001/archinternmed.2010.319>.
- Nickel JC, Alexander RB, Schaeffer AJ, et al. *J Urol* 2003;170(3): 818-822. <https://doi.org/10.1097/01.ju.0000082252.49374.e9>.
- Franco JV, Turk T, Jung JH, et al. *Cochrane Database Syst Rev* 2018;1(1): CD012551. <https://doi.org/10.1002/14651858.CD012551.pub2>.
- Franco JVA, Turk T, Jung JH, et al. *BJU Int* 2020; 125(4): 490-496. <https://doi.org/10.1111/bju.14988>.
- Doklinichni doslidzhennja likars'kyh zasobiv : metodychni rekomendacii' / za red. O. V. Stefanova, Kyiv, 2001: 528 p.
- Zajchenko GV, Andrijanenko OV, Gevojan SR, Soldatova JeO. Novitni pidhody do modeljuvannja kriotravmy peredmihurovoi' zalozy v eksperymenty : inform. lyst, Kyiv, 2013: 4 p.
- Patent 38911 UA. Sposib vyznachennja koncentracii' S-reaktyvnoho bilka ekspres-metodom.
- Merkulov G. A. Kurs patologistologicheskoy tehniky, Moskva, 1969: 424 p.

**КОРЕЛЯЦІЯ ЗАПАЛЕННЯ
ІЗ СТРУКТУРНИМИ І ФУНКЦІОНАЛЬНИМИ ЗМІНАМИ
В ПЕРЕДМІХУРОВІЙ ЗАЛОЗІ ЩУРІВ ІЗ ХРОНІЧНИМ ПРОСТАТИТОМ
ЗА УМОВ ЗАСТОСУВАННЯ ХОНДРОЇТИНУ СУЛЬФАТУ**

Бречка Н.М.¹, Козар В.В.², Коренева Є. М.¹, Бондаренко В.О.¹,
Должикова О. В.², Ткаченко Н. О.³, Борозинець В. В.³, Проценко О. С.³, Залюбовська О. І.⁴

¹ ДУ «Інститут проблем ендокринної патології ім. В. Я. Данилевського НАМН України»,
м. Харків, Україна

² Національний фармацевтичний університет, м. Харків, Україна

³ Харківський національний університет ім. В. Каразіна, м. Харків, Україна

⁴ Харківський національний медичний університет, м. Харків, Україна
natalia01073@gmail.com

За статистикою близько 10 % урологічних хворих в Україні мають діагноз хронічного простатиту/ синдрому хронічного тазового болю, або абактеріального хронічного простатиту. Етіологія і патогенез залишаються значною мірою ще невизначеними, проте запалення є одним із тригерів цього стану, в який залучена і сполучна тканина.

Метою даного дослідження було оцінити та співставити зміни маркерів запалення та гістоструктури тканини простати у щурів із експериментальним хронічним простатитом в умовах застосування Хондрітину сульфату. Експериментальна модель небактеріального простатиту була змодельована хірургічним доступом до передміхурової залози (ПЗ) та місцевим зрошенням простати спреєм «Вартнер» протягом 5 секунд. Для оцінки протизапальних та простатопротекторних властивостей застосовували введення субстанції Хондрітину сульфату препарату порівняння Простаплант форте, які починали вводити за три доби до моделювання простатиту та протягом 11 діб. Визначали стан запалення за концентрацією С-реактивного білка, кількістю лейкоцитів, швидкістю зсідання еритроцитів в крові. Стан сполучної тканини оцінювали за результатами гістологічного дослідження передміхурової залози. Встановлено, що в умовах моделювання простатопатії маркери запалення в крові та тканині простати мають паралельні однонаправлені зміни. Досліджені препарати мають протизапальні властивості та зменшують деструктивні зміни в простаті. ХС не поступався за ефектом препарату порівняння Простаплант форте, і був навіть дещо ефективнішим за нормалізацією концентрації С-реактивного білка та відновленням тканини передміхурової залози. Обидва препарати мають виразний протизапальний ефект та здатні захищати тканину простати від деструктивних змін, які виникли в результаті запалення. Хондрітину сульфат за відновленням тканини передміхурової залози та зменшенням рівня маркерів запалення у крові навіть дещо перевищує дію препарату порівняння. Отримані результати вказують на перспективність застосування у терапії простатитів комбінації простатопротекторів та препаратів, які здатні впливати на метаболізм і відновлення сполучної тканини.

Ключові слова: абактеріальний простатит, Хондрітину сульфат, Простаплант форте, сполучна тканина, запалення.

**CORRELATION OF INFLAMMATION
WITH STRUCTURAL AND FUNCTIONAL CHANGES
IN THE RATS' PROSTATE GLAND WITH CHRONIC PROSTATITIS
UNDER THE EXPOSURE OF CHONDROITIN SULPHATE**

**N. M. Brechka^{1,2}, V. V. Kozar², Ye. M. Korenieva¹, V. A. Bondarenko¹,
O. V. Dolzhykova², N. O. Tkachenko³, V. V. Borozenets³, O. S. Protsenko³, E. I. Zalubovskaya⁴**

¹ *SI «V. Danilevsky Institute for Endocrine Pathology Problems
of the NAMS of Ukraine», Kharkiv, Ukraine*

² *National University of Pharmacy, Kharkiv, Ukraine*

³ *V. N. Karazin Kharkiv National University, Kharkiv, Ukraine*

⁴ *Kharkiv National Medical University, Kharkiv, Ukraine
natalia01073@gmail.com*

According to statistics, about 10 % of urological patients in Ukraine have diagnose as well chronic prostatitis/chronic pelvic pain syndrome, or non-bacterial chronic prostatitis. The etiology and pathogenesis continue to be substantially uncertain, but inflammation is one of the triggers that also involves connective tissue. The aim of the work was to evaluate and compare changes of inflammation markers and histological structure of prostate tissue in rats with experimental chronic prostatitis under conditions of Chondroitin sulfate use.

Non-bacterial prostatitis was caused by local irrigation of the previously exposed surgical access to isthmus and ventral parts of the prostate for 5 seconds by an applicator for the wart removal Wartner®, the wounded surface was sewed in afterwards. Non-bacterial prostatitis was caused by local irrigation of the previously exposed surgical access to isthmus and ventral parts of the prostate for 5 seconds by an applicator for the wart removal Wartner®, the wounded surface was sewed in afterwards. To assess the anti-inflammatory and prostatic-protective properties, we used the introduction of the substance Chondroitin sulfate (manufactured by Sigma, USA) and the reference drug Prostoplast forte (manufactured by Schwabe, Germany). The drugs were administered three days before the simulation of cryotraumatic prostatitis and within 11 days after cryotrauma. The state of inflammation was assessed by the level of C-reactive protein, the number of leukocytes, the erythrocyte sedimentation rate in the blood, and during pharmacological correction. The state of the connective tissue was assessed according to the results of histological examination of the prostate.

The results of the laboratory and histological studies in the conditions of simulating prostatopathy have been shown that markers of inflammation of the blood and prostate tissue have parallel unidirectional changes. Both drugs have a distinct anti-inflammatory effect and they are able to protect prostate tissue from destructive changes resulting from inflammation. The effectiveness of Chondroitin sulfate did not concede to the comparison drug Prostoplast forte, and was even partly more effective in normalizing the concentration of C-reactive protein and reconstruction of prostate tissue. These results indicate that the use of a combination of prostatic-protectors and drugs capable of affecting the metabolism and reconstruction of connective tissue is promising for the treatment of prostatitis.

Keywords: non-bacterial prostatitis, Chondroitin sulfate, Prostoplast forte, connective tissue, inflammation.