

MORPHOLOGY 28 (1)

Original Articles

Folia of Human Cerebellum: Structure and Variations

Nataliia Maryenko, Oleksandr Stepanenko

Department of Histology, Cytology and Embryology, Kharkiv National Medical University, Kharkiv, Ukraine

Corresponding author e-mail: maryenko.n@gmail.com

The aim of the study was to describe possible variations in size and shape of folia of human cerebellum to determine morphological and morphometric characteristics of normal cerebellar folia. Cadaveric material (cerebella of 50 people) was studied. It was shown that cerebellar folia aren't uniform in size and shape. We developed the original classification of cerebellar folia. The folia were divided into 3 types according to folium height (small, medium and large) and width (small, medium and large). 9 anatomical variants of cerebellar folia were described in accordance with the shape and ratio of height and width of the folia. Different cerebellar lobules and branches have different folial variants, but all described folial types and variants may be found in a single cerebellum. The results of the study may be helpful to distinguish normal and abnormal cerebellar folia to diagnose cerebellar malformations in clinical neuroimaging and morphological studies of cerebellum.

Key words: brain, cerebellum, vermis, folium, variations

Introduction

Human cerebellum has the most geometrically complex shape and spatial configuration among the various structures of the central nervous system. Cerebellar cortex forms a three-dimensional convoluted foliated structure, duplicating external contour of white matter [7, 13].

Cerebellar folium is the smallest recognizable fold of the cerebellar cortex (gyrus), located on the plate of white matter. Some folia have their own white matter (core of the folium) departing from the underlying white matter of the cerebellar branches.

Cerebellar folium has the crown (apex) and walls (lateral surfaces). Adjacent folia are separated by fissures. The bottoms of separating fissures have their own cortex (interfolial) and are also called “fundi”. The folial cortex has some structural features in different parts of folia: the granular layer has greater volume and thickness in the folial crown, Purkinje cell density is greater in folial crowns than in walls and fundi [13].

Cerebellar folium is considered by some scientists as a distinct structural, connectional and functional entity and independent working module (unit) of cerebellum, which has common afferent and common efferent pathways [13].

Morphological changes of cerebellar folia (changes in size, structure and spatial organization) are found in many neurodegenerative diseases, cerebellar dysplasia and hypoplasia [4, 10] and are used as basic parameters in classifications of cerebellar malformations [4, 9]. There are some studies describing pathological changes in cerebellar folia and cortex as neuroimaging findings: disorganization and malorientation of the folia, abnormal folial pattern, decrease in folium size (cerebellar microgyria), absence of folia (cerebellar agiriya) etc. [3, 4, 9, 10, 11, 12]. Thus, detailed information about shape and size of normal cerebellar folia is needed to distinguish normal and abnormal cerebellar folia to diagnose cerebellar malformations using neuroimaging methods. Welker described the structure of cerebellar folia [13]. But we didn't find any information about size and variability of folia of human cerebellum. That's why in this study we aimed to describe possible variations in size and shape of folia of human cerebellum to determine morphological and morphometric characteristics of normal cerebellar folia.

Material and Methods

The study was performed on cadaveric material. Cerebella of 50 people (20-88 years old) who died of causes unrelated to central nervous system pathology were studied. Causes of death of people included in the study are given in **Table 1**.

Table 1. Causes of death of people included in the study

Cause of death	Acute heart failure	Malignant tumors (except brain tumors)	Pneumonia	External or internal bleeding	Asphyxia	Total
N	25	14	5	3	3	50

Cerebella were obtained during the forensic autopsies and were fixed during one month in 10% formalin solution. Macrophotographs of midsagittal sections of cerebella (**Fig. 1**) were investigated. Possible variations in the size, shape of the folia of cerebellar vermis were described.

Histological sections of individual cerebellar vermal lobules were prepared and used for morphometric study of cerebellar folia (**Fig. 2**). Hematoxylin and eosin staining was used.

The morphometric study was performed using the computer program “Image Tool”. The height, the width, the length of the ganglionic layer (Purkinje cell layer), the number of Purkinje cells, the average distance between the centers of the Purkinje cells and the Purkinje cells density were measured and calculated on each individual folium.

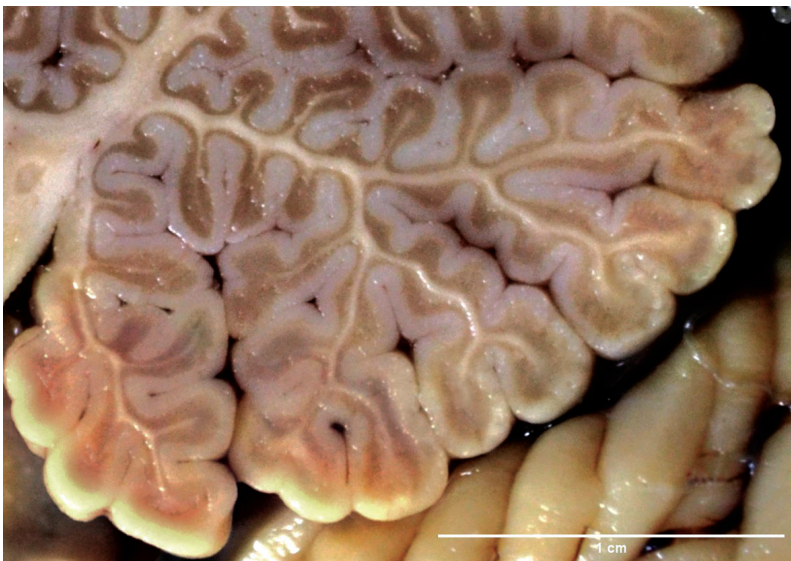

Fig.1. Midsagittal section of human cerebellum vermis, folia of lobules IX and X. Scale bar 1 cm.

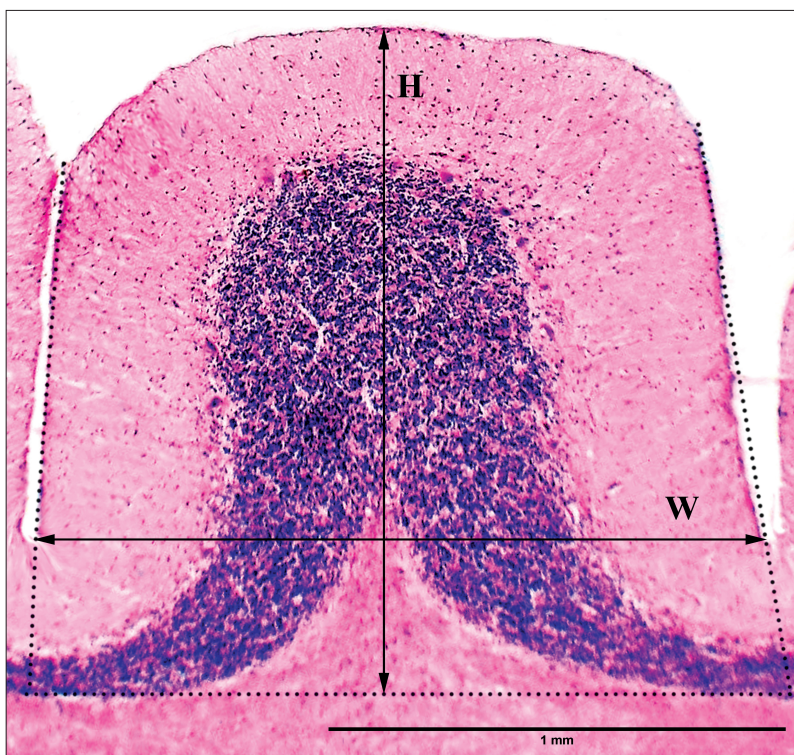


Fig.2. Cerebellar folium (hematoxylin and eosin staining), H – folium height, W – folium width. Scale bar 1 mm.

The folium height was measured as a distance between the apical point of the folium and the line, which connects basal (the deepest) points of the granular layer of the fundi – interfolial fissures (basal line). The folium width was measured as a maximal distance between the lateral surfaces of the folium. The folium height was perpendicular (or close to perpendicular) to the basal line and to the folium width in folia with simple shape. The morphometric parameters (height and width) and features of the shape of folia were used to describe folial types and variants to develop classification of cerebellar folia.

Statistical data processing was performed using Microsoft Excel 2010. The relative prevalence of different folial types and variants was calculated as a ratio between the number of folia which were classified as belonging to different types or variants and the general number of folia. The following values of morphometric parameters of cerebellar folia were calculated: the sample mean (M) and the standard error of the mean (m), standard deviation (σ), the minimum (min) and the maximum (max) values. These parameters were calculated for all folia and individually for different variants of folia ($M \pm m$). The normality of distribution was verified using the Kolmogorov–Smirnov KS test: the empirical distribution function of the sample was compared to normal distribution function with the same values of the sample mean and standard deviation. The significance of statistical difference between the values of morphometric parameters of different folial variants was assessed using Kruskal–Wallis test and post hoc Dunn’s test for multiple comparisons. The significance level for all results was accepted as $p < 0.05$ (the differences between groups (folial variants) and the differences between distributions (empirical and normal) were considered as significant).

Results

The morphometric parameters and the shapes of cerebellar folia are quite diverse. We measured and calculated the average morphometric parameters of cerebellar folia in general in our previous studies [8] and used those average values to develop the original classification of cerebellar folia in the present study. The values of folium height and folium width were normally distributed ($p > 0.95$). Thus, the values of the sample mean and standard deviation were eligible to be used to develop the classification of the folia. We divided folia into groups (types) in accordance with the sample mean values of the folia height and width (M) and standard deviation of those values (σ) (**Table 2**). Height and width of the folia were classified as medium if value of size parameter was ranged between $M - \sigma$ and $M + \sigma$; small – up to $M - \sigma$; large – more than $M + \sigma$. The mean value of folium height was $1727.94 \pm 55.94 \mu\text{m}$ (min – $324 \mu\text{m}$, max – $5286 \mu\text{m}$, standard deviation – $842.82 \mu\text{m}$). The folia were divided into three types according to the height: small (height up to $884 \mu\text{m}$), medium (height 885 – $2571 \mu\text{m}$), and large (height $5286 \mu\text{m}$ and more). The mean value of folium width was $1794.94 \pm 58.10 \mu\text{m}$ (min – $828 \mu\text{m}$, max – $3893 \mu\text{m}$, standard deviation – $436.78 \mu\text{m}$). The folia were also divided into similar types according to the width: small (width up to $1357 \mu\text{m}$), medium (width 1358 – $2231 \mu\text{m}$), and large (width $2232 \mu\text{m}$ and more). These types of folia may be combined in different ways and have different prevalence. The folial types (described according to height and width) are combined independently of each other, all possible combinations were found.

Table 2. The prevalence of combinations of different folial types

Height of folium	Width of folium			Total
	Small	Medium	Large	
Small	2.10%	9.01%	3.04%	14.15%
Medium	11.01%	48.22%	8.70%	67.93%
Large	1.47%	13.52%	2.94%	17.92%
Total	14.57%	70.75%	14.68%	100%

However, in addition to morphometric parameters, folia have shape features that have a significant impact on their structure. We described 9 anatomical variants of cerebellar folia, taking into account the morphometric characteristics (height, width and their ratio) and the shape of folia (**Table 3, Fig. 3**).

Table 3. Classification of cerebellar folia

Folium variant	Ratio "height / width"		Height	Width
	Min	Max		
1 st	0.25	0.489	small	large
	0.25	0.489	small	medium
	0.25	0.489	medium	large
	<i>except</i>		<i>medium</i>	<i>medium</i>
2 nd	0.25	0.75	medium	medium
	0.49	0.75	small	small
	0.49	0.75	small	medium
	<i>except</i>		<i>medium</i>	<i>large</i>
3 rd	0.49	0.75	medium	large
4 th	0.751	1.249	small	medium
			medium	medium
			medium	large
			large	large
5 th	1.25	1.799	medium	medium
			medium	small
			large	medium
6 th	1.8	2.78	medium	small
			large	medium
			large	small

Folium variant	Ratio "height / width"		Height	Width
	Min	Max		
7 th	0.49	1.249	The folia have the isthmus (basal narrowing or neck) in the basal part	
8 th	1.25	1.799		
9 th	1.8	3.77		

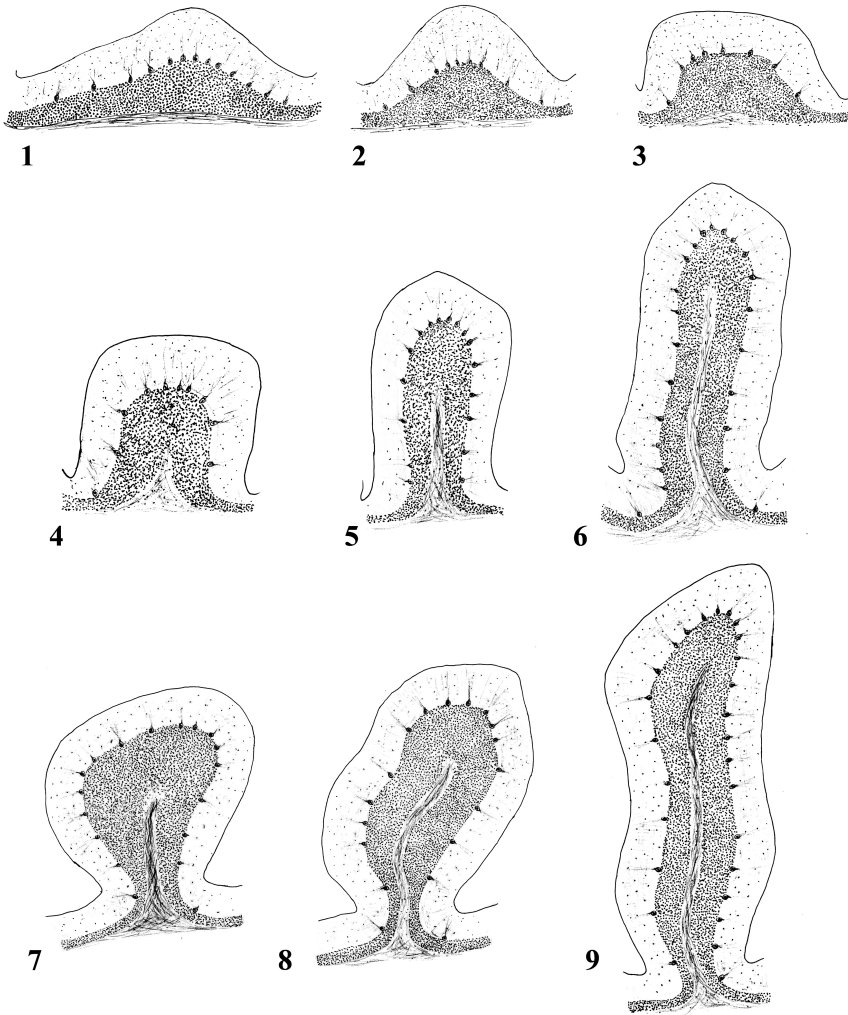


Fig.3. Anatomical variants of cerebellar folia (author's drawing)

The 1st variant: the folia have the shape of a low wave, have rounded or flattened crown (top) and don't have their own white matter. The shape of those folia may be asymmetrical. The folia are located on the inner surfaces of the white matter branches near their base (often) or on the outer surfaces of the white matter branches between large long folia (rarely).

The 2nd variant: the folia are small, have triangle-like or crescent-like (demilune-like) shape and have rounded or pointed crown. White matter also has triangle-like or crescent-like shape. Sometimes folia don't have their own white matter. The folia are located between large folia (often) or are located on the inner surfaces of the white matter branches (rarely).

The 3rd variant: the folia have the semicircle-like or rectangle-like shape. The folia often don't have their own white matter. The folia are located on small white matter branches (often) or on the main trunk of white matter, forming the lobule (less often).

The 4th variant: the folia have the square-like or semicircle-like shape; the crown is rounded or rectangular. The shape of white matter is triangle-like (often) or crescent-like (rarely). Sometimes the folia don't have their own white matter. The folia are located on the inner surfaces of the white matter branches (often) or on the outer surfaces of branches and the main trunk of white matter (less often).

The 5th variant: the folia have the elongated rectangle-like shape; the crown is rounded or rectangular. The white matter has the shape of the elongated plate (simple branch). The folia are located on the outer surfaces of the main trunk and secondary branches of the cerebellar white matter.

The 6th variant: the folia have the shape of a tall rectangle; the crown is round or rectangular. The white matter has the branch-like shape. The folia are located on the main trunk of the lobules (often) or on the outer surfaces of the branches (less often).

The folia of 7th, 8th and 9th variants have the isthmus in the basal part (basal narrowing or neck) which is a distinctive feature of the shape.

The 7th variant: the folia have rounded goblet-like shape and have the isthmus in the basal part. The crown is rounded, pointed or flattened. The white matter has the branch-like shape. The folia are located on the apical points of branches and form the visible surface of cerebellum (often) or are located on the main trunk of lobules (less often).

The 8th variant: the folia have elongated goblet-like or leaf-like shape and have the isthmus in the basal part. The apex is pointed or rounded. The white matter has the branch-like shape. The folia may be apical and form the visible surface of cerebellum or are located on the main trunk of lobules (more often).

The 9th variant: the folia are the longest among all variants, have the isthmus in the basal part. The folium shape is leaf-like or sword-like: the apex is pointed or rounded (rarely), sometimes flattened. The white matter has the branch-like shape. The folia are located on the common trunk of the lobules VI-VII, on the main trunks of lobules VIII and IX (often), less often on the main trunks of lobules II, III and X.

The variants of cerebellar folia shape have different values of morphometric parameters (**Table 4**). The sample mean values of height, width, length of ganglionic layer and number of Purkinje cells in different folial variants were significantly different ($p < 0.05$). The sample mean values of the average distance between the centers of Purkinje cells and the Purkinje cells density in different folial variants were not significantly different ($p > 0.05$).

Table 4. The morphometric parameters of different variants of cerebellar folia, $M\pm m$

Parameters		Folium variant								
		1 st	2 nd	3 rd	4 th	5 th	6 th	7 th	8 th	9 th
Height, μm	<i>M</i>	838.8	1026.5	1358.1	1396.7	1961.9	2784.0	1993.8	2613.2	3437.3
	<i>m</i>	70.2	78.5	266.3	106.8	314.2	718.8	157.6	201.6	459.3
Width, μm	<i>M</i>	2225.2	1730.7	2178.9	1502.2	1372.0	1281.9	1996.1	1759.1	1583.6
	<i>m</i>	182.2	132.4	427.3	114.9	219.7	331.0	157.8	135.7	211.6
Ratio “height/width”, μm	<i>M</i>	0.385	0.599	0.627	0.937	1.431	2.182	1.011	1.486	2.204
	<i>m</i>	0.03	0.05	0.12	0.07	0.23	0.56	0.08	0.11	0.29
Length of ganglionic layer, μm	<i>M</i>	2683.4	2441.0	3569.4	3048.5	4121.1	5666.1	4729.1	5717.9	7286.9
	<i>m</i>	221.3	186.7	700.0	233.1	659.9	1463.0	373.9	441.2	973.8
Number of Purkinje cells	<i>M</i>	11.24	10.49	14.12	13.52	15.74	22.93	19.39	23.47	30.16
	<i>m</i>	0.92	0.80	2.77	1.03	2.52	5.92	1.53	1.81	4.03
Average distance between the centers of the Purkinje cells, μm	<i>M</i>	249.22	282.60	302.82	255.80	345.69	263.06	289.04	280.82	252.90
	<i>m</i>	24.15	21.61	59.39	19.56	55.35	67.92	22.85	21.67	33.80
Purkinje cells density, cells per mm	<i>M</i>	4.14	4.33	3.98	4.42	3.80	4.04	4.09	4.07	4.16
	<i>m</i>	0.34	0.33	0.78	0.34	0.61	1.04	0.32	0.31	0.56

The described folial variants have different prevalence, which reflects the distribution of the folia in different phylogenetic regions of cerebellum – Upper Paleocerebellum (lobules I-V), Neocerebellum (lobules VI-VII), Lower Paleocerebellum (lobules VIII-X) and Archicerebellum (lobule X) (**Table 5**). Different cerebellar lobules and branches have different prevalence of folial variants, but all described folial types and variants may be found in a single cerebellum. Thus, the differences in size and shape of cerebellar folia aren't the direct signs of cerebellar malformations. Distribution and grouping of folia with different shape and size into lobules would be expected to reflect functional features of various cerebellar regions.

Table 5. The prevalence of different variants of the folia in different phylogenetic regions of human cerebellum

Folium variant	Localization of the folia (phylogenetic regions of cerebellum)				Total
	Upper Paleocerebellum (lobules I-V)	Neocerebellum (lobules VI-VII)	Lower Paleocerebellum (lobules VIII-X)	Archeo-cerebellum (lobule X)	
1 st	5.97%	3.98%	4.93%	0.42%	15.30%
2 nd	7.97%	4.51%	5.14%	0.31%	17.93%
3 rd	1.47%	0.84%	0.42%	0%	2.73%
4 th	8.39%	5.14%	3.67%	0.84%	18.04%
5 th	1.68%	0.94%	1.15%	0.31%	4.08%
6 th	0.31%	0.51%	0.42%	0.42%	1.66%
7 th	7.65%	4.30%	3.98%	0.84%	16.77%
8 th	6.18%	4.72%	5.66%	1.05%	17.61%
9 th	1.26%	1.26%	2.94%	0.42%	5.88%
Total	40.88%	26.20%	28.31%	4.61%	100.00%

Discussion

In this study we described variations in size and shape of cerebellar folia. Differences in folial shape and size reflect anatomical variability of human cerebellum. Larsell&Jansen [7] and Bispo et al. [2] described some anatomical variations of individual lobules of cerebellar vermis; it was shown that vermal lobules are varying in size and shape.

But we didn't find the information about anatomical variability of folia of human cerebellum. Variations in the size of folia of the avian cerebellum were described by Iwaniuk et al. [5]. The length of the Purkinje cell layer (ganglionic layer) of each cerebellar folium was measured as well as in the present study. Additionally, we measured and calculated some other parameters: height, width of folia and their ratio, the number of Purkinje cells, the average distance between the centers of the Purkinje cells and the Purkinje cells density in individual folia.

The distance between Purkinje cells and the Purkinje cells density were determined by other researches [1, 6]. These values particularly coincide with our data. The distance between 2 Purkinje cells was ranged between 82.6-346.6 μm (mean 179.3 \pm 18.4 μm) [6]; in our study the mean value was ranged between 249.22-345.69 μm in different folial variants. The mean value of the Purkinje cells density in the control group was 3.46 cells/mm [1]; in our study it was ranged between 3.80-4.42 cells/mm in different folial variants. These parameters were previously determined only in the cerebellar cortex in general; we determined them in the individual folia and in the folia with different shape and size for the first time.

Thus, the obtained values of morphometric parameters of folia of human cerebellum, the original classification of folial variants with variant descriptions may be considered as quantitative and qualitative parameters of normal cerebellar folia.

Conclusions

It was shown that folia of human cerebellum aren't uniform in size and shape. Size and shape of all normal cerebellar folia would be expected to correspond to one of the folial variants which were described in the present study. The results of the study may be helpful to distinguish normal and abnormal cerebellar folia to diagnose cerebellar malformations in clinical neuroimaging and in morphological studies of cerebellum.

References

1. **Axelrad, J. E., E. D. Louis, L. S. Honig, I. Flores, G. W. Ross, R. Pahwa, K. E. Lyons, P. L. Faust, J.P. Vonsattel.** Reduced Purkinje cell number in essential tremor: a postmortem study. – *Arch Neurol.*, **65**(1), 2008, 101-107.
2. **Bispo, R., A. Ramalho, L. Gusmão, A. Cavalcante, A. Rocha, C. Sousa-Rodrigues.** Cerebellar vermis: Topography and variations. – *Int. J. Morphol.*, **28**(2), 2010, 439-443.
3. **Chatur, C., A. Balani, R. Vadapalli, M. G. Murthy.** Isolated unilateral cerebellar hemispheric dysplasia: A rare entity. – *Can J Neurol Sci.*, **46**(6), 2019, 760-761.
4. **Demaerel, P.** Abnormalities of cerebellar foliation and fissuration: classification, neurogenetics and clinicoradiological correlations. – *Neuroradiology*, **44**, 2002, 639-646.
5. **Iwaniuk, A. N., P. L. Hurd, D. R. Wylie.** Comparative morphology of the avian cerebellum: II. Size of folia. – *Brain Behav Evol.*, **69**(3), 2007, 196-219.
6. **Kalanjati, V.P., A.K. Dewi, M.W.A. Santoso.** Quantitative study on human cerebellar cortex from anatomy cadaver preparations. – *Int. J. Morphol.*, **35**(1), 2017, 167-171.
7. **Larsell, O., J. Jansen.** **Adult Human Cerebellum.** – In: *The comparative anatomy and histology of the cerebellum. The human cerebellum, cerebellar connections, and the cerebellar cortex* (Ed. J. Jansen). Minneapolis, The University of Minnesota Press, 1972, 36-64.
8. **Maryenko, N. I., O. Yu. Stepanenko.** Folium as a structural unit of the human cerebellum. – *Ukr. ž. med. biol. sportu*, **5**(1), 2020, 56–61. [in Ukrainian]
9. **Patel, S., A. J. Barkovich.** Analysis and classification of cerebellar malformations. – *Am J Neuroradiol.*, **23**(7), 2002, 1074-1087.
10. **Poretti, A., E. Boltshauser, D. Doherty.** Cerebellar hypoplasia: Differential diagnosis and diagnostic approach. – *Am J Med Genet Part C Semin Med Genet.*, **166**, 2014, 211-226.
11. **Sasaki, M., H. Oikawa, S. Ehara, Y. Tamakawa, S. Takahashi, H. Tohgi.** Disorganised unilateral cerebellar folia: a mild form of cerebellar cortical dysplasia? – *Neuroradiology*, **43**(2), 2001, 151-155.
12. **Soto-Ares, G., C. Delmaire, B. Deries, L. Vallee, J. P. Pruvo.** Cerebellar cortical dysplasia: MR findings in a complex entity. – *Am J Neuroradiol.*, **21**(8), 2000, 1511-1519.
13. **Welker, W.I.** The significance of foliation and fissuration of cerebellar cortex. The cerebellar folium as a fundamental unit of sensorimotor integration. – *Arch. Ital. Biol.*, **128**(2-4), 1990, 87-109.