

MORPHOLOGICAL FEATURES OF THE UTERUS IN WOMEN AT DIFFERENT TIME INTERVALS OF THE POSTMORTEM PERIOD AS DIAGNOSTIC CRITERIA FOR ESTABLISHING THE POSTMORTEM INTERVAL

DOI: 10.36740/WLek202104102

Vasil O. Olkhovsky¹, Edgar K. Grygorian¹, Mykhailo S. Myroshnychenko¹, Sergii V. Kozlov², Kostiantyn M. Suloiiev², Anton O. Polianskyi³, Petro A. Kaplunovskiy¹, Yuliia Ya. Fedulenkova¹, Iryna V. Borzenkova⁴

¹KHARKIV NATIONAL MEDICAL UNIVERSITY, KHARKIV, UKRAINE

²STATE INSTITUTION «DNIPROPETROVSK MEDICAL ACADEMY OF THE MINISTRY OF HEALTH OF UKRAINE», DNIPRO, UKRAINE

³NATIONAL SCIENTIFIC CENTER «HON. PROF. M. S. BOKARIUS FORENSIC SCIENCE INSTITUTE», KHARKIV, UKRAINE

⁴PUBLIC NONPROFIT ORGANIZATION OF THE KHARKIV DISTRICT COUNCIL «REGIONAL CLINICAL HOSPITAL», KHARKIV, UKRAINE

ABSTRACT

The aim is to identify the morphological features of the uterus layers in women at different time intervals of the postmortem period as diagnostic criteria for establishing the postmortem interval.

Materials and methods: In the study we used surgical and autopsy material – uterine tissue fragments. All materials were divided into two groups. The 1st group (G1) included surgical material from women (n=6) who underwent removal of the uterus, or uterus with the appendages due to leiomyoma, uterine prolapse. The 2nd group (G2) included autopsy material from 42 women with known causes of death and postmortem period (from 24 to 48 hours – 6 cases, from 49 to 72 hours – 7 cases, from 73 to 96 hours – 8 cases, from 97 to 120 hours – 6 cases, from 121 to 144 hours – 8 cases, more than 144 hours – 7 cases). Histological and immunohistochemical study methods were used.

Results: A comprehensive morphological study of the women uterus revealed a time-dependent increase of postmortem changes in this organ linked with the increase of postmortem period. In cases of postmortem period duration up to 144 hours, the structural elements of the uterine layers were identified. In cases where the duration of the postmortem period was more than 145 hours, microscopically the uterus was represented by eosinophilic fibrous or dusty masses, the histogenesis of which could not be determined. The processes of autolysis occurred more intensely and faster in the mucous membrane of the uterus, in comparison with the muscular and serous membranes, and in the vessels – in their inner membrane, in comparison with the middle and outer membranes. Autolytic changes in the muscular membrane of the uterus and vascular walls occurred more intensely in muscle fibers compared to connective tissue fibers.

Conclusions: The histological and immunohistochemical features of the women uterus at different postmortem periods have a certain forensic medical significance and can be used for establishing the postmortem interval.

KEY WORDS: morphological features, uterus, postmortem period, diagnostic criteria

Wiad Lek. 2021;74(4):821-827

INTRODUCTION

The issues of determining the postmortem interval in forensic science and practice were always relevant and will probably remain so for a long time [1]. The prescription of death, as is known, is determined by a forensic expert when examining a corpse at the place of its detection and its subsequent autopsy [2].

Today, there is a large arsenal of diagnostic methods that allow forensic experts to establish approximate time intervals for the prescription of death. Some methods are quite complex for practical use, while others are only of scientific and theoretical significance, since their implementation requires complex and expensive equipment, which is used in special fields of science and technology [3, 4]. Thus, an important issue of modern forensic science and practice is the search and development of new and effective diagnostic criteria that would allow experts to determine the post-

mortem interval more accurately and to give a reasoned opinion meeting the needs of law enforcement agencies.

An important role in the development of diagnostic criteria that allow experts to establish the postmortem interval in various terms of the postmortem period is assigned to morphological methods. In the available domestic and foreign literature, we did not identify the complex morphological studies of the uterus in order to establish the valid and reliable diagnostic criteria for determining the postmortem interval. That fact actualizes the current study.

THE AIM

The aim is to identify the morphological features of the uterus layers in women at different time intervals of the postmortem period as diagnostic criteria for establishing the postmortem interval.

MATERIALS AND METHODS

In the study we used surgical and autopsy material – uterine tissue fragments. All materials were divided into two groups. The 1st group (G 1) included surgical material from women (n=6) who underwent removal of the uterus, or uterus with the appendages due to leiomyoma, uterine prolapse. The 2nd group (G 2) included autopsy material from 42 women with known causes of death and postmortem period (from 24 to 48 hours – 6 cases, from 49 to 72 hours – 7 cases, from 73 to 96 hours – 8 cases, from 97 to 120 hours – 6 cases, from 121 to 144 hours – 8 cases, more than 144 hours – 7 cases). The average age of women in G 1 and G 2 did not have significant differences ($p>0.05$) and amounted to 68.7 ± 2.5 years and 69.4 ± 2.7 years, respectively, which, according to the age classification of the World Health Organization, corresponds to old age. The criteria for excluding cases from G 1 were the presence of information in the medical history about the woman's intake of alcohol or drugs, from G 2 – the presence of information about the woman's intake of alcohol or drugs, violent death or death with an unknown cause and diagnosis.

In G 1 and G 2 the fragments of uterine tissue were cut out through the entire thickness of the organ in the areas without macroscopically detected pathological processes. The resulting material was fixed in a 10 % solution of neutral formalin (pH 7.4) for 24-48 hours, carried out according to the generally accepted technique and embedded in paraffin. From paraffin blocks serial sections with a thickness of 4-5 μm were made. The slides stained with hematoxylin and eosin were examined using an Olympus BX-41 microscope (Japan).

Immunohistochemical study was performed according to standardized protocols using a murine monoclonal antibody (MCA) to smooth muscle actin (HHF35 clone, Diagnostic BioSystems Inc., USA). Visualization was performed using a PolyVue Plus™ HRP/DAB Detection System (Diagnostic BioSystems Inc., USA).

RESULTS

In G 1, an observation microscopy in the uterus revealed three characteristic layers (mucosa, or endometrium; muscular, or myometrium; serous, or perimetrium), the boundaries between which were clear (fig. 1a, 1b). Among these layers, myometrium was characterized by the greatest thickness. In all uterus layers, stained with hematoxylin and eosin, there was a uniform staining of cell nuclei in a blue and violet color and the cells cytoplasm, connective tissue fibers in a pink-red color.

The endometrium was lined with a single-layer prismatic epithelium, which was located on the loose unformed connective tissue. Vessels, nerve fibers and numerous uterine glands, extending through the entire thickness of the endometrium, passed between the connective tissue fibers. The uterine glands in some fields of view looked like narrow straight tubes or cystic-enlarged cavities, and in some fields of view they lengthened and twisted in a corkscrew-like manner. Also, between the connective tis-

sue fibers, a diffuse polymorphic cellular infiltration was revealed, which mainly consisted of the cells of fibroblast series and immune cells.

The myometrium was characterized by the presence of parenchyma and stroma. The parenchymal component was represented by a set of smooth muscle cells, which united into bundles and formed three layers, the boundaries between which were indistinct. The direction of smooth muscle cells in the layers was different: longitudinal – in the outer and inner layers, circular – in the middle layer. In most fields of view, the bundles of muscle fibers were tightly attached to each other. Myocytes were characterized by the presence of a rod-shaped nucleus located in the central part of the cell. The stroma was represented by thin layers of connective tissue fibers, between which vessels and nerve fibers were located. Also diffuse, moderately pronounced polymorphic cellular infiltration was determined, represented mainly by the cells of fibroblast series and immune cells.

The serous layer was adjacent to the myometrium and was represented by densely located connective tissue fibers. Between them, there were nerve fibers, vessels and polymorphic-cellular infiltration, which was represented mainly by the cells of fibroblast series and immune cells. From the surface, the serous layer was covered by mesothelium.

In G 1, an immunohistochemical reaction with MCA to smooth muscle actin showed the uniform and clear cytoplasmic dark brown staining of myofibroblasts located in all layers of the uterus, as well as of smooth muscle cells of the vessels and myometrium.

In G 2, in cases where the postmortem period lasted from 24 to 48 hours, an observation microscopy revealed clear boundaries between the uterus layers. The endometrium was characterized by uneven thickness (fig. 2a). It lacked the characteristic single-layer prismatic epithelium. In the lamina propria there were moderate edematous changes of the cellular elements and connective tissue fibers, which unevenly stained with hematoxylin and eosin. Light slit-like spaces were identified between the connective tissue fibers. Stromal cellularity did not change compared with G 1. In most of the uterine glands, desquamation of epithelial cells was detected. Desquamated cells were located in groups in the glands lumens, had a well-defined structure or were enlarged in size with pyknotic nuclei. In the lumens of some glands, only the epithelial cells nuclei were determined, which indicated about the violation of the integrity of these cells.

In myometrium, it was revealed uneven staining with hematoxylin and eosin of the cells nuclei and cytoplasm, as well as connective tissue fibers (fig. 2b). In this membrane, moderate edema of muscle and connective tissue fibers with the presence of light slit-like spaces between them was identified. Muscle fibers in some field of views were also characterized by the presence of few foci of wave-like deformations, thinning and partial ruptures across the fiber axis. In some fields of view, the nuclei of muscle cells were increased in size with light purple color, and in other places they were small with dark purple color. In some myocytes,

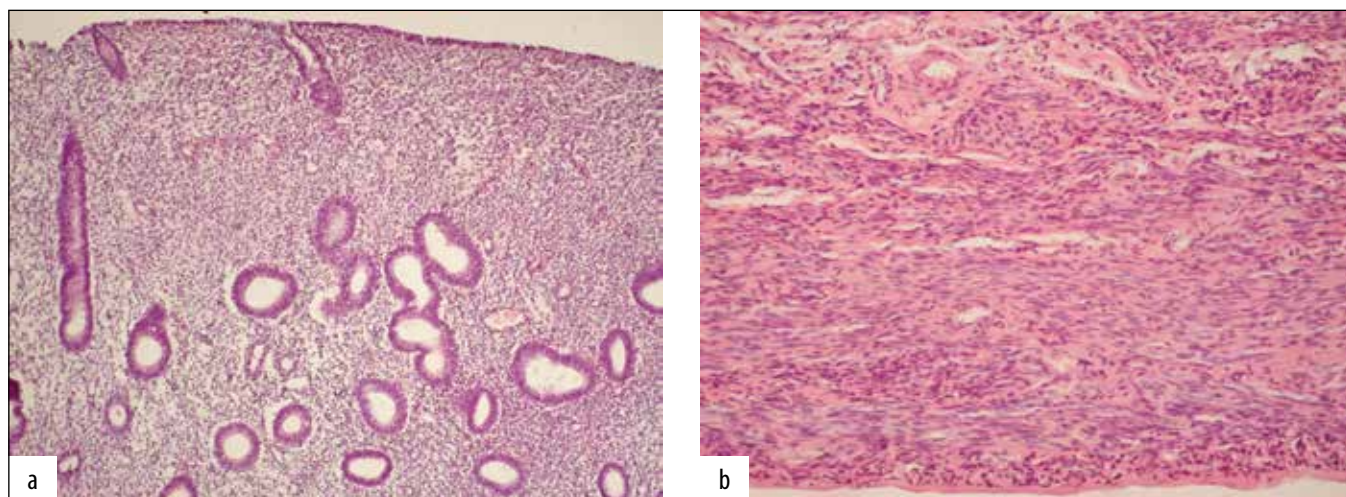


Fig. 1. G 1. Microscopic structure of the mucous, muscular and serous layers of the uterus. Hematoxylin and eosin staining, a) $\times 100$, b) $\times 200$.

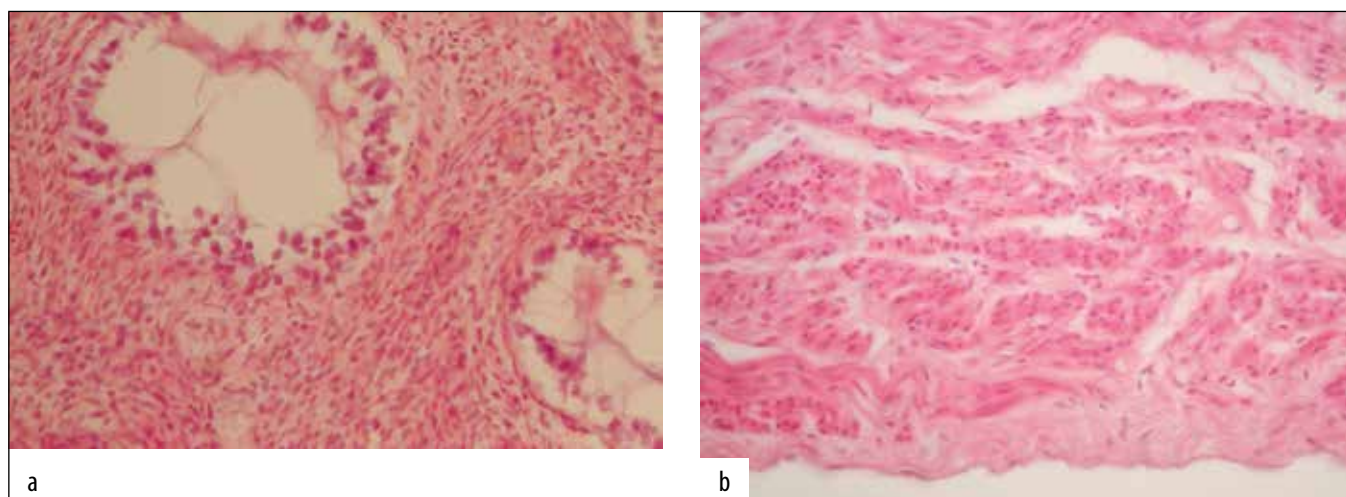


Fig. 2. G 2. The duration of the postmortem period was 39 hours. Microscopic structure of the mucous, muscular and serous layers of the uterus. Hematoxylin and eosin staining, a) $\times 400$, b) $\times 400$.

nuclei were not detected. Between the connective tissue fibers, as in G 1, the cells of fibroblast series and immune cells with moderate edematous changes were visualized.

In serous layer, the mesothelium was practically undetectable (fig. 2b). Moderate edematous changes of cellular elements and connective tissue fibers led to their uneven staining with hematoxylin and eosin. In the light slit-like spaces between the connective tissue fibers, the cells of fibroblast series and immune cells were determined, the number of which was similar to G 1.

In most of the vessels located in all layers of the uterus, there were pronounced endothelial cells desquamation, moderate edematous changes of connective tissue and muscle fibers, and the absence of nuclei in some of the myocytes. In the lumens of most vessels, desquamated endothelial cells of an elongated-curved shape and unchanged erythrocytes were found.

The expression of smooth muscle actin was determined in myofibroblasts, smooth muscle cells of the vessels and myometrium. However, in the described cases, in comparison with G 1, a decrease of the smooth muscle actin

expression was revealed in some fields of view, as a result of which these areas had a light brown color.

In cases where the postmortem period ranged from 49 to 72 hours, in comparison with the earlier postmortem period, we found more pronounced edematous changes and uneven staining of cellular elements and connective tissue fibers with hematoxylin and eosin in all uterine layers.

In mucous membrane we determined the deformed glands with ruptures. There were an increase the desquamative changes of epithelial cells, which were located in the glands lumen and characterized by the absence of nuclei or the presence of dark-violet nuclei of reduced in size, turbid cytoplasm and indistinct contours. It was revealed the increased number of glands with the presence of a fragment of epithelial cells in their lumens, reduced in size nuclei with the clear areas in their central part (fig. 3). Cellularity of stroma was decreased. The connective tissue fibers were with a loss of the characteristic clarity of the contours, their fragmentation. Also there were increased the spaces between the connective tissue fibers.

In myometrium it was revealed an increase the number

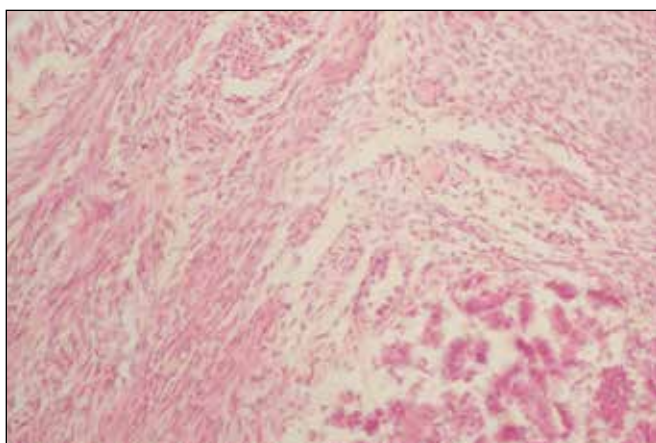


Fig. 3. G2. The duration of the postmortem period was 68 hours. Microscopic structure of the mucous and muscular layers of the uterus. Hematoxylin and eosin staining, $\times 400$.

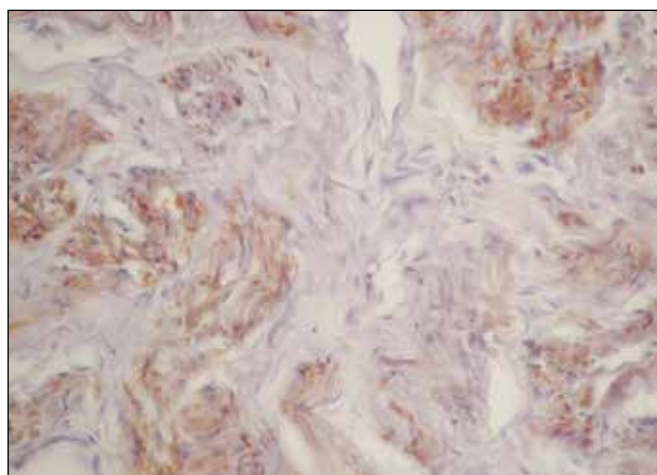


Fig. 4. G2. The duration of the postmortem period was 85 hours. Immunohistochemical reaction with MCA to smooth muscle actin, $\times 400$.

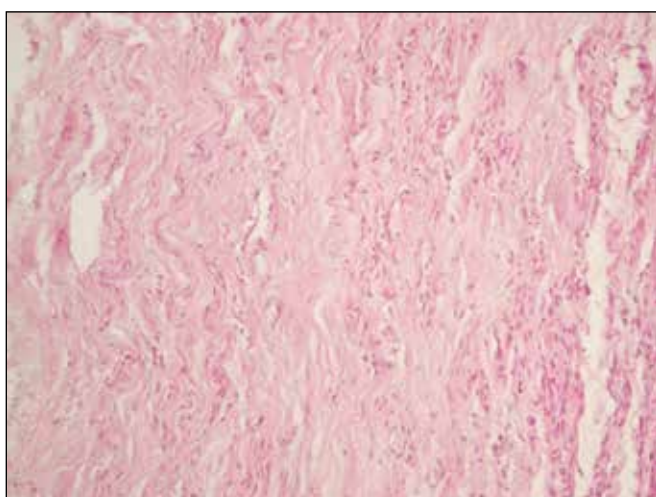


Fig. 5. G2. The duration of the postmortem period was 110 hours. Microscopic structure of the myometrium. Hematoxylin and eosin staining, $\times 200$.

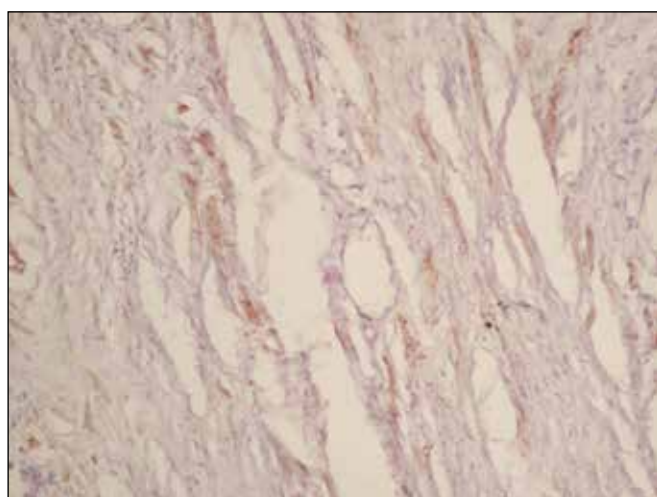


Fig. 6. G2. The duration of the postmortem period was 136 hours. Immunohistochemical reaction with MCA to smooth muscle actin, $\times 200$.

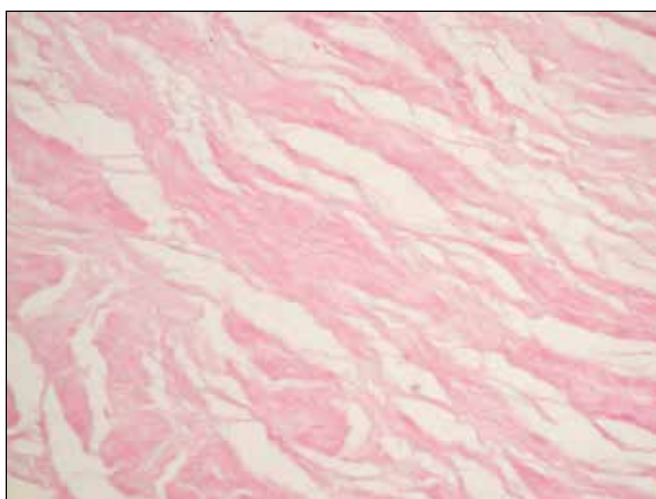


Fig. 7. G2. The duration of the postmortem period was 155 hours. Hematoxylin and eosin staining, $\times 200$.

of the fields of view with the wave-like deformations of the muscular fibers, swelling and turbidity of the their cytoplasm, lack of characteristic clarity of their contours, their

fragmentation and partial ruptures. It was determined the muscle fibers with a complete rupture and disintegration into separate segments. Myocyte nuclei decreased in size and were light purple. We found an increase the number of non-nuclear myocytes. The myocytes nuclei appeared in the intercellular spaces. It was revealed an increase the spaces between the muscle fibers (fig. 3).

In stroma of the myometrium, as well as in serous layer, it was noted an increase the connective tissue fibers swelling. Connective tissue fibers disintegrated into the separate fragments. The spaces between the connective tissue fibers continued to increase. Cellularity decreased markedly.

In the vessels that were located in all uterine layers, the endothelium was not visualized. There was an increase the muscle and connective tissue fibers swelling. It was appeared the rupture and loss of the muscle and connective tissue fibers contour visibility. We found an increase the number of non-nuclear myocytes. An increase the number of desquamated endothelial cells and the appearance of hemolyzed erythrocytes were noted in the vessels lumens.

An immunohistochemical study revealed a decreased expression of smooth muscle actin by myofibroblasts,

smooth muscle cells of the myometrium and vessels, which was manifested by an increase the number of light brown areas. In few fields of view the expression of that MCA was virtually undetected.

In cases where the duration of the postmortem period ranged from 73 to 96 hours, microscopically in all uterine layers there were fields of view with structures unevenly stained with hematoxylin and eosin. Besides, the number of such fields of view in these cases was larger compared to cases where the duration of the postmortem period ranged from 49 to 72 hours. Also in these cases in myometrium and walls of the vessels during hematoxylin and eosin staining there were some fields of view with light pink color and the presence of shadow nuclei, in which it was impossible to differentiate the muscle and connective tissues.

The mucous membrane of the uterus in these cases was not detected in some fields of view. In the fields of view, where that membrane was detected, in comparison with previous cases, there were an increase the number of glands with ruptures and desquamative changes in epithelium of the glands, as a result of which, in their spaces, the small formless elements or strata without a pronounced structure were observed. Some glands took the shape of round-oval voids of various sizes.

In stroma of the endometrium edematous changes of the cellular elements and connective tissue fibers increased, which led to the swelling of the latte. The cellularity was sharply decreased, which in some fields of view was not determined. There was an increase the number of fields of view with thinning, ruptures and fragmentation of connective tissue fibers into separate particles, the boundaries of which in most cases were indistinguishable. The spaces increased between the connective tissue fibers.

In parenchyma of the myometrium, edematous changes of muscle fibers increased, which led to their swelling. Wave-like deformation and complete ruptures of muscle fibers, that did not have clear contours, were growing. It was an increase the number of non-nuclear myocytes and myocytes with the presence of shadow nuclei. These were also an increase the number of the fields of view with the presence in the intercellular space of reduced nuclei of light violet color, or fragments of nuclei. The intermuscular spaces became larger and in some fields of view took the form of cavities.

In connective tissue fibers of muscle and serous layers, there were an increase edematous changes and their swelling. These fibers continued to lose the characteristic clear boundaries and to grow their disintegration into the separate fragments. Between the connective tissue fibers, the spaces increased, which in some fields of view looked like cavities. The cellularity sharply decreased, which was not detected in some fields of view.

In vessels located in all layers of the uterus, there were an increase edematous changes and swelling, ruptures and loss of clarity contours of muscle and connective tissue fibers. We found an increase the number of non-nuclear myocytes and myocytes with the presence of shadow nuclei. In lumens of the vessels, erythrocytes-shadows were identified.

The expression of smooth muscle actin by myofibroblasts, smooth muscle cells of the vessels and myometrium was sharply reduced. In a significant number of fields of view, the number of areas with a positive reaction sharply decreased. The latter were light brown color (fig. 4).

In cases where the duration of the postmortem period ranged from 97 to 120 hours, microscopically the mucous membrane was not determined in the uterus. The boundaries between the muscular and serous layers were indistinct. In comparison with the previous cases, in these cases there was an increase the unevenness of staining of structural elements with hematoxylin and eosin.

In myometrium, in a significant number of fields of view there was an increase the number of homogeneous areas of light pink color. In those areas it was impossible to differentiate the muscle and connective tissues (fig. 5). In single fields of view, where muscle and connective tissue were visualized, in muscle fibers there were an increase edema and swelling, wave-like deformation, fragmentation, loss of contours clarity. The number of myocytes without nuclei and myocytes with shadow nuclei increased. The width of the intermuscular spaces increased, and they often had a cavity-like shape.

In the connective tissue fibers of myometrium and perimetrium, swelling, fragmentation, loss of contours clarity and ruptures were increased. In these layers only in some fields of view the cells of fibroblast series and immune cells were detected.

Vessels located in all layers of the uterus in some fields of view had a totally homogeneous wall of light pink color, in which the layers were not contoured. In some of the vessels, predominantly of large caliber, the contouring of the layers was noted, in there, the muscle and connective tissue fibers were characterized by swelling, indistinct contours and ruptures. The number of non-nuclear myocytes, myocytes with the presence of shadow nuclei, myocytes with reduced in size nuclei of light purple color increased. Lumens of the vessels were without any content or, in some places, erythrocytes-shadows were determined.

In single fields of view, a few smooth muscle cells of the muscle layer expressed smooth muscle actin. These areas looked light brown.

In cases where the duration of the postmortem period ranged from 121 to 144 hours, when stained with hematoxylin and eosin, in all fields of view the eosinophilic (light pink) nuclear-free fibrous structures or their fragments were revealed in the muscular layer that was located closer to the serous membrane. In these areas, it was not possible to differentiate the muscle and connective tissue components, and single basophilic structures that were localized between the fibers fragments which resembled the structure of immune cells. There were wide spaces or cavities between the above-mentioned fibrous structures.

In the deeper parts of the myometrium, located in the direction or closer to the mucous membrane, against the background of eosinophilic fragments of fibrous structures, the histogenesis of which could not be determined, the single areas with the presence of small fragments of muscle

and connective tissue fibers were revealed. The latter did not have clear boundaries, looked swollen and fragmented. In a part of myocytes, small nuclei of light violet color without clear boundaries or shadow nuclei were revealed. The spaces between the fibers were wide. Between the fibers, in some places there were single immune cells.

When stained with hematoxylin and eosin, the serous membrane was represented in a significant number of the fields of view by eosinophilic (pale pink) fragments of fibrous structures that did not have clear contours and were located chaotically. Also, in this layer, single basophilic (light purple) structures were identified the structure of which most likely corresponded to immune cells.

The vessels located in all layers had a rounded-oval shape and were characterized by the presence of light pink fibers, among which it was impossible to differentiate muscle and connective tissues. Fibrous structures often looked fragmented and swollen, with breaks. There was no content in the lumens of the vessels.

When staging an immunohistochemical reaction with smooth muscle actin, its expression by single smooth muscle cells of the muscular layer was revealed. These myocytes were uniformly light brown or contained light brown granules. In a significant number of the fields of view, the expression of this MCA was not detected (fig. 6).

In cases where the duration of the postmortem period was more than 145 hours, when stained with hematoxylin and eosin, it was impossible to differentiate the muscular and serous layers. The basophilic structures were not determined (fig. 7). Only fibrous structures or dusty masses of light pink were noted. The fibrous structures, totally, looked sharply swollen, with indistinct contours and with the areas of breaks. Small vessels were not visualized, while large vessels were identified due to their rounded or rounded-oval shapes.

The expression of smooth muscle actin was not determined.

DISCUSSION

Autolysis processes that occur after death are a special feature of biological objects to hydrolytically decompose their own molecular and cellular structures. The autolytic process, as is known, is usually divided into several stages depending on the time of death (the stage of initial changes, pronounced changes and the stage of late autolytic changes), each of which is characterized by certain biochemical, biophysical, morphological and immunohistochemical changes [5].

During this study, the features of morphological changes in the mucous, muscular and serous layers of the uterus of elderly women at different periods of the postmortem period were defined for the first time. The authors found that the processes of autolysis in the uterus occur more intensively and faster in the mucous membrane compared to the muscular and serous membranes, which was confirmed by the absence of this membrane during microscopic examination, in cases where the duration of the postmortem period was 97 hours or more.

The study of the morpho-functional features of the endometrium in forensic science and practice allowed examiners to obtain additional information about the age, obstetric and gynecological data and some phenotypic features of the identified personality [6].

In our study, it was noted that in the muscular layer of the uterus, as well as in the walls of the vessels located in all its layers, autolytic changes occurred more intensively in muscle fibers in comparison with connective tissue fibers. This fact, from our point of view, is due to the structural features of the connective tissue (its high density, poor hydrophilicity).

Delayed autolytic changes in connective tissue were noted by a number of scientists when studying the morphological features of the Achilles tendon at various times of the postmortem period [7]. Resistance to postmortem changes in connective tissue and foci of sclerosis was also noted by scientists during a morphological study of the kidneys [8].

Scientists studying postmortem changes in the skeletal muscles of rats during postmortem autolysis showed rapid changes in the properties of actin and myosin, which are known to be proteins constituting the structural basis of myofibrils [9].

Immunohistochemical studies are a useful tool for more accurate, in comparison with other morphological methods, determination of the age of various types of wounds, postmortem interval, etc. [10]. The authors' immunohistochemical study with MCA to smooth muscle actin made it possible to identify myofibroblasts located in all layers of the uterus, as well as to differentiate muscle and connective tissue fibers in the walls of blood vessels and the myometrium.

CONCLUSIONS

1. A comprehensive morphological study of the women uterus revealed a time-dependent increase of postmortem changes in this organ linked with the increase of postmortem period. In cases of postmortem period duration up to 144 hours, the structural elements of the uterine layers were identified. In cases where the duration of the postmortem period was more than 145 hours, microscopically the uterus was represented by eosinophilic fibrous or dusty masses, the histogenesis of which could not be determined. The processes of autolysis occurred more intensely and faster in the mucous membrane of the uterus, in comparison with the muscular and serous membranes, and in the vessels – in their inner membrane, in comparison with the middle and outer membranes. Autolytic changes in the muscular membrane of the uterus and vascular walls occurred more intensely in muscle fibers compared to connective tissue fibers.
2. The histological and immunohistochemical features of the uterus of women at different postmortem periods have a certain forensic medical significance and can be used for establishing the postmortem interval.

The prospect for further research is the development of a computer program for analyzing the color properties of raster images, which will allow, when examining slides, to identify qualitative characteristics and, as a result, to carry out the accurate and correct morphological diagnostics of processes or phenomena, as well as perform a statistical analysis of the data obtained.

REFERENCES

- Mishalov VD, Dunaev OV, Kostenko EYa, Kozlov SV. Perspektivy doslidzhennja biologichnyh ridyn dlja vyznachennja davnosti smerti. Prospects for studying biological fluids to determine the death prescription. Ukrainian Journal of Medicine, Biology and Sport. 2019;4(4/20):218-223. (Ua).
- Kildyushov EM. Modelyrovanye posmertnogo processa teploobmena y opredelenye davnosti nastuplenija smerty. Modeling the postmortem heat transfer process and determining the death prescription. Immanuel Kant Baltic Federal University Vestnik. 2014;7:128-134. (Ru).
- Bachynskiy VT, Ushenko OG, Vanchuliak OY, Sarkisova YV. Zastosuvannja novyh perspektyvnyh tehnologij dlja vyznachennja davnosti nastannja smerti v praktyci sudovo-medychnogo eksperta. Application of perspective new technologies to determine the time of death in practice of forensic medical experts. Clinical and Experimental Pathology. 2017;16(1/59):157-159. (Ua).
- Olkhovskiy VO, Golubovic LL, Tagaev NN et al. Vyznachennja davnosti nastannja smerti. Determing the statute of limitations for death. Kharkiv: FOP Brovin OV, 2017. 168 p. (Ua).
- Byvaltsev VA, Stepanov IA, Semenov AV et al. Vozmozhnosti diagnostiki davnosti nastuplenija smerti po izmenenijam v pojasnichnyh mezhpozvonkovykh diskah (sopostavlenie morfologicheskikh, immunogistohimicheskikh i tomograficheskikh rezultatov). [The possibilities for diagnostics of prescription of death coming based on the changes in the lumbar intervertebral disks (the comparison of the morphological, immunohistochemical and topographical findings).] Forensic Medical Expertise. 2017;4:4-8. (Ru).
- Nedugov HV, Nedugova VV. Issledovanie funkcionalnoj morfologii jendometrija v celjah identifikacii lichnosti. Investigation of the endometrial morphology for the personal identification. Problems of expertise in medicine. 2003;2:18-20. (Ru).
- Povstyanyy V. Dynamika mikroskopichnyh zmin Ahillovogo suhozhyku uprodovzh dvoh tyzhniv pislja nastannja smerti. Dynamics of microscopic changes of the Achilles tendon for two weeks after the death. Forensic examination. 2016;2:38-43. (Ua).
- Kildyushov EM, Ermakova YuV, Tumanov EV, Kuznetsova GS. Diagnostika davnosti nastuplenija smerti v pozdnem posmertnom periode v sudebno-medicinskoj praktike (obzor literatury). Estimation of time since death in the late postmortem period in forensic practice (literature review). Russian Journal of Forensic Medicine. 2018;4(1):34-38. (Ru).
- Nikitina ZK, Abrosimenkova NN, Rebrov LB. Izmeneniya aktina skeletnykh myshc krysa v processe posmertnogo autoliza. Alterations in actin of rat skeletal muscles during postmortem autolysis. Voprosy meditsinskoj khimii. 1990;36(2):65-68. (Ru).
- Fedulova MV, Kupriyanov DD. Dostovernost immunogistohimicheskoy ocenki prizhiznennosti i davnosti povrezhdenij: analiz i perspektivy issledovanij. Reliability of the immunohistochemical estimation of vitality and injury age: analysis and perspectives for study. Forensic Medical Expertise. 2020;63(2):52-57. (Ru).

ORCID and contibutionship:

Vasil O. Olkhovskiy – 0000-0003-2843-2692 ^{A,F}
 Edgar K. Grygorian – 0000-0001-5634-015X ^{A,D}
 Mykhailo S. Myroshnychenko – 0000-0002-6920-8374 ^{D,F}
 Sergii V. Kozlov – 0000-0002-7619-4302 ^{B,E}
 Kostiantyn M. Suloiev – 0000-0002-6841-3632 ^{C,E}
 Anton O. Polianskyi – 0000-0003-3005-8206 ^E
 Petro A. Kaplunovskiy – 0000-0002-8060-7982 ^B
 Yuliia Ya. Fedulenkova – 0000-0001-8599-9500 ^{B,F}
 Iryna V. Borzenkova – 0000-0002-0701-5286 ^{C,D}

Conflict of interest:

The Authors declare no conflict of interest.

CORRESPONDING AUTHOR

Mykhailo S. Myroshnychenko

Pathological Anatomy Department,
 Kharkiv National Medical University,
 Str. Svetlaya 27A, apt. 70, 61129, Kharkiv, Ukraine
 tel: +380501699763, +380961033038
 e-mail: msmartyshnychenko@ukr.net

Received: 08.11.2020

Accepted: 04.03.2021

A – Work concept and design, **B** – Data collection and analysis, **C** – Responsibility for statistical analysis, **D** – Writing the article, **E** – Critical review, **F** – Final approval of the article