

**GUIDELINES FOR STUDENTS 4–6 YEARS
OF MEDICAL FACULTIES
RECOMMENDATIONS FOR TESTING
OF THE LICENSE ISSUE OF KROK-2**

Section "Surgery", explanation

**MINISTRY OF HEALTH OF UKRAINIAN
Kharkiv national medical university
Міністерство охорони здоров'я України
Харківський національний медичний університет**

**GUIDELINES FOR STUDENTS 4–6 YEARS
OF MEDICAL FACULTIES
RECOMMENDATIONS FOR TESTING
OF THE LICENSE ISSUE OF KROK-2**

Section "Surgery", explanation

**МЕТОДИЧНІ ВКАЗІВКИ
ДЛЯ СТУДЕНТІВ 4–6-х КУРСІВ
МЕДИЧНИХ ФАКУЛЬТЕТІВ
ЩОДО РОЗВ'ЯЗАННЯ
ТЕСТОВИХ ЗАВДАНЬ ЛІЦЕНЗІЙНОГО ІСПИТУ
КРОК-2**

Секція "Хірургія", пояснення

Затверджено вченою радою ХНМУ.
Протокол № 4 від 18.04.2019.

**Харків
ХНМУ
2019**

Guidelines for students 4–6 years of medical faculties recommendations for testing of the license issue of KROK-2. Section "Surgery", explanation / comp. I. A. Krivoruchko, O. A. Tonkoglas, S.-K. T. Goni. – Kharkiv : KhNMU, 2019. – 24 p.

Compilers I. A. Kryvoruchko,
O. A. Tonkoglas
S.-K. T. Goni

Методичні вказівки для студентів 4–6-х курсів медичних факультетів щодо розв'язання тестових завдань ліцензійного іспиту КРОК-2. Секція "Хірургія", пояснення / упоряд. I. А. Криворучко, О. А. Тонкоглас, С.-К. Т. Гоні. – Харків : ХНМУ, 2019. – 24 с.

Упорядники I. А. Криворучко
О. А. Тонкоглас
С.-К. Т. Гоні

INTRODUCTION

In the field of studying different methods of control, significant results have been achieved. Scientists have defined the content and tasks of control, in particular test, its functions in the learning process; a classification of control tasks is created, the main requirements for the development of control tasks, the control procedure itself are formulated; analyzed and described features of the organization of control of various types of knowledge; the specifics of control are considered.

The process of monitoring and evaluating students learning activities should be based on the requirements of the principles of systematic, objective, differentiated and individualized student characteristics, transparency, unity of requirements and benevolence.

In accordance with the accepted methodology of the set of examination test, it includes obligatory test assignments from exam booklets of previous years that have the appropriate psychometric characteristics and are anchored.

When preparing for the licensed exam KROK-2, the use of the instructions created aims to help the student correctly choose the correct answer, which will improve the quality of preparation for the KROK-2 licensed exam.

These guidelines were created for students of medical universities of 4–6 courses to prepare for the licensing exam KROK-2. The guidelines included surgical tests that were selected from the KROK-2 booklets for the 2017–2018 academic year.

All test questions contain correct answers with a brief justification and explanation. For each task, a summary has been prepared explaining the terms of the tasks and questions of the KROK-2 licensed exam.

8. 4 days after a patient received a gunshot wound to the soft tissues of middle third of the thigh, his condition suddenly began deteriorating. There are complaints of bursting pain in the wound; pain has been increasing during the last 12 hours. Edema of skin and hypodermic tissue quickly grows. Body temperature is 38,2 °C, heart rate is 102/min. The wound edges gape, are dull in color; the muscles, viable as of day before, now protrude into the wound, look boiled, are dull in color, have dirty-gray coating, and fall apart when held with forceps. What infection has developed in the wound?

A. *Anaerobic**

B. *Aerobic gram-negative*

C. *Putrid*

D. *Aerobic gram-positive*

E. *Diphtheria of the wound*

A. Anaerobic. This infection is particularly relevant to military and trauma surgery. Patients who are immunocompromised, diabetic or have malignant disease are at greater risk, particularly if they have wounds containing necrotic or foreign material, resulting in anaerobic conditions. Military wounds provide an ideal environment as the kinetic energy of high-velocity missiles or shrapnel causes extensive tissue damage. The cavitation which follows passage of a missile through the tissues causes a «sucking» entry wound, leaving clothing and environmental soiling in the wound in addition to devascularised tissue. Anaerobic wound infections are associated with severe local wound pain and crepitus (gas in the tissues, which may also be visible on plain radiographs – gas gangrene). The wound produces a thin, brown, sweet-smelling exudate, in which Gram staining will reveal bacteria. Oedema and spreading gangrene follow the release of collagenase, hyaluronidase, other proteases and alpha toxin. Early systemic complications with circulatory collapse and organ failure follow if prompt action is not taken.

Bailey & Love's short practice of surgery. – 27th edition. – P. 49.

10. A parturient woman complains of pain in her mammary gland. In the painful area there is an infiltration 3×4 cm in size with softened center. Body temperature is $38,5^{\circ}\text{C}$. What is the most likely diagnosis?

- A. *Acute suppurative mastitis**
- B. *Pneumonia*
- C. *Pleurisy*
- D. *Milk retention*
- E. *Birth trauma*

A. Acute suppurative mastitis.

Bacterial mastitis is the most common variety of mastitis and is associated with lactation in the majority of cases. The affected breast, or more usually a segment of it, presents the classical signs of acute inflammation (pain, infiltration, fever). Early on this is a generalised cellulitis but later an abscess will form (softened center is telling about presence of suppuration and formation of abscess).

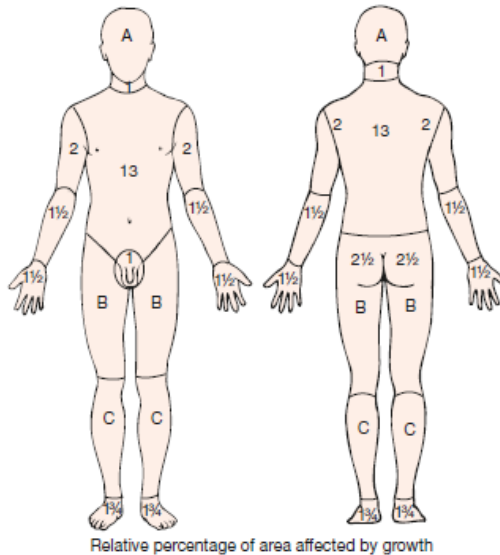
Bailey & Love's short practice of surgery. – 27th edition. – P. 866.

14. A patient received flame burns of both hands. On the dorsal and palmar surface of the hands there are blisters filled with serous fluid. The wrist joint region is hyperemic. The forearms were not injured. What is the provisional diagnosis?

- A. *II degree flame burn of the hands, 4 % of body surface area**
- B. *II degree flame burn of the hands, 2 % of body surface area*
- C. *IIIa degree flame burn of the hands, 4 % of body surface area*
- D. *III degree flame burn of the hands, 4 % of body surface area*
- E. *IIB degree flame burn of the hands, 2 % of body surface area*

A. II degree flame burn of the hands, 4 % of body surface area

Burn size needs to be formally assessed in a controlled environment. This allows the area to be exposed and any soot or debris washed off. Care should be taken not to cause hypothermia during this stage. In the case of smaller burns or patches of burn, the best measurement is to cut a piece of clean paper the size of the patient's whole hand (digits and palm), which represents 1 % TBSA, and match this to the area. Another accurate way of measuring the size of burns is to draw the burn on a Lund and Browder chart, which maps out the percentage TBSA of sections of our anatomy. It also takes into account different proportional body surface area in children according to age. The 'rule of nines', which states that each upper limb is 9 % TBSA, each lower limb 18 %, the torso 18 % each side and the head and neck 9 %, can be used as a rough guide to TBSA outside the hospital environment.



Bailey & Love's short practice of surgery. – 27th edition. – P. 621.

32. A 65-year-old woman on abdominal palpation presents with a tumor in the umbilical region and above it; the tumor is 13×8 cm in size, moderately painful, non-mobile, pulsing. On auscultation systolic murmur can be observed. What is the most likely diagnosis?

- A. Abdominal aneurysm*
 - B. Gastric tumor
 - C. Arteriovenous aneurysm
 - D. Tricuspid insufficiency
 - E. Bicuspid insufficiency
- A.** Abdominal aneurysm

Dilatations of localised segments of the arterial system are called aneurysms when there is a $> 50\%$ increase in the diameter of the vessel; below 50% they are termed ectatic. Abdominal aortic aneurysm (AAA) is by far the most common type of large vessel aneurysm and is found in 2% of the population at autopsy; 95% have associated atheromatous degeneration and 95% occur below the renal arteries. Most remain asymptomatic until rupture occurs; the risk of rupture increases with increasing size (diameter) of the aneurysm. Asymptomatic aneurysms are found incidentally on physical examination (presents of a non-mobile, pulsing tumor in the umbilical region, on auscultation -systolic

murmur), radiography or ultrasound investigation. Symptomatic aneurysms may cause minor symptoms, such as back and abdominal discomfort, before sudden, severe back and/or abdominal pain develops from expansion and rupture. Rarely, symptoms may occur as a result of erosion or compression of surrounding structures, e.g. aortoenteric fistula, ureteric obstruction.

Bailey & Love's short practice of surgery. – 27th edition. – P. 961ю

39. A 45-year-old patient complains of pain in the epigastric region, left subcostal area, abdominal distension, diarrhea, loss of weight. He has been suffering from this condition for 5 years. Objectively: the tongue is moist with white coating near the root; deep palpation of abdomen reveals slight pain in the epigastric region and Mayo-Robson's point. Liver is painless and protrudes by 1 cm from the costal arch. Spleen cannot be palpated. What disease can be primarily suspected?

A. *Chronic pancreatitis**

B. *Atrophic gastritis*

C. *Peptic stomach ulcer*

D. *Chronic cholecystitis*

E. *Chronic enteritis*

A. Chronic pancreatitis

Chronic pancreatitis is a progressive inflammatory disease in which there is irreversible destruction of pancreatic tissue. Its clinical course is characterised by severe pain and, in the later stages, exocrine and endocrine pancreatic insufficiency. In the early stages of its evolution, it is frequently complicated by attacks of acute pancreatitis, which are responsible for the recurrent pain that may be the only clinical symptom.

Pain is the outstanding symptom in the majority of patients. The site of pain depends to some extent on the main focus of the disease. If the disease is mainly in the head of the pancreas, then epigastric and right subcostal pain is common, whereas if it is limited to the left side of the pancreas, left subcostal and back pain are the presenting symptoms. In some patients, the pain is more diffuse. Radiation to the shoulder can occur. The pain is often dull and gnawing. Severe flare-ups of pain may be superimposed on background discomfort. Weight loss is common, because the patient does not feel like eating. The patient's lifestyle is gradually destroyed by pain, analgesic dependence, weight loss and inability to work. Loss of exocrine function leads to steatorrhoea in more than 30 % of patients with chronic pancreatitis.

Bailey & Love's short practice of surgeryю – 27th editionю – P.1230ю

48. A 74-year-old patient was delivered into admission room with clinical presentations of acute deep vein thrombosis of the shin. What symptom is the most typical of this pathology?

- A. Homans' sign*
- B. Rovsing's sign
- C. Courvoisier's sign
- D. Mayo-Robson's sign
- E. Grey Turner's sign

A. Homans's sign is often used in the diagnosis of deep venous thrombosis of the leg. A positive Homans's sign (calf pain at dorsiflexion of the foot) is thought to be associated with the presence of thrombosis.

Clinical examination for DVT is unreliable. Physical signs may also be absent. Mild pitting oedema of the ankle, dilated surface veins, a stiff calf and tenderness over the course of the deep veins should be sought. Leg pain occurs in about 50 % of patients with DVT but is nonspecific. Homans' sign – resistance (not pain) of the calf muscles to forcible dorsiflexion – is not specific and should not be elicited. Tenderness occurs in 75 % of patients but is also found in 50 % of patients without objectively confirmed DVT. The pain and tenderness associated with DVT does not usually correlate with the size, location or extent of the thrombus.

Bailey & Love's short practice of surgery. – 27th edition. – P. 988.

57. A 17-year-old young man complains of general weakness, trismus, twitching of the muscles in his left shin. 7 days ago he pierced his foot with a nail. Objectively: at the sole of the foot there is a wound, 0,3 × 0,2 mm in size, with small amount of serous-purulent discharge, the skin around the wound is hyperemic. What is the most likely diagnosis?

- A. Tetanus*
- B. Phlegmon
- C. Osteomyelitis
- D. Infected wound
- E. Erysipelas

A. Tetanus

Tetanus usually follows a recognized injury. Contamination of wounds with soil, manure, or rusty metal can lead to tetanus. It can complicate burns, ulcers, gangrene, necrotic snakebites, middle ear infections, septic abortions, childbirth, intramuscular injections, and surgery.

There is a clinical triad of rigidity, muscle spasms and, if severe, autonomic dysfunction. Neck stiffness, sore throat, and difficulty opening the mouth are often early symptoms.

Masseter spasm causes trismus or «lockjaw». Spasm progressively extends to the facial muscles causing the typical facial expression, 'risus sardonicus', and muscles of swallowing causing dysphagia. Rigidity of the neck muscles leads to retraction of the head. Truncal rigidity may lead to opisthotonus and respiratory difficulty with decreased chest wall compliance.

In addition to increased muscle tone, there are episodic muscular spasms. These tonic contractions have a convulsion-like appearance affecting agonist and antagonist muscle groups together. They may be spontaneous or triggered by touch, visual, auditory, or emotional stimuli.

In the commonest form of tetanus, generalized tetanus, muscles throughout the body are affected.

With lower toxin loads and peripheral injuries local tetanus is seen. Spasm and rigidity are restricted to a limited area of the body.

The entry wound may show a localised small area of cellulitis. Exudate or aspirate may give a sample that can be stained to show the presence of gram-positive rods.

Cook T. M. Tetanus: A review of the literature. / T. M. Cook, R. T. Protheroe, J. M. Handel // Br J Anaesth. – 2001. – Vol. 87. – P. 477–87.

59. A 58-year-old patient complains of pain in the lower left extremity, which aggravates during walking, sensation of cold and numbness in the both feet. The patient has been suffering from this condition for 6 years. Objectively: the skin is pale and dry, with hyperkeratosis. On the left shin hair is scarce, "furo" symptom of inflamed inguinal lymph nodes is positive. Pulse cannot be detected over the pedal and popliteal arteries and is weakened over the femoral artery. In the right limb popliteal artery pulsation is retained. What is the most likely diagnosis?

A. *Arteriosclerosis obliterans of the lower extremities**

B. *Obliterating endarteritis*

C. *Femoral artery thrombosis*

D. *Raynaud's disease*

E. *Buerger's disease (thromboangiitis obliterans)*

A. *Arteriosclerosis obliterans of the lower extremities*

Intermittent claudication occurs as a result of anaerobic muscle metabolism and is classically described as debilitating cramp-like pain felt in the muscles that is:

- reliably brought on by walking;
- not present on taking the first step (unlike osteoarthritis);
- reliably relieved by rest both in the standing and sitting positions; usually within 5 min.

As disease progression occurs the claudication distance decreases and perfusion to the leg may be so severely compromised that anaerobic respiration

occurs even at rest, typically affecting the foot and/or calf. The pain is exacerbated by lying down or elevation of the foot due to loss of the gravitational effects on perfusion pressure in the foot. The patient characteristically describes pain that is worse at night and may be lessened by hanging the foot out of bed or by sleeping in a chair (effects of gravity restored). Chronically ischaemic limb tends to equilibrate with the temperature of its surroundings and may feel quite warm under the bedclothes. Chronic ischaemia does not produce paralysis and sensation is usually intact. Elevation of the limb reveals the severity of the ischaemia, with venous guttering and foot pallor that changes to a red/purple colour when the limb is allowed to hang down again (dependent rubor or the sunset foot sign). Diminution of a femoral and/or popliteal pulse can often be appreciated by comparing it with its opposite number; however, pedal pulses are either clinically palpable or absent. Pulsation distal to an arterial occlusion is usually absent.

Bailey & Love's short practice of surgery. –27th edition. – P. 943.

68. A 20-year-old woman on the 10th day after her discharge from the maternity ward developed fever up to 39 °C and pain in her left mammary gland. On examination the mammary gland is enlarged, in its upper outer quadrant there is a hyperemic area. In this area a dense spot with blurred margins can be palpated. The patient presents with lactostasis and no fluctuation. Lymph nodes in the right axillary crease are enlarged and painful. Specify the correct diagnosis:

- A. *Lactational mastitis**
- B. *Abscess*
- C. *Erysipelas*
- D. *Dermatitis*
- E. *Tumor*

A. Lactational mastitis is seen far less frequently than in former years. Most are caused by *S. aureus* and, if hospital acquired, are likely to be penicillin resistant. The intermediary is usually the infant; after the second day of life, 50 % of infants harbour staphylococci in the nasopharynx. Although ascending infection from a sore and cracked nipple may initiate the mastitis, in many cases the lactiferous ducts will first become blocked by epithelial debris leading to stasis; this theory is supported by the relatively high incidence of mastitis in women with a retracted nipple. Once within the ampulla of the duct, staphylococci cause clotting of milk and, within this clot, organisms multiply.

The affected breast, or more usually a segment of it, presents the classical signs of acute inflammation (high fever, pain, sharply painful infiltrate, the skin over the infiltrate is red, subareolar area and nipple are swollen and painful). Early on this is a generalised cellulitis but later an abscess will form.

Bailey & Love's short practice of surgery. – 27th edition. – P. 866.

76. A patient has the second and third degree burns of the 15 % of the body surface. On the 20th day after the trauma the patient presents with sharp increase of body temperature, general weakness, rapid vesicular respiration; facial features are sharpened, BP is 90/50 mm Hg, heart rate is 112/min. What complication is it?

- A. Sepsis*
- B. Pneumonia
- C. Acute intoxication
- D. Purulent bronchitis
- E. Anaerobic infection

A. Sepsis

The inflammatory changes caused by the burn have an effect on the patient's immune system. Cell-mediated immunity is significantly reduced in large burns, leaving them more susceptible to bacterial and fungal infections. There are many potential sources of infection, especially from the burn wound and from the lung if this is injured, but also from any central venous lines, tracheostomies or urinary catheters present.

Control of infection begins with policies on hand-washing and other cross-contamination prevention measures. Bacteriological surveillance of the wound, catheter tips and sputum helps to build a picture of the patient's flora. If there are signs of infection, then further cultures need to be taken and antibiotics started. This is often initially on a best guess basis, hence the usefulness of prior surveillance; close liaison with a bacteriologist is essential. In patients with large burns that remain catabolic, the core temperature is usually reset by the hypothalamus above 37 °C. Significant temperatures are those above 38.5°C, but often other signs of infection are more useful to the clinician. These include significant rise or fall in the white cell count, thrombocytosis, increasing signs of catabolism and decreasing clinical status of the patient.

Infection control in burns patients

- Burns patients are immunocompromised
- They are susceptible to infection from many routes
- Sterile precautions must be rigorous
- Swabs should be taken regularly
- A rise in white blood cell count, thrombocytosis and increased catabolism are warnings of infection

Bailey & Love's short practice of surgery. – 27th edition. – P. 619.

81. Two days ago a woman fell from the height of 1,5 m. She complains of severe thoracic pain on the left and dyspnea. Chest X-ray reveals hydropneumothorax on the left with fluid level at the 7th rib and the lung collapsed by 1/3. The 6th-7th ribs are fractured along the scapular line. Serohemorrhagic fluid was obtained during thoracic puncture. What treatment tactics should be chosen?

- A. *Thoracocentesis on the left at the 7th intercostal space**
- B. *Thoracocentesis at the 2nd intercostal space*
- C. *Repeated puncture of the pleural cavity*
- D. *Intubation of trachea with artificial pulmonary ventilation*
- E. *Alcohol-novocaine block of the fracture area*

A. The most common cause of massive haemothorax in blunt injury is continuing bleeding from torn intercostal vessels or occasionally from the internal mammary artery secondary to fractures of the ribs. Accumulation of blood in a haemothorax can significantly compromise respiratory efforts, compressing the lung and preventing adequate ventilation.

Presentation is with haemorrhagic shock, flat neck veins, unilateral absence of breath sounds and dullness to percussion.

The initial treatment consists of correcting the hypovolaemic shock, insertion of an intercostal drain (the 7th intercostal space) and, in some cases, intubation.

Initial drainage of more than 1 500 mL of blood or ongoing haemorrhage of more than 200 mL/h over 3–4 hours is generally considered an indication for urgent thoracotomy. Blood in the pleural space should be removed as completely and rapidly as possible to prevent ongoing bleeding, an empyema or fibrothorax later. Clamping a chest drain to tamponade a massive haemothorax is not helpful.

Bailey & Love's short practice of surgery. – 27th edition. – P. 368.

86. A 46-year-old woman has been hospitalized with open fracture of the left thigh in its middle third. She underwent the surgery – fixation with extraosseous osteosynthesis plates. On the 4th day after the surgery she developed pain in the wound, body temperature rose over 39 °C. What measures should be taken in this case?

- A. *Undo the sutures, drain the wound, and prescribe antibiotics**
- B. *Prescribe broad spectrum antibiotics and hormonal agents*
- C. *Administer antibiotics intraosseously and hypothermia locally*
- D. *Inject antibiotics into the area surrounding the wound, prescribe spasmolytics and analgesics*
- E. *Remove the fixation, prescribe sulfanilamides*

A. Surgical site infection (SSI)

A major SSI is defined as a wound that either discharges significant quantities of pus spontaneously or needs a secondary procedure to drain it. The

patient may have systemic signs such as tachycardia, pyrexia and a raised white cell count. Minor wound infections may discharge pus or infected serous fluid but are not associated with excessive discomfort, systemic signs or delay in return home. The differentiation between major and minor and the definition of SSI is important in audits and clinical trials of antibiotic prophylaxis.

If an infected wound is under tension, or there is clear evidence of suppuration, sutures or clips need to be removed, with curettage if necessary, to allow pus to drain adequately. In severely contaminated wounds, such as an incision made for drainage of an abscess, it is logical to leave the skin open. Delayed primary or secondary closure can be undertaken when the wound is clean and granulating.

Some heavily infected wounds may be left to heal by secondary intention, with no attempt at closure, particularly where there is a loss of skin cover and healthy granulation tissue develops. While the end result may be excessive scarring, that can always be revised with plastic surgery under clean surgical conditions at a later stage.

Risk factors for increased risk of wound infection

- Malnutrition (obesity, weight loss)
- Metabolic disease (diabetes, uraemia, jaundice)
- Immunosuppression (cancer, AIDS, steroids, chemotherapy and radiotherapy)
- Colonisation and translocation in the gastrointestinal tract
- Poor perfusion (systemic shock or local ischaemia)
- Foreign body material
- Poor surgical technique (dead space, haematoma)

Bailey & Love's short practice of surgery. – 27th edition. – P. 42.

90. After excessive consumption of fatty food a 60-year-old woman suddenly developed pain in her right subcostal area, nausea, bile vomiting, sharp bitter taste in her mouth. In 2 days she developed jaundice, her urine darkened. Objectively: sclera and skin are icteric, the abdomen is distended, the liver is enlarged by 3 cm, soft and painful on palpation, Ortner's, Murphy's, Kehr's, Zakharyin's, Mayo-Robson's signs are positive. What diagnostic technique should be used in the first place?

- A. US of the gallbladder and bile duct*
- B. Fibrogastroduodenoscopy
- C. X-ray of the abdomen
- D. Radionuclide scanning of the liver and gallbladder
- E. Laparoscopy

A. A diagnosis of gallstone disease is based on the history and physical examination with confirmatory radiological studies such as transabdominal ultrasonography and radionuclide scans.

In the acute phase, the patient may have right upper quadrant tenderness that is exacerbated during inspiration by the examiner's right subcostal palpation (Murphy's sign). A positive Murphy's sign suggests acute inflammation and may be associated with a leucocytosis and moderately elevated liver function tests. A mass may be palpable as the omentum walls off an inflamed gall bladder. Fortunately, in the majority of cases, this process is limited by the stone slipping back into the body of the gall bladder and the contents of the gall bladder escaping by way of the cystic duct. This achieves adequate drainage of the gall bladder and enables the inflammation to resolve. If resolution does not occur, an empyema of the gall bladder may result. The wall may become necrotic and perforate, with the development of localised peritonitis. The abscess may then perforate into the peritoneal cavity with a septic peritonitis – however, this is uncommon, because the gall bladder is usually localised by omentum around the perforation.

A palpable, non-tender gall bladder (Courvoisier's sign) portends a more sinister diagnosis. This usually results from a distal common duct obstruction secondary to a peripancreatic malignancy. Rarely, a non-tender, palpable gall bladder results from complete obstruction of the cystic duct with reabsorption of the intraluminal bile salts and secretion of uninfected mucus secreted by the gall bladder epithelium, leading to a mucocele of the gall bladder.

Bailey & Love's short practice of surgery. – 25th edition. – P. 1121.

95. A 57-year-old woman complains of a sensation of esophageal compression, palpitations, difficult breathing when eating solid food, occasional vomiting with a full mouth, "wet pillow" sign at night for the last 6 months. Objectively: body temperature – 39 °C, height – 168 cm, weight – 72 kg, Ps – 76/min, BP – 120/80 mm Hg. X-ray study revealed considerable dilation of esophagus and its constriction in the cardial part. What pathology is the most likely to have caused dysphagia in this patient?

- A. *Achalasia cardiae**
- B. *Primary esophageal spasm*
- C. *Hiatal hernia*
- D. *Esophageal carcinoma*
- E. *Reflux esophagitis*

A. *Achalasia cardiae*

The physiological abnormalities are a non-relaxing LOS and absent peristalsis in the body of the oesophagus. In its earliest stages, the oesophagus is of normal calibre and still exhibits contractile (although non-peristaltic) activity. In some patients, these uncoordinated contractions result in pain as much as a sense

of food sticking. With time, the oesophagus dilates and contractions disappear, so that the oesophagus empties mainly by the hydrostatic pressure of its contents. This is nearly always incomplete, leaving residual food and fluid. The gas bubble in the stomach is frequently absent, as no bolus with its accompanying normal gas passes through the sphincter. The 'megaesophagus' becomes tortuous with a persistent retention oesophagitis due to fermentation of food residues and this may account for the increased incidence of carcinoma of the oesophagus.

The disease is most common in middle life, but can occur at any age. It typically presents with dysphagia, although pain (often mistaken for reflux) is common in the early stages. Patients often present late and, having had relatively mild symptoms, remain untreated for many years. Regurgitation is frequent, and there may be overspill into the trachea, especially at night.

Diagnosis

Achalasia may be suspected at endoscopy by finding a tight cardia and food residue in the oesophagus. Barium radiology may show hold-up in the distal oesophagus, abnormal contractions in the oesophageal body and a tapering stricture in the distal oesophagus, often described as a 'bird's beak'. The gastric gas bubble is usually absent. These typical features of welldeveloped achalasia are often absent, and endoscopy and radiology can be normal. A firm diagnosis is established by oesophageal manometry. Classically, the LOS does not relax completely on swallowing, there is no peristalsis and there is a raised resting pressure in the oesophagus. The LOS pressure may be elevated, but is often normal.

Bailey & Love's short practice of surgery. – 25th edition. – P. 1035.

99. A 42-year-old man was delivered to a surgical in-patient department with complaints of icteric skin, pain in the right subcostal area. Biochemical blood analysis: total bilirubin – 140 $\mu\text{mol/l}$, direct bilirubin – 112 $\mu\text{mol/l}$. On US: choledoch duct – 1,4 cm, a concrement is detected in the distal area. Gallbladder is 40 cm, no concrements. What treatment tactics should be chosen?

- A. *Endoscopic papillosphincterotomy* *
- B. *Laparoscopic cholecystectomy*
- C. *Laparotomy with choledoch duct drain*
- D. *Laparotomy with cholecystectomy*
- E. *Treatment in an infectious diseases hospital*

A. Patient has a choledocholithiasis. ERCP and endoscopic sphincterotomy are treatment of choice at most centers

- Successful clearance of BD in more than 90 % of patients
- Definitive treatment of BD stones in postcholecystectomy patients

- Most common treatment of BD stones when laparoscopic cholecystectomy is planned and BD stones are documented or strongly suspected

- Permits leaving gallbladder intact after ERCP in patients at high risk for surgery; need for subsequent cholecystectomy is 10 to 20 % within 5 to 10 years.

Jacobson Ira M. *Weine Handbook of Liver Disease* / Ira M. Jacobson, Douglas M. Weine. –Third Edition. – 2012.

101. A patient with chronic pancreatitis complains of diarrhea occurring up to 5 times per day (no blood traces), loss of body weight, abdominal distention, dryness of skin, loss of hair, thirst, bleeding gums, convulsions. Complete blood count: leukocytes – $5,8 \cdot 10^9/l$; Hb – 86 g/l; ESR – 15 mm/g; Blood protein test: protein – 48 g/l; albumins – 28 g/l. What indicators of coprological analysis would accompany this syndrom?

A. *Steatorrhea, creatorrhea**

B. *Large amount of mucus, amyloorrhea*

C. *Large amount of starch grains and cellulose*

D. *Gas bubbles, acid reaction*

E. *Large numbers of iodophilous microbes*

A. Chronic pancreatitis

Chronic pancreatitis is a progressive inflammatory disease in which there is irreversible destruction of pancreatic tissue. Its clinical course is characterised by severe pain and, in the later stages, exocrine and endocrine pancreatic insufficiency. In the early stages of its evolution, it is frequently complicated by attacks of acute pancreatitis, which are responsible for the recurrent pain that may be the only clinical symptom.

Pain is the outstanding symptom in the majority of patients. The site of pain depends to some extent on the main focus of the disease. If the disease is mainly in the head of the pancreas, then epigastric and right subcostal pain is common, whereas if it is limited to the left side of the pancreas, left subcostal and back pain are the presenting symptoms. In some patients, the pain is more diffuse. Radiation to the shoulder can occur. The pain is often dull and gnawing. Severe flare-ups of pain may be superimposed on background discomfort. Weight loss is common, because the patient does not feel like eating. The patient's lifestyle is gradually destroyed by pain, analgesic dependence, weight loss and inability to work. Loss of exocrine function leads to steatorrhoea in more than 30% of patients with chronic pancreatitis.

Bailey & Love's short practice of surgery . –27th edition. – P.1230.

134. A 53-year-old woman complains of weight loss up to 10 kg within the last 2 years, liquid foulsmelling stool two times a day that poorly washes off the toilet, periodic bouts of nausea, girdle pain in the upper abdomen. Objectively: pain in Gubergrits zone (on the right from navel) and at Mayo-Robson's point. Biochemical blood analysis: glucose – 3,2 mmol/l, bilirubin – 16,5 mcmol/l, crude protein – 56,4 g/l. Urine diastase/amylase – 426 g/h/l. D-xylose test (oral administration of 25 g of d-xylose) after 5 hours reveals 3 g of xylose in urine. The most likely diagnosis is:

- A. *Pancreatitis. Malabsorption syndrome**
- B. *Pseudomembranous colitis*
- C. *Nonspecific ulcerative colitis*
- D. *Irritable bowel syndrome*
- E. *Chronic gastritis*

A. Chronic pancreatitis

Pain is the outstanding symptom in the majority of patients. The site of pain depends to some extent on the main focus of the disease. If the disease is mainly in the head of the pancreas, then epigastric and right subcostal pain is common, whereas if it is limited to the left side of the pancreas, left subcostal and back pain are the presenting symptoms. In some patients, the pain is more diffuse. Radiation to the shoulder can occur. The pain is often dull and gnawing. Severe flare-ups of pain may be superimposed on background discomfort. Weight loss is common, because the patient does not feel like eating. The patient's lifestyle is gradually destroyed by pain, analgesic dependence, weight loss and inability to work. Loss of exocrine function leads to steatorrhoea (liquid foulsmelling stool, that poorly washes off the toilet) in more than 30% of patients with chronic pancreatitis. Loss of endocrine function and the development of diabetes are not uncommon, and the incidence increases as the disease progresses.

Bailey & Love's short practice of surgery. – 27th edition. – P. 1230.

136. A 64-year-old patient has been hospitalized with complaints of progressive jaundice that developed over 3 weeks without pain syndrome and is accompanied by general weakness and loss of appetite. Objectively: temperature is 36,8 °C, heart rate is 78/min, abdomen is soft and painless, peritoneum irritation symptoms are not detected, palpation reveals sharply enlarged tense gallbladder. What disease can be characterised by these symptoms?

- A. *Cancer of pancreas head**
- B. *Duodenal ulcer*
- C. *Acute cholecystitis*
- D. *Chronic cholecystitis*
- E. *Cholecystitis caused by lamblia*

A. Courvoisier's sign (or law) describes an enlarged, palpable gallbladder in patients with obstructive jaundice caused by tumors of the biliary tree or by pancreatic head tumors. This kind of biliary obstruction evolves slowly. The gall bladder will be dilated, with a thin wall; it is not tender to the touch. By contrast, acute cholecystitis due to obstruction by stone(s) is a quick process that causes a dilated gall bladder that is tender to the touch (Murphy's sign). The inflammation of chronic cholelithiasis results in a shrunken, fibrotic gallbladder.

Couvoisier's sign can be found in patients with:

- biliary tumor (cholangiocarcinoma);
- periampulary carcinoma (adenocarcinoma of Vater papilla or duodenum);
- pancreatic head cancer;
- lymph node metastasis in the porta hepatis.

Harrison's principles of Internal Medicine / KASPER, Dennis L – FAUCI, Anthony S – LONGO, Dan L. et al. – 16th edition. – New York : McGraw-Hill Companies, Inc., 2005. – 2607 p. – P. 537.

140. A 19-year-old woman complains of severe pain in the axillary crease. Condition onset occurred a week ago after her swimming in a cold river and epilation. The next day a painful "boil" appeared. The "boil" was increasing in size every day and became a plum-sized tumor. Upon examination there are nodular conical growths joined together detected, the skin covering them is bluish-red in color. Some nodules have fistulous openings producing thick purulent mass. Body temperature is 38,5 °C, general malaise. What is the most likely diagnosis?

*A. Hydradenitis**

B. Carbuncle

C. Cutaneous tuberculosis

D. Necrotizing ulcerative trichophytosis

E. Pyoderma chancreiformis

A. Hydradenitis is a follicular occlusion followed by folliculitis and secondary infection with skin flora (usually *Staphylococcus aureus* and *Propionibacterium acnes*) culminates in chronic suppurative, painful, skin abscesses, sinus tracts and scarring. HS occurs in skin containing apocrine glands, commonly in the axillae and groins; but also the scalp, breast, chest and perineum. It appears to have a genetic predisposition with variable penetrance, and is strongly associated with obesity and smoking. It affects four women for every man.

Bailey & Love's short practice of surgery. – 27th edition. – P. 595.

143. A 54-year-old patient complains of weakness, jaundice, itching skin. Disease onset was 1,5 months ago: fever up to 39 °C appeared at first, with progressive jaundice developed 2 weeks later. On hospitalization jaundice was severely progressed. Liver cannot be palpated. Gallbladder is enlarged and painless. Blood bilirubin is 190 mcmol/l (accounting for direct bilirubin). Stool is acholic. What is the most likely jaundice genesis in this patient?

- A. *Mechanical jaundice**
- B. *Hepatocellular jaundice*
- C. *Hemolytic jaundice*
- D. *Caroli syndrome*
- E. *Gilbert's syndrome*

A. Courvoisier's sign (or law) describes an enlarged, palpable gallbladder in patients with obstructive jaundice caused by tumors of the biliary tree or by pancreatic head tumors. This kind of biliary obstruction evolves slowly. The gall bladder will be dilated, with a thin wall; it is not tender to the touch. By contrast, acute cholecystitis due to obstruction by stone(s) is a quick process that causes a dilated gall bladder that is tender to the touch (Murphy's sign). The inflammation of chronic cholelithiasis results in a shrunken, fibrotic gallbladder.

Couvoisier's sign can be found in patients with:

- biliary tumor (cholangiocarcinoma);
- periampulary carcinoma (adenocarcinoma of Vater papilla or duodenum);
- pancreatic head cancer;
- lymph node metastasis in the porta hepatis.

Harrison's principles of Internal Medicine / KASPER, Dennis L – FAUCI, Anthony S – LONGO, Dan L. et al. – 16th edition. – New York : McGraw-Hill Companies, Inc., 2005. – 2607 p. – P. 537.

156. A 25-year-old woman has a self-detected tumor in the upper outer quadrant of her right breast. On palpation there is a painless firm mobile lump up to 2 cm in diameter, peripheral lymph nodes are without alterations. In the upper outer quadrant of the right breast ultrasound revealed a massive neoplasm with increased echogenicity sized 21 × 18 mm. What is the most likely diagnosis?

- A. *Fibroadenoma**
- B. *Lactocele*
- C. *Diffuse mastopathy*
- D. *Mammary cancer*
- E. *Mastitis*

A. Fibroadenomas usually arise in the fully developed breast between the ages of 15 and 25 years, although occasionally they occur in much older women. They arise from hyperplasia of a single lobule and usually grow up to 2–3 cm in size. They are surrounded by a well-marked capsule and can thus be enucleated through a cosmetically appropriate incision. A fibroadenoma does not require excision unless associated with suspicious cytology, it becomes very large or the patient expressly desires the lump to be removed. Even if clinically obvious, a biopsy should be obtained if the patient is over 25 or there are any atypical features on ultrasound.

Bailey & Love's short practice of surgery. – 27th edition. – P. 870.

162. After significant physical exertion a 66-year-old man with deep vein thrombosis of the extremities developed shortness of breath, intense pain in the chest on the left, marked palpitations. The patient's condition is grave, his face is cyanotic, the cervical veins are swollen, BP is 60/40 mm Hg. What investigation method would be the most advisable in this case?

- A. *Selective angiopneumography**
- B. *Chest X-ray*
- C. *Echocardiography*
- D. *Magnetic resonance imaging of the chest*
- E. *Fiber-optic bronchoscopy*

A. Selective angiopneumography

The most common presentation of a DVT is pain and swelling, especially in the calf, usually in one leg. Pulmonary embolism (according to the clinical signs and anamnesis – patient with deep vein thrombosis of the extremities developed shortness of breath, intense pain in the chest on the left, marked palpitations. The patient's condition is grave, his face is cyanotic, the cervical veins are swollen, BP is 60/40 mm Hg). The diagnosis of DVT and pulmonary embolus should be established by special investigations as the symptoms and signs are non-specific and may be absent. In addition, treatment with anticoagulation is not without risk and the diagnosis must be made with reasonable certainty. Venous duplex ultrasound is commonly performed to look for evidence of thrombosis throughout the deep or superficial venous system. Pulmonary embolus is diagnosed definitively by computed tomography (CT) pulmonary angiogram, which will demonstrate the presence of filling defects in the pulmonary arteries. Pulmonary angiography is rarely required unless thrombolysis is being considered.

Bailey & Love's short practice of surgery. – 27th edition. – P. 986.

166. A 24-year-old patient had been delivered to a thoracic department with a chest injury, fracture of the IV, V VI ribs on the right. Plan radiography showed the fluid level in the pleural cavity to be reaching the III rib on the right. Puncture contained blood clots. What is the optimal treatment tactics?

- A. *Emergency thoracotomy**
- B. *Pleural puncture*
- C. *Thoracentesis and thoracostomy*
- D. *Hemostatic therapy*
- E. *Medical thoracoscopy*

A. Emergency thoracotomy is indicated as a treatment of haemothorax.

The most common cause of massive haemothorax in blunt injury is continuing bleeding from torn intercostal vessels or occasionally from the internal mammary artery secondary to fractures of the ribs. In penetrating injury, a variety of viscera, both thoracic and abdominal (with blood leaking through a hole in the diaphragm from the positive pressure abdomen into the negative pressure thorax) may be involved. Accumulation of blood in a haemothorax can significantly compromise respiratory efforts, compressing the lung and preventing adequate ventilation. Presentation is with haemorrhagic shock, flat neck veins, unilateral absence of breath sounds and dullness to percussion. The initial treatment consists of correcting the hypovolaemic shock, insertion of an intercostal drain and, in some cases, intubation. Initial drainage of more than 1 500 mL of blood or ongoing haemorrhage of more than 200 mL/h over 3–4 hours is generally considered an indication for urgent thoracotomy. Blood in the pleural space should be removed as completely and rapidly as possible to prevent ongoing bleeding, an empyema or fibrothorax later. Clamping a chest drain to tamponade a massive haemothorax is not helpful.

Bailey & Love's short practice of surgery. – 27th edition. – P. 368.

186. A 28-year-old woman complains of girdle pain in her epigastric and left subcostal areas with irradiation to the back, nausea, and vomiting without relief. On examination a surgeon observes stomach distension and meteorism. There are positive Mondor's, Mayo-Robson's, and Cullen's symptoms. What is the most likely diagnosis?

- A. *Acute pancreatitis **
- B. *Acute cholecystitis*
- C. *Acute intestinal obstruction*
- D. *Aortic dissecting aneurysm*
- E. *Splenic infarction*

A. Acute pancreatitis clinical presentation pain is the cardinal symptom. It characteristically develops quickly, reaching maximum intensity within minutes rather than hours and persists for hours or even days. The pain is frequently severe, constant and refractory to the usual doses of analgesics. Pain is usually experienced first in the epigastrium but may be localised to either upper quadrant or felt diffusely throughout the abdomen. There is radiation to the back in about 50 % of patients, and some patients may gain relief by sitting or leaning forwards. Nausea, repeated vomiting and retching are usually marked accompaniments. On examination, the appearance may be that of a patient who is well or, at the other extreme, one who is gravely ill with profound shock, toxicity and confusion. Bleeding into the fascial planes can produce bluish discolouration of the flanks (Grey Turner's sign) or umbilicus (Cullen's sign). Abdominal examination may reveal distension due to ileus or, more rarely, ascites with shifting dullness. A mass can develop in the epigastrium due to inflammation. There is usually muscle guarding in the upper abdomen, although marked rigidity is unusual.

Bailey & Love's short practice of surgery. – 27th edition. – P. 1222.

191. A woman complains of frequent, liquid stool (up to 9–10 times per day) with mucus and blood admixtures, dull pain in the hypogastrium, weight loss of 4 kg within the last year. Objectively: malnutrition, dry skin, low turgor, aphthous stomatitis. The stomach is soft, the sigmoid colon is spastic and painful on palpation. Occult blood test is positive. Fibrocolonoscopy: edema, hyperemia, mucosal granulation, pseudopolyps, small ulcers with irregular edges. Make the diagnosis:

- A. *Nonspecific ulcerative colitis**
- B. *Chronic enterocolitis*
- C. *Colon cancer*
- D. *Irritable bowel syndrome*
- E. *Crohn's disease (regional enteritis)*

A. Nonspecific ulcerative colitis.

UC is a disease of the rectum and colon with extraintestinal manifestations (arthritis, sclerosing cholangitis, skin lesions – erythema nodosum and pyoderma gangrenosum, uveitis and episcleritis, aphthous stomatitis). Colonic inflammation is diffuse, confluent and superficial, primarily affecting the mucosa and superficial submucosa. Severe disease corresponds to more than six bloody stools a day and evidence of systemic illness, with fever, tachycardia, anaemia and raised inflammatory markers. Hypoalbuminaemia is common and an ominous finding.

Bailey & Love's short practice of surgery. – 27th edition. – P. 1267.

193. On the 9th day after childbirth the obstetric patient developed high fever up to 38 °C. She complains of pain in the right mammary gland. On examination a sharply painful infiltrate can be palpated in the right mammary gland, the skin over the infiltrate is red, subareolar area and nipple are swollen and painful. What is your diagnosis?

- A. *Abscess of the right mammary gland**
- B. *Mastopathy*
- C. *Cancer of the right mammary gland*
- D. *Serous mastitis*
- E. *Fibrous cystic degeneration of the right mammary gland*

A. Abscess of the right mammary gland. Lactational mastitis is seen far less frequently than in former years. Most are caused by *S. aureus* and, if hospital acquired, are likely to be penicillin resistant. The intermediary is usually the infant; after the second day of life, 50% of infants harbour staphylococci in the nasopharynx. Although ascending infection from a sore and cracked nipple may initiate the mastitis, in many cases the lactiferous ducts will first become blocked by epithelial debris leading to stasis; this theory is supported by the relatively high incidence of mastitis in women with a retracted nipple. Once within the ampulla of the duct, staphylococci cause clotting of milk and, within this clot, organisms multiply.

The affected breast, or more usually a segment of it, presents the classical signs of acute inflammation (high fever, pain, sharply painful infiltrate, the skin over the infiltrate is red, subareolar area and nipple are swollen and painful). Early on this is a generalised cellulitis but later an abscess will form.

Bailey & Love's short practice of surgery. – 27th edition. – P. 866.

Навчальне видання

**МЕТОДИЧНІ ВКАЗІВКИ
ДЛЯ СТУДЕНТІВ 4–6-х КУРСІВ
МЕДИЧНИХ ФАКУЛЬТЕТІВ
ЩОДО РОЗВ'ЯЗАННЯ
ТЕСТОВИХ ЗАВДАНЬ ЛІЦЕНЗІЙНОГО ІСПИТУ
КРОК-2**

Секція "Хірургія", пояснення

Упорядники Криворучко Ігор Андрійович
 Тонкоглас Олександр Аркадійович
 Гоні Самха-Катерина Тахірівна

Відповідальний за випуск С.-К.Т.Гоні



Комп'ютерна верстка О. Ю Лавриненко

Формат А5. Ум. друк. арк.1,5. Зам. № 19-33784.

**Редакційно-видавничий відділ
ХНМУ, пр. Науки, 4, м. Харків, 61022
izdatknmurio@gmail.com**

Свідоцтво про внесення суб'єкта видавничої справи до Державного реєстру видавництв, виготовників і розповсюджувачів видавничої продукції серії ДК № 3242 від 18.07.2008 р.