MORPHOLOGIA



ISSN 1997-9665

2018 • Том 12 • Номер 3 2018 • Volume 12 • Number 3

ISSN 1997-9665

MORPHOLOGIA

2018 • Том 12 • Номер 3

Науковий фаховий електронний журнал Всеукраїнської громадської організації „Наукове товариство анатомів, гістологів, ембріологів і топографоанатомів України"
Періодичність видання – 4 рази на рік
Засновники:
ВГО «Наукове товариство анатомів, гістологів, ембріологів і топографоанатомів України»
ДЗ «Дніпропетровська медична академія Міністерства охорони здоров'я України»

Індексація журналу:
«NLM Catalog – US National Library of Medicine» (http://www.ncbi.nlm.nih.gov/nlmcatalog)
«Medical Journals Links» (http://www.medical-journals-links.com)
«CiteFactor Academic Scientific Journals» (http://www.citefactor.org)
Міжнародна наукометрична база «Російський індекс наукового цитування» (http://elibrary.ru)
Поточний імпакт-фактор – 0,170

Атестований як періодичне електронне наукове видання в галузі медичних наук і включений до **Переліку наукових фахових видань України**, в яких можуть публікуватися основні результати дисертаційних робіт (Наказ Міністерства освіти і науки України від 10.10.2013 р. № 1411).

Свідоцтво про державну реєстрацію № 26 від 25.04.2014 р.

Оглядові, проблемні й оригінальні статті рецензуються. Журнал публікує наукові роботи морфологів, а також результати морфологічних досліджень фахівців інших спеціальностей.

Видається і рекомендується для вільного поширення мережею Internet згідно з рішенням вченої ради ДЗ «Дніпропетровська медична академія МОЗ України» (протокол № 3 від 27 вересня 2018 року).
Підписано до друку 28.09.2018 р. Умовн. друк. арк. 26.

Адреса редакції: 49005, м. Дніпро, вул. Севастопольська, 19, редакція журналу „Morphologia".
Тел.: +380974584284. E-mail: morphology@dsma.dp.ua

ISSN 1997-9665

MORPHOLOGIA

2018 • Volume 12 • Number 3

Scientific specialized electronic journal of the Ukrainian public organization
"Ukrainian scientific Society of Anatomists, Histologists, Embryologists"
Periodicity – quarterly
Founders:
Ukrainian scientific Society of Anatomists, Histologists, Embryologists
State Institution "Dnipropetrovsk Medical Academy of Ministry of Healthcare of Ukraine"

Indexed by:
«NLM Catalog – US National Library of Medicine» (http://www.ncbi.nlm.nih.gov/nlmcatalog)
«Medical Journals Links» (http://www.medical-journals-links.com)
«CiteFactor Academic Scientific Journals» (http://www.citefactor.org)
International scientometric database «Российский индекс научного цитирования» (http://elibrary.ru/)
The current Impact Factor – 0,170

Certificated and included in the List of scientific specialized editions in which the main results of scientific works may be published (Order of Ministry of Education and Science of Ukraine № 1411 Oct 10, 2013).

Certificate of state registration № 26 Apr 25, 2014.

Reviews, critical and research articles are reviewed. Journal publishes scientific works of morphologists and also morphological works of specialists in other fields.

Published and recommended for distribution via the Internet according to the decision of the Academic Council of SI "Dnipropetrovsk Medical Academy of MH of Ukraine" (protocol № 3 Sep 27, 2018).
Signed for publishing on Sep 28, 2018. Conventional printed pages – 26.

Address: editorial office of journal "Morphologia", 19 Sevastopolska Str., Dnipro, Ukraine, 49005.
Tel.: +380974584284. E-mail: morphology@dsma.dp.ua

ISSN 1997-9665

MORPHOLOGIA

2018 • Том 12 • Номер 3

Научный специализированный электронный журнал Всеукраинской общественной организации "Научное общество анатомов, гистологов, эмбриологов и топографоанатомов Украины"
Периодичность издания – 4 раза в год
Учредители:
ВОО «Научное общество анатомов, гистологов, эмбриологов и топографоанатомов Украины»
ГУ «Днепропетровская медицинская академия Министерства здравоохранения Украины»

Индексация журнала:
«NLM Catalog – US National Library of Medicine» (http://www.ncbi.nlm.nih.gov/nlmcatalog)
«Medical Journals Links» (http://www.medical-journals-links.com)
«CiteFactor Academic Scientific Journals» (http://www.citefactor.org)
Международная наукометрическая база «Российский индекс научного цитирования» (http://elibrary.ru)
Текущий импакт-фактор – 0,170

Аттестован как периодическое электронное научное издание в области медицинских наук и включен в Перечень научных специализированных изданий Украины, в которых могут публиковаться результаты диссертационных работ (Приказ Министерства образования и науки Украины от 10.10.2013 г. № 1411).

Свидетельство о государственной регистрации № 26 от 25.04.2014 г.

Обзорные, проблемные и оригинальные статьи рецензируются. Журнал публикует научные работы морфологов, а также результаты морфологических исследований специалистов других специальностей.

Издается и рекомендуется для свободного распространения в сети Internet по решению ученого совета ГУ «Днепропетровская медицинская академия МЗ Украины» (протокол № 3 от 27 сентября 2018 года).
Подписано в печать 28.09.2018 г. Усл. печ. л. 26.

Адрес редакции: 49005, г. Днепр, ул. Севастопольская, 19, редакция журнала „Morphologia”.
Тел.: +380974584284. E-mail: morphology@dsma.dp.ua

ЗМІСТ

CONTENTS

Оглядові та проблемні статті

Reviews and topical articles

Оригінальні дослідження

Research, original papers

V.G. Dudenko [1]
V.Yu. Vdovichenko [2]
I.M. Korobka [3]

[1,2] Kharkiv National Medical University,
[3] Kharkiv city policlinic № 3, Kharkiv, Ukraine

Надійшла: 22.08.2018
Прийнята: 24.09.2018

DOI: https://doi.org/10.26641/1997-9665.2018.3.74-78

UDC 611.94:611.26:004.94:004.932

CLINICAL MORPHOMETRY OF MALE'S DIAPHRAGM IN THE SAGITTAL PLANE

The article is a fragment of research work «Individual anatomical variability of the human diaphragm structure» (state registration № 0115U000242).

© Morphologia. – 2018. – Т. 12, № 3. – С. 74-78.

✉ osta.dept@gmail.com

Dudenko V.G., Vdovichenko V.I., Korobka I.M. Clinical morphometry of male's diaphragm in the sagittal plane.
ABSTRACT. Background. Individual spatial topography of the diaphragm is of great importance for understanding the organization of the body in a particular clinical case. For diagnostic and particularly therapeutic manipulation knowledge of the individual characteristics of each patient is required. This knowledge allows you to avoid damage to the internal organs of the abdominal and thoracic cavities when they puncture (catheterization) and more accurately determine the localization of the pathological process, choose the method further surgical or conservative treatment. **Objectve.** The purpose of our research was determination of the individual characteristics of the spatial topography of the human diaphragm in two vertical planes — sagittal and frontal based on SCT-research depending on gender, age and somatotype. **Methods.** According to the results of the measurements reveal the presence (or absence) of the relationship between individual characteristics and spatial topography of gender, age and the type of body structure. **Results.** The resulting data were also used to make individual 3D modeling programs for human diaphragm. Material the data of 75 patients surveyed in the last 2 years about various diseases of the abdominal and thoracic cavities. Any diaphragm with pathology was excluded. Analysis and image processing were performed on a workstation "HP-Z820" c using the specialized program "Vitrea 2". Gender-based cases were: male – 61 and female – 14 cases. Age interval from 26 to 82 years old, according to the type of the structure revealed the following relationships — male hypersthenics — 35%, normosthenics — 60%, asthenics — 15%; for female following ratio was 30%, 50% and 20% resp. Type of body structure was determined by the index of Pinue. Due to the limited amount of messages we do not give all the findings are limited to the minimum and maximum values. The height of the cupola of a diaphragm and angles of its attachment in the sagittal plane have been calculated. The study of angles of attachment of the human diaphragm in the sagittal plane was made along next lines: vertebral (vl), paravertebral (pvl), scapular (sl) and posterior axillary (pal) lines for left side and the same lines except vertebral line for right side of body. Statistical analysis of the measurements revealed little correlation between the age and height of diaphragmatic cupolas in male. Other parameters were not correlated with the studied values (sex and type of body structure). **Conclusion**. Individual spatial topography of the diaphragm is highly variable and is practically independent of sex, age and type of body structure. In some cases (10%) in both sexes the height of the cupola of the diaphragm more on the left side than the right. Obtained data should be taken into account in the interpretation of X-ray research data and performing thoracentesis left.
Key words: morphometry, topography, attachment angle of diaphragm.

Citation:
Dudenko VG, Vdovichenko VI, Korobka IM. [Clinical morphometry of male's diaphragm in the sagittal plane]. Morphologia. 2018;12(3):74-8. DOI: https://doi.org/10.26641/1997-9665.2018.3.74-78.

Introduction

Individual spatial topography of the diaphragm is of great importance for understanding the organization of the body in a particular clinical case [5]. For diagnostic and particularly therapeutic manipulation knowledge of the individual characteristics of each patient is required. This knowledge allows you to avoid damage to the internal organs of the abdominal and thoracic cavities when they puncture (catheterization) and more accurately determine the localization of the pathological process, choose the method further surgical or conservative treatment [6,7].

Objective

The purpose of our research was determination of the individual characteristics of the spatial topography of the human diaphragm in two vertical planes — sagittal and frontal based on SCT-research depending on gender, age and somatotype [1,2].

According to the results of the measurements reveal the presence (or absence) of the relationship between individual characteristics and spatial topography of gender, age and the type of body structure. The resulting data were also used to make individual

3D modeling programs for human diaphragm [3,4].

Material and methods

Material the data of 75 patients surveyed in the last 2 years about various diseases of the abdominal and thoracic cavities. Any diaphragm with pathology was excluded. Analysis and image processing were performed on a workstation "HP-Z820" c using the specialized program "Vitrea 2".

Gender-based cases were: male – 61 and female – 14 cases. Age interval from 26 to 82 years old, according to the type of the structure revealed the following relationships — male hypersthenics — 35%, normosthenics — 60%, asthenics — 15%; for female following ratio was 30%, 50% and 20% resp. Type of body structure was determined by the index of Pinue. Due to the limited amount of messages we do not give all the findings are limited to the minimum and maximum values.

The height of the cupola of a diaphragm and angles of its attachment in the sagittal plane have been calculated.

The study of angles of attachment of the human diaphragm in the sagittal plane was made along next lines: vertebral (vl), paravertebral (pvl), scapular (sl) and posterior axillary (pal) lines for left side and the same lines except vertebral line for right side of body.

Presentation data show values of 2 angles of attachment of the human diaphragm in the sagittal plane in male on indicated lines: for the anterior (as) and posterior (ps) surfaces (Fig. 1).

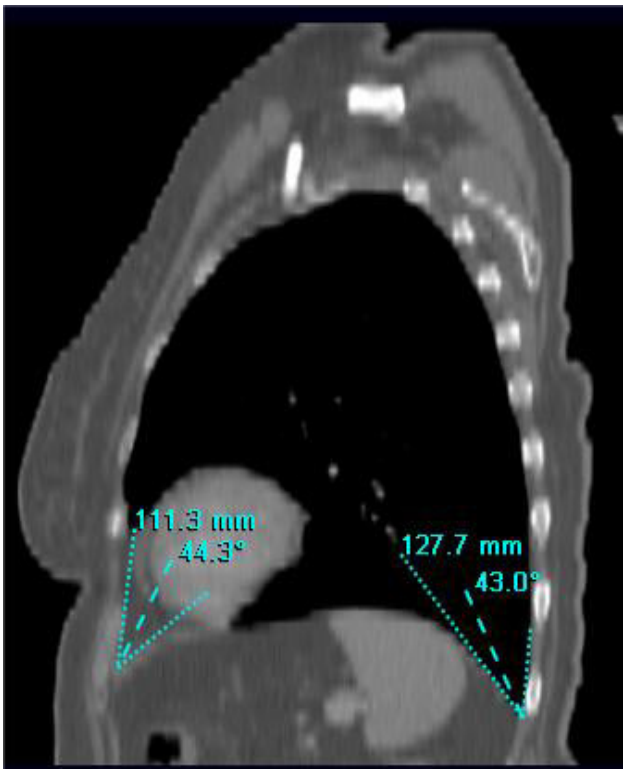

Fig. 1. Angles of attachment of the human diaphragm in the sagittal plane on the level of left scapular line.

Results and discussion

The data of the minimum and maximum values of the angle of attachment of the diaphragm in males are given in table 1.

Some values of the attachment of the diaphragm along the vertebral line (anterior surface) were met repeatedly. Thus, the value of 50.0° - 3 cases (46 years old, asthenic, 37 years old, normosthenic and 73 years old, hypersthenic), 52.3° - 3 cases (80 years old, hypersthenic, 69 years old, hypersthenic and 76 years old, normosthenic), 65.0° - 2 cases (79 years old, normosthenic and 80 years old, asthenic), 71.6° - 3 cases (43 years old, normosthenic, 63 years old, hypersthenic and 75 years old, normosthenic), 72.1° - 4 cases (74 years old, hypersthenic, 71 years old, normosthenic, 38 and 63 years old, asthenics), 76.0° - 3 observations (60 years old, asthenic, 66 and 53 years old, hypersthenics).

The greatest number of values is noted in the range from 70° to 80°. Such cases were 17 (28.3%). In the range from 50° to 60°, 14 (23.3%) cases were detected.

The second value along the vertebral line (posterior surface) for male were the following values: 9.2° - 2 cases (44 years old, asthenic and 66 years old, hypersthenic), 13.1° - 2 cases (59 years old, hypersthenic and 58 years old, asthenic), 24.6° - 2 cases (59 years old, hypersthenic and 66 years old, normosthenic), 25.5° - 2 cases (43 and 67 years old, hypersthenics).

Table 1

Minimum and maximum values of the angle of attachment of the diaphragm for male in the sagittal plane

line		Asthenics		Normosthenics		Hypersthenics	
		min	max	min	max	min	max
vl (grad.)	as	26,4°	58,6°	33,6°	95,4°	29,6°	60,0°
	ps	5,2°	40,2°	10,0°	43,4°	9,2°	48,4°
Left pvl	as	35,7°	91,0°	27,7°	89,2°	15,0°	02,8°
(grad.)	ps	20,5°	75,0°	23,3°	76,5°	17,1°	80,6°
Left sl	as	27,2°	83,5°	38,4°	106,0°	41,5°	01,8°
(grad.)	ps	27,1°	75,6°	23,3°	66,1°	24,0°	69,1°
Left pal	as	27,2°	92,6°	38,4°	106,0°	41,5°	01,8°
(grad.)	ps	24,0°	75,5°	16,1°	54,1°	23,1°	51,7°
Right pvl	as	32,6°	74,4°	16,1°	73,5°	42,4°	85,3°
(grad.)	ps	32,9°	80,5°	24,1°	76,1°	17,5°	72,5°
Right sl	as	28,2°	66,0°	21,7°	65,2°	36,3°	75,7°
(grad.)	ps	24,1°	69,7°	21,5°	70,4°	29,7°	74,5°
Right pal	as	22,1°	46,0°	16,6°	68,5°	19,5°	76,6°
(grad.)	ps	20,4°	63,0°	21,5°	81,7°	24,8°	75,5°

The most frequent values were in the interval from 10° to 20° - 21 cases, which was 35% and in the interval from 20° to 30° - 13 cases (21.6%). Thus, in the range from 10° to 30° - 56.6% of all cases were notated.

Some cases were found in the interval from 60° to 70° - 11 cases (18.3%). In the interval from 70° to 90° there were 16 cases (26.6%). Thus, 44.9% of observations were in the range from 60° to 90°. A total were made 42 measurements in male.

The second values for male along the left paravertebral line are the next: several values were repeated. This is 40.0° - 2 cases (72 years old, hypersthenic and 63 years old, asthenic) and 75.0° - 2 cases (50 years old, asthenic and 64 years old, normosthenic).

Angles of attaching the diaphragm along the left scapular line.

For male the first value was next: 53.2° - 2 cases (58 years old, asthenic and 26 years old, asthenic), 56.0° - 2 cases (46 years old, asthenic and 76 years old, normosthenic), 61.2° - 2 cases (36 years old, normosthenic and 53 years old, hypersthenic), 71.0° - 2 cases (80 years old, hypersthenic and 66 years old, asthenic).

The values in the interval from 50° to 60° were encountered more often. There were 15 observations (25%). In the range from 60° to 80° 41.6% of all observations were encountered. Thus, in the range from 50° to 80° 66.6% of all observations were contained.

The second values for male were: 33.5° - 3 cases (53 years old and 62 years old, both hypersthenics and 79 years old, normosthenic), 52.2° - 3 cases (74, 72 and 69 years old, hypersthenics), 60.0° - 2 cases (71 and 76 years old, normosthenics).

Values in the range from 30° to 40° were encountered the most often - 21 observations, which accounted for 35% of all observations. Thus, 58.3% is detected in the range from 30° to 50°.

The next line studied in the sagittal plane to the left is the posterior axillary line.

The first values (anterior surface) for male were next: 34.2° - 2 cases (62 and 34 years old, both hypersthenics), 36.9° - 2 cases (47 and 76 years old, normosthenics), 47.0° - 2 cases (66 years old, hypersthenic and 80 years old, asthenic), 55.0° - 4 cases (79 years old, hypersthenic, 75, 43 and 66 years old, normosthenics), 56.6° - 2 cases (50 years old, asthenic and 77 years old, hypersthenic), 57.5° - 2 cases (66 and 53 years old, hypersthenics).

The most often cases were encountered in the interval from 30° to 40° - 25 observations (41.6%) and from 50° to 60° - 15 observations (25%). Thus, in the interval from 30° to 60°, 83.2% of all observations were found.

Second values (posterior surface) in the posterior axillary line for male were next: 30.5° - 2 cases (37 years old, normosthenic and 69 years old, hypersthenic), 36.0° - 2 cases (62 years old, hypersthenic and 76 years old, normosthenic), 36.9° - 2 cases (37 and 53 years old, hypersthenics), 39.4° - 2 cases (80 years old, asthenic and 82 years old, normosthenic), 45.5° - 2 cases (74 and 72 years old, hypersthenics), 45.9° - 2 cases (58 and 71 years old, normosthenics).

Angles of attaching the diaphragm on the right side along the same lines.

For male, the first value of the joining angle were as follows: 32.9° - 2 cases (47 years old, normosthenic, 46 years old, asthenic), 48.3° - 3 cases (66 years old, hypersthenics , 58 years old, asthenic and 74 years old, hypersthenics), 58.2° - 4 cases (43, 77, 80 years old - hypersthenics and 54 years old, normosthenic), 59.7° - 2 cases (59 years old, hypersthenic and 63 years old, asthenic), 60.6° - 3 cases (76 years old, normosthenic, 67 years old, hypersthenics and 64 years old, normosthenic),

74.0° - 2 cases (80 years old, asthenic and 82 years old, normosthenic), 85.3° 2 cases (72 and 53 years old, hypersthenics).

Values in the range from 50° to 60° were encountered more often. There were 20 (33.33%). Thus, 56.6% was in the range from 40° to 60°.

The second value (posterior surface) on the left paravertebral line represented by the following: 43.0° - 2 cases (59 years old, hypersthenic and 58 years old, asthenic), 46.2° - 3 cases (47 and 75 years old, normosthenics and 26 years old, asthenic).

Values in the range from 40° to 50° were encountered more often. There were 22 observations (36.66%). Thus, in these intervals 51.66% of all cases were detected.

The next studied line in the sagittal plane was right scapular line. For male, first values in degrees were as follow: 34.1° - 2 cases (80 years old, asthenic and 44 years old, hypersthenic), 37.0° - 2 cases (63 years old, hypersthenic and 75 years old, normosthenic), 44.3° - 2 casess (33 years old, normosthenic and 75 years old, hypersthenic), 53,6° - 2 cases (58 years old, asthenic and 71 years old, asthenic).

Values in the range from 50° to 60° were encountered more often. There were 17 observations (28.33%). Thus, in the range from 30° to 70° over 75% of all observations was occurred.

The second values (posterior surface) on the right scapular line for male are represented by the following: 31.3° - 2 cases (66 years old, hypersthenic and 51 years old, normosthenic), 35.9° - 2 cases (26 years old, asthenic and 75 years old, normosthenic), 43.9° - 2 cases (50 years old, asthenic and 54 years old, normosthenic), 47.0° - 2 cases (75 years old, normosthenic and 76 years old, normosthenic).

The values in the range from 30° to 40° were more common. Thus, in the interval from 30° to 50° - 66.6% of all observations were detected.

Angles of attaching the diaphragm along the right posterior axillary line.

For male, the first values were next: 36.4° - 2 cases (74 and 80 years old, hypersthenics).

The values in the interval from 30° to 40° were more common. There were 23 cases (38.33%). Thus, in the range from 20° to 40° 64.99% of all observations were contained.

The second values (posterior surface) along the right posterior axillary line for male are represented by the following: 36.4° - 2 cases (75 and 73 years old, hypersthenics), 36.5° - 2 cases (62 years old, hypersthenic and 28 years old, asthenic), 43.1° - 2 cases (74 and 66 years old, hypersthenics), 46.0° - 2 cases (26 years old, asthenic and 36 years old, normosthenic), 51.4° - 2 cases (60 years old, asthenic and 45 years old, hypersthenic).

More often values were found in the range of 30° to 40° and 40° to 50°. Thus, in the interval from 30° to 50° 2 65% of all observations were detected.

Conclusions

1. Individual spatial topography of the diaphragm is highly variable and is practically independent of sex, age and type of body structure.

2. In some cases (10%) in both sexes the height of the cupola of the diaphragm more on the left side than the right.

3. Obtained data should be taken into account in the interpretation of X-ray research data and performing thoracentesis left.

Prospects for further research

For increase knowledge about the spatial topography of the human diaphragm further studies in other planes and projections relatively with sex, age and type of body structure are needed.

References

1. Dudenko VG, Avrunin OG, Tymkovych MYu, Kurinnyi VV. [Construction of the personified anatomical model of the human diaphragm]. Eksperymentalna i klinichna medycyna. 2014;2(63):68-70. Russian.

2. Dudenko VG, Kurinnyi VV. [Individual topography of the "weak" places of the human diaphragm]. In: [Morphology - medical science and practice; 2014 October 23-24; Minsk, Republic of Belarus]. BGMU; 2014. p. 103-105. Russian.

3. Dudenko VG, Kurinnyi VV. [Technique of processing medical images for preoperative modeling of the human diaphragm]. Eksperymentalna i klinichna medycyna. 2014;3(64):148-51. Russian.

4. Dudenko VG, Vdovichenko VYu, Kurinnyi VV. [Individual spatial topography of the human diaphragm based on spiral computed tomography]. In: [New in the medicine of the modern world; 2014 November 28-29; Lviv, Ukraine]. Lvivska medychna spilnota; 2014. p. 64-66. Russian.

5. Adams DC, Rohlf FJ, Slice DE. Geometric Morphometrics: Ten Years of Progress Following the 'Revolution'. Italian Journal of Zoology. 2004;71:5-16.

6. Ahmad I, Kaukab N, Ikram M, Hussain A. Anatomical Variations of Diaphragmatic Crura. Joumal of Rawalpindi Medical College. 2011;15(2):120-2.

7. Hsu-Chong Yeh, Halton KP, Gray CE. Anatomic Variations and Abnormalities in the Diaphragm Seen with USI. Radiographics. 1990;10(6):1019-30.

Дуденко В.Г., Вдовіченко В.Ю., Коробка І.М. Клінічна морфометрія діафрагми чоловіків в сагітальній площині.

РЕФЕРАТ. Для проведення діагностичних і лікувальних маніпуляцій має велике значення знання індивідуальної просторової топографії діафрагми пацієнта. Проведене дослідження з метою встановити індивідуальні особливості просторової топографії діафрагми людини в сагітальній площині на основі даних СКТ-дослідження з урахуванням статі, віку та соматотипу. Матеріалом були дані 75 пацієнтів обстежених з приводу захворювань різних органів черевної та грудної порожнин. Вимірювання кутів приєднання діафрагми вироблялося у сагітальній площині по вертебральній, паравертебральній, лопатковій та задній аксілярній лініях з обох сторін (переднє та заднє значення). Статистична обробка отриманих вимірювань виявила маленьку кореляційний залежність між віком і кутом прикріплення діафрагми у чоловіків. Інші показники не мали кореляції з досліджуваними значеннями (стать і тип будови тіла).

Ключові слова: морфометрія, топографія, кут приєднання діафрагми.

Дуденко В.Г., Вдовиченко В.Ю., Коробка И.Н. Клиническая морфометрия диафрагмы мужчин в сагиттальной плоскости.

РЕФЕРАТ. Для проведения диагностических и лечебных манипуляций имеет большое значение знание индивидуальной пространственной топографии диафрагмы пациента. Проведено исследование с целью установить индивидуальные особенности пространственной топографии диафрагмы человека в сагитальной плоскости на основе данных СКТ-исследования с учетом пола, возраста и соматотипа. Материалом послужили данные 75 пациентов обследованных по поводу заболеваний различных органов брюшной и грудной полостей. Измерение углов присоединения диафрагмы производилось в сагиттальной плоскости по позвоночной, парапозвоночной, лопаточной и задней подмышечной линиям с обеих сторон (переднее и заднее значение). Статистическая обработка полученных измерений выявила маленькую корреляционную зависимость между возрастом и углом прикрепления диафрагмы у мужчин. Остальные показатели не имели корреляции с изучаемыми значениями (пол и тип строения тела).

Ключевые слова: морфометрия, топография, угол присоединения диафрагмы.