

Research Article

Clinical, Neurophysiological and Immunological Peculiarities of Myasthenia Gravis in Patients with Different Histologic Types of Thymoma

Olena Tovazhnyanska¹, Hanna Samoilo^{1*}, Olena Protsenko², Natalia Remnyova², Yuri Kostya³

Abstract

Thymoma is characterized by various clinical manifestations. About half of them are manifested as an asymptomatic course, others occur in a combination with different syndromes. 25% of patients develop compression of tumor blood vessels, nerves and organs of the mediastinum or clinical signs of germination of thymic tumor in other organs. 40% of patients are diagnosed with autoimmune diseases due to dysfunction of the thymus. Generalized myasthenia gravis (75%) is most frequently observed.

The objective of the research was to study clinical and immunological peculiarities of myasthenia gravis depending on the size and histological type of thymoma.

Materials and methods. The results of clinical and immunological, instrumental and histological examination of 30 patients with myasthenia on the background of thymoma were analyzed. The severity of the disease was assessed using clinical classification of the Myasthenia Gravis Foundation of America (MGFA, 2001). To determine the barrier function of phagocytic cells, phagocytosis activity of neutrophils was evaluated using the light microscope. The phagocytic index, the phagocytic number and the index of phagocytosis completion were determined. The suspension culture of *Saccharomyces cerevisiae* was used as a microbial agent. Preparations were stained using the Romanovsky-Himze methods. Neutrophilic leukocytes were separated from leukocyte suspension of peripheral blood. The expression of differentiation clusters CD3+, CD4+ and CD8+ on subpopulation of T- and B-cells were evaluated by indirect ELISA using monoclonal antibodies labeled with FITC-dye. To diagnose thymoma, we used spiral CT "Marconi" SeleCT/SP. For histologic study thymoma samples were fixed in 10% neutral formalin for 24 hours. The material was embedded in paraffin after posting through the chloroform in the usual way; then, sections with the thickness of 5-7 μm were prepared. Preparations were stained with hematoxylin and eosin.

Results and conclusions. The severity of the clinical course of myasthenic syndrome on the background of thymoma does not depend on tumor size; it depends on the histologic type and immunological imbalance. The severest clinical picture was observed in patients with type AB thymoma and the least severe course of myasthenic symptoms was found in patients with lymphoid thymoma (type B1). Lymphoepithelial and epithelial thymomas were accompanied by similar immunological disorders. The reduction in the levels of CD3+ and CD4+ lymphocyte subpopulations can be used as a reliable diagnostic criterion. Lymphoid thymomas are characterized by a significant reduction in the indicators of the phagocytic index, the phagocytic number, and the level of CD8+ lymphocyte subpopulations as well as an increase in the level of CD4+ subpopulations. Surgical treatment as a method of choice in case of radical immunosuppression is indicated for all patients with confirmed thymoma regardless of its size and histological characteristics.

Keywords

myasthenia gravis; thymoma; immunological imbalance; electromyography

¹ Kharkiv National Medical University, Kharkiv, Ukraine

² V. N. Karazin Kharkiv National University, Kharkiv, Ukraine

³ V. T. Zaitsev Institute of General and Emergency Surgery of the Ministry of Health of Ukraine, Kharkiv, Ukraine

*Corresponding author: samoylova-hanna@i.ua

Problem statement and analysis of the recent research

Thymic neoplasms are the most common tumors of the anterior mediastinum including thymoma and carcinoma of the thymus [1, 2].

Thymomas constitute approximately 20% of mediastinal

tumors; their average incidence is 0.18 cases per 100,000 men and 0.10 cases per 100,000 women. Thymic carcinomas are rare tumors and represent less than 15% of all tumors of the mediastinum. They are more invasive than thymomas having worse prognosis [1].

The first case of the tumor of the thymus gland was described by Lantensau and Kay in 1867. Some publications

appeared later; however, they were mainly sectional findings. The term “thymoma”, being offered by Grandhomme and Schminke in 1900, is used to this day. However, some authors believe that the term “thymoma” is insufficient, since it refers only to the organ itself and does not reflect their histogenetic diversity [1-3].

Thymoma is usually a pale pink or grayish-white node, often with evident capsules of varying thickness and density. Multiple primary tumors are less common.

In 90% of cases, the tumor is located in the upper part of the anterior mediastinum. Thymomas of other localization (in the middle and posterior mediastinum, etc.) are associated with aberrant thymic tissue. Tumor size ranges from a few millimeters to a few tens of centimeters (averaging 6-8 cm) [2, 3].

Its heterogeneity is associated not only with different content of T-cells and their precursors in the tumor but with pronounced variability of epithelial cell morphology. Therefore, modern histogenetic classification includes the existence of two major subpopulations of thymic epithelial cells, namely the cortical and medullary thymic epithelial cells, which have different origins in embryogenesis [2, 3].

According to the latest histological classification of thymoma modified in 2004 by the WHO, thymic neoplasms are distinguished on the basis of histological and immunophenotypic affinity to the cortical or medullary layers of thymic cells. The WHO classification system defines the following histologic types [1]:

- Type A thymoma is defined as a tumor is composed of neoplastic thymic epithelial cells that have a spindle/oval shape, lack nuclear atypia, and are accompanied by few, if any, nonneoplastic lymphocytes;
- Type B1 is described as a tumor that resembles the normal functional thymus and combines large expanses having an appearance practically indistinguishable from the normal thymic cortex with areas resembling thymic medulla;
- Type B2 is a tumor in which the neoplastic epithelial component appears as scattered large epithelial cells with vesicular nuclei and distinct nucleoli against a heavy population of lymphocytes;
- Type B3 corresponds to tumors composed predominantly of epithelial cells having a round or polygonal shape and exhibiting no or mild atypia;
- Type AB thymoma is defined as a tumor in which foci having features of type A thymoma are admixed with foci showing features of type B thymoma;
- Type C thymoma is defined as a tumor exhibiting clear-cut cytologic atypia and a set of cytoarchitectural features no longer specific to the thymus, but rather analogous to those seen in carcinomas of other organs.

Thymoma is characterized by various clinical manifestations as well. About half of them are manifested as an asymptomatic course, others occur in a combination with different syndromes. 25% of patients develop compression of

tumor blood vessels, nerves and organs of the mediastinum or clinical signs of germination of thymic tumor in other organs. 40% of patients are diagnosed with autoimmune diseases due to dysfunction of the thymus. Generalized myasthenia gravis (75%) is most frequently observed [2, 3].

The objective of the research was to study clinical and immunological peculiarities of myasthenia gravis depending on the size and histological type of thymoma.

1. Materials and methods

The results of clinical and immunological, instrumental and histological examination of 30 patients (17 women and 13 men) with myasthenia against the background of thymoma treated at the thoracic department of V.T. Zaitsev Institute of General and Emergency Surgery of the Ministry of Health of Ukraine were summarized and analyzed. The severity of the disease was assessed using clinical classification of the Myasthenia Gravis Foundation of America (MGFA, 2001) [4, 5].

To determine the barrier function of phagocytic cells, phagocytosis activity of neutrophils was evaluated using the light microscope. The phagocytic index (PI), the phagocytic number (PN) and the phagocytosis completion index (PCI) were determined. The suspension culture of *Saccharomyces cerevisiae* was used as a microbial agent. Preparations were stained using the Romanovsky-Himze methods. Neutrophilic leukocytes were separated from leukocyte suspension of peripheral blood [6, 7].

The expression of differentiation clusters CD3+, CD4+ and CD8+ on subpopulation of T- and B-cells were evaluated by indirect ELISA using monoclonal antibodies labeled with FITC-dye [7].

To diagnose thymoma, we used spiral CT “Marconi” Se-leCT/SP. For histologic study thymoma samples were fixed in 10% neutral formalin for 24 hours. The material was embedded in paraffin after posting through the chloroform in the usual way; then, sections with the thickness of 5-7 μm were prepared. Preparations were stained with hematoxylin and eosin.

Statistical analysis of the results was performed using the software package Statistica 6. The average values and standard errors were calculated. Types of sign distribution among patients were determined using the Shapiro-Wilk test; the equality of variances for a variable was calculated using the Levene’s test.

The comparison of two groups with normal distribution was performed using classical Student’s t-test for independent samples and Student’s t-test with separate estimation of variances. The Mann-Whitney U test was used as a nonparametric test. Differences were considered significant at $p < 0.05$.

The control group consisted of 30 practically healthy individuals.

2. Results and Discussion

Myasthenia gravis was diagnosed in all patients (manifestation of the disease at the age of 48.3 ± 9.7 years). According to clinical classification of the MGFA, at the time of hospitalization 7 (23.3%) patients had MGF Class 3A, 13 (43.6%) patients had MGF Class 3B, 6 (20%) patients had MGF Class 4A, and 4 (13.1%) patients had MGF Class 5.

During neurological examination, severe weakness of the skeletal (average muscle strength of the upper and lower extremities accounted for 2.5 points) and respiratory muscles, oropharyngeal weakness (reduced excursion of the soft palate, difficulty in swallowing, dysphonia) were observed in all patients. 4 patients required mechanical ventilation (MV).

During electromyography (EMG), a significant decrease in the amplitude of negative phase M- response in musculus orbicularis oculi (0.44 ± 0.2 mV; in the control group – 0.9 ± 0.2 mV; $p < 0.05$), musculus abductor digiti minimi (3.96 ± 1.1 mV; in the control group – 5.1 ± 0.2 mV; $p < 0.05$) and increase in the response decrement rate ($49.02 \pm 5.8\%$, in the control group – $11.3 \pm 0.2\%$; $p < 0.05$) were observed compared to those in the control group.

According to the data of spiral CT of the thymus gland, the size of the thymus increased. In 10 patients, thymoma was in average 2.1 ± 0.6 in diameter. Clinical myasthenic syndrome in this group of patients was characterized by a decrease in muscle strength in the limbs to 2.5-3.0 points as well as the presence of dysarthria and dysphagia. 2 patients were diagnosed with the myasthenic crisis thereby requiring MV.

According to clinical classification of the MGFA, at the time of hospitalization 2 patients had MGF Class 3A, 4 patients had MGF Class 3B, 2 patients had MGF Class 4A, and 2 patients had MGF Class 5.

11 patients were diagnosed with thymoma being 4.4 ± 0.8 cm in diameter. Dysphagia and dystonia on the background of muscle weakness being 2.0-3.0 points were detected as well. Severe course of the disease which required MV was observed in 1 patient. According to clinical classification of the MGFA, at the time of hospitalization 3 patients had MGF Class 3A, 5 patients had MGF Class 3B, 2 patients had MGF Class 4A, and 1 patient had MGF Class 5.

The largest size of thymoma being 8.3 ± 1.3 cm in diameter was found in 9 patients; however, the clinical picture of myasthenia gravis did not significantly differ from the previous two groups. According to clinical classification of the MGFA, at the time of hospitalization 2 patients had MGF Class 3A, 4 patients had MGF Class 3B, 2 patients had MGF Class 4A, and 1 patient had MGF Class 5.

The study of the phagocytic function in all patients with myasthenia and co-existent thymoma revealed significant ($p < 0.05$) reduction in the PI to $32.4 \pm 2.6\%$ (in the control group – $73.1 \pm 9.0\%$) and the PN to 2.1 ± 0.5 (in the control group – 3.6 ± 0.1) with the preservation of the PCI within the control values [6].

The same dynamics of the phagocytic function was ob-

served in all groups of patients regardless of tumor size. When studying the parameters of T-cell immunity, we found a significant ($p < 0.05$) reduction in CD4+ to $21.0 \pm 9.4\%$ and CD8+ to $13.0 \pm 3.7\%$ (in the control group – $29.0 \pm 8.6\%$ and $18.0 \pm 4.5\%$, respectively), the severity of which did not depend on the size of thymoma.

Considering the variability of histological thymoma all the examined patients were divided into three groups according to the WHO classification and histological type of thymus gland tumor.

Group I included 12 patients with histologically confirmed lymphoepithelial thymoma (type AB according to the WHO classification) (Fig. 1). The clinical picture of myasthenia gravis was characterized by considerable generalized muscle weakness (muscular strength in the legs was 2.5-3.0 points) and severe bulbar disorders; 8 patients had MGF Class 3B and 2 patients had MGF Class 4A. 2 patients with MGF Class 5 required MV.

Group II consisted of 8 patients with histologically confirmed epithelial thymoma (type B3 according to the WHO classification). Myasthenia gravis manifested itself as severe muscle weakness (muscular strength in the extremities of 3.0-3.5 points) and bulbar disorders. According to clinical classification of the MGFA, all patients were divided as follows: 2 patients with MGF Class 3A, 3 patients with MGF Class 3B, 2 patients with MGF Class 4A, 1 patient with MGF Class 5. Group III included 10 patients with lymphoid thymoma (type B1 according to the WHO classification). The clinical picture of myasthenia gravis was characterized by severe lesions of skeletal muscles (muscle strength in the limbs was 3.0-3.5 points) and moderate bulbar disorders; 5 patients had MGF Class 3A, 2 patients had MGF Class 3B and 2 patients had MGF Class 4A. 1 patient with MGF Class 5 required MV.

The results of immunological study in patients with myasthenia and co-existent thymoma based on histological types of tumors are presented in Tables 1 and 2. The maximum reduction in the PI (by 1.5 times) was observed in patients with type B1 thymoma. In patients with type AB and type B3 thymoma, the reduction in this indicator was significant as well; however, it was less pronounced (by 1.1 and 1.2 times compared to the control group) (Table 1).

The reduction in the PN was observed in groups with type AB and type B1 thymoma (by 1.3 and 1.2 times, respectively), and in patients with epithelial thymoma, this indicator increased by 1.2 times. The PCI in patients with epithelial thymoma increased twofold; in patients of other groups this indicator did not significantly differ from the control group (Table 2).

Patients with type AB and type B3 thymoma noticed a significant reduction in CD3+ by 1.5 and 1.8 times, respectively, which was not observed in the group of patients with type B1 thymoma (Table 2).

The level of CD4+ cluster was significantly depressed in the group of patients with type AB and type B3 thymoma; the level of CD8+ in these groups was not significantly different

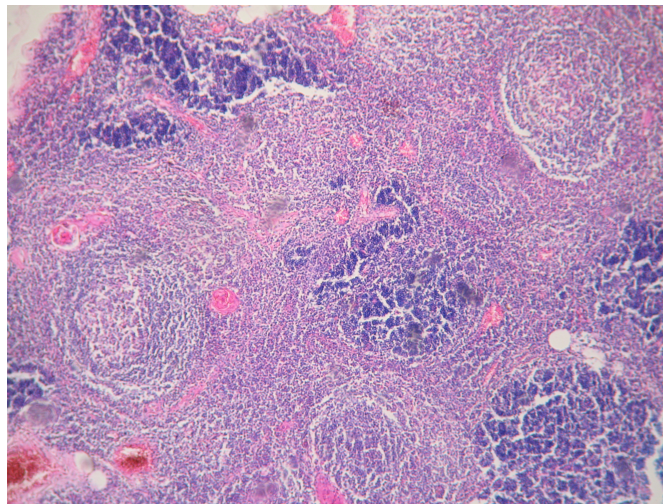


Figure 1. Thymus. Lymphoepithelial thymoma with lymphoid follicles and germinal centers.

Staining with hematoxylin and eosin.

Magnification: x100.

Table 1. Changes in primary indicators of immunity in patients depending on histological characteristics of thymoma.

Morphological structure of the thymus	PI, %	PN	PCI
Control group, n=30	73.1±9.0	3.6±0.1	1.1±0.2
Patients with lymphoepithelial thymoma (type AB), n=12	65.3±8.7*	2.7±0.5*	1.1±0.3
Patients with epithelial thymoma (type B3), n=8	61.4±10.9*	4.3±1.5*	2.3±0.7*
Patients with lymphoid thymoma (type B1), n=10	47.8±16.9*	2.8±0.4*	1.7±0.8

Note.

* - size differed significantly from that in the control group (p<0.05).

Table 2. Changes in indicators of T-cell immunity in patients with thymoma depending on histological characteristics.

Morphological structure of the thymus	CD3+, %	CD4+, %	CD8+, %
Control group, n=30	52.0±11.4	29.0±8.6	18.0±4.5
Patients with lymphoepithelial thymoma (type AB), n=12	35.6±10.1*	13.8±12.1*	14.3±12.7
Patients with epithelial thymoma (type B3), n=8	28.6±12.9*	15.9±5.1*	13.5±11.5
Patients with lymphoid thymoma (type B1), n=10	49.2±14.7	37.9±7.4*	7.9±3.4*

Note.

* - size differed significantly from that in the control group (p<0.05).

from that in the control group. In patients with lymphoid thymoma (type B1), CD4+ exceeded the reference value by 1.3 times, and cytotoxic T- lymphocytes (CD8+) were significantly depressed (Table 2).

Summarizing the findings it should be noted that myasthenic symptoms in patients with thymoma are of generalized character and are accompanied by severe weakness of the skeletal (average muscle strength of the upper and lower extremities accounted for 2.5 – 3.0 points) and respiratory muscles, oropharyngeal weakness. According to clinical clas-

sification of the MGFA, 13 (43.6%) patients had MFFA Class 3B and 6 (20%) patients had MFFA Class 4A.

The development of myasthenia gravis in patients with thymoma is accompanied by immunological disorders in the form of the reduction in the PI and the PN as well as the levels of CD4+ and CD8+ clusters. Clinical and immunological comparison depending on the size of thymoma and its histologic type showed that the severity of myasthenic symptoms and immunological disorders do not depend on the size of thymoma. At the same time, various histologic types of thy-

moma are characterized by various clinical manifestations of myasthenia gravis and immunological disorders.

For example, lymphoepithelial and epithelial thymomas were accompanied by considerable weakness of the limbs as well as bulbar muscles, which was combined with equally directed impaired T-cell immunity - a significant reduction in the levels of CD3+ and CD4+ subpopulations and the tendency to the reduction in the levels of CD8+ clusters.

The differences in immunological disorders were associated with the primary immune response: myasthenia gravis secondary to lymphoepithelial thymoma was accompanied by a significant reduction in the PI and the PN; myasthenia gravis with co-existent epithelial thymoma was accompanied by a significant reduction in the PI and increase in the PN and the PCI.

In case of lymphoid thymoma, myasthenic symptoms are characterized by a predominance of limb lesions; they are accompanied by significant (compared to that in the control group and other groups) reduction in the PI, the PN, subpopulations of CD8+ and increase in CD4+ levels.

Surgical treatment was used in all cases as a radical method of immunosuppression. It should be noted that 80% of patients in the postoperative period had a tendency to myasthenic syndrome regression and reduction in neostigmine methylsulfate dosage. 3% of patients (type AB thymoma) had a complicated postoperative period (myasthenic crisis), which required replaceable plasma exchange with the subsequent administration of glucocorticoids (prednisolone).

3. Conclusions

The severity of the clinical course of myasthenic syndrome secondary to thymoma does not depend on tumor size; it depends on the histologic type and immunological imbalance. The severest clinical picture was observed in patients with type AB thymoma and the least severe course of myasthenic symptoms was found in patients with lymphoid thymoma (type B1).

Lymphoepithelial and epithelial thymomas are accompanied by similar immunological disorders. The reduction in the levels of CD3+ and CD4+ lymphocyte subpopulations can be used as a reliable diagnostic criterion.

Lymphoid thymomas are characterized by a significant reduction in the indicators of the PI, the PN, and the level of CD8+ lymphocyte subpopulations as well as an increase in the level of CD4+ subpopulations.

Surgical treatment as a method of choice in case of radical immunosuppression is indicated for all patients with confirmed thymoma regardless of its size and histological characteristics.

References

- [1] Zakharych VD, Ganul AV. Thymus tumors: diagnosis and treatment. 2014. Available from: http://health-ua.com/pics/pdf/ZU_2014_Onko_3/17.pdf.
- [2] Kharchenko VP, Chkhikvadze VD, Kolesnikov PG, et al. [Treatment of thymomas associated with myasthenia]. *Vestnik Rossiyskogo Nauchnogo Tsentra rentgenoradiologii*. 2011;11:1–11
- [3] Machaladze ZO, Davyidov MI, Polotskiy BE, et al. Tumors of the thymus gland. *Vestnik RONTs im. NN Blogina RAMN*. 2008;1(19):47–58
- [4] Shkolnik VM, Kalbus AI, Shulga OD. Myasthenia gravis: what do we know today. Available from: http://health-ua.com/pics/pdf/ZU_2010_Nevro_3/10-11.pdf.
- [5] Kerty E, Elsaïs A, Argov Z, et al. EFNS/ENS Guidelines for the treatment of ocular myasthenia. *European Journal of Neurology*. 2014;2:687–693. DOI: <http://dx.doi.org/10.1111/ene.12359> [PMid: 24471489]
- [6] Tovazhnyanskaya EL, Klimova EM, Samoylova AP, et al. Clinical and immunological features of patients, depending on the structure of the thymus. *Neurology and Neurosurgery. Eastern Europe*. 2015;4(28):15–23
- [7] Klimova EM, Boyko VV, Drozdova LA, et al. Features of immuno-biological reactions in patients with different clinical types of myasthenia gravis. *Kharkivska khirurhichna shkola*. 2014;3(66):46–52

Received: 26 September 2016

Revised: 18 October 2016

Accepted: 24 October 2016